

# Recurring Ischemic Infarcts Showing Biermer's Disease Associated with Protein S Deficiency

GUINHOYA Kokou Mensah<sup>1</sup>, AGBA Lehleng<sup>2</sup> and ANAYO Nyinevi<sup>3</sup>

<sup>1</sup> Universite de Lome

*Received: 13 December 2015 Accepted: 2 January 2016 Published: 15 January 2016*

## Abstract

Observation-Mrs ASS?.AKOU, 36 married and right handed household was at her second episode of stroke in six months. Concerning her history; six months ago, during her first episode of stroke she was discovered and known to have a high blood pressure in the left anterior cerebral artery, responsible of an after effects right crural hemiparesis at 4/5. She was not using hormonal contraception and there was not a sign of alcoholic or tobacco intoxication. Since six months she has been under second prevention with acetylsalicylic under 100 mg per day and sartan 150 mg per day. The current episode was marked by a brutal installation of a left hemi body deficit predominant to inferior member in the morning of 26th December 2014 at her home. When she was admitted the exam allowed to note a blood pressure of 160/80 Hg in the left hand and 160/90 mmHg in the right, a beat of 78 pulsations per minute, a temperature at 37°C talking of a neurology she was conscious without trouble of superior functions.

## Index terms—

Recurring Ischemic Infarcts Showing Biermer's Disease Associated with Protein S Deficiency Kokou Mensah Guinhouya ? , Léhleng Agba ? , Nyinévi Anayo ? & Mofou Belo ? Observation-Mrs ASS?.AKOU, 36 married and right handed household was at her second episode of stroke in six months Concerning her history; six months ago, during her first episode of stroke she was discovered and known to have a high blood pressure in the left anterior cerebral artery, responsible of an after effects right crural hemiparesis at 4/5.

She was not using hormonal contraception and there was not a sign of alcoholic or tobacco intoxication. Since six months she has been under second prevention with acetylsalicylic under 100 mg per day and sartan 150 mg per day.

The current episode was marked by a brutal installation of a left hemi body deficit predominant to inferior member in the morning of 26 th December 2014 at her home. When she was admitted the exam allowed to note a blood pressure of 160/80 Hg in the left hand and 160/90 mmHg in the right, a beat of 78 pulsations per minute, a temperature at 37°C talking of a neurology she was conscious without trouble of superior functions. She was presenting a paraplegia with no sensitive level nor trouble of sphincter with a left predominance and mortice forces at 4/5 in the right inferior member and 1/5 in the left inferior member. There was signs of spasticity in the right inferior member. The cerebral scan CT which was urgently made allowed to objective post ischemic after effect in the left anterior cerebral artery and a sharp phase of ischemic in the right anterior cerebral artery (fig 1). The injected tomography from supra aortic artery trunks was normal. The electrocardiogram was at a sinusal rhythm and so was the transthoracic and the trans oesophagus echography. The hemogram showed a slight anaemia (haemoglobin = 11,5 g/dl) macrocytic (MCV = 115 fl). The mixture protein S and C showed a deficit in protein S. the renal and hepatic functions was normal.

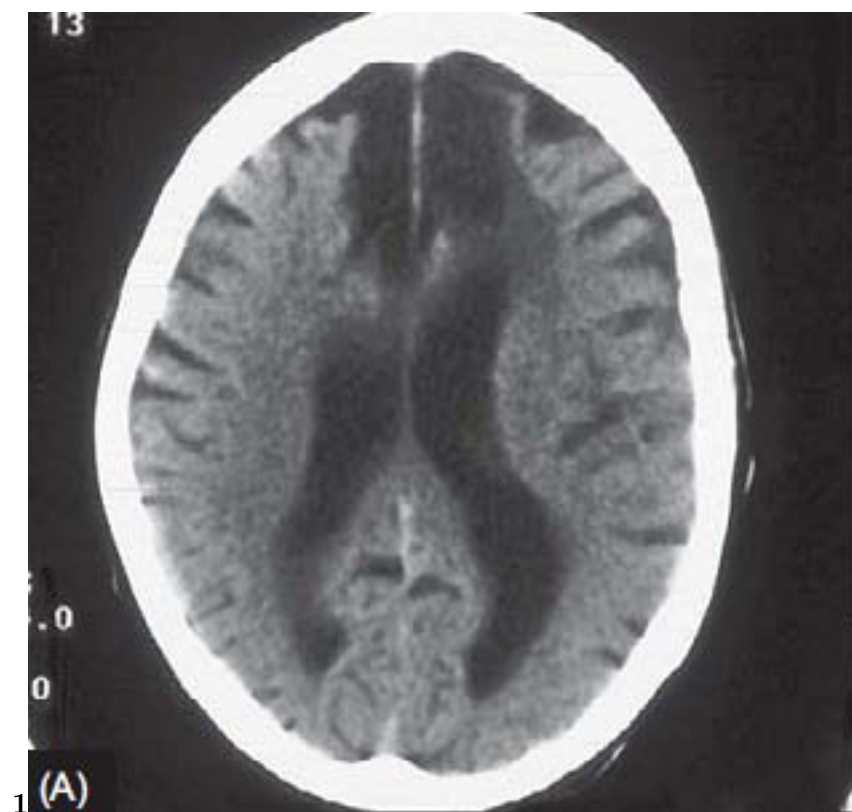


Figure 1: Figure 1 :

- 
- 42 [Bamford et al. ()] ‘A prospective study of acute cerebrovascular disease in the community: the Oxfordshire  
43 Community Stroke Project 1981-86. 2. Incidence, case fatality rates and overall outcome at one year of  
44 cerebral infarction, primary intracerebral and Author ? ? ? ? : Service de neurologie du CHU Sylvanus  
45 OLYMPIO’. J Bamford , P Sandercock , M Dennis , J Burn , C Warlow . *J Neurol Neurosurg Psychiatry*  
46 1990. 57 p. . (BP)
- 47 [Tairou et al. ()] ‘Création d’un système d’approvisionnement en médicaments essentiels et de recouvrement des  
48 coûts dans la région centrale du Togo’. A Tairou , A Stadler , A K Ahawo . *Echos de santé* 1996. 34 p. .
- 49 [Bougteba et al. (2009)] ‘Infarctus cérébral récidivant révélant une maladie de Biermer’. A Bougteba , A Basir ,  
50 N Kissani . *Rev Neurol* 2009 Dec. 165 (12) p. .
- 51 [Bevan et al. ()] ‘Stroke in young adults’. H Bevan , K Sharma , W Braley . *Stroke* 1990. 21 p. .
- 52 [Rodeghiero and Tosetto ()] ‘The epidemiology of inherited thrombophilia: the VITA Project. Vicenza Throm-  
53 bophilia and Atherosclerosis Project’. F Rodeghiero , A Tosetto . *Thromb Haemost* 1997. 78 p. .