Volume 20 Issue 13
Originally issued as A1

Global Journal of Medical Research: A
Neurology and Nervous System
Volume 20 Issue 1 Version 1.0 Year 2020
Type: Double Blind Peer Reviewed International Research Journal
Publisher: Global Journals
Online ISSN: 2249-4618 & Print ISSN: 0975-5888

Neurological Symptoms in Patients with Mild Combat Traumatic Brain Injury

By Volodymyr Korshnyak
Institute of Neurology, Psychiatry and Narcology

Abstract- We evaluated 97 patients aged 23 to 37 years in the acute period of mild combat traumatic brain injury, prescription of which was from 2 to 5 days. We observed the loss of consciousness (from 5 to 20 minutes) in 39 individuals. We studied in detail the neurological status and state of the autonomic nervous system. We obtained the data that allowed to note the peculiarities of the disease course depending on the vector of action of the explosive injury with regard to the body side. Under the impact of the blast wave to one of the body sides we observed the following features as a nonspecific hemi syndrome, decreased of sensitivity to pain, decreased smell, decreased pain sensitivity on the tongue, decreased taste, hearing, decreased periosteal and tendon reflexes, decreased muscle strength and tonus on the side of the sensory defect, and when the direction of the blast is frontal (to the face), the clinical course of the disease is much more severe.

Keywords: acute combat traumatic brain injury, sensori motor nonspecific hemi syndrome, vegetative disorders, "sleep-waking" cycle disorders.

GJMR-A Classification: NLMC Code: WE 706

Strictly as per the compliance and regulations of:

© 2020. Volodymyr Korshnyak. This is a research/review paper, distributed under the terms of the Creative Commons Attribution Noncommercial 3.0 Unported License http://creativecommons.org/licenses/by-nc/3.0/), permitting all non-commercial use, distribution, and reproduction in any medium, provided the original work is properly cited.

Neurological Symptoms in Patients with Mild Combat Traumatic Brain Injury

Volodymyr Korshnyak

Abstract- We evaluated 97 patients aged 23 to 37 years in the acute period of mild combat traumatic brain injury, prescription of which was from 2 to 5 days. We observed the loss of consciousness (from 5 to 20 minutes) in 39 individuals. We studied in detail the neurological status and state of the autonomic nervous system. We obtained the data that allowed to note the peculiarities of the disease course depending on the vector of action of the explosive injury with regard to the body side. Under the impact of the blast wave to one of the body sides we observed the following features as a non-specific hemi syndrome, decreased of sensitivity to pain, decreased smell, decreased pain sensitivity on the tongue, decreased taste, hearing, decreased periosteal and tendon reflexes, decreased muscle strength and tonus on the side of the sensory defect, and when the direction of the blast is frontal (to the face), the clinical course of the disease is much more severe. We also observed the total anesthesia, violation of discriminative types of sensitivity throughout the whole body, accentuation of the sensory defect in distal parts of extremities and on the scalp, with a combination of a group of axial, hand, pathological foot reflexes.

Thus, we can characterize the clinical picture of a mild combat traumatic brain injury as having a significantly severe course, and it is much different from a civilian traumatic brain injury.

Keywords: acute combat traumatic brain injury, sensori motor nonspecific hemi syndrome, vegetative disorders, "sleep-waking" cycle disorders.

I. Introduction

Definition of mild traumatic brain injury (mTBI) caused by an explosive wave is a problem in both wartime and peacetime. American Ministry of Defense determines a mild traumatic brain injury as a "head trauma associated with a loss or alteration of consciousness for up to 30 minutes, loss of consciousness for the period not less than 24 hours or post-traumatic amnesia which lasts not less than 24 hours».

In our opinion, the mTBI, which is caused by the blast wave, differs from the other forms of a closed TBI in that the physical forces resulting from the blast wave and causing the TBI differ from the physical forces causing the closed civilian TBI, which in our opinion is more than reasonable.

Combat traumatic brain injuries are the complex combined brain injuries that includes concussion, acoustic injuries, vibration traumas, additional contusions to the head, spine, lung, heart, and other organs and body parts. However, an integral part of all barotraumas is a real concussion as a result of an air wave action that corresponds to a short massive blow by a wide, dense surface [2, 3, 4, 5].

The main clinical manifestations of trauma (loss of consciousness, hearing and speech, headache, dizziness, amnesia) are associated with changes in the brain so that the overall impact of a shockwave on other parts of the body tends to be secondary. But this effect remains, and above all, it is a very strong, short-term effect on the baroreceptors, tactile receptors, and skin pain receptors, the number of which on each square centimeter of the skin reaches dozens. That is, there is a super-powerful flow of afferent impulse, which can cause inhibition of the activity of brain structures, especially the basal ones, which causes their desynchronization and imbalance, which worsens the consequences of the direct impact of a shock wave on the same structures and forms specific neurological symptoms at the patient in the future.

II. Aim of the Work

To study the features of the clinic and neurological status in combatants with mild traumatic brain injury.

III. Research Materials

We examined the clinical characteristics of the acute period of mild combat TBI in 97 patients who were on inpatient treatment at the neurological department of the Military Medical Clinical Center of the Northern region and at the neurosurgical clinic of the Institute of Neurology, Psychiatry, and Narcology of the Academy of Medical Sciences of Ukraine from 2014 till 2018.

The study included patients who met the following criteria: a) age 23 - 37 years; b) no somatic and neurological depressing history; c) presence of only mild TBI (without alcoholic intoxication, chest injuries, tuberculosis at the time of injury, and other somatic, mental disorders). These criteria allowed us to exclude as much as possible factors that significantly affected the course of the disease. Neurological status was examined and studied in detail.

Author: State Institution "Institute of neurology, psychiatry and narcology of the National academy of medical sciences of Ukraine", Kharkiv, Ukraine. e-mail: korshnyak.doc@gmail.com

© 2020 Global Journals

IV. The Obtained Results and Discussions

Through the initial survey, it was found that most patients at the time of injury estimated the distance from the site of the projectile or mine explosion for 4 to 6 or 10 meters. The duration of trauma at the time of the survey was between 2 and 5 days. At the time of injury, 39 people lost consciousness (for the period of 5 to 20 minutes).

The major complaints of patients in the acute period were headache, vegetative disorders, unsteady gait, fatigue, memory loss, and impaired sleep-wake cycle.

All examined patients complained of a headache. Its localization was not the same in these patients: in 41 patients, it was localized in the frontotemporal region; in 35 - in the left or right side of the head; in 12 - the pain was localized in the occipital region and 9 people - the headache was diffuse, "the pain through the whole head." (Table 1).

The frequency of occurrence of subjective manifestations of the acute period of the combat TBI, such as headache, dizziness, nausea, noise in the head, general weakness, sleep disturbance, are presented in table 1.

Table 1: The major complaints in the acute period of the mild TBI caused by the explosive wave

Complaints	Number of patients	P
Headache	97 (100%)	<0,05
- persistent	71 (73%)	<0,05
- cyclic	26 (27%)	
Dizziness	82 (85%)	<0,05
- persistent	18 (19%)	
- cyclic	64 (66%)	<0,05
Vomiting	78 (81%)	<0,05
Pain in eyes	72 (74%)	<0,05
Noise in head and ears	65 (67%)	<0,05
Asthenic signs	91 (94%)	<0,05
Hyperhidrosis	59 (61%)	<0,05
Memory impairment	85 (88%)	<0,05
Drowsiness throughout the day	77 (80%)	<0,05
Sleep disorders	91 (94%)	<0,05
Fears	24 (25%)	
Finger tremor	57 (59%)	<0,05

The major complaint during the initial examination of patients was a headache, which occurred in all 97 patients ($p < 0.05$). In 71 patients, the headache was persistent. The nature of the headache was pressing, bursting, mainly in the frontotemporal and parietal areas with a feeling of pressure on the eyeballs. Heavy headedness was noted by 81 (84%) of the examined. When turning the head, 42 (43%) of the patients complained of increased dizziness and nausea.

The cyclic dizziness was noted in patients in 64 (66%) cases and was accompanied by severe affective (fear, anxiety) and vegetative phenomena.

The asthenic manifestations were observed in the acute period in 91 (94%) of the examined patients and characterized by physical and neuropsychic weakness, a feeling of fatigue and general malaise, inability for prolonging neuropsychic and physical stress; there were objective signs of a decrease in the functional capabilities of the body and personality-decreased functioning, fatigue, the inability to perform even easy types of any activity. This condition did not improve after sleep and rest and was observed in them about 2-3 months later after the cerebral trauma.

Sleep disturbance observed in 91 (94%) of the examined persons and manifested itself in the superficial nature of sleep, in complaints about lack of rest, premature awakening, sleepiness during the day ("I would like to sleep, but something does not let me do that"), weakness and tiredness during the day.

There are various pathophysiological processes in the genesis of asthenic manifestations, which may include: a) disorders of neurodynamics of cortical processes resulting from trauma - weakening of internal inhibition, exhaustion of excitation, damage to the intermediate brain and weakness of activating influence of the ascending reticular formation; b) disorders of limbic mechanisms of emotions, motivations and activating nonspecific systems of diencephalon and mesencephalon, and disorders of cortical-subcortical balance.

We noted the sleep disturbances during the initial examination of 91 (94%) patients, which was manifested in light, superficial sleep, as well as premature awakening, which was further expressed by severe drowsiness during the day, sleepiness, and weakness. Regardless of the structure of sleep

© 2020 Global Journals

disturbance, patients complained of a lack of rest, often night and morning headaches. All this indicates dysfunction in non-specific brain systems, which is caused by a violation of the relationship between the activating and synchronizing systems of the brain, which specifically disrupts the sleep-wake cycle.

In most cases, patients complained of pronounced general weakness, rapid fatigability, constant nausea, impaired sleep-wake cycle, a sharp decrease in memory for current events, and drowsiness during the day.

Neurological status was not the same for all patients and depended on the direction of the blast wave with regard to the patient's side.

We want to note that in 9 patients the direction of the shock wave was "to the face" (Fig. 1). With a detailed objective neurological examination, they observed a slowdown in motor activity, anosmia on both sides, paresis of the eyeballs, the lack of reaction of the pupils to light, facial amimia. Movement of the eyeballs to the sides was impossible (the patient watched the subject with his eyes turning his head)-the syndrome of doll eyes. There was a deterioration in hearing from two sides, speech was quiet and slow downed. The increase in sound strength caused painful facial expressions.

Also, we noted a sharp decrease in strength in the distal extremities, in tendon and periosteal reflexes up to the areflexion. The coordination test was not performed clearly by patients. Rough ataxia with static tests took place. We observed the severe hyperhidrosis (especially of the distal extremities). The skin of the upper and lower extremities was bluish (according to the type of long "socks" and "gloves") (Fig. 1).

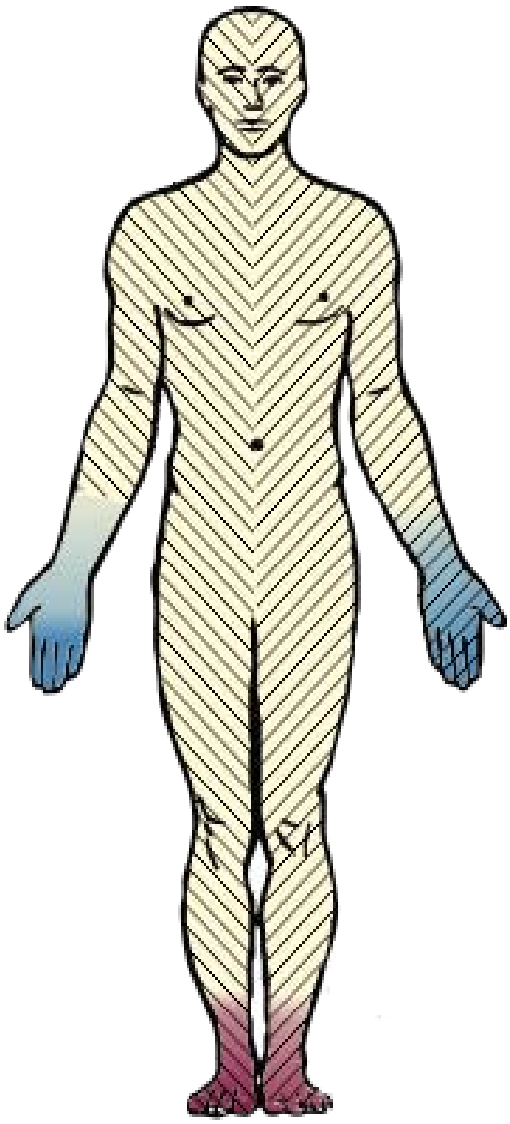

Figure 1: The vector of the blast wave action to the face

© 2020 Global Journals

We noted the swollened distal parts of extremities (especially in the ankle segment) and limited finger movements due to pain.

When a blast wave was directed to one side (right or left) of the head or body, we observed sensitivity disorders of hemihypalgesia type, which were distinguished by significant severity, relative homogeneity, weak dynamism, or unusual stability of sensory hypesthesia on the same side (Fig. 2). At the same time, on the side of the sensory defect, there was no corneal reflex, a slight decrease in smell, pain sensitivity in the tongue, and a decrease in taste and hearing were noted. On the side of the sensory defect, inhibition of periosteal and tendon reflexes, the decreased muscle strength, and muscle tone in the limbs were observed. We noted a mild upper and lower Barre's syndrome. In most of the examined patients this syndrome was stable, without significant dynamics for a year or more.

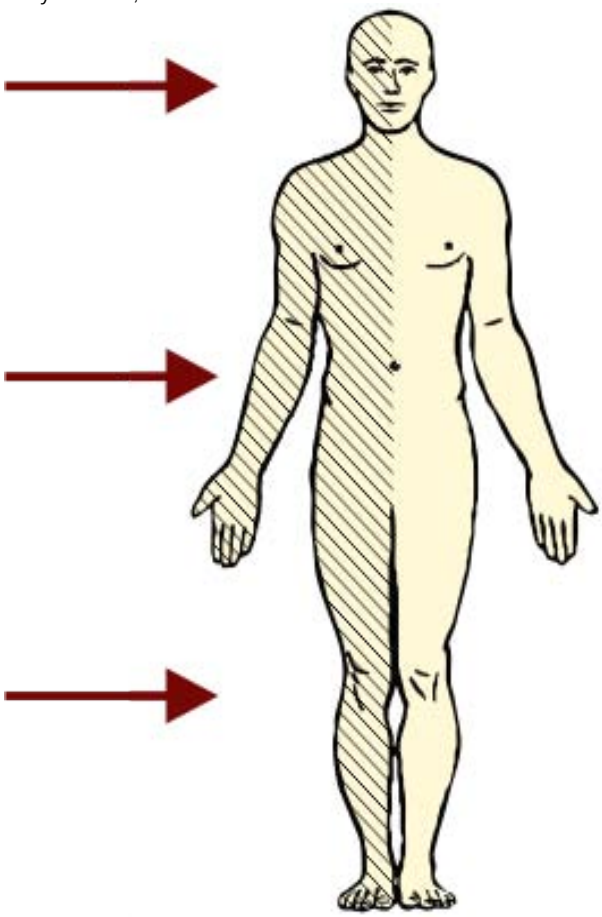

Figure 2: The vector of the blast wave action to the right side of the body

When an individual obtain the TBI from an explosive wave, damage to different parts of the brain depends on the direction of the damaging force vector.

If the direction of the blast force is "in the face", its vector is directed in the sagittal plane, i.e., on the frontal-occipital axis, with brain damage occurring in the frontal (impact) and occipital lobes (contrecoup). Inhibition of motor and cognitive functions, expressed in general weakness, accompanies the damage to these parts of the brain. In the sagittal direction of the action of the force vector, due to the hydrodynamic impact of the liquor in the walls of the III and IV ventricles, there is pressure on the vegetative centers, located at the bottom and walls of these ventricles, as well as pressure on the brain stem structures (I, III, VIII cranial nerves). Also, the nuclei of the lateral corners of the rhomboid fossa, which are part of the vestibular system, are also affected.

An anterior - posterior course of action, in addition to the above, may also be accompanied by hydrodynamic effects on the receptor apparatus of the inner ear, changes and disrupts the reception of sound signals.

A detailed neurological examination of the victims of the blast wave revealed diverse, polymorphic symptomatology of damage to the central and autonomic nervous systems. When inspecting, they focused on the most common symptoms of brain damage: nystagmus, nausea, deviation of the tongue, ataxia, and other violations in neurological status.

We presented the main clinical symptoms of brain damage in this patient group in Table 2.

© 2020 Global Journals

Table 2: The frequency of the objective symptoms in the acute period of mild combat TBI

Patterns	Number of patients	P
nystagmus	65 (67%)	< 0,05
convergence disorder	89 (92%)	< 0,05
Gurevich-Mann symptom	58 (59%)	< 0,05
decrease of corneal reflex	70 (72%)	< 0,05
facial asymmetry	19 (20%)	
deviation of tongue	28 (29%)	
tongue swelling	53 (55%)	< 0,05
tendon anisoreflexia	68 (70%)	< 0,05
disorder of hemitype sensitivity	73 (75%)	< 0,05
pale skin	67 (69%)	< 0,05
tremor of the eyelids, fingers	88 (91%)	< 0,05
ataxia	94 (97%)	< 0,05
pathological symptoms	52 (54%)	< 0,05
vegetative disorders	93 (96%)	< 0,05
dermographism impairment	97 (100%)	< 0,05
hyperhidrosis	81 (84%)	< 0,05

It can be seen from Table 2, that the most frequent objective signs in case of mild combat TBI were symptoms reflecting vegetative and vascular disorders. And the most frequent symptoms of CNS injury were nystagmus (67%), convergence disorder 89 (92%), and decrease of corneal reflex 70 (72%). We found the rest signs of mild combat TBI in more than 29% of injured.

Nystagmus at the initial examination occurred in 65 (67%) patients. It was more often horizontal, small-swinging, and combined with complaints about headaches of different nature (most often patients noted acute pain with photophobia and hyperacusia). We observed the disappearance of nystagmus in most patients on 7-12 days after hospitalization. Normalization of the general condition occurred on 20-27 days of hospitalization in 70% of all hospitalized patients. The rest of the patients needed further rehabilitation.

Symptoms of the vegetative nervous system (VNS) damage were observed in 93 patients. At the time of blast wave injury, there was damage to various parts of the brain that are responsible for vegetative regulation. Our investigations established that an indirect effect on vegetative functions through numerous connections with specific centers of vegetative regulation can be provided by almost all brain structures. Therefore, if any brain structure is damaged, especially if there is diffuse damage to its various segments, the probability of occurrence of dysregulating autonomic disorders is quite high [3].

The symptom of dysfunction of the VNS in prevalence takes the second place in patients of this group. These lesions are most defined in the clinical picture and, in many respects, determine the further course of the mild concussion TBI [2, 3, 5]. These include symptoms such as bradycardia, arterial hypertension/hypotension, acrohyperhidrosis, paleness, or hyperemia of the face, dermographism impairment.

We found the increase in blood pressure upon the admission to the clinic in 14 patients, hypotension – in 49 patients. We detected the dermographism impairment in 97 people. Distal hyperhidrosis occurred in 81 patients.

To evaluate the state of vegetative homeostasis in these patients, we evaluated: the initial vegetative tonus (VT), the vegetative reactivity (VR), the vegetative provisioning (VP) according to the generally known method [1].

The integrative state of the functional activity of VNS, according to the Kerdo index, showed that parasympathicotonia was observed in 79 (82%) patients, sympathicotonia in 14 (14%). The obtained results indicate the predominance of the action of the parasympathetic branch of the VNS in the majority of those, who were examined in the acute period of mild combat TBI.

During the initial examination, autonomic reactivity in 73 (75%) people was insufficient. VP in 79 (82%) patients was insufficient and in 15 (15%) - excessive.

© 2020 Global Journals

Table 3: Vegetative indexes in patients with acute mild closed TBI

Vegetative indexes	Major group (n=97)	p
Kerdo vegetative index		
Normotonia	4 (4 %)	p>0,05
Sympathicotonia	14 (14%)	p>0,05
Parasympathicotonia	79 (82%)	p<0,05
Vegetative reactivity		
Normal	1(1%)	p>0,05
Insufficient	73 (75%)	p<0,05
Excessive	5 (5%)	p>0,05
Distorted	18 (18%)	p>0,05
Vegetative provisioning		
Normal	3 (3%)	p>0,05
Insufficient	79 (82%)	p<0,05
Excessive	15 (15%)	p>0,05

Thus, the obtained results indicate that in the acute period of mild concussion combat TBI there is a pronounced imbalance and desynchronization in the activity of the VNS structures caused by the action of the blast wave on the higher vegetative centers (Table 3).

Currently, there is no doubt that closed TBIs, especially concussion injuries, considerably simulate the neurology of nonspecific brain structures and that many of their clinical and pathophysiological features are determined by the nature and severity of damage to these structures.

One of the major and general features of sensory disturbances in combat concussive traumatic brain injury is, as a rule, that they manifest themselves in the form of unusual, atypical variants that differ from classical sensory syndromes.

Unusual sensitivity disorders discovered by us at the initial stages of the study are total-type sensitivity disorders, peculiar variants of the half-length, longitudinal type.

The syndrome of total anesthesia was characterized by changes in all kinds of sensitivity throughout the body or mainly violations of discriminative types, the accentuation of a sensory defect in the distal extremities and on the scalp; less significant depth of sensitivity disorder in the proximal regions and on the trunk; initial restoration of primitive, and later-complex types of sensitivity. We observed such disorders in patients who got the blast wave directed to the face (Fig. 1).

Also, in the acute period of combat closed TBI, there is a significant number of symptoms in the form of a combined group of axial, wrist, foot pathological reflexes, among which a combination of axial Marinesco-Radovici sign, Bekhterev mandibular reflex with Wartenberg, Babinsky, Chaddock foot reflexes and Wartenberg, Zhukovsky and Rossolimo-Venderovich hand reflexes. This combination of pathological axial, hand, and foot reflexes, as a rule, was symmetrical and was observed by the author in half of the observations [4].

In the presence of this syndrome, it is impossible to determine the localization of the lesion or even several of them within the sensory systems, which would give a picture of the global half-sensory defect, including sensory hypesthesia. A one-sided change in taste, hearing, and smell occurs only when the corresponding receptor apparatuses or the first neurons and brain nuclei in which they end are damaged. It is only based on these facts that when the brain is damaged by the blast wave and have these hemisyndromes, it is said that the extralemniscal formations are involved in the process, which functionally combines various specific systems within one half of the brain - sensory, etc.

It is the so-called non-specific sensorimotor hemisyndrome of the extralemniscal type. There is no doubt that craniocerebral contusion injuries significantly modulate the neuropathology of nonspecific brain structures (nonspecific structures of the limbic system, spinal reticular, reticulospinal tract, spinothalamic tract) and many of their clinical and pathophysiological features are determined by the nature and severity of damage to these structures.

In this regard, we should note the role of non-specific regulatory systems of the brain. The influence of the reticular formation provides particular filtering of impulses that are directed to the cerebral cortex, thus preventing the excessive “bombardment” of the brain by afferent impulses. The downward influence of the reticular formation on the sensory systems is one of the major mechanisms by which the flow of impulses that carry information that is necessary for constant orientation in the environment is controlled, changed, and modulated already at the input.

The influence of the reticular formation on the sensory systems in the ascending direction can be twofold: firstly, speech can affect changes in the general

© 2020 Global Journals

excitability of neurons in the brain with a diffuse ascending activating effect; secondly, under its influence, the excitability of sensory systems at the cortical level can be selectively changed, regardless of the functional state of the cerebral cortex as a whole. The functional state of the reticular formation, which affects the cortical sensory mechanisms, in turn through the cortifugal and corticoreticular systems, is controlled by the cortex itself.

Also, with this pathology, there is a violation of the activity of the vestibular analyzer and receptor apparatus of the inner ear [6]. Our studies confirm that the central departments of the auditory analyzer suffer from explosive injuries. According to the registration of auditory evoked potentials, we detected the violations in the cork section of the auditory analyzer in 100% of the examined military personnel who were in the combat zone. Based on the data obtained, we can state that in combat cerebral trauma, violations are observed not only in the peripheral but also in the central departments of the auditory analyzer. According to evoked auditory potentials, in these patients, there is a violation in the cortical, subcortical, and stem structures of the auditory analyzer expressed to varying degrees. The data obtained by us confirm the significant role of the state of the stem and cortical parts of the auditory analyzer in the development of sensorineural disorders during combat concussion traumatic brain injury.

At the same time we found the cases of asymmetric damage to the auditory system (according to tonal threshold audiometry, acoustic impedance measurement) in most of the examined military personnel, which may be due to the impact of a shock wave to one side of the head [4].

Thus, concussion combat TBI is a polytrauma and, in its characteristics, differs significantly from a peacetime injury. In traumatic brain injury caused by a blast wave, there is a diverse, polymorphic symptomatology of damage to the central and vegetative nervous systems. In the acute period of trauma, the major complaints of patients are complaints of a headache, impairments of the vegetative nervous system, and violation of the “sleep-wake” cycle.

V. Conclusions

The modern combat traumatic brain injury with a concussion and contusion of the brain of a mild severity have more severe course in the acute period compared to a closed peacetime TBI.

The closed TBI due to the blast wave is combined with stress, the influence of this complex is mediated through the functional systems of the brain and leads to the tension of the autonomic mechanisms and is accompanied by autonomic disorders that are permanent. Structural and functional insufficiency of suprasegmental structures, which occurs in the acute period of TBI, can develop in the life of patients when they require the tension of adaptive mechanisms, which, in turn, can lead to disruption.

Cerebral trauma received during the war-time is a complex of structural and functional changes of the nervous system of the adaptive type, which is a dynamic, multilevel process. The severity and dynamics of clinical manifestations of structural and functional disorders of the main pathogenetic processes directly depend on the severity of the injury.

References Références Referencias

1. Vegetative disorders: clinic, treatment, diagnostics (2000). Under edition of A. M. Vein. Moscow. Medical News Agency Publ. 752 p.
2. Kas, Yu. V, Korshniak, V. O., Polishchuk, V. T. (2015). Features of acute closed traumatic brain injury caused by an explosive wave in combatants in the eastern Ukraine. Visnyk naukovih doslidzhen. No.2. pp.41-45.
3. Korshniak, V. O. (2016). Influence of an explosive wave on the formation of neurological symptoms in patients with combat traumatic brain injury. Mizhnarodniy nevrolohychniy zhurnal. No. 5 (83). pp. 83-87.
4. Acute combat contusion traumatic brain injury: pathogenesis, diagnosis, treatment (2018). Under edition of Korshniak V. O. Kharkiv. IE Liburkina L. M. Publ., 156p.
5. Lihterman, L. B., Kravchuk, A. D., Filatova, M. M. (2008). Brain concussion: tactics, treatment and outcomes. Moscow. IP "T.M. Andreeva" Publ. 160 p.
6. Shidlovskaya, T. A., Petruk, L. G., Shidlovskaya, T. V. (2017). Acoustic trauma in the combat zone. Provision of medical aid for sensory-neural hearing impairments: diagnosis, treatment, stages, prevention. Kyiv. 61p.

© 2020 Global Journals