Volume 20 Issue 40
Originally issued as A2



Global Journal of Medical Research: A
Neurology and Nervous System
Volume 20 Issue 2 Version 1.0 Year 2020
Type: Double Blind Peer Reviewed International Research Journal
Publisher: Global Journals
Online ISSN: 2249-4618 & Print ISSN: 0975-5888

Neuro form EZ Stent for Late Thrombosis after Carotid Intracranial Stenosis: A Case Report and Literature Review

By Bin Liao, Huanlun He, Liang Zhang, Kaifeng Li, Xiongjun He & Yajie Liu

Introduction- The patient was a 44-year-old male. He came to Fenggang People's Hospital in Dongguan City, Guangdong Province for left limb weakness in November 2019. His NIHSS score on admission was 1 point. The diagnosis was as follows: 1. acute watershed infarctions in the bilateral cerebral hemispheres; 2. occlusion of the right internal carotid artery (segment C6) and left internal carotid artery; 3. hyperlipidaemia; 4. prior bilateral occipital lobe old cerebral infarction, treated with aspirin 100 mg qd and atorvastatin 40 mg qn. Following the treatment of the previous infarction, the patient's symptoms had improved, and he had been discharged with an NIHSS score of 0 points.

Keywords: stent; thrombosis; intracranial artery stenosis.

GJMR-A Classification: NLMC Code: WL 340



Strictly as per the compliance and regulations of:



© 2020. Bin Liao, Huanlun He, Liang Zhang, Kaifeng Li, Xiongjun He & Yajie Liu. This is a research/review paper, distributed under the terms of the Creative Commons Attribution-Noncommercial 3.0 Unported License http://creativecommons.org/licenses/by-nc/3.0/), permitting all non-commercial use, distribution, and reproduction in any medium, provided the original work is properly cited.

Neuro form EZ Stent for Late Thrombosis after Carotid Intracranial Stenosis: A Case Report and Literature Review

Bin Liao [α], Huanlun He [σ], Liang Zhang [ρ], Kaifeng Li [ω], Xiongjun He [¥] & Yajie Liu [§]

Keywords: *stent; thrombosis; intracranial artery stenosis.*

I. Introduction

The patient was a 44-year-old male. He came to Fenggang People's Hospital in Dongguan City, Guangdong Province for left limb weakness in November 2019. His NIHSS score on admission was 1 point. The diagnosis was as follows: 1. acute watershed infarctions in the bilateral cerebral hemispheres; 2. occlusion of the right internal carotid artery (segment C6) and left internal carotid artery; 3. hyperlipidaemia; 4. prior bilateral occipital lobe old cerebral infarction, treated with aspirin 100 mg qd and atorvastatin 40 mg qn. Following the treatment of the previous infarction, the patient's symptoms had improved, and he had been discharged with an NIHSS score of 0 points. After discharge, he regularly took "aspirin 100 mg qd, atorvastatin calcium tablets 10 mg qn". On December 3, 2019, the left limb was numb and fatigued, and the patient's speech became ambiguous again. Then, he came to the Department of Encephalology, Dongguan Traditional Chinese Medicine Hospital, Guangzhou University of Traditional Chinese Medicine. Head and neck magnetic resonance imaging showed multiple small frontal parietal infarcts (Figure 1); bilateral occipital lobe, left thalamus, and right cerebellar hemisphere softening; left anterior cerebral and middle cerebral arteriosclerosis, mild to moderate stenosis; occlusion throughout the left internal carotid artery and in the bed of the upper right carotid artery; and severe stenosis at the end of the right carotid artery. DSA showed severe stenosis of the upper part of the right carotid artery bed and occlusion at the beginning of the left internal carotid artery (Figures 2a, 2b). After admission, he was treated with aspirin 100 mg qd, clopidogrel sulfate 75 mg qd, atorvastatin 40 mg qn, and butylphthalide capsules 0.2 g tid. After treatment, his limb weakness improved, and he was discharged. His NIHSS score at discharge was 0 points. After discharge, the patient was treated with "aspirin 100 mg qd, clopidogrel sulfate 75 mg qd, and atorvastatin 40 mg qn. On January 13, 2020, became to our hospital again for further endovascular treatment. High-resolution magnetic resonance imaging was performed, revealing that the upper segment of the right carotid artery bed was severely narrowed (ulcerous plaque) (Figure 3) and that the left internal carotid artery was occluded. Genotyping of clopidogrel response genes detected an intermediate metabotype. After communicating with the clinical team, the patient and family members agreed to surgery.

On January 15, the patient underwent balloon dilation and stenting of the right carotid artery under general anaesthesia. After successful puncture of the right femoral artery, systemic heparinization was performed (calculated based on 2/3 of body weight, that is, 0.667 mg per kilogram of body weight plus 1/2 of the previous dose per hour until 10 mg). A 6 F guide catheter was placed in the C1 segment of the right internal carotid artery (Figure 4). Under roadmap guidance, a Tran send micro-guide wire measuring 0.014 * 205 mm (Boston Scientific Corporation, Stryker (Beijing) Medical Devices Co., Ltd.) was carefully transferred through the narrow section to the M1 segment of the right middle cerebral artery. A 3.0 * 15 mm NC TREK RX coronary balloon (Abbott Vascular, USA) was selected and placed in the stenotic section under the guidance of a microwire. After accurate positioning, the stenosis was slowly expanded at 8 standard atmospheres of pressure (Figure 5a). After the stenosis was slowly expanded further at 10 standard atmospheres of pressure, the local dissection and elastic retraction were observed on angiography (Figure 5b). A Neuro form EZ (4.5 * 20 mm, Stryker (Beijing) Medical Devices Co., Ltd., Stryker Neurovascular, USA) stent was passed through the stenosis, and the stent was released after positioning. The angiography showed that the stent was well positioned, the stenosis was improved, and the residual stenosis was approximately 30%. The patient's m TICI classification was Level 3 (Figure 6). The patient's vital signs were stable after the operation, the left limb could be lifted, the NIHSS score was 0, and the postoperative blood pressure was controlled at 100-140/60-90 mmHg; he was prescribed aspirin 100 mg qd, clopidogrel sulfate 75 mg qd, and atorvastatin tablets 40 mg qn. At 21:00 on the night of the operation, the patient's left limb muscle activity was good. At 7:30 the next morning (approximately 15 hours after surgery), the patient was mentally exhausted, his speech was unclear, the muscle strength of the left limb was decreased, the muscle strength of the left upper limb was grade 0, and the muscle strength of the left

Author: *e-mail: 757089780@qq.com*

© 2020 Global Journals

lower limb was grade 4. The patient's NIHSS score was 6 points. A rapid MRI of the head to examine the right frontal and parietal lobes revealed multiple new infarcts in the bilateral frontal and parietal cortex (Figure 7a). Skull MRA showed bilateral internal carotid artery occlusion (Figure 7b), bilateral anterior and middle cerebral arteriosclerosis, and mild to moderate stenosis of the lumen. The patient had multiple recent infarcts in the right frontal parietal cortex and subcortex. Internal carotid artery occlusion caused by an embolization event or stent thrombosis was considered likely. Given the uncertainty of the patient's limb muscle strength, the infarct size was inferred to be large, and he was not eligible for intravenous thrombolysis because his last normal time had been 15 hours prior. The area of the cerebral infarction was large, and the risk of thromboem bolism and bleeding after revascularization was high. The patient's family members did not agree to repeated intravascular treatment, and he continued to receive stroke prevention, dehydration, cranial pressure, collateral circulation, and active acupuncture rehabilitation treatment. A review of head and neck CTA during treatment showed that the bilateral internal carotid artery was occluded, the distal end of the stent was well developed, no blood flow was visible at the proximal end of the stent, and a thrombus had formed at the proximal end of the stent (Figures 8-11). After treatment, the patient's left upper limb muscle strength recovered more than before, reaching grade 3 proximally and grade 1 distally; the left lower limb muscle strength was grade 5 both proximally and distally. The patient's NIHSS score on discharge was 3 points.

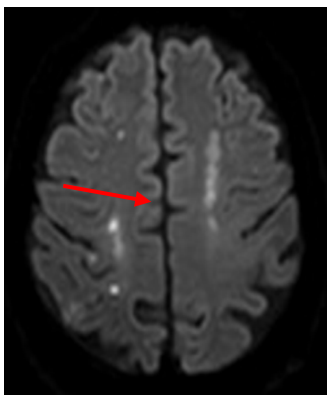

▪ 4

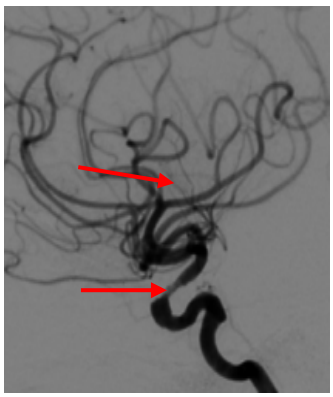

▪ 2a

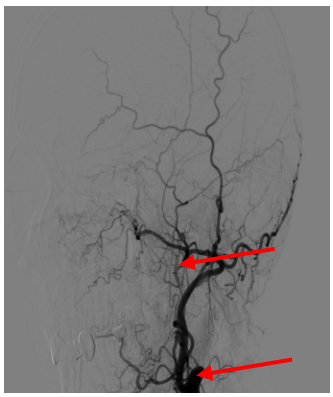

▪ 5a

▪ 2b



▪ 5b

▪ 3



▪ 6

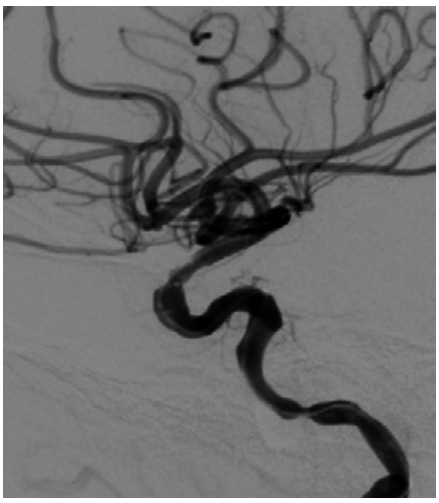

▪ 7a



▪ 7b

© 2020 Global Journals

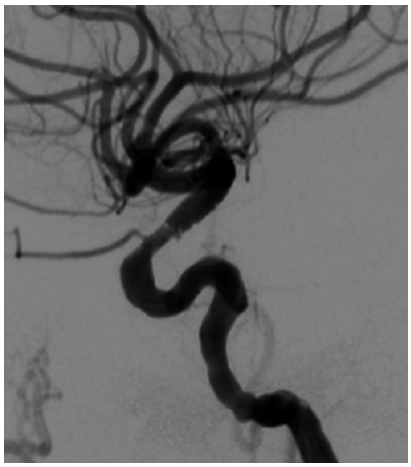

▪ 6

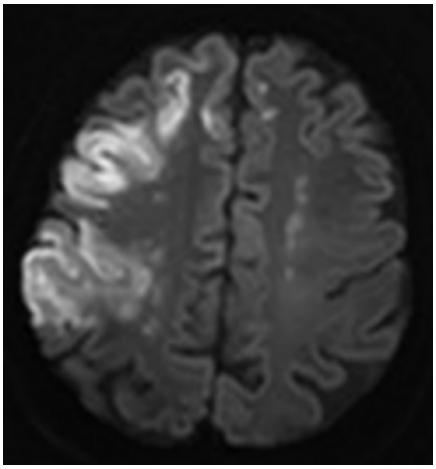

▪ 7a

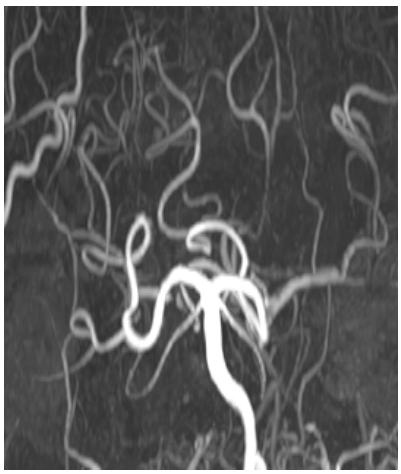

▪ 7a

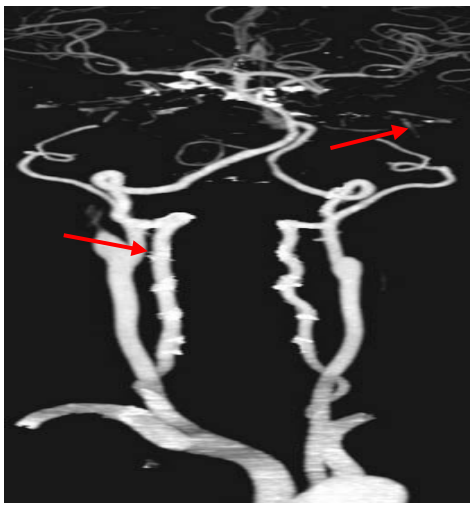

▪ 7b

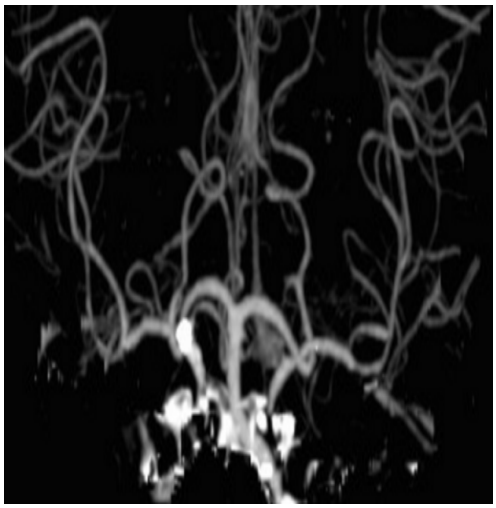

▪ 8

▪ 9

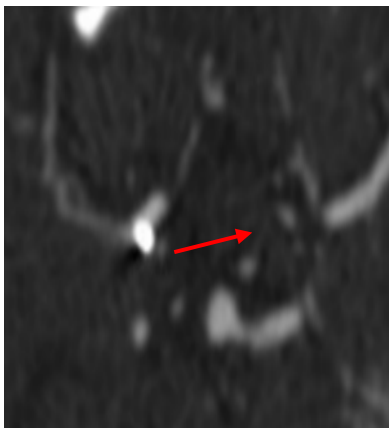

▪ 10

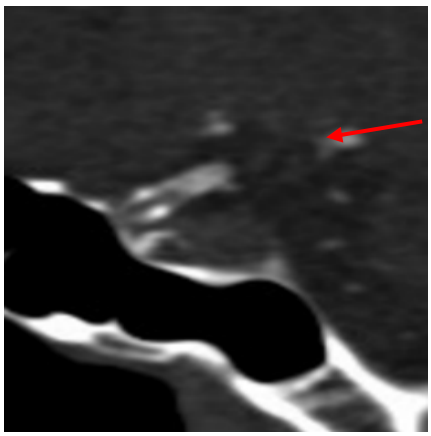

▪ 11

© 2020 Global Journals

Note: figure 1: Multiple small frontal parietal infarcts; Figure 2a: Severe stenosis of the upper part of the right carotid artery bed; Figure 2b: 0cclusion at the beginning of the left internal carotid artery; Figure 3: The upper segment of the right carotid artery bed was severely narrowed (ulcerous plaque) ; figure4-6(surgical procedure):Figure 4: A 6 F guide catheter was placed in the C1 segment of the right internal carotid artery; Figure 5a: The stenosis was slowly expanded at 8 standard atmospheres of pressure; Figure 5b: After the stenosis was slowly expanded further at 10 standard atmospheres of pressure, the local dissection and elastic retraction were observed on angiography; Figure 6: The patient's m TICI classification was Level 3; Figure 7a: 15 hours after operation, a rapid MRI of the head to examine the right frontal and parietal lobes revealed multiple new infarcts in the bilateral frontal and parietal cortex; Figure 7b: Bilateral internal carotid artery occlusion; Figure 8-11: A review of head and neck CTA during treatment showed that the bilateral internal carotid artery was occluded, the distal end of the stent was well developed, no blood flow was visible at the proximal end of the stent, and a thrombus had formed at the proximal end of the stent.

II. Discussion

Ischaemic cerebro vascular disease is a common disease in neurology, and angioplasty has become a treatment option. Endovascular treatment of symptomatic severe intracranial arterial stenosis has been used in clinical practice. Compared with drug treatment alone, interventional therapy can improve and restore the shape and blood flow of intracranial arteries, stabilize plaque, and reduce the long-term incidence of stroke [1]. Acute stent thrombosis is one of the rare serious complications of intracranial arterial stenting. According to the time of occurrence, it can be classified as early, delayed, or very delayed. Early intra-stent thrombosis, defined as occurring within 30 days after PCI, includes acute (24 hours after PCI) and sub acute (24 hours to 30 days after PCI) intra-stent thrombosis. Delayed intra-stent thrombosis is defined as occurring 30 days to 1 year after PCI, and very delayed intra-stent thrombosis is defined as occurring more than 1 year after PCI [2]. By reviewing the relevant literature and combining the clinical data of this patient, we analysed the common factors of stent thrombosis, including plaque rupture, platelet activation, increased release of procoagulant substances in the body, hypercoagulable state, insufficient anti platelet aggregation treatment, clopidogrel or heparin resistance, thinned blood vessels, long lesions, diabetes, chronic renal insufficiency, poor stent and blood vessel fitting, and excessive stent placement.

a) Anatomical characteristics of the siphon of the internal carotid artery

The formation and progression of internal carotid artery stenosis is complicated by the interaction of systemic factors, changes in the biomechanical properties of the vessel wall, and local haemodynamic factors (such as low and oscillating wall shear stress) [3, 4]. Arterial stenosis often occurs in areas related to changes in blood flow, such as bends and bifurcations [5]. The internal carotid artery siphon section is noted for its tortuosity and is among the sites most sensitive to vascular injury [6]. Studies have shown that the geometry of the internal carotid artery plays an important role in the occurrence and development of stenosis. A new classification of "U", "V", "C" and "S" shapes of carotid siphons has been proposed. There is a correlation between stenosis and morphological classification of the siphon. Haemodynamic simulation results for the siphon showed that different haemodynamic factors have different distribution rules among different types of internal carotid arteries, which verified the influence of internal carotid artery geometry on haemodynamics and stenosis. According to clinical reports, stenosis mostly occurs in the second half of the C2 segment and in the full C4 segment [7, 8]. In the siphon, U-shaped morphology is the most common type. In a comparison of the stenotic parts of the siphon section, there was no significant difference in the incidence of C2-segment stenosis among different morphologies, whereas U-shaped siphons were significantly more likely than other morphologies to have C4-segment stenosis. In addition, a U-shaped internal carotid artery may have more stenoses than other morphologies, and there is a higher risk of atherosclerotic stenosis. There may be an increased risk of restenosis after stenting. The patient's siphon was tortuous and "U"-shaped. The proximal end of the stent was at the genu, and the distal end was at MCA M1. The lesion was narrow and severe, and the two ends of the stent were bent. The radial force of the lesion failed to reach the maximum, and the stent adheres poorly, which posed a high risk of intra-stent thrombus formation and a high risk of restenosis after surgery.

b) The characteristics of stenotic lesions

1) The patient's lesion was an unstable plaque, and high-resolution magnetic resonance imaging revealed a thin fibrous cap and many lipid cores. No obvious calcified plaque was seen. After balloon dilatation and stent formation, the plaque was easily ruptured and displaced, the degree of intimal avulsion was intensified, and the thrombus-forming substance was exposed under the in tima. Partially displaced plaques and avulsed endometrium could still penetrate the gap of the stent, increasing the risk of thrombosis and plaque detachment.

© 2020 Global Journals

2) Regarding the geometric and structural features of intracranial blood vessels, Mori et al. [9] defined 3 types (A, B, and C) of stenotic intracranial vessels. The structure of type a vessels is relatively simple, and the incidence of acute thrombosis and restenosis after angioplasty is relatively low. Types B and C vessels are at an angle, and the thrombus is eccentric. After angioplasty, the blood vessels change greatly, and the changes in blood flow are complicated. The rate of acute thrombosis and restenosis after operation is relatively high. In this case, high-resolution magnetic resonance imaging showed severe stenosis caused by a partial plaque. The angiography showed that the length of the stenosis was less than 10 mm, and it was classified as type B. This was one of the factors that caused acute thrombosis and restenosis after surgery.
3) Following angioplasty, the structural characteristics of intracranial blood vessels change in a different manner from those of coronary arteries. The outer wall of intracranial blood vessels is thin, the muscle layer is discontinuous, and cerebral effusion readily infiltrates. The potential damage may cause the destruction of vascular integrity, which, in turn, leads to acute thrombosis after surgery through a series of coagulation mechanisms [10].

c) The details of the operation

1) Local observation of lesions during surgical release of the stent showed that the stent was not smooth and had residual stenosis (30%); the mTICI classification was grade 3. After 20 minutes of observation, the stent, localized in the lesion, was not smooth, and there was a possibility of local thrombosis, which was one of the factors that promoted thrombosis in the stent.
2) After the intraoperative guidance was in place, the diseased blood vessels spasmed, the siphon section became more curved, and the blood flow rate was slowed. This was one of the factors that caused thrombosis. The patient's intraoperative vasospasms were caused by mechanical stimulation from the 6 F guide wire. The blood vessels were still contracted after the stent was released, and the spasm was relieved after the stimulation was reduced and intravenous papaverine was administered.

d) Material selection

1) A balloon measuring approximately 3.0 * 15 mm was used during surgery to cover the lesion. At the first dilation, the pressure was 8 atm. After dilatation, the degree of stenosis was improved (Figure 5a), but the residual stenosis was increased. The second expansion was performed with a pressure of 10 atm. After the expansion, the stenosis showed elastic retraction, and the local dissection appeared (Figure 5b). There may have been insufficient pre-expansion, increasing the residual stenosis rate and poor adherence after stent release. A meta-analysis of the literature shows that the use of intravascular ultrasound during coronary stent implantation can guide the stent to completely adhere to the wall, thereby greatly reducing the incidence of acute stent thrombosis and providing a reference for intracranial stent surgery [11]. A study showed that a stent diameter/vessel diameter ratio (SAR) of 1.2 or less yielded good results. When the SAR is greater than 2, it can cause immediate vasospasm, immediate and delayed thrombosis, and intimal hyperplasia [12]. During surgery, the diameter of the distal end of the blood vessel was 3.8 mm. The diameter of the stent was 4.5 mm, and the length was 20 mm. The lesion was completely covered. The atherosclerotic artery plaque that was cut near the distal and distal edges of the stent was not considered to cause thrombosis. In percutaneous coronary angioplasty (PTCA), when the stent diameter is greater than 3 mm and the SAR is greater than 1, the restenosis rate is significantly reduced after stent placement. Anticoagulation needs to be increased after stent placement in small and low-flow vessels, and platelet aggregation should be inhibited for at least 8 weeks [13].
2) Current stents for intracranial atherosclerosis include the Wingspan and Apollo stents. The Wingspan stent is an open-loop self-expanding stent, which has higher adherence to tortuous blood vessels and a stronger radial support force than the Apollo stent, but the former is more difficult to place, and the operation is more complicated after release. The Apollo is a balloon-expandable stent that can be positioned accurately but is difficult to pass through a tortuous lesion, and it is also prone to displacement. The maximum diameter is 4.0 mm. In cases such as ours, a small stent can cause poor adherence and a high restenosis rate. The Neuro form EZ stent is an open-loop design and has superior adhesion to tortuous vascular segments. The patient had a tortuous "U"-shaped siphon. Nonetheless, the micro catheter release stent easily reached the lesion, and the release was simple. In the current case, we considered the options and chose to implant a Neuro form stent, but in cases where it is difficult for a stent to support the siphon segment, the intervention is difficult, and there are certain risks and challenges in balloon expansion and stent implantation.
3) The Neuro form EZ is an auxiliary intracranial aneurysm stent. Among four available auxiliary aneurysm stents, the radial support force is as follows: the LVIS stent has the highest supporting radial force (37.1 gf), followed by the Leo stent

© 2020 Global Journals

(34.2gf), Enterprise stent (15.2 gf), and Neuroform stent (11.4 gf). Krischek's study [14] and other works compared the radial force of the self-expanding Wingspan stent and the Enterprise, Solitaire, Neuroform, and Leo auxiliary aneurysm stents at 50% compression, and there was a clear ranking of radial strength, which, from lowest to highest, was as follows: Leo, Neuroform3, Enterprise, Solitaire, and Wingspan. The support of the Neuroform stent is weaker than that of the previous three stents. Several stent comparisons showed that the Neuro form had relatively weak radial force. After treatment of severe stenosis in the present case, there was severe residual stenosis, which can easily lead to stent thrombosis. In addition, the siphon lesion was tortuous. The proximal end of the stent was in the genu, and the distal end was in MCA M1. The lesion was narrow and heavy, and the two ends of the stent were curved to the maximal extent.

4) The mesh area of the Neuroform stent is larger. The Leo and LVIS stents (0.979 and 0.782 pores/mm2, respectively) have higher pore density than the Neuroform and Enterprise stents (both 0.276 pores/mm2, respectively). The lesions in patients with stenosis are mainly ulcerated plaques. When the stent mesh is large, the plaques can easily rupture and cause irritation at the site of their adhesion to the stent. This is one of the factors causing intra-stent thrombosis.

e) Postoperative Medication

Strict anti platelet therapy before surgery is an important factor in preventing stent thrombosis. Preoperative regular oral aspirin 100 mg qd and Polivir 75 mg qd were used for 20 days, and this preparatory drug regimen was not considered insufficient. Acute and sub acute thrombosis in the stent is mostly resistant to anticoagulant and anti platelet aggregation drugs [15]. Gene polymorphisms such as CYP2C19, CYP2C9 and CYP2B6 are closely related to clopidogrel resistance. Patients with CYP2C19 allele mutations are prone to clopidogrel resistance, and the incidence of cardiovascular is chaemic events and mortality is increased [16]. Xie et al. [17] showed that weak clopidogrel metabolism is an independent predictor of stent thrombosis within 1 year after PCI. Testing of clopidogrel metabolism genes in the present patient suggested an intermediate metabo type, which may be related to clopidogrel resistance. The doses of drugs such as ticagrelor or cilostazol can be adjusted based on clinical outcomes. Postoperative anticoagulation treatment can reduce or eliminate the risk of stent thrombosis. The absence of anticoagulant therapy after surgery may increase the risk of stent thrombosis.

f) Postoperative observation

At 21:00 the day after surgery, the patient's left limbs were flexible, but his left limb movement was poor after he woke up the next day. His symptoms had worsened in that 10-hour period. Magnetic resonance imaging showed a large area of cerebral infarction, and the right internal carotid artery was occluded. Because of the high risk of recanalization bleeding, interventional recanalization was not performed at that time. By strictly observing patients' neurological symptoms during sleep, it is possible to detect the functional deficits of patients early and make time for recanalization and saving of nerve function. Strict blood pressure management is an important measure during the perioperative period. High blood pressure can lead to hyper perfusion syndrome and even cerebral haemorrhage. Low blood pressure can lead to insufficient cerebral perfusion and cerebral infarction. The postoperative blood pressure of our patient was strictly controlled at 100-140/60-90 mmHg.

III. Conclusion

The efficacy of intracranial angioplasty has been affirmed, but the serious complication of late thrombosis after angioplasty is an important risk that should be given sufficient attention. For internal carotid artery stent implantation, pre-expansion must be sufficient. A stent with good support must be selected. The release of the stent through a micro catheter may increase the risk of thrombosis in the stent and should be performed with caution.

References Références Referencias

1. Wei-Jian Jiang 1, Wengui Yu, Bin Duet al. Outcome of Patients With ≥70% Symptomatic Intracranial Stenosis After Wingspan Stenting. Stroke 2011, Jul; 42(7): 1971-1975.
2. Chaitman BR, Bourassa MG, Davis Ket al. Angiographic Prevalence of High-Risk Coronary Artery Disease in Patient Subsets (CASS). Circulation1981, Aug: 64 (2), 360-367.
3. Malek AM, Apler SL, Izumo S. Hemodynamic shear stress and its role in atherosclerosis. JAMA1999, Dec: 282(21):2035-2042.
4. Van Gijin J, Kerr RS, Rinkel GJ. Subarachnoid haemorrhage. Lancet 2007, Jan; 369 (9558): 306-318.
5. Flaherty JT, Pierce JE, Ferrans VJ et al. Endothelial nuclear patterns in the canine arterial tree with particular reference to hemodynamic events. Circ Res1972, Jan; 30(1): 23–33.
6. Sakata N, Takebayashi S. Localization of atherosclerotic lesions in the curving sites of human internal carotid arteries. Biorheology1988, 25(3): 567–578.

© 2020 Global Journals

7. Meng S, Costa LF, Geyer S Het al. Three-dimensional description and mathematical characterization of the parasellar internal carotid artery in human infants. J Anat 2008, May; 212(5): 636-644.
8. Provenzale JM. Dissection of the internal carotid and vertebral arteries: imaging features. Am J Roentgenol 1995, Nov; 165(5): 1099–1104.
9. Mori T, Kazita K, Seike Met a1.Successful cerebral artery stent placement for total occlusion of the vertebrobasilar artery in a patient suffering from acute stroke: case report. J Neurosurg 1999, May: 90(5): 955-958.
10. Marius H, Olav J. Angioplasty and stenting of intracranial stenosis. Curr Opin Neurol 2005, Feb; 18(1): 39-45.
11. Stehouwer CD, Henry RM,Dekker JMet al. Microalbuminuria Is Associated With Impaired Brachial Artery, Flow-Mediated Vasodilation in Elderly Individuals Without and With Diabetes: Further Evidence for a Link Between Microalbu minuria and Endothelial Dysfunction--The Hoorn Study. Kidney IntSuppl2004,Nov:(92) : 42-44.
12. Duprat Jr G, WrightK C, Charnsangavej Cet al. Self-expanding Metallic Stents for Small Vessels: An Experimental Evaluation. Radiology 1987, Feb: 162(2): 469-472.
13. Roubin G S, Cannon A D, Agrawal S K,et a1. Intracoronary Stenting for Acute and Threatened Closure Complicating Percutaneous Trans luminal Coronary Angioplasty. Circulation 1992 , Mar; 85(3) : 916-927.
14. Krischek O, Miloslavski E, Fischer S, et al. A Comparison of Functional and Physical Properties of Self-Expanding Intracranial Stents [Neuroform3, Wingspan, Solitaire, Leo+, Enterprise. Minim In vas Neurosurg2011, Feb; 54: 21-28.
15. Arkuszewski M, Targosz-Gajniak M, Swiat M, et a1.Acute intracranial in-stent thrombosis after angioplasty of middle cerebralartery symptomatic stenosis: a case report. Neurologist 2012, Sep: 18(5): 290-295.
16. Lev EI, Patel RT, Maresh KJ, et al. Aspirin and clopidogreldrug response in patients undergoing percutaneous coronary intervention: the role of dual drug resistance. J Am CollCardiol2006, Jan; 47(1): 27-33.
17. XIE X, MA YT, YANG YN, et al. CYP2C19 phenotype, stent thrombosis myocardial infarction, and mortality in patients with coronary stent placement in a Chinese population. PLoS One2013, 83 : e59344.

© 2020 Global Journals