Volume 20 Issue 24
Originally issued as J3



Global Journal of Medical Research: J
Dentistry & Otolaryngology
Volume 20 Issue 3 Version 1.0 Year 2020
Type: Double Blind Peer Reviewed International Research Journal
Publisher: Global Journals Inc. (USA)
Online ISSN: 2249-4618 & Print ISSN: 0975-5888

A Descriptive Study of Benign Vocal Cord Lesions with Speech Prameters Operated with Microlaryngoscopy

By Dr. Tushar Govind Borade, Dr. Meena Vishwanath Kale
& Dr. Ninad Subhash Gaikwad

Abstract- *Background:* Humanity has appreciated the importance and power of the human voice. Voice disorders like benign, malignant lesions of vocal cord affect the voice quality and also can have a devastating effect on daily functioning and quality of life. These lesions can be diagnosed and treated with microlaryngoscopy. Micro-laryngoscopy is a procedure for visualization of a magnified view of the voicebox (larynx) with the help of a laryngoscope assisted with an operating microscope for precise laryngeal surgery. Speech parameters helps in voice quality assessment for vocal cord lesions.

Method: We have studied 30 cases of benign vocal cord lesion by simple random sampling for two years which got operated with microlaryngoscopic conventional surgery. Their pre and post-operative assessment is done with respect to speech parameters like Maximum Phonation Time, Voice Handicap Index and GRBAS Score. Clinical history and rigid Hopkins 70^0 also helped in diagnosing of benign vocal cord lesions.

Result: After conventional microlaryngeal surgery helps in improvement in MPT, VHI score, GRBAS Score post-operatively that of 3 months follow up. The effectiveness was seen more along with voice rest, corticosteroids and most important speech therapy.

Keywords: *benign vocal cord lesion, grbas score, maximum phonation time, speech therapy, microlaryngoscopy, voicebox, voice handicap index.*

GJMR-J Classification: *NLMC Code: WU 530*



Strictly as per the compliance and regulations of:



© 2020. Dr. Tushar Govind Borade, Dr. Meena Vishwanath Kale & Dr. Ninad Subhash Gaikwad. This is a research/review paper, distributed under the terms of the Creative Commons Attribution-Noncommercial 3.0 Unported License http://creativecommons.org/licenses/by-nc/ 3.0/), permitting all non-commercial use, distribution, and reproduction in any medium, provided the original work is properly cited.

A Descriptive Study of Benign Vocal Cord Lesions with Speech Prameters Operated with Microlaryngoscopy

Dr. Tushar Govind Borade [α], Dr. Meena Vishwanath Kale [σ] & Dr. Ninad Subhash Gaikwad [ρ]

Abstract- *Background:* Humanity has appreciated the importance and power of the human voice. Voice disorders like benign, malignant lesions of vocal cord affect the voice quality and also can have a devastating effect on daily functioning and quality of life. These lesions can be diagnosed and treated with microlaryngoscopy. Micro-laryngoscopy is a procedure for visualization of a magnified view of the voicebox (larynx) with the help of a laryngoscope assisted with an operating microscope for precise laryngeal surgery. Speech parameters helps in voice quality assessment for vocal cord lesions.

Method: We have studied 30 cases of benign vocal cord lesion by simple random sampling for two years which got operated with microlaryngoscopic conventional surgery. Their pre and post-operative assessment is done with respect to speech parameters like Maximum Phonation Time, Voice Handicap Index and GRBAS Score. Clinical history and rigid Hopkins 70^0 also helped in diagnosing of benign vocal cord lesions.

Result: After conventional microlaryngeal surgery helps in improvement in MPT, VHI score, GRBAS Score post-operatively that of 3 months follow up. The effectiveness was seen more along with voice rest, corticosteroids and most important speech therapy.

Conclusion: Clinical history, speech parameters and rigid Hopkins laryngoscopy helps in the diagnosis of benign vocal cord lesions. All above assess the postoperative effectiveness of microscopic conventional laryngeal surgery.

Keywords: benign vocal cord lesion, grbas score, maximum phonation time, speech therapy, microlaryngoscopy, voicebox, voice handicap index.

Corresponding Author α: Senior Resident, B/12, BMC Colony, Shri Krishna Chowk, New Mill Road, Kurla West, Mumbai, Maharashtra, India. e-mail: tusharborade1985@gmail.com

Author σ: Senior Resident, 11, Vijaya Building, BSDGS CHS, Opp. Vijaya Bank, RC Marg, Chembur, Mumbai 400071. Maharashtra, India. e-mail: meenakale33@gmail.com

Author ρ: Professor And HOU, ENT Department, ENT OPD 8, 2nd floor, OPD building, TNMC & BYL Nair Ch Hospital, Mumbai Central Mumbai, Maharashtra, India. e-mail: ninad_19@yahoo.com

I. Introduction

It is true that if eyes are mirrors of the soul, then surely voice is the loudspeaker. Human voice is extra-ordinary, complex and is integral to our personality. A clear, pleasing confident voice conveys the positive impression of an adequate personality.[1]

In 1854 Manual Garcia a Spanish singing teacher living in London was recognised as "Father of Laryngology" and first to report the visualisation of the larynx with mirrors and reflected sunlight.[2]

Before surgical microscope, the larynx was visualized using the laryngeal mirror which did not allow a complete examination. Hence with the advent of micro-laryngoscopy (ML-Scopy) the larynx is seen with the help of a direct laryngoscope and the view is magnified by using an operating microscope for diagnosis and surgery.

Kleinsasser introduced the use of the new design of laryngoscope in conjunction with the operating microscope in the early 1960s. He was a pioneer in the development of the technique for the treatment and examination of different laryngeal lesions.[3]

The development of micro-laryngoscopy has made precise microlaryngeal surgery possible and it has based on 3 basic principles are as follows[4]

1) Maximal preservation of healthy mucosa particularly on the free edge of the vocal folds
2) Minimal disruption of the superficial lamina propria layer and avoidance of any damage to the underlying vocal ligament
3) Preservation of the mucosal trigone at the anterior laryngeal commissure to avoid the formation of synechiae.

II. Methodology

A retrospective study of 30 patients with benign vocal cord lesions (BVCL) who have attended T.N.M.C. and B. Y. L. Nair Ch. tertiary care hospital from September 2014 to September 2016. Patients were selected by simple random sampling who satisfied the inclusion criteria. Following conventional MLScopy excision, patients were assessed with the speech

© 2020 Global Journals

parameter in the OPD after 7, 30 & 90 days. The data entered with appropriate statistical software. Informed and willing consent taken for ML-Scopy.

Microsoft office 2007 was used to make tables and graphs. Descriptive statistics like mean, percentages were used to interpret the data and conclude the results.

a) Inclusion Criteria

- Patients with age above 18 years with benign vocal cord lesions like polyp, nodule, cyst, vocal cord papilloma, Reinke's oedema not responding to medical and speech therapy for 2 weeks.

b) Exclusion Criteria

- Malignant lesions and patients not fit for general anaesthesia.

III. Aims and Objectives

1. To study the surgical management of benign vocal cord lesion with use of ML-Scopy and its outcome in terms of improvement in voice quality, resolution of lesion on Rigid Hopkins 70 degree scopy.
2. Improvement in voice quality will be assessed by maximum phonation time, improvement in score of GRBAS and voice handicap index.
3. To study and correlate effectiveness of ML-Scopy with respect to Demographic variation, Intra-operative findings & Post- operative follow up.

IV. Speech Assessment Parameters

a) Maximum Phonation Time:[5]

The time an individual can sustain a sung tone, a vowel sound (ah) produced on one deep breath, after having filled the lungs maximally. Selection Rationale: 1) The MPT is the best of 3 attempts at sustaining a vowel ("ah") without straining.
2) Quick and easy to administer
3) In practice since 40 years, non-invasive and requires no special equipment, other than a stopwatch.

Normally, adult males and females can sustain vowel ("ah") sounds for between 25-35 seconds and 15-25 seconds respectively. In general the MPT of less than 10 seconds is abnormal and interferes with daily life significantly. In cases of vocal dysfunction, the MPT is considerably reduced.

b) GRBAS Scale[6,7,8]

Hirano proposed the GRBAS scale a widely used by speech pathologists and laryngologists for the evaluation of voice quality. And also GRBAS for evaluating the hoarse voice: proposed by Japan Society of Logopedics and Phoniatrics

Evaluation: grading is a subjective perceptual evaluation
0: Non hoarse or normal 1: Slight 2: Moderate 3: Extreme

The five elements:

Grade (G): a description of the degree of hoarseness

Roughness (R): the perceptual irregularity of vocal fold vibrations, usually the result of a change in fundamental frequency or amplitude of vibration.

Breathiness (B): the assessment of air leakage through the glottis.

Aesthenic (A): voice denotes weakness and lack of power.

Strain (S): reflects a perception of vocal hyperfunction.

c) Vocal/Voice Handicap Index (VHI) (Developed by Jacobson et al 1997)[9,10]

Handicap is defined as, "a social, economic, or environmental disadvantage resulting from an impairment or disability." The VHI is a quality-of-life subjective questionnaire for self-evaluating voice disorders, which has excellent reliability and reproducibility. The VHI can also be useful as a component of measuring functional outcomes in behavioural, medical, and surgical treatments of voice disorder. The VHI is a 30 questionnaire (120-points total) to quantify the 10-item of each subscale of functional, emotional and physical impacts of a voice disorder problem.

Vocal pathologies can have different levels of handicap. Subjects were asked to read each item and circle one of five responses comprising an equal-appearing 5-point scale. The scale had the words anchoring 0: never, 1: almost never, 2: sometimes, 3: almost always, 4: always.

VHI is classified as

Mild: values of 0-30: mildly impaired voice

Moderate: values of 31-60: moderately impaired voice

Severe: values of 61-120: self-perception of voice as severe

d) Operative procedure

The Kleinsasser laryngoscope along with microscope of 400mm focal length was fixed with the help of Levy type of suspension apparatus on the chest. During this, pulse and ECG of the patient carefully recorded.

We have studied various cases of benign vocal cord lesions with ML-Scopy surgery without much damage to normal mucosa.

Preoperative speech therapy is advised to all patients to prepare for post-operative rehabilitation programme.[11]

Post operatively mainly treated with:

- Strict voice rest
- corticosteroids (Oral, nebulisation)
- antihistaminics
- steam inhalation
- post-op 1 week later: speech therapy.
- ceasation of addiction.

© 2020 Global Journals

After surgery follow up on 7 days, 1 month and 3 months in outpatient department and clinically assessed by

1) Hopkins rigid 70 degree scope
2) Speech parameter by MPT, GRBAS, VHI Scale.

V. Benign Vocal Cord Lesions (BVCL)

1) Vocal cord nodules: result from the voice misuse or abuse and in non-professional singers with poor singing technique.[12] It is chronic, commonly present as a pinkish, fusiform usually bilateral mucosal swelling of the membranous portion of the vocal folds.[13] These nodules are typically located slightly below the vocal fold free edge of the junction of the anterior and middle third of the glottis. Pathophysiologically a forceful vibration of the membranous vocal folds that translates into maximal shearing forces at the midpoint of the vocal ligament. Nodules are much less frequently seen in prepubertal males than in females.[14]

Delicate surgical intervention with resection of the nodule with utmost care of normal mucosa and superficial lamina propria layer of the vocal fold is done.[15] Bilateral nodules can be removed during the same session, but a trigone of healthy mucosa must be preserved to avoid vocal fold web formation.

2) Vocal cord Polyps: [12,14,15,16]

A vocal polyp is an inflammatory benign swelling of greater than 3 mm that arises from the free edge of the vocal fold.

Polyps are the most common cause of hoarseness, frequently seen in middle aged (25-45 years) smokers, males. Phonotrauma is an important while yelling or shouting at times of infective laryngitis or oesophageal reflux are aetiological factor. May be due to disruption to the vascular basement membrane, capillary proliferation, minute haemorrhage and fibrin exudation. Usually solitary, but can be bilateral.

Polyps are either sessile or pedunculated (Fig: 1A) and are treated by microsurgical excision (Fig: 1B) followed by intrachordal corticosteroids injection to avoid recurrance with post-operative medical management.

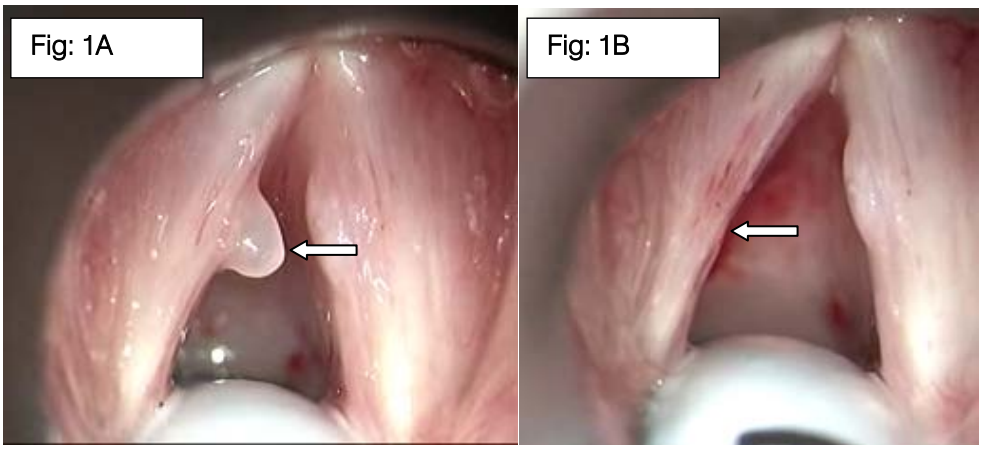

Fig. 1: ⇦ Microlaryngoscopy of left vocal cord sessile polyp
Fig. 1A: Preoperative
Fig. 1B: Postoperative

3) Reinke's Edema: [17,18,19,20,21]

Reinke's Oedema of vocal fold is essentially seen in smokers with voice abuse, leads to typical inflammatory and oedematous lesion.

It can be bilateral, asymmetrical change and more prominent on the superior and free edge of the vocal folds.

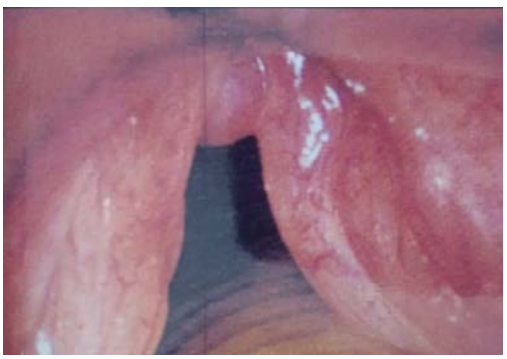

Fig. 2: Reinke's oedema of bilateral vocal cord

© 2020 Global Journals

In this surgery, the mucosa is dissected from the myxoid components of Reinke's oedema on top and from the vocal ligament underneath. Once the pseudomyxoma is fully resected, the mucosa of free edge is folded back onto the vocal ligament and fixed in position with fibrin glue for optimal return of voice.

4) Vocal cord cyst [15,16,22]

The cyst is usually unilateral and typically mucoid, fusiform lesion situated in the superficial lamina propria layer in free edge of vocal cord. Cyst results from cicatrical occlusion of a mucus gland duct.



Fig. 3: Left vocal cord cyst

A cyst can be approached via a lateral microflap incision made on the superior surface of the vocal fold away from its medial edge. The flap is then elevated from lateral to medial, the lesion excised and the flap replaced.

5) Vocal cord papilloma[23,24]

Frequently recurring and are due to the human papilloma virus (subtypes 6 and 11). They are single or multiple, friable and often found at areas of constriction in larynx. Where there is increased air turbulence, drying of mucosa can lead to change of ciliary to squamous epithelium.



Fig.4: Bilateral vocal cord papilloma

Surgical techniques for multiple papilloma include using injection of saline submucosally (hydrodissection) and excising the mucosa en-bloc with cold steel. This gives a lower recurrence rate than surface ablation.

6) Vocal cord haemangioma[25,26]

The incidence of laryngeal hemangioma in infants is 4-5% but rare in adults and when it is present in adults it is more prevalent in the male population. Mostly midportion vibratory edge of vocal folds are subjected to trauma from chronic over-talking, high volume talk, screaming or aggressive singing i.e. vocal abuse, cigarette smoking and laryngeal trauma such as in case of intubation blood vessels may tear with blood seeping into the vocal fold. Once the blood vessels heal due to thinner vessel walls, they tend to be more dilated and assume a tortuous form. If dilated vessels may become engorged during phonation with the risk of subsequent rupture leading to subepithelial hemorrhage.

Initially, conservative management with voice rest and steroids is recommended. Episodes of frequent development then need for surgical excision.

© 2020 Global Journals

VI. Results

- In our study, the maximum benign lesions were seen in age groups of 31 to 50 years (Table:1) i.e. 20(66.6%) cases with mean age of patients as per our study is 40.5 years. Where there is equal distribution among male and female for benign vocal cord lesion.

Table 1: Age and Sex distribution

Sr.No.	Age in years	No. of males	No of females	Total
1	21-30	1	2	3
2	31-40	5	7	12
3	41-50	4	4	8
4	51-60	4	1	5
5	>60	1	1	2
	TOTAL	15	15	30

- Even though equality seen among both sexes for BVCL but variability existed in each special lesion which explained as in Table: 2

Table 2: Sex distribution of BVCL

Sr.No.	Vocal cord lesions	Males	Females	Total No. of cases	Percentage
1	Nodules	6	8	14	46.66
2	Polyps	2	4	6	20
3	Haemangioma	1	1	2	6.66
4	Cyst	1	1	2	6.66
5	Papilloma	1	-	1	3.33
6	Chronic laryngitis with Reinke's oedema	4	1	5	16.66
	TOTAL	15	15	30	100

Majority of cases were found to have vocal cord nodules i.e. 14 cases (46.66%) and most commonly found in 8(26.6%) females, while incidence of Reinke's oedema was more in males (13.3%).

- Our study says; each patient of BVCL was suffered whether it was a small or large lesion. Most of the complaints were as follows (Table: 3)

Table 3: Distribution of Symptoms

Sr. no.	Symptoms	No of cases	Percentage
1	Change in voice/Hoarseness	26	86.66
2	Foreign body sensation in throat	22	73.33
3	Discomfort in throat	20	66.66
4	Inability to raise the voice	9	30
5	Fatigue of Voice	2	6.66

Change in the voice/Hoarseness of voice (86.66%) and foreign body sensation (73.33%) were the most common complaints given by patients of benign vocal cord lesion.

© 2020 Global Journals

❖ Most of the voice related occupations and person's habits (Table 4 and 5) can be responsible for change in sensitive vocal cord mucosa into benign lesions.

Table 4: Distribution according to occupation

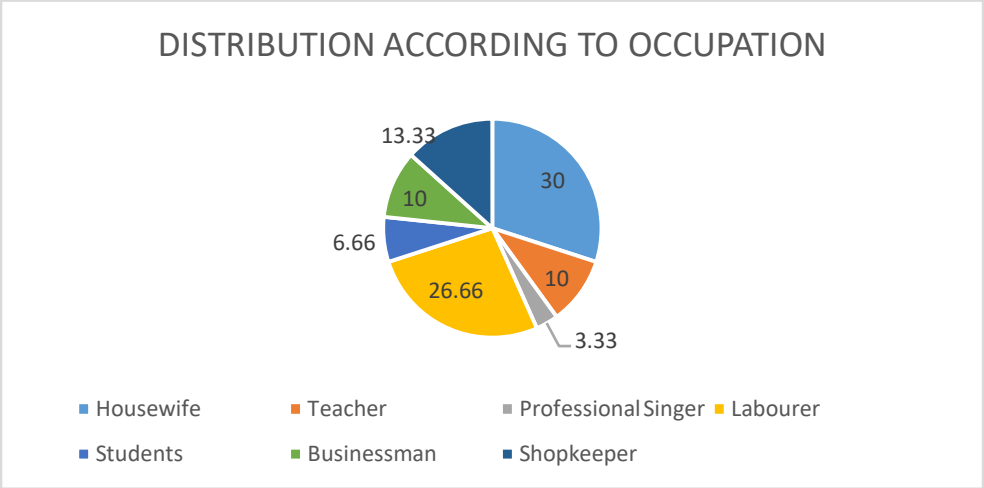

Table 5: Distribution of cases according to habits

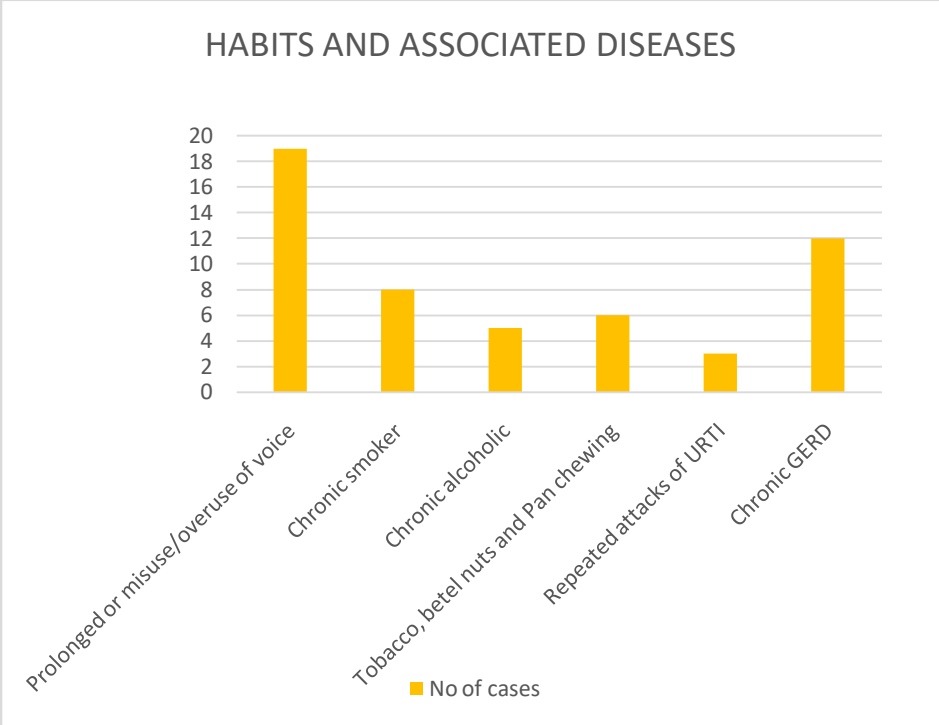

Table 4 and 5 shows vocal cord lesions occurs to people with prolonged voice abusers like teachers, housewife (30%) because of their screaming and shouting and a bad singer can lead to vocal lesions. Cessation of addiction can minimise the appearance of vocal cord lesion. Our study shows 26.6% and 20% patients were affected with benign vocal cord lesion were addicted smoking and tobacco chewing habits respectively.

❖ After diagnosis of BVCL and its surgical treatment with conventional MLScopy; patients were assessed with voice changes in the form of its speech parameters such as MPT, VHI and GRBAS Score in preoperatively and post-operatively every 7, 30 and 90 days duration shown in Tables 6, 7, 8.

© 2020 Global Journals

A. MPT assessment

Table 6: Pre & Post Operative MPT of BVCL after 1 week

MPT In Sec	No. Of Cases in Pre & Post Operative													
	Nodules		Polyps		Haemangioma		Cyst		Papilloma		Reinke's oedema		Total	
	Pre	*Post*	*Pre*	*Post*	*Pre*	*Post*	*Pre*	*Post*	*Pre*	*Post*	*Pre*	*Post*	*Pre*	*Post*
0-5	0	0	0	0	0	0	0	0	1	0	0	0	1	0
6-10	3	0	3	0	0	0	0	0	0	1	1	0	7	1
11-15	8	1	3	1	1	0	1	0	0	0	2	0	15	2
16-20	2	6	0	1	1	0	1	1	0	0	2	1	6	9
21-25	1	3	0	3	0	1	0	0	0	0	0	1	1	8
More than 25	0	4	0	1	0	1	0	1	0	0	0	3	0	10
Total	14		6		2		2		1		5		30	

There is good improvement seen in mean MPT i.e. from preoperative 10.5 sec to 20.5 sec postoperatively after 1 week of conventional microscopic laryngeal surgery. With corticosteroids and voice rest; marked improvement seen after 3 months along with speech therapy. 10 out of 30 patients (33.33%) shows MPT more than 25sec in 1 week postoperative.

B. VHI Score assessment

Table 7: Pre and Post-Operative VHI Scores after 4 week

VHI Score with severity	No. Of Cases of Benign Vocal Cord lesion Pre and post operative												Total	
	Nodules		Polyp		Haemangioma		Cyst		Papilloma		Reinke's oedema			
	Pre	*Post*	*Pre*	*Post*	*Pre*	*Post*	*Pre*	*Post*	*Pre*	*Post*	*Pre*	*Post*	Pre	Post
0 –30 (mild)	8	11	1	5	1	2	1	2	0	0	0	4	11	23
31-60 (moderate)	6	3	5	1	1	0	1	0	0	1	5	1	18	6
61-120 (severe)	0	0	0	0	0	0	0	0	1	0	0	0	1	1
TOTAL	14		6		2		2		1		5		30	

After 4 weeks of surgical and medical management VHI score in preoperative 18cases (60%) were between 31-60score which has improved postoperatively from moderate to mild i.e. upto 0-30 score seen in 23 (76.6%) cases and ultimately voice has improved.

C. GRBAS Score assessment

Table 8: GRBAS Score pre and post-operative after 3 months follow up

Sr. No.	GRBAS Score / No. of cases	Pre-operative	Post-operative
1	10	G3R2B0A1S2	G1R1B0A1S0
2	14	G2R2B0A3S2	G0R1B0A0S0
3	6	G1R1B0A0S2	G1R0B0A0S1

© 2020 Global Journals

GRBAS score has improved in most of the cases from grade-3 to grade-1 or grade-0 as seen above in table 8.

- After 3 months follow up, on clinical history and rigid Hopkin's endoscopy shows, only 1(3.33 %) case of recurrence of vocal cord polyp due to poor compliance to speech therapy and had not quit smoking who needed revision procedure.

A case of bilateral vocal cord papilloma required two stage surgery after at 4 weeks of medical management and1st surgery due to incomplete excision of lesion so as to avoid development of laryngeal web.

VII. Discussions

We have studied 30 patients with various benign vocal cord lesions operated with conventional ML-Scopy. Our analysis was as follows:

BVCL in our study, the commonest pathology was vocal cord nodules 14 (46.66%) cases were noted. Similarly noted in study of Brodnitz who reported 45% of vocal nodules.[27] (20%) 6 cases of vocal cord polyp similar with incidence of study of Mahesh Chandra et al and Kotby et al i.e. 24%.[28,29]

Most of our cases were in the 31-50 years of age, which included total 20 cases i.e. almost more than 50% also seen in Siddapur GK et al[30] and Guha et al[31] of benign vocal fold lesion. In our study female preponderance was seen in cases of vocal cord nodules where 53.3: 40% of female: male seen as inverse findings in the study by Chopra et al.[32] As per occupation, 9 (30%) cases were housewives, 8 (26.66%) were labourer, 3(10%) cases of each were teachers and businessmen. Even our study matches with Ruma Guha et al which showed most of the lesions are common in middle age house wife (28%) followed by office workers (26%) and Labourer (22%).[31]

All of our patients had change of voice/hoarseness as their major presenting complaint. Siddapur GK et al study shows hoarseness of voice, vocal fatigue and foreign body sensation as the commonest presenting symptoms.[30] It is often seen in patients who are chronically exposed to irritants such as tobacco smoke.[30]

The mean MPT preoperatively was 10.5seconds and after 1 week post-operatively was 20.5seconds. In 1week post-operative, 33.33% cases had their mean MPT more than 25seconds; which significantly improved to 50% after 3months with voice rest and speech therapy, study by Emilie Bequignon et al in 2013 had similar results.[33]

In a study by Kiagiadaki D et al the maximum phonation time significantly improved post microlaryngoscopy with voice rest. Also noticable improvement was seen in overall GRBAS score. And mean VHI score after 4 weeks shows 76.6% cases improvement into 0-30 VHI Score. While after 3 months post-operative correlated with study by Emilie Bequignon et al and Devora Kiagiadaki et al study [33,34]

Surgical approach through conventional ML-Scopy with post-operative speech therapy was the mainstay of our treatment.[35] Excision of vocal cord lesion with maximum preservation of normal mucosa is supported by Singhal et al (94%) and Hegde et al (83.29%)[36,32]

Outcome was assessed by various speech indices, symptomatology and Hopkins rigid 70^0 scopy. The patients were assessed at 7th day post-operative period and then at 1 and 3months post-operatively.

Nowadays with advent technology; laser assisted, powered instrument assisted like laryngeal microdebrider microscopic laryngeal surgery has become more precise than conventional surgery. Cons of these new technology are that they are costly and require good surgical skill.

Acknowledgements: We are grateful to the Dean Sir, Dr. R. N. Bharmal, TN Medical College & BYL Nair Charitable Hospital, Mumbai Central, Mumbai-400008 for allowing us to publish this article.

Declarations:

Funding: No funding sources

Conflict of interest: None declared

Ethical approval: Not required

VIII. Conclusions

In our study of 30 Cases of benign vocal cord lesions the following conclusions were made.

1. Common cases of benign vocal cord lesions presenting to us were of Vocal cord nodules (46.66%), Vocal cord polyps (20 %) and Reinke's edema (16.66 %).
2. The mean age of presentation of cases of benign vocal cord lesions was 40.5 years with female preponderance in our study especially in cases of vocal cord nodules. Overall most of the cases of benign vocal cord lesions were in the age group of 31 to 50 years.
3. Commonest cause of benign vocal cord lesions was phonotrauma most commonly due occupational demand, habits and reflux.
4. Satisfactory improvement were obtained post-operatively with respect to the symptoms, speech parameters (the mean MPT, mean VHI score, GRBAS Score) and rigid Hopkins 70^0 scopy examination.
5. Conventional microlaryngoscopic surgery are cheap, effective than advent technology where skillful hands required.

References Références Referencias

1. Michael M. et al Update on the etiology, diagnosis, and treatment of vocal fold nodules, polyps, and

© 2020 Global Journals

cysts. Current Opinion in Otolaryngology & Head & Neck Surgery: December 2003 - Volume 11 - Issue 6 - pp 456-461
2. Michael LA. Otolaryngology at Baylor University Medical Center. Proc (Bayl Univ Med Cent). 2001;14(2):164–171.
3. Jako GJ. Laryngoscope for microscopic observation, surgery and photography. The development of an instrument. Arch Otolaryngol. 1970; 91(2):196–199.
4. Sultan Pradhan: surgery of larynx and hypopharynx: phonomicrosurgical technique, chapter 1,4.2:11.
5. Maslan J, Leng X, Rees C, Blalock D, Butler SG. Maximum phonation time in healthy older adults. J Voice. 2011; 25(6):709–713.
6. Hirano, M. "Psycho acoustic evaluation of voice, Clinical Examination of Voice." Disorders of Human Communication (1981): 81-84.
7. Omori, Koichi. "Diagnosis of Voice Disorders." July/August (2011). JMAJ 54(4): 248–253.
8. Nemr, Katia et al. "GRBAS and Cape-V scales: high reliability and consensus when applied at different times." Journal of voice: official journal of the Voice Foundation vol. 26,6 (2012): 812.e17-22.
9. Jacobson GH, Johnson A, Grywalski C et al (1997) The Voice handicap index (VHI): development and validation. Am J Speech Lang Pathol 6:66–70
10. A. Rosen, A. S. Lee, J. Osborne, T. Zullo, and T. Murry, "Development and validation of the voice handicap index-10," The Laryngoscope, vol. 114, no. 9, pp. 1549–1556, 2004.
11. Cohen SM, Garrett CG Utility of voice therapy in the management of vocal fold polyp and cysts. Otolaryngology—head and neck surgery; official journal of American academy of otolaryngology-head and neck surgery (2007) 136; 742-746.
12. Wallis L, Jackson-Menaldi C, Holland W, Giraldo A. Vocal fold nodule vs. vocal fold polyp: Answer from surgical pathologist and voice pathologist point of view. Journal of Voice. 2004; 18: 125–9.
13. Martins RH, Defaveri J, Custodio Domingues MA et al Vocal cord nodules: Morphological and immunohistochemical investigations. Journal of voice: official journal of the voice foundation (2010)24:531-539.
14. Nagata K, Kurita S, Yasumoto S, Maeda T, Kawasaki H, Hirano M. Vocal fold polyps and nodules. A 10-year review of 1,156 patients. Auris Nasus Larynx. 1983; 10:27–35.
15. Kleinsasser O. Restoration of the voice in benign lesions of the vocal folds by endolaryngeal microsurgery. Journal of Voice. 1991; 5: 257–63.
16. Johns MM. Update on the etiology, diagnosis, and treatment of vocal fold nodules, polyps and cysts. Current Opinion in Otolaryngology –Head and Neck Surgery. 2003; 11: 456–61.
17. Raabe J, Pascher W. Das Reinke's edema: An investigation on the aetiology, prognosis and effectiveness of therapeutic interventions. Laryngo rhino otology. 1999 Feb; 78 (02): 97-102.
18. Bransky RC, Saltman V Sulica L et al cigarette smoking and reactive oxygen species metabolism- : implications for pathophysiology of Reinke's oedema. The Laryngoscope (2009)119:2014-2018.
19. Jovanovic MB, Mulutinovic Z, Perovic J, Grubor A, Milenkovic S, Malobabic S. Contact telescopy reveals blood vessel alterations of vocal fold mucosa in Reinke's edema. J Voice. 2007; 21(3):355–360.
20. Marcotullio D, Magliulo G, Pezone T. Reinke's edema and risk factors: clinical and histopathologic aspects. Am J Otolaryngol. 2002; 23(2):81–84.
21. Tillmann B.,Rudert H, Schunkes M et al Morphological studies on the pathogenesis of Reinke's edema. European archives of oto-rhino-laryngology: official journal of the European federation of Oto-Rhino-Laryngological Societies (1995) 252(8):469-474.
22. Bouchayer M, Cornut G, Loire R, Roch JB, Witzig E, Bastian RW. Epidermoid cysts, sulci and mucosal bridges of the true vocal cord: a report of 157 cases. Laryngoscope. 1985; 95: 1087–94.
23. M. Carifi, D. Napolitano, M. Morandi, and D. Dall'Olio, "Recurrent respiratory papillomatosis: current and future perspectives," Therapeutics and Clinical Risk Management, vol. 11, pp. 731–738, 2015.
24. R. Ivancic, H. Iqbal, B. deSilva, Q. Pan, and L. Matrka, "Current and future management of recurrent respiratory papillomatosis," Laryngoscope Investigative Otolaryngology, vol. 3, no. 1, pp. 22–34, 2018.
25. Prasad SC, Prasad KC, Bhat J. Vocal cord hemangioma. Med J Malaysia. 2008;63(5):419–420.
26. Wang T, Wu C. Vocal cord cavernous hemangioma: case report. Lung Breath Journal. 2017; 1(3):1-2.
27. Brodnitz FS. Goals, results and limitations of vocal rehabilitation. Arch Otolaryngol. 1963;77:148-56
28. Mahesh C, Panduranga KM, Kiran B, Ranjith P, Ravi BP. Benign lesions of larynx-a clinical study. Indian J Otolaryngol Head Neck Surg. 2012; 57(1):35- 8.
29. Kotby MN, Nassar AM, Seif EI, Helal EH, Saleh MM. Ultrastructural features of vocal fold nodules and polyps. Acta Otolaryngol. 1988;105:477-82
30. Siddapur GK, Siddapur KR. Comparative study of benign vocal fold lesions in a tertiary health centre. Int J Otorhinolaryngol Head Neck Surg 2015;1:65-8.
31. Guha, Ruma & Mondal, Tanushree & Dutta, Mainak & Hansda, Rajesh. (2015). Clinico-demographic trend of Benign Vocal Cord Lesions among Urban Population attending a Tertiary Medical Institution of Kolkata. IOSR Journal of Dental and Medical Sciences. 14. 64-6.

© 2020 Global Journals

32. Chopra, H., Kapoor, M. Study of benign glottic lesions undergoing microlaryngeal surgery. IJO & HNS 49, 276–279 (1997).
33. Béquignon, Emilie et al. "Long-term results of surgical treatment of vocal fold nodules." The Laryngoscope vol. 123,8 (2013): 1926-30.
34. Kiagiadaki D, Remacle M, Lawson G, Bachy V, Van der Vorst S. The effect of voice rest on the outcome of phonosurgery for benign laryngeal lesions: preliminary results of a prospective randomized study. Ann Otol Rhinol Laryngol. 2015; 124(5):407–412.
35. Hochman II, Zeitels SM. Phonomicrosurgical management of vocal fold polyps: The subepithelial microflap resection technique. Journal of Voice. 2000; 14: 112–8.
36. Singhal, P., Bhandari, A., Chouhan, M., Sharma, M. P., & Sharma, S. Benign tumors of the larynx: a clinical study of 50 cases. Indian Journal of Otolaryngology and Head & Neck Surgery, 2009; 61(1), 26-30.

© 2020 Global Journals