Volume 20 Issue 56
Originally issued as C4



Global Journal of Medical Research: C
Microbiology and Pathology
Volume 20 Issue 4 Version 1.0 Year 2020
Type: Double Blind Peer Reviewed International Research Journal
Publisher: Global Journals
Online ISSN: 2249-4618 & Print ISSN: 0975-5888

Gastric Lavage-An Alternate Approach in the Diagnosis of Idiopathic Pulmonary Hemosiderosis: A Case Report

By Ayesha Afreen Islam

Abstract- Idiopathic pulmonary Hemosiderosis (IPH) is a rare and life threatening condition, found primarily in children, that causes recurrent episodes of diffuse alveolar hemorrhage. It is characterized by hemoptysis, alveolar infiltrates on chest radiograph and various degrees of anemia. It affects pediatric patients in approximately 80% of cases with equal gender incidence. When no underlying cause for repeated episodes of diffuse alveolar hemorrhage is apparent, the entity is referred to as idiopathic pulmonary Hemosiderosis. Studies have shown that the detection of hemosiderin-laden macrophages in broncho alveolar lavage fluid and gastric aspirate is crucial for the confirmation of diagnosis. We present a case of 10 months old baby boy where cytological findings in the gastric lavage proved highly beneficial in the diagnosis of IPH.

GJMR-C Classification: *NLMC Code: WG 142*



Strictly as per the compliance and regulations of:



© 2020. Ayesha Afreen Islam. This is a research/review paper, distributed under the terms of the Creative Commons Attribution-Noncommercial 3.0 Unported License http://creativecommons.org/licenses/by-nc/3.0/), permitting all non-commercial use, distribution, and reproduction in any medium, provided the original work is properly cited.

Gastric Lavage-An Alternate Approach in the Diagnosis of Idiopathic Pulmonary Hemosiderosis: A Case Report

Ayesha Afreen Islam

Abstract- Idiopathic pulmonary Hemosiderosis (IPH) is a rare and life threatening condition, found primarily in children, that causes recurrent episodes of diffuse alveolar hemorrhage. It is characterized by hemoptysis, alveolar infiltrates on chest radiograph and various degrees of anemia. It affects pediatric patients in approximately 80% of cases with equal gender incidence. When no underlying cause for repeated episodes of diffuse alveolar hemorrhage is apparent, the entity is referred to as idiopathic pulmonary Hemosiderosis. Studies have shown that the detection of hemosiderin-laden macrophages in broncho alveolar lavage fluid and gastric aspirate is crucial for the confirmation of diagnosis. We present a case of 10 months old baby boy where cytological findings in the gastric lavage proved highly beneficial in the diagnosis of IPH.

I. Introduction

The estimated incidence of IPH in children is 0.24–1.23 cases per million, with a mortality rate as high as 50%. Only 500 cases have been described in medical literature. [1] It is characterized by the triad of iron deficiency anemia, hemoptysis, and multiple alveolar infiltrates on chest radiograph.[2,3] It may occur as a primary phenomenon, most commonly seen in children or secondary to cardiac, systemic vascular or hemorrhagic diseases, which is more common in adults.[3] IPH is a diagnosis of exclusion and there should be a high degree of suspicion if patients with iron deficiency anemia don't respond to iron therapy, they should be examined for IPH.[4] Laboratory and radiological findings that have been found helpful in diagnosing the disease are anemia(the value of RBC indices , and serum iron were very low, peripheral smear examination shows microcytic hypo chromic anemia, bone marrow biopsy show hyper plastic erythropoiesis), chest X-ray showing diffuse parenchymal infiltrates, pulmonary function tests showing interstitial lung disease, and increase in single breath carbon monoxide (CO) uptake.[5] A diagnosis by lung biopsy is considered gold standard but many have accepted the presence of hemosiderin laden macrophages in gastric or broncho alveolar lavage fluid as diagnostic if other diagnostic criteria are met.[1] The definitive diagnosis of IPH is made based upon the typical clinical and radiological profile, accompanied by the identification of hemosiderin-laden macrophages in sputum or in gastric lavage.[1,4]

II. Case Report

A 10 month old baby boy presented to the pediatric OPD with complains of failure to thrive, blood stained sputum and recurrent episodes of hemoptysis and severe pallor which was refractory to extensive iron therapy he received in the past. On clinical examination the patient was afebrile, no organomegaly and patients' hemogram showed severe microcytic hypo chromic anemia. On admission patient had pallor +++, bilateral crepitations on chest examination, other systems were unremarkable. Chest X-ray showed bilateral infiltrates (Fig 1). Anti GBM antibody was negative. A spectrum of other antibodies like ANCA, ANA, APLA, MPO and PR-3 all proved to be negative in this case. C-reactive protein, rheumatoid factor, antinuclear antibody (ELISA), anti phospholipid antibody were all negative. AFB and CBNAAT study in the sputum and gastric lavage were also negative. A diagnosis of Idiopathic pulmonary hemosiderosis was made based on the clinical triad (iron deficiency anemia, hemoptysis, bilateral chest infiltrates) and after ruling out other causes of alveolar hemorrhage by relevant investigations. A Cytological study of the gastric lavage revealed numerous hemosiderin-laden macrophages (HLM) confirmed by Perl's Prussian blue stain for hemosiderin (Fig 2A, 2B). Broncho alveolar lavage was not possible in our case owing to young age of the patient. The case was diagnosed as Idiopathic pulmonary hemosiderosis and patient was treated with systemic steroids. The patient is clinically stable at present.

Author: e-mail: annie28dec85@gmail.com

© 2020 Global Journals



Fig. 1: X ray showing bilateral infiltrates.

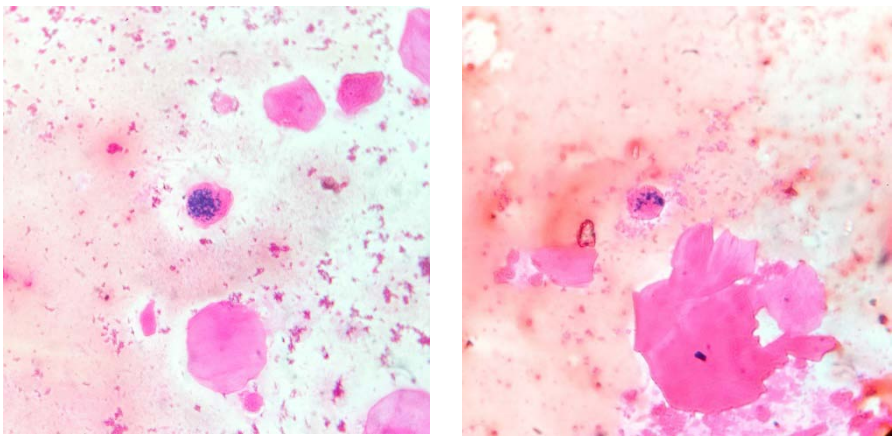

Fig. 2(A, B): Perl's Prussian blue stain showing hemosiderin pigment.

III. Discussion

Studies have shown that the age of presentation in IPH is bimodal, with a frequency peaks in children less than five years of age and in adolescents 11 years or older. [2] Our patient was a 10 month old baby boy. Bulucea C et al in their study of IPH in the Romanian population found that 4 out of the 15 children diagnosed presented with the classical triad of clinical features. They found that all patients, from the beginning had anemia and only 6 children presented with pulmonary symptoms. [6] In our case the predominant feature was anemia refractory to iron therapy along with chest infiltrates and episodes of hemoptysis. It is difficult to diagnose IPH because nutritional iron deficiency anemia is common in children, as is TB, which may present with lung infiltrates not responding to routinely used antibiotics. [7] In case of our patient Tuberculosis was ruled out by Sputum AFB and CBNAAT study. The diagnosis of IPH can be confirmed only after excluding other causes of pulmonary hemorrhage, such as mitral stenosis with congestive cardiac failure, Peri Arteritis Nodosa, Wegener's granulomatosis, Good-pasture's syndrome, Systemic lupus erythematosus, coagulopathies etc.[4,8] In our patient, investigations such as echocardiography, anti neutrophil cytoplasmic antibody (ANCA), antinuclear antibody (ANA), anti-GBM antibody, and coagulation profile were all found to be negative, thus excluding these common causes of pulmonary bleeding. The gold standard for IPH diagnosis is lung biopsy. On the other hand, diagnosis of IPH can be confirmed by bronchoscopy with broncho alveolar lavage, showing hemosiderin-laden macrophages.[5] Khonglah Y et al and Bakalli I et al in their respective studies have found siderophages in gastric lavage fluid, which is equally diagnostic and also the simplest, reliable test in infants and young children.[1,9] Our case was diagnosed by the presence of abundant hemosiderin laden macrophages in the gastric lavage fluid which was confirmed by Perl's Prussian blue stain for hemosiderin. Corticosteroids have a favorable effect in acute episodes of alveolar hemorrhage, although there have been few studies showing that, in patients with IPH, they are protective against recurrence or evolution to pulmonary fibrosis.[10] Low dose immuno suppressants like Azathioprine

© 2020 Global Journals

added with corticosteroids is also used in recent times for therapy.[10] Our patient on diagnosis was started with parental steroid therapy supported by iron and vitamin supplementation. The patient at present is stable and under follow up.

IV. Conclusion

Idiopathic pulmonary Hemosiderosis is a rare disorder and the diagnosis is by exclusion. Therefore, early definitive diagnosis and aggressive immunosuppressive therapy of idiopathic pulmonary hemosiderosis (IPH) are required to prevent pulmonary fibrosis and mortality in these patients. Late diagnosis may yield poorer prognosis. Obtaining broncho alveolar lavage in neonates and children can be difficult and in centers where bronchoscopy is not available, the present of hemosiderin laden macrophages in the gastric lavage fluid is equally diagnostic and also the simplest, reliable diagnostic test.

References Références Referencias

1. Y Khonglah, V Raphael et al. Idiopathic pulmonary hemosiderosis: diagnosis by gastric lavage. Afr J Respir Med 2013; 8: 26-27.
2. Ioachimescu OC, Sieber S, Kotch A. Idiopathic pulmonary hemosiderosis revisited. Eur Respir J 2004; 24:162-70.
3. Ferrari GF, Fioretto JR et al. Idiopathic pulmonary hemosiderosis: Case Report. J Pediatr (Rio J) 2000; 76: 149–52.
4. Koker SA et al. Idiopathic pulmonary hemosiderosis mimicking iron deficiency anemia: a delayed diagnosis? Hematol Rep 2017; volume 9:7048.
5. Salih ZN, Akhter A, Akhtre J. Specificity and sensitivity of hemosiderin laden macrophages in routine broncho alveolar lavage in children. Arch Pathol Lab Med 2006; 130: 1684–6.
6. Bulucea C, Sorin D: Idiopathic pulmonary hemosiderosis in children: a Romanian experience. Pediatrics 2008; 121:158–159.
7. Kwak GY, Lee NY, Lee MH, et al. A case of idiopathic pulmonary hemosiderosis with seasonal recurrence. Korean J Peds 2009; 52: 256–60.
8. Patra C, Sarkar S, Dasgupta MK. A child with recurrent pallor and hemoptysis: Diagnostic challenges. Egyp J Bronchology 2017; 11:62–65.
9. Bakalli I, Kota L et al. Idiopathic pulmonary hemosiderosis - a diagnostic Challenge. Ital J Pediatr 2014, 40:35.
10. Sant Ana C et al. Idiopathic pulmonary hemosiderosis treated with Azathioprine in a child. J Bras Pneumol. 2007; 33(6):743-746.

© 2020 Global Journals