Volume 20 Issue 56
Originally issued as C4



Global Journal of Medical Research: C
Microbiology and Pathology
Volume 20 Issue 4 Version 1.0 Year 2020
Type: Double Blind Peer Reviewed International Research Journal
Publisher: Global Journals
Online ISSN: 2249-4618 & Print ISSN: 0975-5888

Unilateral Primary Ovarian Lymphoma: A Case Report

By Ayesha Afreen Islam

Abstract- Involvement of the ovary by malignant lymphoma is well known as a late manifestation of disseminated nodal disease. But primary ovarian lymphoma as the initial manifestation is unusual. Histologically they are almost always of the non-Hodgkin's type. Primary ovarian lymphomas, account for only 0.5% of all non-Hodgkin lymphomas (NHLs) and 1.5% of all ovarian neoplasms. Previous studies of NHL involving gynecologic sites have shown that most (90%) NHLs involving the ovary are systemic tumors, of which ovarian involvement is only one aspect. In this article we report a case of unilateral primary ovarian NHL in a 35 yrs female patient. Consecutive histopathology and immunohistochemistry study revealed a primary Diffuse Large B-Cell Lymphoma (DLBCL) of ovary.

GJMR-C Classification: NLMC Code: QZ 350



Strictly as per the compliance and regulations of:



© 2020. Ayesha Afreen Islam. This is a research/review paper, distributed under the terms of the Creative Commons Attribution-Noncommercial 3.0 Unported License http://creativecommons.org/licenses/by-nc/3.0/), permitting all non-commercial use, distribution, and reproduction in any medium, provided the original work is properly cited.

Unilateral Primary Ovarian Lymphoma: A Case Report

Ayesha Afreen Islam

Abstract- Involvement of the ovary by malignant lymphoma is well known as a late manifestation of disseminated nodal disease. But primary ovarian lymphoma as the initial manifestation is unusual. Histologically they are almost always of the non-Hodgkin's type. Primary ovarian lymphomas, account for only 0.5% of all non-Hodgkin lymphomas (NHLs) and 1.5% of all ovarian neoplasms. Previous studies of NHL involving gynecologic sites have shown that most (90%) NHLs involving the ovary are systemic tumors, of which ovarian involvement is only one aspect. In this article we report a case of unilateral primary ovarian NHL in a 35 yrs female patient. Consecutive histopathology and immunohistochemistry study revealed a primary Diffuse Large B-Cell Lymphoma (DLBCL) of ovary.

I. Introduction

Non-Hodgkin's lymphoma (NHL)is known to involve the female genital tract. The ovary is the most common anatomic site to be involved. Ovarian involvement by NHL is usually secondary, occurring as a part of systemic disease. [1] The primary involvement of the ovary by NHL is rare and accounts for less than 0.5% of all ovarian neoplasms, unlike testis where primary lymphomas account for 5% of testicular neoplasms. Less than 10% of all ovarian NHLs have been reported to be of primary origin. [2] Their presentation is similar to other ovarian tumors and less commonly, the tumors are incidental findings. [3]

Here, we take the opportunity to report a case of ovarian NHL along with the immuno histochemical (IHC) panel and its differential diagnosis.

II. Case Report

A 45 yr old female presented to the gynecology OPD with complaints of amenorrhea, occasional spotting, distension of abdomen and pain in the lower abdomen. Her sonogram revealed a right adnexal mass measuring 51mmx37mmx10mm (Fig1A). The SOL was solid cystic in nature. The left ovary was unremarkable. Pelvic lymph nodes were not involved (Fig 1B). The patient underwent total abdominal hysterectomy with bilateral salphingo-oopherectomy. On histopathological examination, the uterus and the smaller left ovary were unremarkable. Sections from the right ovary showed a tumor with solid and cystic areas comprising sheets of small round cells with hyper chromatic nuclei, 2-3 nucleoli and scanty basophilic cytoplasm. The tumor was interspersed with plentiful tingible body macrophages. The capsule was intact. (Fig2A,2B,2C). Although the tumor morphologically resembled a lymphoma, in view of the common differentials like the possibility of a poorly differentiated carcinoma had to be excluded. A panel of IHC for markers was used. The tumor showed to be LCA positive, CD20 positive (Fig 2D) and was negative for CK, inhibin and CD-117. PAX8 and WT1 were also negative, ruling out the possibility of ovarian carcinoma, dysgerminoma and desmoplastic small round cell tumor. Ki 67 index was approximately 10%.

Based on histology and IHC results the diagnosis of unilateral primary DLBCL of the ovary was made.

Author: *e-mail: annie28dec85@gmail.com*

© 2020 Global Journals



FIG 1A

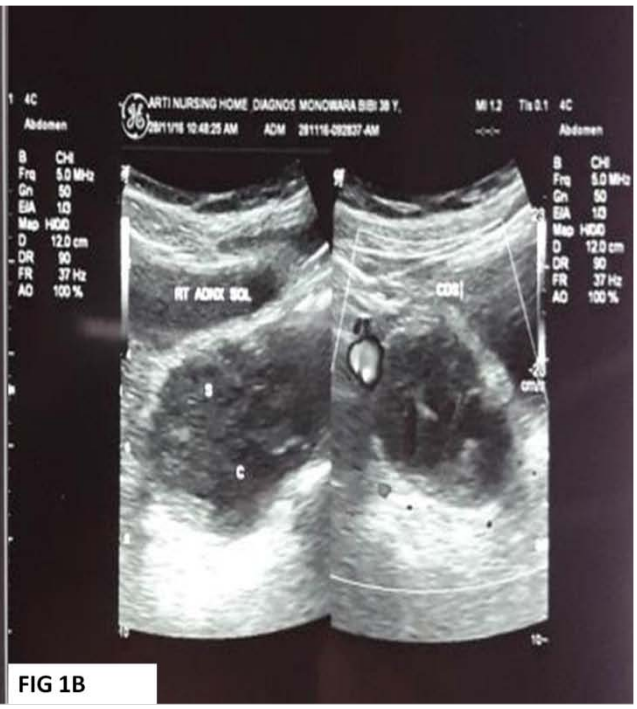

FIG 1B

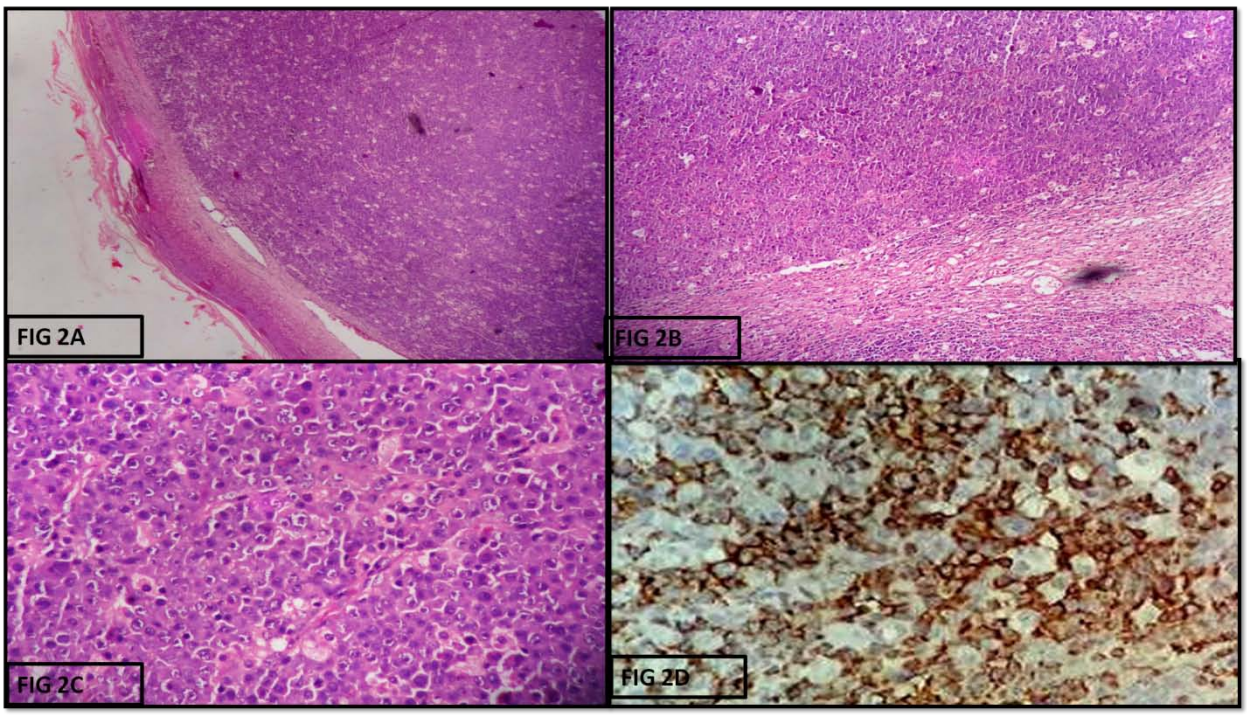

FIG 2A

FIG 2B

FIG 2C

FIG 2D

III. Discussion

Primary ovarian NHL often mimics the more common ovarian tumors like advanced epithelial carcinoma therefore correct diagnosis is needed for ideal treatment. [3] Secondary ovarian involvement by malignant lymphoma is a well recognized entity and has been reported in 20-30% of cases in some autopsy series. The distinction between primary and secondary lymphomas is usually made postoperatively, after thorough histological examination and ruling out secondary involvement. In this study the confirmation of the diagnosis was made postoperatively, as the preliminary diagnosis was an ovarian carcinoma. As suggested by Fox et al, diagnostic criteria for primary ovarian lymphoma are a) a disease confined to ovary, b) absence of disease in blood and bone marrow; c) the extra ovarian carcinoma deposits if any should appear at least after few months.[4] In our case there was no blood, bone marrow, spleen or hepatic involvement. Other sided ovary and fallopian tube were unremarkable. Absence of lymphadenopathy with

© 2020 Global Journals

normal blood and bone marrow findings favor the diagnosis of primary lymphoma. [4] Although CA-125 is a sensitive marker, it lacks specificity for confirming the diagnosis of epithelial ovarian tumors. High serum levels of CA-125 have been reported sometimes in ovarian lymphoma. [1]

Histologically, nearly all primary lymphomas (80%–95%) of the ovary are B-cell neoplasms. DLBCL is most common in the 35 to 45year age group, and our case falls into this age group. Rarely patients of ovarian lymphoma are HIV positive and immuno suppressed similar to cases of primary testicular and primary CNS lymphomas, however in majority of the cases there are no predisposing factors. [5] Primary lymphoma of the ovary may be a misdiagnosed with other primary ovarian tumors like dysgerminoma, granulocytic sarcoma, granulosa cell tumor, undifferentiated carcinoma, Desmoplastic Small Round Cell Tumor (DSRCT) and metastatic carcinoma. Of these, dysgerminoma and DSRCT commonly mimic lymphoma, both macroscopically and microscopically. Only 10% of dysgerminoma are bilateral in contrast to 50% of the lymphomas.[4,6] The most common histological subtype of Primary Ovarian NHL in adults is DLBCL (75%) followed by Burkitt lymphoma (12.5%) and Follicular Lymphoma and rare cases of B and T lymphoblastic lymphoma. Burkitt lymphoma is the most common NHL subtype affecting ovaries of children and adolescents. [8] Histomorphological features of the tumor cells along with IHC help to arrive at a definite diagnosis. Immunohistochemistry in our case showed positivity of tumor cells for B lineage markers (CD 20) and negative for epithelial and mullerian markers. [9]

Primary lymphomas distinctly have a better prognosis than poorly differentiated ovarian carcinomas. Therefore, it is important to make the distinction of this entity from other differentials. Treatment principles and prognosis are same as that of other nodal lymphomas and there are documentation of complete remission after treatment with chemotherapeutic regimens.[1] However, after documentation of complete remission, the patient should be assessed clinically (history and physical examination) at 3-month follow-ups for 2 years, every 6 months for the next 2 years, and yearly thereafter. Repeat contrast-enhanced CT or PET-CT should be per-formed at follow-up only if there is a clinical suspicion of relapse. [1] The follow-up of the patients with primary ovarian lymphoma remain the same as for nodal lymphomas. [10]

IV. Conclusion

Here we take the opportunity to report a case of Primary NHL of the ovary along with its histological differentials. IHC is useful in establishing and categorizing the tumor subtype. Accurate diagnosis and subtyping is important for management as its prognosis differs vastly from other primary and metastatic ovarian tumors.

References Références Referencias

1. Shokralla HA, Fathalla AE, Sidhom NFH. Primary Ovarian Non-Hodgkin's Lymphoma: Retrospective Study of 16 Patients. J Cancer Ther. 2016; 7:55-62.
2. Bhartiya R, Kumari N, Mallik M, Singh RV. Primary Non Hodgkin's Lymphoma of the Ovary. J Clin Diagn Res.2016.
3. Yadav PS, George P, Sharma SC, Gorsi U, McClennan E, Martino MA et al. Primary Non-Hodgkin Lymphoma of the Ovary. Semin Oncol. 2014; 41:19-30.
4. Fox H, Langley FA, Govan AD, Hill SA, Bennett MH. Malignant Lymphoma Presenting as an Ovarian Tumor: A Clinico pathological Analysis of 34 Cases. Br J Obstet Gynaecol.1988; 95:386-90.
5. Senol T, Doger E, Kahramanoglu I, Geduk A, Kole E, Yucesoy I et al. Five Cases of Non-Hodgkin B-Cell Lymphoma of the Ovary. Case Rep Obstet Gynecol. 2014; 1014:392758.
6. Skodras G, Fields V, Kragel PJ. Ovarian Lymphoma and Serous Carcinoma of Low Malignant Potential arising at the Same Ovary. A Case Report with Literature Review of 14 Primary Ovarian Lymphomas. Arch Pathol Lab Med. 1994; 118: 647-50.
7. Azizoglu C, Altinok G, Uner A, Sokmensuer C, Kucukali T, Ayhan A. Ovarian Lymphomas: A Clinico pathological Analysis of 10 Cases. Arch Gynecol Obstet. 2001; 265:91-93.
8. Deepti A, Sangeeta S, Rani B, Shikha S. Primary Bilateral Ovarian Non Hodgkin's Lymphoma. J Clin Diagn Res. 2010; 4:3212-14.
9. Ray S, Mallick MG, Pal PB, Choudhury MK, Bandopadhya A, Guha D. Extra nodal Non Hodgkin Lymphoma presenting as an ovarian mass. Indian J Pathol Microbiol. 2008; 51:528-30.
10. Komoto D, Nishiyama Y, Yamamoto Y, Monden T, Sasawaka Y, Toyama Y et al. A case of non-Hodgkin's lymphoma of the ovary: Usefulness of 18 FDG PET for staging and assessment of the therapeutic response. Ann Nucl Med. 2006; 20: 157–60.

© 2020 Global Journals