Volume 20 Issue 55
Originally issued as E6

Global Journal of Medical Research: E
Gynecology and Obstetrics
Volume 20 Issue 6 Version 1.0 Year 2020
Type: Double Blind Peer Reviewed International Research Journal
Publisher: Global Journals
Online ISSN: 2249-4618 & Print ISSN: 0975-5888

A Case of Transient Cortical Blindness in Posterior Reversible Encephalopathy Syndrome in the Late Postpartum Period

By Dr. Krishna. K. Nair, Dr. Jayanthi. R & Dr. Sahitya Meda

Introduction- Posterior reversible encephalopathy syndrome (PRES) is a reversible neurological entity characterized by seizure, headaches, visual symptoms, impaired consciousness and other focal neurological findings.

It is caused by a wide variety of causes ultimately leading to vasogenic cerebral oedema of occipital and parietal lobes of the brain.

The pathophysiology is failure of cerebral autoregulationand endothelial dysfunction.

GJMR-E Classification: NLMC Code: QS 675

ACASEOFTRANSIENTCORTICALBLINDNESSINPOSTERIORREVERSIBLEENCEPHALOPATHYSYNDROMEINTHELATEPOSTPARTUMPERIOD

Strictly as per the compliance and regulations of:

© 2020. Dr. Krishna. K. Nair, Dr. Jayanthi. R & Dr. Sahitya Meda. This is a research/review paper, distributed under the terms of the Creative Commons Attribution-Noncommercial 3.0 Unported License http://creativecommons.org/licenses/by-nc/3.0/), permitting all non-commercial use, distribution, and reproduction in any medium, provided the original work is properly cited.

A Case of Transient Cortical Blindness in Posterior Reversible Encephalopathy Syndrome in the Late Postpartum Period

Dr. Krishna. K. Nair [α], Dr. Jayanthi. R [σ] & Dr. Sahitya Meda [ρ]

I. Introduction

Posterior reversible encephalopathy syndrome (PRES) is a reversible neurological entity characterized by seizure, headaches, visual symptoms, impaired consciousness and other focal neurological findings.

It is caused by a wide variety of causes ultimately leading to vasogenic cerebral oedema of occipital and parietal lobes of the brain.

The pathophysiology is failure of cerebral autoregulationand endothelial dysfunction.

II. Case Presentation

A 33 years old women, Para-2,Live-2,post elective LSCS on POD 10,with no prior co-morbities, presented with the history of abrupt onset of blurring of vision since last 5 hours, which was progressive and developed transient loss of vision within 2 hours from the onset of the symptoms.

It was associated with deviation of angle of mouth to the right side and mild headache. No h/o loss of consciousness, seizure episode, voimiting, weakness in the upper or lower limbs or trauma. she has an otherwise uneventful pregnancy. No H/O gestational hypertension. No significant family history.

Intraoperative and postoperative period was uneventful. no H/O undue bleeding in the postpartum period. She was breastfeeding her newborn.

On examination: patient was conscious, alert and oriented. she was found to have elevated BP-180/100mmhg.Rest of the vital signs were within normal limits. Systemic examination was done no abnormalities were detected.

Power was 5/5 in all 4 limbs. sensory function was intact .cranial nerve examination was unremarkable. cerebral signs were intact. no signs of neck rigidity. plantars were B/L flexors.

On ocular examination, visual acuity of both the eyes were 1/60 with bilateral pupils reacting well to the light with normal fundus.

Investigations: Laboratory findings were –Hb-11.6gm%, TLC-11500cmm, Platelet count-2.75 lakhs/cmm; No proteinuria; PT, APTT, INR –within normal limits. LFT,RFT-were within normal limits.

MRI –Bilateral occipital lobe hyperdensities noted in the T2 Flair images, consistent with posterior reversible encephalopathy syndrome (PRES).

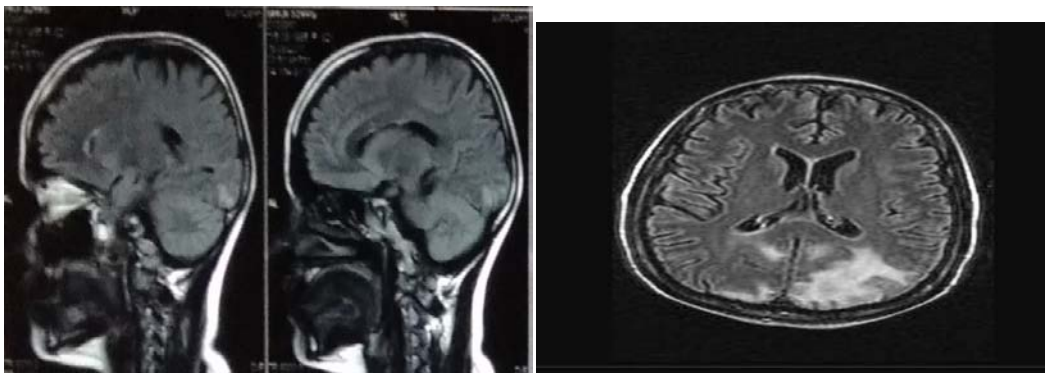

Author α: Postgraduate, Department of Obstetrics and Gynaecology, Meenakshi Medical College Hospital and Research Institute, Kanchipuram Tamilnadu India. e-mail: krishnasarathnair@gmail.com
Author σ: Professor and HOD, Department of Obstetrics and Gynaecology, Meenakshi medical college hospital and research Institute, Kanchipuram Tamilnadu India.
Author ρ: Assistant Professor, Department of Obstetrics and Gynaecology, Meenakshi Medical College Hospital and Research Institute, Kanchipuram Tamilnadu India.

© 2020 Global Journals

Differential Diagnosis:

1. Ischemic stroke
2. cerebral haemorrhage
3. cerebralvenous thrombosis,
4. Posterior reversible encephalopathy syndrome (PRES)
5. Hypertensive emergency with retinal haemorrhage.

Treatment: The patient was transferred to the intensive care unit. LABETALOL infusion was started at a rate of 1mg/min with close monitoring of blood pressure. Patient's symptoms gradually resolved and her vision improved to 6/6 after 8 hours.

Her Blood pressure was maintained at 130/80mmhg and Labetalol infusion was stopped and was started on Tab. Amlodipine 5 mg 12th hourly.

Patient continued to improve clinically and was discharged on 5th day of hospitalization. She was prescribed Tab. Amlodipine 2.5mg BD.

III. Discussion

Posterior reversible encephalopathy syndrome (PRES) was first described by Hinchey et al. in 1996.

It is a reversible neurological entity characterized by the presence of white matter oedema affecting the occipital and parietal lobes. It can occur at any age and most commonly affects female.

A variety of clinical conditions are associated with the development of PRES, which include hypertensive emergency, renal disease, pre-eclampsia/ eclampsia, immunosuppressive agents, sepsis, auto immune disease.

MRI is the imaging modality of choice. Diffusion-weighted MRI helps to distinguish the Vasogenic oedema from cytotoxic oedema. Permanent neurological impairment or death occurs only in a minority of patients. Recurrence of symptoms has been observed in 8% of the cases.

IV. Conclusion

As indicated by its name, appropriate treatment is expected to ensure a full recovery. MRI of the brain is crucial to make the diagnosis.

The management of PRES involves early diagnosis, treatment of the symptomatology and correction of the causative factor.

References Références Referencias

1. Hinchey J, Chaves C, Appignani B, et al. A reversible posterior leukoencephalopathy syndrome. N Engl J Med 1996; 334:494–500.
2. Legriel S, Pico F, Azoulay E. Understanding posterior reversible encephalopathy syndrome. Annual update in intensive care and emergency medicine 2011. Springer, 2011:631–53.
3. Servillo G, Bifulco F, De Robertis E, et al. Posterior reversible encephalopathy syndrome in intensive care medicine. Intensive Care Med 2007; 33:230–6.
4. Roth C, Ferbert A. Posterior reversible encephalopathy syndrome: long-term follow-up. J Neurol Neurosurg Psychiatry 2010; 81:773–7.
5. Felz MW, Barnes DB, Figueroa RE. Late postpartum eclampsia 16 days after delivery: case report with clinical, radiologic, and pathophysiologic correlations. J Am Board Fam Pract 2000; 13:39–46.
6. Ekawa Y, Shiota M, Tobiume T, et al. Reversible posterior leukoencephalopathy syndrome accompanying eclampsia: correct diagnosis using preoperative MRI. TohokuJ Exp Med 2012; 226: 55–8.
7. Dominguez-Fuentes B, Garcia-Gil D, Romero-Palacios A, et al. [Posterior reversible leukoencephalopathy in a patient with postpartum eclampsia]. Medicina Intensiva 2008; 32:361–3.
8. Garg RK. Posterior leukoencephalopathy syndrome. Postgrad Med J 2001; 77:24–8.
9. Chiou YH, Chen PH. Reversible posterior encephalopathy syndrome as the presentation of late postpartum eclampsia: a case report. Acta Neurol Taiwan 2007; 16:158–62.
10. Chhabra S, Tyagi S, Bhavani M, et al. Late postpartum eclampsia. J Obstet Gynaecol 2012; 32:264–6.

© 2020 Global Journals