



GLOBAL JOURNAL OF MEDICAL RESEARCH: F
DISEASES

Volume 22 Issue 4 Version 1.0 Year 2022

Type: Double Blind Peer Reviewed International Research Journal

Publisher: Global Journals

Online ISSN: 2249-4618 & Print ISSN: 0975-5888

Epicapsular Stars: A Rare Entity

By Fiqhi Aissam

Hospital Militaire Rabat Maroc

Introduction- An 18-year-old female presented to the ophthalmology clinic for allergic conjunctivitis with a 20/20 best-corrected visual acuity. Slit-lamp examination of her left eye revealed, fortuitously, multiple tiny, stellate-shaped, pigment deposits on the anterior lens capsule suggestive of Epicapsular stars. These pigmentations were clustered in an exceptional shape reminiscent of the letters "J" and "Y". Epicapsular stars result from incomplete apoptosis of the anterior portion of "tunica vasculosa lentis". They could affect one or both eyes, be isolated or clustered, and are usually asymptomatic like in our case. Consequently, our patient didn't need any treatment but has still followed up regularly.

GJMR-F Classification: DDC Code: 617.7 LCC Code: RE1



Strictly as per the compliance and regulations of:



Epicapsular Stars: A Rare Entity

Fiqhi Aissam

INTRODUCTION

An 18-year-old female presented to the ophthalmology clinic for allergic conjunctivitis with a 20/20 best-corrected visual acuity. Slit-lamp examination of her left eye revealed, fortuitously, multiple tiny, stellate-shaped, pigment deposits on the anterior lens capsule suggestive of Epicapsular stars. These pigmentations were clustered in an exceptional shape

reminiscent of the letters "J" and "Y". Epicapsular stars result from incomplete apoptosis of the anterior portion of "tunica vasculosa lentis". They could affect one or both eyes, be isolated or clustered, and are usually asymptomatic like in our case. Consequently, our patient didn't need any treatment but has still followed up regularly.

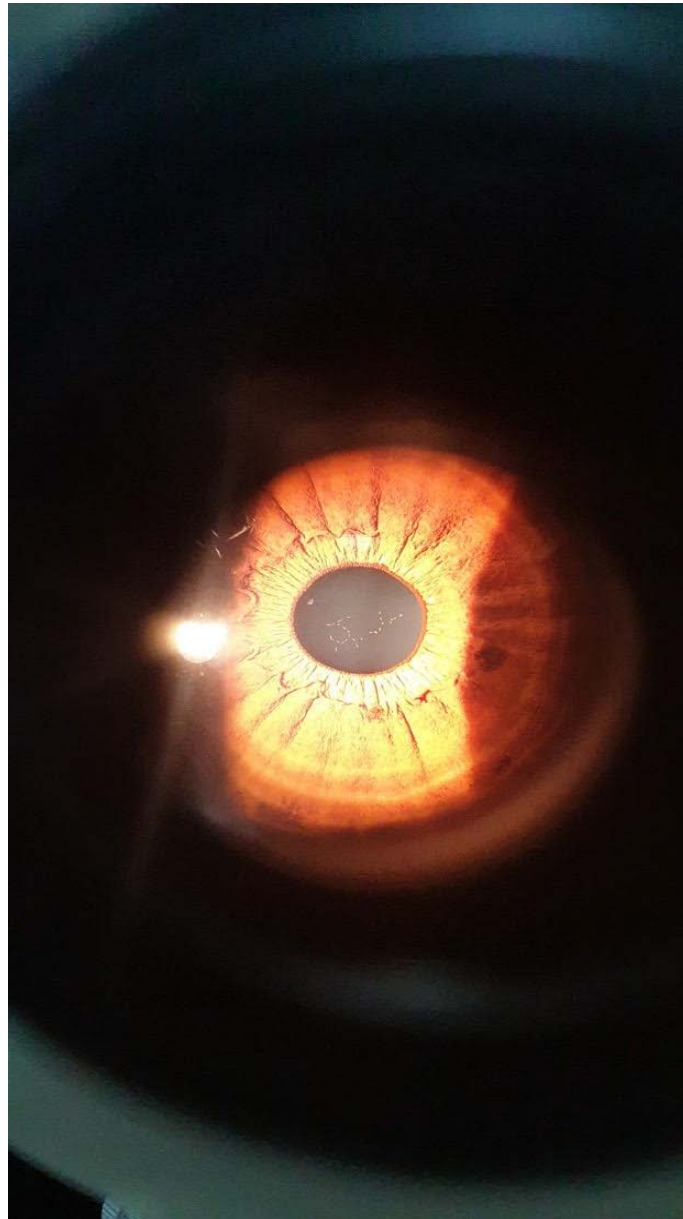


Figure 1: Pigmentations clustered in an exceptional shape reminiscent of the letters "J" and "Y"

Author: Hospital Militaire Rabat Maroc. e-mail: fiqhiaissam@gmail.com

REFERENCES RÉFÉRENCES REFERENCIAS

1. Zeng R, Liang X, Wang Guoping. Epicapsular stars. Ophtalmology. 2016; 123: 2076.
2. Choudhry S, Rao SK, Choudhry S. Management of a typical epicapsular star .J Cataract Refract Surg. 2001; 27: 481-484.
3. Gavris M, Horge I, Avram E, Belicioiu R, Olieanu IA, Kedves H. Persistent pupillary membrane or accessory iris membrane. Rom J Ophthalmol 2015; 59: 184-7.

