Volume 19 Issue 26
Originally issued as J3

Global Journal of Medical Research: J
Dentistry & Otolaryngology
Volume 19 Issue 3 Version 1.0 Year 2019
Type: Double Blind Peer Reviewed International Research Journal
Publisher: Global Journals
Online ISSN: 2249-4618 & Print ISSN: 0975-5888

Pterygoid Implant: A Graftless Approach for Maxillary Rehabilitation using TTPHIL-ALL TILT® (Tall Tilted Pin Hole Placement with Immediate Loading) Technique

By Dr. P. Venkat Ratna Nag, Dr. P. Sarika & Dr. Tejashree Bhagwatkar

Abstract- Edentulism is a common dental problem in the elderly population. The maxillary posterior edentulous region offers a unique and challenging condition in implant dentistry. The maxillary posterior region presents with numerous anatomic complications in terms of bone quantity, quality, maxillary sinus pneumatization, and poor approachability. Most remarkable surgical approaches include sinus lift, bone grafting, pterygoid implant, considered as valid solutions to this problem. Pterygoid implants require lot of skill of the dentist and also is proven to be statistically superior. In this case series, the pterygoid implants placed and restored using TTPHIL (Tall Tilted Pin Hole placement with Immediate Loading)- ALL TILT® technique in the patients with atrophic posterior maxilla are discussed.

Keywords: pterygoid implants, graftless solutions, immediate loading, TTPHIL-ALL TILT®.

GJMR-J Classification: NLMC Code: WV 345



Strictly as per the compliance and regulations of:

© 2019. Dr. P. Venkat Ratna Nag, Dr. P. Sarika & Dr. Tejashree Bhagwatkar. This is a research/ review paper, distributed under the terms of the Creative Commons Attribution-Noncommercial 3.0 Unported License http://creativecommons.org/licenses/by-nc/3.0/), permitting all non-commercial use, distribution, and reproduction in any medium, provided the original work is properly cited.

Pterygoid Implant: A Graftless Approach for Maxillary Rehabilitation using TTPHIL-ALL TILT® (Tall Tilted Pin Hole Placement with Immediate Loading) Technique

Dr. P. Venkat Ratna Nag [α], Dr. P. Sarika [σ] & Dr. Tejashree Bhagwatkar [ρ]

Abstract- **Edentulism is a common dental problem in the elderly population. The maxillary posterior edentulous region offers a unique and challenging condition in implant dentistry. The maxillary posterior region presents with numerous anatomic complications in terms of bone quantity, quality, maxillary sinus pneumatization, and poor approachability. Most remarkable surgical approaches include sinus lift, bone grafting, pterygoid implant, considered as valid solutions to this problem. Pterygoid implants require lot of skill of the dentist and also is proven to be statistically superior. In this case series, the pterygoid implants placed and restored using TTPHIL (Tall Tilted Pin Hole placement with Immediate Loading)- ALL TILT® technique in the patients with atrophic posterior maxilla are discussed.**

Keywords: pterygoid implants, graftless solutions, immediate loading, TTPHIL-ALL TILT®.

I. Introduction

Oral health plays important role to uphold proper mastication, digestion, phonation, aesthetic, and emotional well-being. The loss of permanent teeth can occur for a variety of reasons, ranging anywhere from hereditary factor, congenital absence, diseases of the dentition (e.g., caries or periodontal disease) and trauma.[1]An edentulous condition existing in the posterior maxilla poses a challenge to all the clinicians. The reasons behind this are the anatomic factors like bone quality (type III or IV) according to Lekholm and Zarb [2], quantity, location of the maxillary sinus, and poor accessibility in the posterior region[3,4].

The pterygoid implants was introduced by Tulasne JF (1992). The advantage of a pterygoid implant is that it allows anchorage, eliminates posterior cantilever and improved axial loading in the posterior atrophic maxilla.[5] It eradicates the need for other techniques like sinus lifts or bone grafts[6,7], increased implant diameters or short implant of 8mm or lesser and implant placement in zygoma[9]. Placement of implants in the pterygoid region provides posterior bone support, bypass sinus augmentation, or bone grafts. Because of inadequate accessibility, placement of pterygoid implants is more technically demanding than placing short implants anterior to the maxillary antrum. However, there are no risks associated with implant placement in pterygoid area[3].

The TTPHIL-ALL TILT® – (Tall Tilted Pin Hole Immediate Loading) concept has evolved from various ideologies in implantology: basal, pterygoid and angulated/tilted implants under immediate loading. To maximize the success of rehabilitation, the TTPHIL technique utilizes the use of long tilted bicortical implants by engaging the pterygoid region. Pterygoid implants were intended to pass through maxillary tuberosity, the pyramidal process of palatine bone and the pterygoid process of the sphenoid bone.[3,10,11] In the literature, success rates of pterygoid implants for maxillary rehabilitation have been more than 94 to 99%. Thus, the TTPHIL-ALL TILT® technique is a novel approach for the placement of implants; it was derived from established schools of thought in implantology.[12]

In this article, following cases are examples of patients indicated for pterygoid implants using TTPHIL-ALL TILT® in partially edentulous and completely edentulous maxilla.

II. Case Report

Case 1: Partially Edentulous Maxillary Arch (Immediate Implantation)

A 42-year-old male patient reported with a chief complaint of loose teeth in the upper left back region of the jaw. Clinical examination revealed Grade II mobility about tooth 27, gingival recession, missing 26, and poor oral hygiene status. (Fig: 1 a, b) The patient was willing to go ahead with a fixed prosthesis for the same region. TTPHIL- ALL TILT® technique was planned for the same; a thorough radiographic evaluation was suggested to the patient. These studies included panoramic films, CBCT, and stereolithography models. The mouth

Author α: MDS, Professor, Department of Prosthodontics, S.B. Patil Dental College and Hospital, Bidar, Karnataka, India Director, Institute for Dental Implantology, Hyderabad, India.
e-mail: tdspublication@gmail.com
Author σ: MDS, Reader, Department of Pedodontics and Preventive Dentistry, S.B. Patil Dental College and Hospital, Bidar, Karnataka, India. e-mail: sarikapedo@gmail.com
Author ρ: MDS, Oral Pathologist, Institute for Dental Implantology, Hyderabad, India. e-mail: dr.tejashree12@gmail.com

© 2019 Global Journals

opening was also evaluated and found adequate for pterygoid implants. Routine blood investigations were performed. Radiographic picture (Fig: 1 c) and computed tomography suggested moderate bone loss present in the maxillary sinus region. Considering the amount of bone, atraumatic extraction of 27, followed by the placement of two implants in the left maxillary posteriori. e. 26, 28 (pterygoid implant) was planned and discussed with patient. Patient consent for the treatment was taken. Under aseptic precautions, local anesthesia was given at the surgical sites, and atraumatic extraction of 27 was performed. The socket was curetted carefully and irrigated with sterile saline solution, drilling was done through extraction socket at the planned length. The pilot drill of 1.2mm was then inserted through the mucosa into the alveolar bone of 26 for point of entry to a depth of 6mm. Single drill concept was used, i.e. long stepped drill with diameters of 1.4 or 2.2mm with enough coolant. The under-drilling concept was followed, wherein the dimension of the drills is less than the implant to be positioned for better anchorage. The bioline implant 3.75mm × 13mm and 3.75mm × 22mm mounted on the implant driver, and torque ratchet was used for final placement of 26, 28 (Fig: 2 a). Post-implant placement orthopantomogram was exposed (Fig: 2 b). Multiunit abutments were placed at correct angulations to compensate for the tilt of the implants. The surgical protocol was followed by the prosthetic phase of impression making with transfer copings, Jig trial, bite records, metal framework trial, bisque trial followed by placement of final prosthesis using CAD-CAM technology for design and fabrication was done (Fig: 2 c). The patient was rehabilitated with screw-retained metal-ceramic fixed prosthesis and orthopantomogram was exposed (Fig: 2 d). The patient was advised to adhere to regular oral hygiene maintenance.



a.



b.

Fig. 1 a and b: Intra-oral view showing gingival recession with 27, missing 26



c.

Fig. 1 c: Pre-operative OPG showing moderate bone loss with 27 and minimal bone in the region of maxillary sinus and adequate bone in the pterygoid region.



Fig. 2 a: Clinical photograph showing two implant placements (26, 28) in left maxillary region



Fig. 2 b: Post-operative OPG showing placement of 2 implants in 26, 28 region

© 2019 Global Journals



Fig. 2 c: Final Metal–ceramic prosthesis was given



Fig. 2 d: Postoperative OPG after fixed implant prostheses

Case 2: Partially Edentulous Maxillary Arch (Delayed Implantation)

A 37-year-old female patient came with a chief complaint of missing teeth and wanted to get them replaced. On intraoral examination (Fig: 3 a), missing 15, 16, 24, 25, 27, root stumps about 17, 26 and badly decayed 11, 12, 13, 21 were observed. The patient was keen on having a fixed prosthesis. On detailed examination of the orthopantomogram (Fig: 3 b), there appeared to be adequate width of the available bone anterior to the maxillary sinus but the inadequate bone in the maxillary sinus region. Treatment plan for the patient was atraumatic extraction of root stumps and immediate placement of six implants i.e. 14, 15, 27 (pterygoid implant), 25, 26, 28 (pterygoid implant). Under aseptic precautions, local anesthesia was administered at the planned surgical sites and atraumatic extraction of 17, 26 was done. Extraction sockets were thoroughly debrided and inspected with the help of periodontal probe for any defect or possible perforation of the cortical plate. Six Bioline implants were placed in the regions of 14, 15, 17 (Pterygoid implant), 25, 26, 28 (Pterygoid implant) (Fig: 4 a). The dimensions of the implants were 3.75 mm × 20 mm (14, 15, 25, 26) and 3.75 mm × 22 mm (Pterygoid implant i.e 17, 28) respectively. The orthopantomogram of post-implant placement was exposed (Fig: 4 b). Multiunit abutments were placed at correct angulations to compensate for the tilt of the implants. Final prosthesis was designed and fabricated using CAD-CAM technology (Fig: 4 c). Postoperative OPG was taken immediately after fixed implant prostheses. (Fig: 4 d) The patient was advised to adhere to strict soft diet regimen for a few days with regular oral hygiene maintenance and recalled for clinical and radiographic assessment.



Fig. 3 a: Intra-oral view shows missing posterior maxillary teeth and badly decayed upper front teeth



Fig. 3 b: Pre-operative OPG shows adequate width of the available bone anterior to maxillary sinus but inadequate bone in maxillary sinus region



Fig. 4 a: Clinical photograph showing implant placement



Fig. 4 b: Post-operative OPG showing placement of 6 implants

© 2019 Global Journals



Fig. 4 c: Final Metal–ceramic prosthesis was given

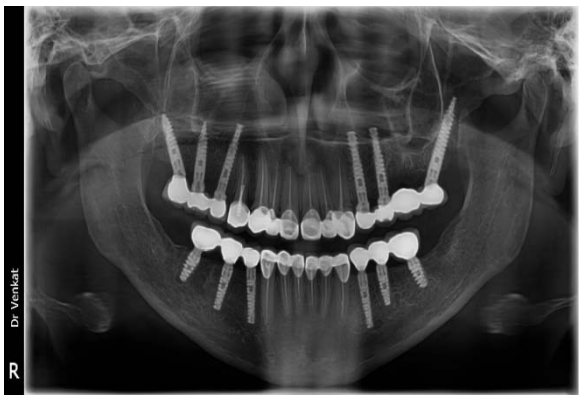

Fig 4 d: Postoperative OPG after fixed implant prostheses

Case 3: Completely Edentulous Maxillary Arch (Immediate Implantation)

A 61-year-old male patient complained of missing teeth in upper back region of jaw and desired replacement. Clinical examination (Fig: 5 a, b) revealed missing 16, 17, 26, 27, Grade II mobility about tooth 25, Grade I mobility about tooth 14, 15, 24 and splinting was present concerning11,12,13. The patient was willing to receive a fixed prosthesis. Medical history revealed a heart problem and high blood pressure. On detailed examination of the orthopantomogram (Fig: 5 c), CT scan shows severe bone loss and inadequate bone in the maxillary sinus region. Extraction of all teeth, and immediate implant placement 13, 15, 17 (pterygoid implant), 23, 25, 27 (pterygoid implant) was planned and excecuted. Routine blood investigations was performed, and the physician's fitness for the surgical procedure was acquired. Patient consent was obtained before a surgical procedure. Surgical protocol emphasized complete asepsis and infection control. Under local anesthesia, atraumatic extractions of all remaining teeth were completed. Extraction sockets were thoroughly debrided and irrigated with saline solution. Six Bioline implants was placed in the regions of 13, 15, 17 (Pterygoid implant), 23, 25, 27 (Pterygoid implant) (Fig 6 a). Post-implant placement orthopantomogram was exposed (Fig: 6 b). The patient was rehabilitated with screw retained metal-ceramic fixed prosthesis (Fig: 6 c). Postoperative OPG was taken immediately after fixed implant prostheses. (Fig: 6 d) The patient was followed up after few years for clinical and radiographic assessment.



a.



b.

Fig. 5 a, b: Intra-oral view showing missing posterior maxillary teeth and splinting present in anterior teeth



Fig. 5 c: Pre-operative OPG showing severe bone loss and inadequate bone in maxillary sinus region



Fig. 6 a: Clinical photograph showing implant placement

© 2019 Global Journals



Fig. 6 b: Post-operative OPG showing placement of 6 implants



Fig. 6 c: Final Metal–ceramic prosthesis was given



Fig. 6 d: Postoperative OPG immediately after fixed implant prostheses

Case 4: Completely Edentulous Maxillary Arch (Delayed Implantation)

A 61-year-old female patient complained of missing upper teeth and wanted replacement of her denture. Intraoral examination revealed edentulous maxillary arch (Fig: 7 a). The patient was using denture for edentulous maxillary arch for two years and wanted a fixed prosthesis. Medical history revealed diabetes and insulin-dependent. On detailed examination of the OPG (Fig: 7 b), CT scan, there appeared severe bone loss and inadequate bone in the maxillary sinus region. Treatment plan was immediate implant placement 13, 15, 17 (Pterygoid implant), 23, 25, 27 (Pterygoid implant). Routine blood investigations were performed, and the physician's fitness was obtained for surgical procedure. Six Bioline implants were inserted in the planned sites (Fig: 8 a). Post-implant placement orthopantomogram was exposed (Fig: 8 b). The prosthetic phase was carried out. The patient was rehabilitated with a screw-retained metal-ceramic fixed prosthesis (Fig: 8 c). Postoperative OPG was taken immediately after fixed implant prosthesis. (Fig: 8 d)



Fig. 7 a: Intra-oral view showing edentulous maxillary arch



Fig. 7 b: Pre-operative OPG showing severe bone loss and inadequate bone in maxillary sinus region



Fig. 8 a: Clinical photograph showing implant placement

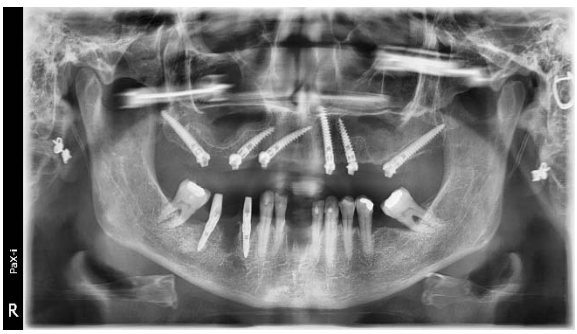

Fig. 8 b: Post-operative OPG showing placement of 6 implants

© 2019 Global Journals



Fig. 8 c: Final Metal–ceramic prosthesis was given



Fig. 8 d: Postoperative OPG was taken after fixed implant prostheses

III. Discussion

Treatment of edentulous patients has always been a challenging task for the dentists. In the modern era, implant dentistry gained popularity and considered as the best alternative, irrespective of resorbed bone, reduced bone density in the maxillary posterior regions and systemic conditions. Krump et al and Barnett et al reported higher success rates for immediate implant placement.[13,14]

In the literature, several articles have assigned many labels for implant placement in the posterior maxillary region. Implants placed in the posterior maxilla have been discussed as pterygoid plate implants[11], tuberosity implants [15-16], and pterygomaxillary implants [17].

The structures that offer support for implant placement are the tuberosity of the maxillary bone, the pyramidal process of the palatine bone, and the pterygoid process of the sphenoid bone [18].

Conventionally, because of the anatomic factors and biomechanical factors[19], the success rates for implants placed in the atrophic posterior maxilla was lower than that for other locations.

In literature, few studies were carried out on pterygoid implants for the survival of implant and prosthesis. Bahat [15] performed a study on 45 patients, 72 implants were engaged in the tuberosity region, and they noted 93% survival rate over an average loading time of 1.7 years. Balshi[16] reported satisfactory 3-year results for 51 implants placed in the pterygoid area supported fixed prostheses in partially edentulous patients. Khayat et al[20] reported on cases of implants placed in the pterygoid region with four years of follow up. Graves[11] described forty-three implants in the pterygoid plate area.

TTPHIL- ALL TILT® (Tall Tilted Pin Hole Immediate Loading) technique[21-25] was evolved after studying and analyzing all the advantages and shortcomings of other traditional and advanced techniques. Using this concept two tall tilted implants engaged the pterygoid region (junction of the palatine process of maxilla, the pyramidal process of palatine bone and pterygoid process of the sphenoid bone), thus eliminating distal cantilever, avoiding sinus encroachment and other augmentation procedures in the posterior maxilla. Tilting of implants avoids anatomical structures like the maxillary sinus. In literature, many studies were carried out on tilted implants, the success rates were found to be 95.7 to 100%[26], which have been improved by bicortical engagement. Tall implants with bicortical engagement offer primary stability which improves implant success.[27]

The subcrestal implant placement decreases the stress in the crestal cortical bone around dental implants. Flapless guided implant placement helps in mucointegration, good aesthetics, reduces the time of treatment, and improves patient satisfaction. Nowadays, practice-driven implantology has been evolved the dimensions (lengths 15-25mm) of implants.[28] Multi-unit abutments, and their components help dentists to correct the angulations caused by the tilted implant.[29] This aids in immediate loading of the fixed prosthesis.[30]

IV. Conclusion

Based on the outcomes of the case reports, Immediate/Delayed implant placement with immediate loading is considered as a feasible treatment option for the patients with the severely atrophic maxilla. The TTPHIL–ALL TILT® technique considered as a graftless solution which is characterized by Tall, tilted implant with bicortical engagement, minimal invasiveness (flapless approach), screw-retained prosthetic solutions with rigid cross arch stabilization with no cantileverage can be delivered in 2-5 days. However, this technique is highly sensitive and requires experts in implant dentistry for its execution. Careful selection of patients, thorough radiographic evaluation, proper treatment planning, and adequate follow-up of surgical and prosthetic protocols are the keys to success.

References Références Referencias

1. Singh M, Kumar L, Anwar M, Chand P. Immediate dental implant placement with immediate loading following extraction of natural teeth. Natl J Maxillofac Surg 2015; 6: 252-5.
2. Lekholm U, Zarb G (1985) Patient selection and preparation. In: Bra°nemark PI, Zarb G, Albrektsson

© 2019 Global Journals

T (eds) Tissue-integrated protheses Osseointegration in clinical dentistry. Quintessence, Chicago, pp 199–209.
3. Balshi T J, Wolfinger G J, Balshi S F II (1999) Analysis of 356 pterygomaxillary implants in edentulous arches for fixed prosthesis anchorage. Int J Oral Maxillofac Implants 14: 398–406.
4. Jaffin R A, Berman C L (1991) The excessive loss of Branemark fixtures in type IV bone: a 5-year analysis. J Periodontol 62: 2–4.
5. Ali S A, Karthigeyan S, Deivanai M, Kumar A. Implant Rehabilitation For Atrophic Maxilla: A Review. J Indian Prosthodont Soc 2014; 14(3): 196–207.
6. Van Steenberghe D, Lekholm U, Bolender C (1990) The applicability of osseointegrated oral implants in the rehabilitation of partial edentulism: a prospective multicenter study on 558 fixtures. Int J Oral Maxillofac Implants 5: 272–281.
7. Johansson B, Wannfors K, Ekenba¨ck J, Smedberg J I, Hirsch J (1999) Implants and sinus-inlay bone grafts in a one-stage procedure on severely atrophied maxillae: surgical aspects of a 3-year follow-up study. Int J Oral Maxillofac Implants 14: 811–818.
8. Hallmann M A (2001) Prospective study of treatment of severely resorbed maxillae with narrow nonsubmerged implants: results after one year of loading. Int Oral Maxillofac Implants 16: 731–736.
9. Sornı´ M, Guarinos J, Pen˜arrocha M (2005) Implants in anatomical buttresses of the upper jaw. Med Oral Patol Oral Cir Bucal 10:163–168
10. Bidra AS, Huynh BG. Implants in the Pterygoid Region: A Systematic Review of the Literature. Int J Oral Maxillofac Surg 2011; 40: 773–781.
11. Graves S L. The Pterygoid Plate Implant: A Solution for Restoring the Posterior Maxilla. Int J Periodont Rest Dent 1994; 14: 513-523
12. Nag PVR, Dhara V, *et al*. Treatment of the Complete Edentulous Atrophic Maxilla: The Tall Tilted Pin Hole Placement Immediate Loading (TTPHIL)-ALL TILT™ Implant Option. J Contemp Dent Pract 2019; 20(6): 754–763.
13. Krump J L, Barnett B G. The immediate implant: A treatment alternative. Int J Oral Maxillofac Implants 1991; 6: 19-23.
14. Singh M, Kumar L, Anwar M, Chand P. Immediate dental implant placement with immediate loading following extraction of natural teeth. Natl J Maxillofac Surg 2015; 6: 252-5.
15. Bahat O (1992) Osseointegrated implants in the maxillary tuberosity: report on 45 consecutive cases. Int J Oral Maxillofac Implants 7: 459–467.
16. Balshi T J (1992) Single tuberosity osseointegrated implant support for a tissue integrated prosthesis. Int J Periodont Restor Dent 12: 345–357.
17. Balshi T J, Hy L, Hernandez R E (1995) The use of pterygomaxillary implants in the partially edentulous patient. Int J Oral Maxillofac Implants 10: 89–99.
18. Grant JCB (1956) An atlas of anatomy. Williams & Wilkins, Baltimore, p 541
19. Anandakrishna G N, Rao G. Pterygomaxillary Implants: A Graftless Solution to Deficient Maxillary Bone. J Indian Prosthodont Soc 2012; 12(3): 182–186.
20. Khayat P, Nader N (1994) The use of osseointegrated implants in the maxillary tuberosity. Pract Periodontics Aesthet Dent 6: 53–61.
21. Venkat Ratna Nag P. Immediate Implant Placement and Loading with Tall and Tilted Pinhole Immediate Loading (TTPHIL) Technique. Guident Sep 2017: 26-27.
22. Venkat Nag P, Sarika P, Pavankumar, A. (2017). TTPHIL-ALL TILT™ Concept – An Innovative Technique in Immediate Functional Loading Implant Placement in Maxilla. Scholars Journal of Dental Sciences. 4(9), 397-399.
23. Venkat Nag P, Sarika P, Khan R, Bhagwatkar T. (2018). Tall and tilted pin hole immediately loaded implants (TTPHIL) technique for maxillary arch rehabilitation. International Journal of Research and Review, 5: 104-110.
24. Venkat Nag P, Sarika P, Khan R, Bhagwatkar T. (2018). Immediate implantation and loading in just two days with TTPHIL technique using CAD/CAM Prosthesis. International Journal of Applied Dental Sciences, 4(3): 209-213.
25. Venkat Ratna Nag, Sarika P, Bhagwatkar T, Dhara V. Tilted Implant Placement for Rehabilitation of Severe Atrophic Maxilla Supported by Finite Element Analysis. The Journal of Implant & Advanced Clinical Dentistry 2019; 11(1): 14-26.
26. Penarrocha O D, Candel M E, Ata A J, et al. Rehabilitation of the Atrophic Maxilla with Tilted Implants: Review of the Literature. Journal of Oral Implantology 2013; 38(5) 625-632.
27. Andrea H, Wook-Jin S, Ryan W. Comparison of initial implant stability of implants placed using bicortical fixation, Indirect sinus elevation, and unicortical fixation. Int J of Oral Max Implants 2016.31; 2: 459-468.
28. Bruno Salles S M, Camila de Andrade L, Plinio Mendes S. Biomechanical evaluation of subcrestal dental implants with different bone anchorages. Braz Oral Res., (São Paulo) 2014; 28(1): 1-7.
29. Singh A V, Singh S. Tilted Implant Concept for Full Mouth Immediate Loading Restoration. Int J Oral Implantol Clin Res 2014; 5(1): 12-23.
30. Nag PVR, Sarika P, Bhagwatkar T, Dhara V. Pterygoid Implant: Option for Rehabilitation of the Atrophic Posterior Maxilla. Int J Contemp Dent Med Rev vol.2019, Article ID: 011218, 2019.

© 2019 Global Journals