Volume 20 Issue 39
Originally issued as F7

Global Journal of Medical Research: F
Diseases
Volume 20 Issue 7 Version 1.0 Year 2020
Type: Double Blind Peer Reviewed International Research Journal
Publisher: Global Journals Inc. (USA)
Online ISSN: 2249-4618 & Print ISSN: 0975-5888

Paracetamol May Increase Cardiac Congenital Malformations Risk in Prediabetic Pregnancy Women

By Dr. Juan Ariel Jara-Guerrero

Medicine Scholl. Complutense University

Abstract- Hepatic fat and abdominal adiposity in early pregnancy promotes impaired glucose homeostasis in mid-pregnancy (De Souza, 2016) and paracetamol overuse predisposes to liver fat. Hyperglycemia induces apoptosis in myocardium, and an amount evidence have demonstrated an increased risk of congenital abnormalities with gestational diabetes.

Acetaminophen overdose is the most often cause of acute liver injury and obese women are in particular risk, because is able to induce mitochondrial oxidative stress (Rousar, 2012). Acetaminophen (Paracetamol) usual high doses decreased embryonic hepatic antioxidant systems as glutathione, that play a vital role in the detoxification of exogenous and endogenous chemicals (Mitchell, 1973, Ishibashi, 1997, Beck, 2001, Rousar, 2012, rev).

The apparent safety of Paracetamol drug, a useful analgesic only (with no anti-inflammatory properties) (Neto, 2004; Hamlyn, 1978, Ucheya, 2006, Bessems, 2001) is compromized by its widespread and extensive chronic use, particularly in Peruvian population. Paracetamol though considered safe at a considerable low dose, especially in women, could cause kidney derangement and cardiac malformations during pregnant state (Ucheya, 2006), if the drug is ingested in the first trimester. Major congenital malformations, including those affecting the cardiovascular system, remain the leading cause of mortality and morbidity in infants of diabetic mothers (Pinter, 2001). Thus, there is an overcome potential maternal acetaminophen (paracetamol) toxicity (Horowitz, 1997).

GJMR-F Classification: NLMC Code: WG 220

PARACETAMOLMAYINCREASECARDIACCONGENITALMALFORMATIONSRISKINPREDIABETICPREGNANCYWOMEN

Strictly as per the compliance and regulations of:

© 2020. Dr. Juan Ariel Jara-Guerrero. This is a research/review paper, distributed under the terms of the Creative Commons Attribution-Noncommercial 3.0 Unported License http://creativecommons.org/licenses/by-nc/ 3.0/), permitting all non-commercial use, distribution, and reproduction in any medium, provided the original work is properly cited.

Paracetamol May Increase Cardiac Congenital Malformations Risk in Prediabetic Pregnancy Women

Dr. Juan Ariel Jara-Guerrero

Abstract- Hepatic fat and abdominal adiposity in early pregnancy promotes impaired glucose homeostasis in mid-pregnancy (De Souza, 2016) and paracetamol overuse predisposes to liver fat. Hyperglycemia induces apoptosis in myocardium, and an amount evidence have demonstrated an increased risk of congenital abnormalities with gestational diabetes.

Acetaminophen overdose is the most often cause of acute liver injury and obese women are in particular risk, because is able to induce mitochondrial oxidative stress (Rousar, 2012). Acetaminophen (Paracetamol) usual high doses decreased embryonic hepatic antioxidant systems as glutathione, that play a vital role in the detoxification of exogenous and endogenous chemicals (Mitchell, 1973, Ishibashi, 1997, Beck, 2001, Rousar, 2012, rev).

The apparent safety of Paracetamol drug, a useful analgesic only (with no anti-inflammatory properties) (Neto, 2004; Hamlyn, 1978, Ucheya, 2006, Bessems, 2001) is compromized by its widespread and extensive chronic use, particularly in Peruvian population. Paracetamol though considered safe at a considerable low dose, especially in women, could cause kidney derangement and cardiac malformations during pregnant state (Ucheya, 2006), if the drug is ingested in the first trimester. Major congenital malformations, including those affecting the cardiovascular system, remain the leading cause of mortality and morbidity in infants of diabetic mothers (Pinter, 2001). Thus, there is an overcome potential maternal acetaminophen (paracetamol) toxicity (Horowitz, 1997).

I. Hyperglycemia and Cardiac Malformations

Prospective and retrospective cohort studies have demonstrated an increased risk of congenital abnormalities with gestational diabetes. This observation is related to the inclusion of women with unrecognized type 2 diabetes (Hoet, 1962, López-Quijada, 1974, Navarrete, 1970, Allen, 2007, Pasarella, 2013). It is known that glucose-induced malformations in animal models, including retarded growth and abnormal heart development, depend on the developmental stage of hyperglycemic exposure and glucose concentration (Roest, 2007, Scott-Drechsel, 2013).

Author: Experimental Endocrinology and Physiology Department, Medicine Scholl. Complutense University, Madrid.
e-mail: poetalobo60@gmail.com

Diabetes mellitus in pregnancy is associated with an increased incidence of various congenital anomalies that occur during organogenesis. Pregnancy in itself is diabetogenic as a result of an augmented physiological insulin resistance (Wu, 1996; Jara, 2001). Thus, pregestational diabetes is a major risk factor of congenital heart defects (CHD).

Animal and human confirmed a role for the diabetic state and elevated insulin resistance in inducing congenital fetal malformations, and free radicals excess have been compromised by week 8 of gestation. In this way, the major congenital malformations associated with non-physiological insulin resistance in pregnancy are caudal regression and renal, cardiac and central nervous system abnormalities (Ryan, 1998, rev).

Pregestational diabetes resulted in CHDs in 58% of the offspring, including ventricular septal defect (VSD), atrial septal defect (ASD), atrioventricular septal defects (AVSD), transposition of great arteries (TGA), double outlet right ventricle (DORV) and tetralogy of Fallot (TOF). Treatment with N-acetylcysteine (NAC) in drinking water in pre-gestational diabetic mice completely eliminated the incidence of AVSD, TGA, TOF and significantly diminished the incidence of ASD and VSD (Moazzen, 2014). It has been demonstrated that maternal hyperglycemia caused a dilation of late-gestation fetal ventricular chambers, a reduction of total ventricular myocardial area, and an increase in transversal ascending thoracic aortic area (Gutierrez, 2007).

Intensive care of the pregnant mother with diabetes has dramatically decreased the incidence of diabetic embryonic malformations and clinical reports seem to link facial malformations to an increased incidence of sacral-caudal malformations in human diabetic pregnancy (Eriksson, 1985, Pinter, 1986). Indeed, congenital malformations in experimental diabetes can be prevented by antioxidants, in vivo (Simán, 1997, Reece, 1997) that replace the glutathione depletion in mother. Improving the embryonic capability to scavenge oxygen radicals, either by increasing superoxide dismutase activity or by supplying a rate-limiting precursor (N-acetylcysteine) for the enhanced synthesis of reduced glutathione, blocks the embryonic dysmorphogenesis (Wentzel, 1997).

© 2020 Global Journals

Hyperglycemia may increase adult heart myocardial apoptosis (Gutierrez, 2009). There has been extensive evidence: maternal hyperglycemia is an inducer of birth defects that include a high incidence of cardiovascular malformations (Reece, 1997; Gutierrez, 2009).

II. Maternal Diabetes Mellitus may Cause Teratogenesis

Maternal diabetes mellitus is associated with increased teratogenesis risks, which can occur in pregestational type 1 and type 2 diabetes. Cardiac defects and neural tube defects are the most common malformations observed in fetuses of pre-gestational diabetic mothers (Corrigan, 2009). In addition, in non-diabetic populations, there is several reports that support the powerful association between maternal obesity and risk of congenital heart defects, this association was present not only for congenital heart defects as a group, but for numerous individual defects (Mills, 2010).

The significant correlation between maternal hyperglycemia in early pregnancy and the risk of fetal abnormalities in pregnant women with diabetes mellitus, particularly type 1 (Todorova, 2005) and non-known-type 2 diabetes mellitus is in line with several reports that demonstrated that fetal abnormalities are strongly associated with higher levels of glycosylated Hemoglobin in the first trimester of pregnancy. (Todorova, 2005), and this elevation in A-1c Hemoglobin has a direct correlation with hepatic glutathione levels (Sakamaki, 1999).

In this way, maternal hyperglycemia is thought to be the primary teratogen, causing particularly adverse effects on cardiovascular development. (Corrigan, 2009). Fetal cardiac defects are associated with raised maternal glycosylated hemoglobin levels up to five times more likely in infants of mothers with pre-gestational diabetes compared with those without diabetes: this cardiac defects include transposition of the great arteries, mitral and pulmonary atresia, double outlet of the right ventricle, tetralogy of Fallot, and fetal cardiomyopathy (Corrigan, 2009).

Despite improvements in prenatal care, the incidence of congenital malformations in diabetic pregnancies is still 3-4 times higher than in normal pregnancies. These defects could be attributed to alterations of intrauterine environment due to disorder of the maternal metabolism (Giavini, 1991). Glutathione (GSH), a tripeptide implicated in cellular protection against reactive oxygen species, is involved in diabetes-related embryotoxicity Interestingly, *teratogenicity of maternal serum in diabetic pregnancy is not mediated exclusively by increased concentrations of glucose and ketone bodies* as its demonstrated by Wentzel et.al (Wentzel, 1996, Wentzel, 2008). Both genetic background and obesity influence the severity of fetal abnormalities in animals (Corrigan, 2009).

Previous studies in vivo and in vitro have suggested that the oxidative metabolism of the embryo may have a role in the teratogenicity of diabetic pregnancy. In particular, the production of reactive oxygen species by the embryonic mitochondria has been implicated in the teratological process. The induction of congenital malformations by the diabetic milieu occurs during the early embryonic development (Yang, 1995). *Hyperglycemia during organogenesis has a primary deleterious effect on yolk sac function with resultant embryopathy* (Pinter, 1986).

Diabetes-induced malformations have been often related, both in vivo and in vitro studies, to morphological and physiological alterations of the yolk sac, the principal organ for the passage of nutrients from the mother to the rodent embryo (Giabini, 1993). The embryos explanted from diabetic mothers showed signs of developmental retardation and 16% were morphologically abnormal (Menegola, 1996). In addition, *reduction in embryonic GSH could reduce the protection against the oxidative stress condition described in diabetic pathology.*

Norbert Freinkel suggested that the altered fuel mixture offered to the growing conceptus may be the key to most of the changes in the embryogenesis of diabetic pregnancy. He coined the term fuel-mediated teratogénesis. In vitro (Eriksson, 1991) and in vivo, a high glucose concentration causes embryonic dysmorphogenesis by generation of free oxygen radicals. An enhanced production of such radicals in embryonic tissues is directly related to an increased risk of congenital malformations in occult diabetic pregnancy.

In this concept, an abnormal handling of reactive oxygen species (ROS) is involved in diabetes-induced dysmorphogenesis in vivo. Indeed, an increased concentration of lipid peroxides, indicating damage caused by ROS, was found in fetuses of diabetes rats. In addition, embryos of diabetic rats had low concentrations of the antioxidant vitamin E compared to control embryos (Simán, 1997 a, b). On the whole, in vivo and in vitro experiments indicate that hyperglycemia itself is not a major factor in producing diabetic embryopathies (Giavini, 1993), but several depletion of tissues glutathione does it. In this way, anti-teratogenic effects of supplementation of N-acetylcysteine in vitro has been demonstrated: N-acetylcysteine limits the teratogenicity of glucose (Wentzel, 1997, Roes, 2007).

There is a solid experimental, clinical and epidemiological evidence that support that increased glucose levels caused embryonic mal development in both normal and diabetic serum. Moreover, despite normalization of the diabetic state, the serum from the insulin-treated diabetic rats caused more growth

© 2020 Global Journals

retardation than the nondiabetic control serum (Wentze, 1996). Therefore, the pathogenesis of fetal malformations in diabetic pregnancy is multifactorial. Thus, maintaining metabolites from all nutrient classes at a normal level may be important in preventing adverse fetal outcome (Eriksoon, 1993; Styrud, 1995)

In the second part of gestation, *the rate of heart myocardial apoptosis may increase in adult mice under a hyperglycemic environment* (Frustaci, 2000, Fiordaliso, 2001, Cai, 2002), and its observed both increased apoptosis and necrosis in myocytes, endothelial cells and fibroblasts of the human adult diabetic heart. In the fetal context, Gutierrez et al. detected ventricular chamber dilation and myocardial reduction in late gestation fetal hearts, collected from hyperglycemic pregnant CD-1 mouse dams (Gutierrez, 2007; Gutierrez, 2009).

III. Paracetamol has a Potential Teratogenic Agent

Glutathione, severely depleted in in vitro and in vivo models of diabetes (Trocino, 1995, Moazzen, 2014) is probably, the main causality factor in cardiomyocyte apoptosis (Ghosh, 2005), in addition the hyperglycemia, and both of them potentially occur, even, at usual high-doses of paracetamol.

Teratogenic potential of diabetes may consist of two components; one associated with 'direct' teratogens perturbing developmental processes in embryos at a 'critical moment' in organogenesis, and a second component, associated with a direct or indirect influence of the diabetic environment on developmental processes in the preimplantation embryos. Thus, there is a threshold glucose level associated with a clear increase of the number of litters with severely malformed fetuses in diabetics animals (Torchinsky, 1997): maternal hyperglycemia altered morphology of the late-gestation fetal mouse heart (Gutierrez, 2007).

Mitochondrial alterations produced by oxidative stress have been described in embryos developing in a diabetic environment. Interestingly, its been demonstrated recently that *Paracetamol in normal doses may be able to induce mitochondrial oxidative stress* (Rousar, 2012). In this regard, oxygen radicals-scavenging enzymes potentially reduce the embryotoxic effects induced by diabetic conditions (Menegola, 1996).

Acetaminophen overdose is the most often cause of acute liver injury. The toxic mechanism is linked to formation of an active metabolite that reacts with glutathione generating acetaminophen-glutathione conjugate (APAP-SG). This compound has been recognized to be non-toxic generally. Recent studies showed, however, that APAP-SG could possess a toxic effect too (Rousar, 2012), particularly in visceral / abdominal obese women.

Liver glutathione stores become depleted with paracetamol (Kaneo, 1994) overdoses –chronic use- so that the liver is unable to deactivate the toxic metabolites. In fact, the paracetamol induced renal damage in pregnant women results from a mechanism similar to that which is responsible for hepatotoxicity (Sule, 2006); this mechanism is probably participate in cardiac malformations in an early pregnant state.

In this context, the worldwide use of paracetamol as a household analgesic, including during pregnancy may be dangerous: in fact, fetal tissues (and maternal) can be adversely affected by paracetamol (Neto, 2004), and are potentially dangerous in the presence of chronic abdominal obesity (pathological insulin resistance) (Jara, 2001) where liver and tissues antioxidant glutathione (Reed, 1984) is reduced.

Prevention: The Exosomes in Pregnancy Cardiac Malformations

Animal models have been used to study the expression patterns of many genes that contribute to structural defects in the heart, although <10% of these underlie congenital cardiac defects in humans (Andersen, 2014, Richards, 2010, Govindsamy, 2018). Intrauterine under- or overnutrition alters offspring cardiac structure and function.

The expression of cardiac-specific genes is likely altered reflecting impaired cardiac insulin signalling that contributes to cardiac insulin resistance, that often precedes cardiovascular disease (Govindsamy, 2018), this hormonal event explains the fact that *congenital malformations occur despite good glycemic control* (Mill, 1988; Simán, 1997), thereby confirming a role for reactive oxygen species ROS and inflammatory and oxidant environment (Simán, 1997), or a lack of antioxidant protection enough, as glutathione, Vitamin E and Selenium.

Enhancing synthesis of reduced glutathione blocks the embryonic dysmorphogenesis (Wentzel, 1997), but not in cardiac malformations, because fetal heart was found to be hypertrophic (Simán, 1997) (resorption rate in fetal organs tended to be decreased with the increased dosage of vitamin E). Then, maternal administration of vitamin E can prevent congenital malformations in mid and late pregnancy, not in the early pregnancy. In comparison, Selenium may offer other additional advantages: its powerful antioxidant properties preserve reduced glutathione because its role in the major intracellular antioxidant enzyme the glutathione peroxidase (Takahashi, 1986). But Peruvian mothers don´t consume diary selenium nor vitamin D.

In addition, it is been demonstrated that acute glutathione depletion causes severe hypertension in normal rats (Vaziri, 2000): Since *Paracetamol causes physiological reduction of glutathione, we don´t surprise that this drug may increase blood pressure in advanced insulin resistant humans* (Sudano, 2010). Therefore,

© 2020 Global Journals

pregnant women must be caution before taking this drug, but never without medical indication.

Placental cells can communicate with maternal tissues to regulate their biological function via extracellular vesicles with immune responses: the exosomes (Salomon, 2017, rev). *Acute hyperglycemia in gestation may disturb exosomes signaling (Rice, 2015), and may promotes severe malformations that occurs during organogenesis* - completed by sixth week after conception- and the critical period for malformations is almost over by the time pregnancy becomes clinically apparent. At this time, the placenta releases exosomes into the maternal circulation - Exosomes are specifically package with signaling molecules, including protein, messenger RNA, microRNA, and noncoding RNA- (Mitchell, 2015, rev), and *elevated maternal exosomes in gestational diabetes strikingly increased the risk of congenital heart defect* (Nair, 2018; Shi, 2017), and these occurs at high amounts even in pregestational maternal diabetes that induces congenital heart defects (Konečná, 2019; Zhong, 2018, rev).

Exosomes released from placental cells and adipose cells have been found to be regulated by oxygen tension and glucose concentration, and abdominal obese women release an excess of this extracellular vesicles that stimulate cytokine release from endothelial cells that increase hepatic and systemic inflammation; a lot of these events disturb placental health and fetal organogenesis in the presence of glucose intolerance exacerbate in paracetamol women consumers.

In addition ro paracetamol-side-effects at normal doses, a recent investigation has found transcriptomic changes in full-genome human miRNA expression and immune modulating effects and oxidative stress responses to paracetamol even at low doses (Jetten, 2012). Because it is very frequent that organogenesis is completed before women recognize that they are pregnant, the precounseling and strict planning of pregnancy, even in prediabetic women or gestational diabetes, become an urgent need.

IV. Conclusions

Glycolysis regulates cardiometabolism behavior during cardiac wall morphogenesis, and any disturb in metabolism pathway may alter ventricular wall morphogenesis and cause congenital cardiac malformations (Fukuda, 2019). Furthemore, *if a reduction of glutathione levels in cells has been found to increase the risks for diseases and poisoning* (Honda, 2017), *Paracetamol, is potentially dangerous in pregnant women*.

Pre-gestational maternal diabetes is associated with strong teratogenic effects on the kidney, urinary tract, and heart, and strongly associated with multiple congenital abnormalities. Pre-conception recognition of women at high risk for type 2 diabetes and optimal glycemic control may reduce the risk of congenital anomalies. A healthy diet and regular exercise (Nielsen, 2005, Allen, 2007, rev) and reduction in paracetamol-toxicity in a subclinical way, may help optimize pre-pregnancy weight and reduce the risk of congenital anomalies. Paracetamol may increase the risk of cryptorchidism and asthma during childhood as well as preeclampsia, maternal phlebothrombosis and pulmonary embolism (Burdan, 2012) as its recently reported.

In the presence of established diabetes, It is must be stress the importance of a strict metabolic control, started well before conception, to prevent excess rates of congenital malformation, and the intensive insulin therapy must be considered as an first option in this regard (Fuhrmann, 1984). Sustained hyperglycemia reduced endocardial and myocardial cell proliferation in the outflow tract of heart and lead to congenital heart malformations (Scott-Drechsel, 2013, Roest, 2006).

In diabetic women who is thinking to pregnant, an optimal metabolic control must been established (Todorova, 2005), and the danger of paracetamol use must be informed, even if the fact that most pregnancies are not recognized clinically until ≥2 weeks after conception, thus, many pregnant women are unaware of both their diabetes status during early pregnancy and the increased risk of morbidity and mortality that prediabetes or occult diabetes has on their unborn child (Roman, 2011 rev, Scott-Drechsel, 2013).

Acetaminophen (Paracetamol) is one of the most common causes of poisoning worldwide, in particular in the patients with low amount of the hepatic glutathione (Burdan, 2012, rev.), that is, insulin resistant and diabetic patients.

© 2020 Global Journals

Abnormal Insulin Resistance in pregnancy due to excess of adipose tissue accumulation (Abdominal obesity) is associated with increased exosomes and inflammation in placental fetal unit (Jayabalan, 2017, rev): Insulin Resistance is worse with Paracetamol ingestion

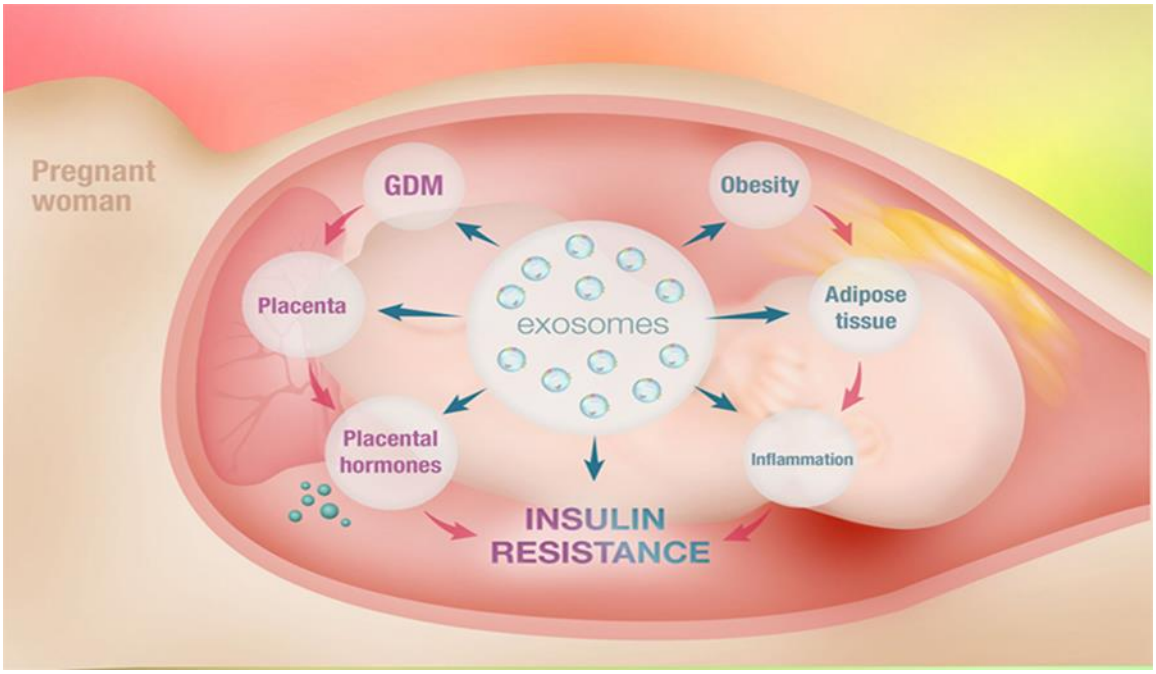

Figure 1

Paracetamol ingestion even at normal doses causes glutathione depletion in maternal liver that translate to placental and fetus, and, in gestational diabetes and pre-diabetic state induce a significant depletion in antioxidant system and cellular apoptosis in development of tissues, that promotes in the early pregnancy, cardiac malformations in offspring (Sakamaki, 1999)

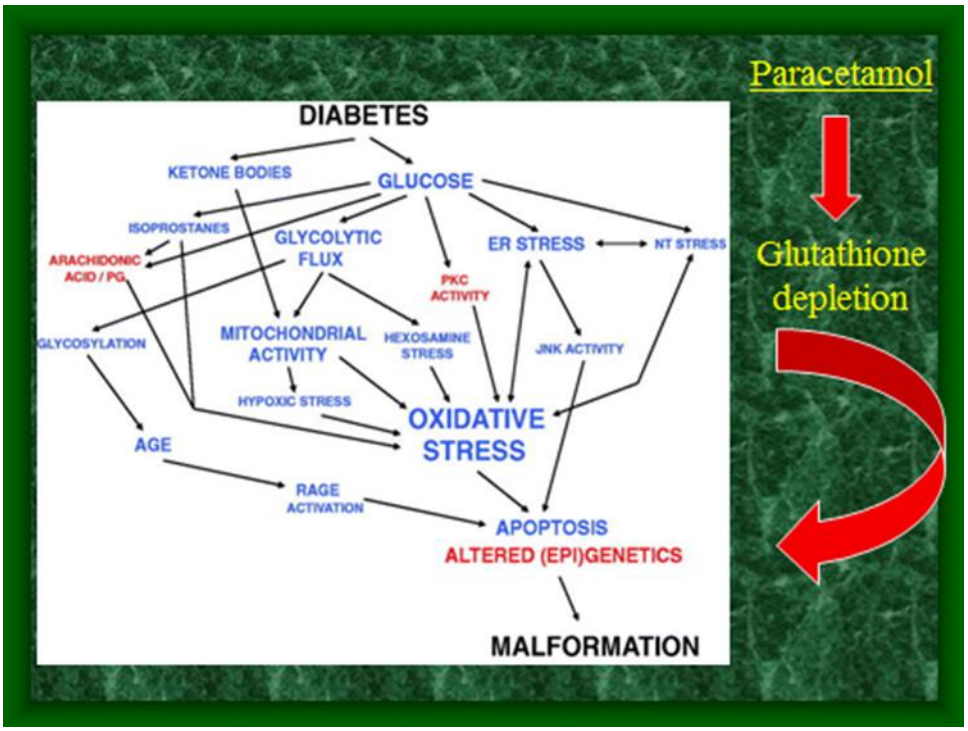

Figure 2

© 2020 Global Journals

References Références Referencias

1. Adam S, Elfeky O, Kinhal V, Dutta S, Lai A, Jayabalan N, Nuzhat Z, Palma C, Rice GE, Salomon C Review: Fetal-maternal communication via extracellular vesicles - Implications for complications of pregnancies. Placenta. 2017 Jun;54:83-88
2. Allen VM, Armson BA, Wilson RD, Allen VM, Blight C, Gagnon A, Johnson JA, Langlois S, Summers A, Wyatt P, Farine D, Armson BA, Crane J, Delisle MF,Keenan-Lindsay L, Morin V, Schneider CE, Van Aerde J, Society of Obstetricians and Gynecologists of Canada Teratogenicity associated with pre-existing and gestational diabetes J Obstet Gynaecol Can. 2007 Nov; 29(11):927-44
3. Andersen TA, Troelsen Kde L, Larsen LA. Of mice and men: molecular genetics of congenital heart disease Cell Mol Life Sci. 2014 Apr; 71(8):1327-52.
4. Baker L, Egler JM, Klein SH, Goldman AS. Meticulous control of diabetes during organogenesis prevents congenital lumbosacral defects in rats Diabetes. 1981 Nov; 30(11):955-9.
5. Bauer AZ, Kriebel D. Prenatal and perinatal analgesic exposure and autism: an ecological link Environ Health. 2013 May 9; 12:41. doi: 10.1186/1476-069X-12-41.
6. Beck MJ, McLellan C, Lightle RL, Philbert MA, Harris C. Spatial glutathione and cysteine distribution and chemical modulation in the early organogenesis-stage rat conceptus in utero Toxicol Sci. 2001 Jul;62(1):92-102.
7. Bessems JG, Vermeulen NP. Paracetamol (acetaminophen)-induced toxicity: molecular and biochemical mechanisms, analogues and protective approaches Crit Rev Toxicol. 2001 Jan; 31(1): 55-138.
8. Burdan F, Starosławska E, Szumiło J Prenatal tolerability of acetaminophen and other over-the-counter non-selective cyclooxygenase inhibitors Pharmacol Rep. 2012;64(3):521-7.
9. Cai L, Li W, Wang G, Guo L, Jiang Y, Kang YJ. Hyperglycemia-induced apoptosis in mouse myocardium: mitochondrial cytochrome C-mediated caspase-3 activation pathway Diabetes. 2002 Jun; 51(6):1938-48.
10. Carvalho NR, da Rosa EF[1], da Silva MH[1], Tassi CC[1], Dalla Corte CL[1], Carbajo-Pescador S[2], Mauriz JL[2], González-Gallego J[2], Soares FA New therapeutic approach: diphenyl diselenide reduces mitochondrial dysfunction in acetaminophen-induced acute liver failure PLoS One. 2013 Dec 11;8(12):e81961
11. Corrigan N, Brazil DP, McAuliffe F Fetal cardiac effects of maternal hyperglycemia during pregnancy Birth Defects Res A Clin Mol Teratol. 2009 Jun;85(6):523-30
12. da Silva MH, da Rosa EJ, de Carvalho NR, Dobrachinski F, da Rocha JB, Mauriz JL, González-Gallego J, Soares FA. Acute brain damage induced by acetaminophen in mice: effect of diphenyl diselenide on oxidative stress and mitochondrial dysfunction Neurotox Res. 2012 Apr; 21(3):334-44. doi: 10.1007/s12640-011-9288-1. Epub 2011 Nov 12.
13. De Lorgeril M, Salem P, Accominotti M, Cadau M, Steghens JP, Boucher F, De Leires J Dietary and Blood Antioxidants in Patients with Chronic Heart Failure: Insigths into the Potential Importance of Selenium in Heart Failure European Journal of Heart Failure 2001; 3: 661-669
14. De Souza LR, Berger H, Retnakaran R, Vlachou PA, Maguire JL, Nathens AB, Connelly PW, Ray JG Hepatic fat and abdominal adiposity in early pregnancy together predict impaired glucose homeostasis in mid-pregnancy. Nutr Diabetes. 2016 Sep 19; 6(9):e229.
15. Eriksson U, Dahlström E, Larsson KS, Hellerström C. Increased incidence of congenital malformations in the offspring of diabetic rats and their prevention by maternal insulin therapy Diabetes. 1982 Jan; 31(1):1-6
16. Eriksson UJ, Styrud J. Congenital malformations in diabetic pregnancy: the clinical relevance of experimental animal studies Acta Paediatr Scand Suppl. 1985; 320:72-8.
17. Eriksson UJ, Wentzel P The status of diabetic embryopathy. Ups J Med Sci. 2016 May; 121(2):96-112
18. Farquhar H, Stewart A, Mitchell E, Crane J, Eyers S, Weatherall M, Beasley R The role of paracetamol in the pathogenesis of asthma Clin Exp Allergy. 2010 Jan;40(1):32-41
19. Fine EL, Horal M, Chang TI, Fortin G, Loeken MR. Evidence that elevated glucose causes altered gene expression, apoptosis, and neural tube defects in a mouse model of diabetic pregnancy Diabetes. 1999 Dec; 48(12):2454-62.
20. Fiordaliso F, Leri A, Cesselli D, Limana F, Safai B, Nadal-Ginard B, Anversa P, Kajstura J Hyperglycemia activates p53 and p53-regulated genes leading to myocyte cell death Diabetes. 2001 Oct; 50(10):2363-75.
21. Frustaci A, Kajstura J, Chimenti C, Jakoniuk I, Leri A, Maseri A, Nadal-Ginard B, Anversa P. Myocardial cell death in human diabetes Circ Res. 2000 Dec 8;87(12):1123-32.
22. Fuhrmann K, Reiher H, Semmler K, Glöckner E. The effect of intensified conventional insulin therapy before and during pregnancy on the malformation rate in offspring of diabetic mothers Exp Clin Endocrinol. 1984 Apr; 83(2):173-7.
23. Fukuda R, Aharonov A, Ong YT, Stone OA, El-Brolosy M, Maischein HM, Potente M, Tzahor E,

© 2020 Global Journals

Stainier DY Metabolic modulation regulates cardiac wall morphogenesis in zebrafish. Elife. 2019 Dec 23; 8. pii: e50161
24. Giavini E, Broccia ML, Prati M, Domenico Roversi G. Diet composition modifies embryotoxic effects induced by experimental diabetes in rats Biol Neonate. 1991; 59(5):278-86.
25. Giavini E. Diabetes in pregnancy: experimental aspects Ann Ist Super Sanita. 1993; 29(1):27-34.
26. Ghosh S, Pulinilkunnil T, Yuen G, Kewalramani G, An D, Qi D, Abrahani A, Rodrigues B Cardiomyocyte apoptosis induced by short-term diabetes requires mitochondrial GSH depletion Am J Physiol Heart Circ Physiol. 2005 Aug; 289(2):H768-76
27. Govindsamy A, Naidoo S, Cerf ME Cardiac Development and Transcription Factors: Insulin Signalling, Insulin Resistance, and Intrauterine Nutritional Programming of Cardiovascular Disease J Nutr Metab. 2018 Feb 1;2018:8547976
28. Gutierrez JC, Hrubec TC, Prater MR, Smith BJ, Freeman LE, Holladay SD. Aortic and ventricular dilation and myocardial reduction in gestation day 17 ICR mouse fetuses of diabetic mothers Birth Defects Res A Clin Mol Teratol. 2007 Jun; 79(6):459-64.
29. Gutierrez JC, Prater MR, Smith BJ, Freeman LE, Mallela MK, Holladay SD Late-gestation ventricular myocardial reduction in fetuses of hyperglycemic CD1 mice is associated with increased apoptosis Birth Defects Res B Dev Reprod Toxicol. 2009 Oct; 86(5):409-15
30. Hamlyn AN, Douglas AP, James O. The spectrum of paracetamol (acetaminophen) overdose: clinical and epidemiological studies Postgrad Med J. 1978 Jun; 54(632):400-4.
31. HOET JP, HOET JJ, GOMMERS A, TREMOUROUX-WATTIEZ M. Prediabetes and congenital abnormalities of the heart Rev Fr Gynecol Obstet. 1962 Apr; 57:233-47.
32. Honda Y1, Kessoku T1, Sumida Y2, Kobayashi T1, Kato T1, Ogawa Y1, Tomeno W1, Imajo K1, Fujita K1, Yoneda M1, Kataoka K3, Taguri M3, Yamanaka T3, Seko Y4, Tanaka S5, Saito S1, Ono M6, Oeda S7, Eguchi Y7, Aoi W8, Sato K9, Itoh Y4, Nakajima A Efficacy of glutathione for the treatment of nonalcoholic fatty liver disease: an open-label, single-arm, multicenter, pilot study. BMC Gastroenterol. 2017 Aug 8; 17(1):96. doi: 10.1186/s12876-017-0652-3.
33. Horowitz RS, Dart RS, Jarvie DR, Bearer CF, Gupta U Placental Transfer of N-Acetylcysteine Following Human Maternal Acetaminophen Toxicity *J Toxicol Clinic Toxicol* 1997; 35: 447-451
34. Ishibashi M, Akazawa S, Sakamaki H, Matsumoto K, Yamasaki H, Yamaguchi Y, Goto S, Urata Y, Kondo T, Nagataki S. Oxygen-induced embryopathy and the significance of glutathione-dependent antioxidant system in the rat embryo during early organogenesis. Free Radic Biol Med. 1997; 22(3):447-54.
35. Jayabalan N, Nair S, Nuzhat Z, Rice GE, Zuñiga FA, Sobrevia L, Leiva A, Sanhueza C, Gutiérrez JA, Lappas M, Freeman DJ, Salomon C Cross Talk between Adipose Tissue and Placenta in Obese and Gestational Diabetes Mellitus Pregnancies via Exosomes. Front Endocrinol (Lausanne). 2017 Sep 27;8:239
36. Jetten MJ, Gaj S, Ruiz-Aracama A, de Kok TM, van Delft JH, Lommen A, van Someren EP, Jennen DG, Claessen SM, Peijnenburg AA, Stierum RH, Kleinjans JC Omics analysis of low dose acetaminophen intake demonstrates novel response pathways in humans Toxicol Appl Pharmacol 2012, 259:320-328
37. Kaneo Y , Ogawa K, Tanaka T, Fujihara Y, Iguchi S A protective effect of glutathione-dextran macromolecular conjugates on acetaminophen-induced hepatotoxicity dependent on molecular size Biol Pharm Bull. 1994 Oct; 17(10):1379-84.
38. Konečná B, Tóthová L, Repiská G Exosom es-Associated DNA-New Marker in Pregnancy Complications? Int J Mol Sci. 2019 Jun 13; 20(12). pii: E2890.
39. Larson AM, Polson J, Fontana RJ, Davern TJ, Lalani E, Hynan LS, Reisch JS, Schiødt FV, Ostapowicz G, Shakil AO, Lee WM; Acute Liver Failure Study Group Acetaminophen-induced acute liver failure: results of a United States multicenter, prospective study Hepatology. 2005 Dec;42(6):1364-72
40. Lawson TB, Scott-Drechsel DE, Chivukula VK, Rugonyi S, Thornburg KL, Hinds MT Hyperglycemia Alters the Structure and Hemodynamics of the Developing Embryonic Heart. J Cardiovasc Dev Dis. 2018 Feb 12; 5(1). pii: E13
41. Lee AT, Reis D, Eriksson UJ. Hyperglycemia-induced embryonic dysmorphogenesis correlates with genomic DNA mutation frequency in vitro and in vivo. Diabetes. 1999 Feb; 48(2):371-6.
42. Lisowski LA, Verheijen PM, Copel JA, Kleinman CS, Wassink S, Visser GH, Meijboom EJ Congenital heart disease in pregnancies complicated by maternal diabetes mellitus. An international clinical collaboration, literature review, and meta-analysis Herz. 2010 Jan;35(1):19-26
43. López-Quijada C, Chiva Carrion L. Maternal disorders of carbohydrate metabolism in cases of cardiac embryopathy. Acta Diabetol Lat. 1974 Mar-Apr; 11(2):140-8.
44. Menegola E, Broccia ML, Prati M, Ricolfi R, Giavini E. Glutathione status in diabetes-induced embryopathies Biol Neonate. 1996; 69(5):293-7.
45. Mill JL, Knopp RH, Simpson JL, Jovanovic-Peterson L, Metzger BE, Holmes LB, Aarons JH, Brown Z, Reed GF, Bieber FR, Van Allen M, Holzman I, et al.

© 2020 Global Journals

NATIONAL INSTITUTE OF CHILD HEALTH AND HUMAN DEVELOPMENT DIABETES IN EARLY PREGNANCY STUDY GROUP: Lack of relation of increased malformation rates in infants of diabetic mothers to glycemic control during organogenesis *N Engl J Med 1988*; 318: 671-676.

46. Mills JL, Troendle J, Conley MR, Carter T, Druschel CM. Maternal obesity and congenital heart defects: a population-based study Am J Clin Nutr. 2010 Jun;91(6):1543-9.
47. Mitchell JR, Jollow DJ, Potter WZ, Gillette JR, Brodie BB Acetaminophen-induced hepatic necrosis. IV. Protective role of glutathione J Pharmacol Exp Ther 1973; 187: 211-217.
48. Mitchell MD, Peiris HN, Kobayashi M, Koh YQ, Duncombe G, Illanes SE, Rice GE, Salomon C Placental exosomes in normal and complicated pregnancy. Am J Obstet Gynecol. 2015 Oct;213(4 Suppl):S173-81.
49. Moazzen H, Lu X, Ma NL, Velenosi TJ, Urquhart BL, Wisse LJ, Groot AC, Feng Q. N-Acetylcysteine prevents congenital heart defects induced by pregestational diabetes Cardiovasc Diabetol. 2014 Feb 18; 13(1):46.
50. Nair S, Jayabalan N, Guanzon D, Palma C, Scholz-Romero K, Elfeky O, Zuñiga F, Ormazabal V, Diaz E, Rice GE, Duncombe G, Jansson T, McIntyre HD, Lappas M, Salomon C Human placental exosomes in gestational diabetes mellitus carry a specific set of miRNAs associated with skeletal muscle insulin sensitivity. Clin Sci (Lon d). 2018 Nov 29; 132(22):2451-2467.
51. Navarrete VN, Rojas CE, Alger CR, Paniagua HE. Subsequent diabetes in mothers delivered of a malformed infant. Lancet. 1970 Nov 14; 2(7681):993-5.
52. Neto JA, Oliveira-Filho RM, Simões MJ, Soares JM Jr, Kulay L Jr. Long-term acetaminophen (paracetamol) treatment causes liver and kidney ultra-structural changes during rat pregnancy Clin Exp Obstet Gynecol. 2004;31(3):221-4.
53. Nielsen GL, Nørgard B, Puho E, Rothman KJ, Sørensen HT, Czeizel AE. Risk of specific congenital abnormalities in offspring of women with diabetes Diabet Med. 2005 Jun; 22(6):693-6.
54. Passarella G, Trifirò G, Gasparetto M, Moreolo GS, Milanesi O. Disorders in glucidic metabolism and congenital heart diseases: detection and prevention Pediatr Cardiol. 2013 Apr;34(4):931-7.
55. Paolisso G, D`´Amore A, Giugliano D, Ceriello A, Varricchio M, and D¨ Onofrio F Pharmacologic doses of vitamin E improve insulin action in healthy subjects and non-insulin-dependent diabetic patients Am J Clin Nutr 1993; 57: 650-656.
56. Pinter E, Reece EA, Leranth CZ, Sanyal MK, Hobbins JC, Mahoney MJ, Naftolin F. Yolk sac failure in embryopathy due to hyperglycemia: ultrastructural analysis of yolk sac differentiation associated with embryopathy in rat conceptuses under hyperglycemic conditions Teratology. 1986 Feb; 33(1):73-84.
57. Pinter E, Haigh J, Nagy A, Madri JA Hyperglycemia-induced vasculopathy in the murine conceptus is mediated via reductions of VEGF-A expression and VEGF receptor activation Am J Pathol. 2001 Apr; 158(4):1199-206.
58. Reece EA, Wu YK. Prevention of diabetic embryopathy in offspring of diabetic rats with use of a cocktail of deficient substrates and an antioxidant Am J Obstet Gynecol. 1997 Apr; 176(4):790-7; discussion 797-8.
59. Reed DJ, Fariss MW Glutathione Depletion and Oxidant Susceptibility Pharmacol Revi 1984; 2: 255-335.
60. Richards AA, Garg V. Genetics of congenital heart disease. Curr Cardiol Rev. 2010 May; 6(2):91-7.
61. Rice GE, Scholz-Romero K, Sweeney E, Peiris H, Kobayashi M, Duncombe G, Mitchell MD, Salomon C The Effect of Glucose on the Release and Bioactivity of Exosomes From First Trimester Trophoblast Cells. J Clin Endocrinol Metab. 2015 Oct;100(10):E1280-8.
62. Roest PA, van Iperen L, Vis S, Wisse LJ, Poelmann RE, Steegers-Theunissen RP, Molin DG, Eriksson UJ, Gittenberger-De Groot AC. Exposure of neural crest cells to elevated glucose leads to congenital heart defects, an effect that can be prevented by N-acetylcysteine. Birth Defects Res A Clin Mol Teratol. 2007 Mar; 79(3):231-5.
63. Roman MA. Preconception care for women with preexisting type 2 diabetes. Clin Diabetes 2011; 29:10–16
64. Roušar T, Nýdlová E, Česla P, Staňková P, Kučera O, Pařík P, Červinková Z Purified acetaminophen-glutathione conjugate is able to induce oxidative stress in rat liver mitochondria Physiol Res. 2012;61 Suppl 2:S103-9.
65. Ryan EA Prevention and Treatment of Diabetes and Its Complications Medical Clinics of North America 1998; 82; 4: 824-842.
66. Sakamaki H, Akazawa S, Ishibashi M, Izumino K, Takino H, Yamasaki H, Yamaguchi Y, Goto S, Urata Y, Kondo T, Nagataki S. Significance of glutathione-dependent antioxidant system in diabetes-induced embryonic malformations. Diabetes. 1999 May; 48(5):1138-44.
67. Salomon C, Rice GE Role of Exosomes in Placental Homeostasis and Pregnancy Disorders. Prog Mol Biol Transl Sci. 2017; 145:163-179.
68. Seo YJ, Lee JW, Lee EH, Lee HK, Kim HW, Kim YH. Role of glutathione in the adaptive tolerance to H2O2. Free Radic Biol Med. 2004 Oct 15; 37(8):1272-81.

© 2020 Global Journals

69. Scott-Drechsel DE, Rugonyi S, Marks DL, Thornburg KL, Hinds MT. Hyperglycemia slows embryonic growth and suppresses cell cycle via cyclin D1 and p21. Diabetes. 2013 Jan;62(1):234-42
70. Shi R, Zhao L, Cai W, Wei M, Zhou X, Yang G, Yuan L Maternal exosomes in diabetes contribute to the cardiac development deficiency. Biochem Biophys Res Commun. 2017 Jan 29;483(1):602-608
71. Simán CM, Eriksson UJ. Vitamin E decreases the occurrence of malformations in the offspring of diabetic rats Diabetes. 1997 Jun; 46(6):1054-61.
72. Simán M. Congenital malformations in experimental diabetic pregnancy: aetiology and antioxidative treatment. Minireview based on a doctoral thesis Ups J Med Sci. 1997; 102(2):61-98.
73. Sudano I, Flammer AJ, Periat D, Enseleit F, Hermman M, Wolfrum M, Hirt A, Kaiser P, Hurlimman D, Neidhart M, Gay S, Holzmeister J, Nussberger J, Mocharla P, Landmesser U, Haile SR, Corti R, Vanhoutte PM, Luscher TF, Noil G, Ruschitzka F Acetaminophen Increases Blood Pressure in Ambulatory Patients With Coronary Artery Disease Circulation 2010; 122:1789-1796.
74. Sule AA, Tai DY, Tze CC, Deepa B, Leow MK Potentially fatal paracetamol overdose and successful treatment with 3 days of intravenous N-acetylcysteine regime--a case report Ann Acad Med Singapore. 2006 Feb; 35(2):108-11.
75. Styrud J, Thunberg L, Nybacka O, Eriksson UJ. Correlations between maternal metabolism and deranged development in the offspring of normal and diabetic rats Pediatr Res. 1995 Mar; 37(3): 343-53.
76. Todorova K, Mazneĭkova V, Ivanov S, Genova M. [The frequency of mild and severe fetal malformations in diabetic women with high values of glycosilated hemoglobin in early pregnancy] Akush Ginekol (Sofiia). 2005; 44(3):3-10.
77. Torchinsky A, Toder V, Carp H, Orenstein H, Fein A. In vivo evidence for the existence of a threshold for hyperglycemia-induced major fetal malformations: relevance to the etiology of diabetic teratogenesis. Early Pregnancy. 1997 Mar; 3(1):27-33.
78. Trocino RA, Akazawa S, Ishibashi M, Matsumoto K, Matsuo H, Yamamoto H, Goto S, Urata Y, Kondo T, Nagataki S Significance of glutathione depletion and oxidative stress in early embryogenesis in glucose-induced rat embryo culture. Diabetes. 1995 Aug; 44(8):992-8.
79. Ucheya RE, Igweh JC. Histological changes in kidney structure following a long-term administration of paracetamol (acetaminophen) in pregnant Sprague Dawley rats Niger J Physiol Sci. 2006 Jun-Dec;21(1-2):77-81.
80. Vaziri ND, Wang XQ, Oveisi F, Rad B Induction of oxidative stress by glutathione depletion causes severe hypertension in normal rats *Hypertension* 2000; 36: 142-146
81. Wentzel P, Eriksson UJ Insulin treatment fails to abolish the teratogenic potential of serum from diabetic rats Eur J Endocrinol. 1996 Apr; 134(4): 459-66.
82. Wentzel P, Thunberg L, Eriksson UJ. Teratogenic effect of diabetic serum is prevented by supplementation of superoxide dismutase and N-acetylcysteine in rat embryo culture Diabetologia. 1997 Jan; 40(1):7-14.
83. Wentzel P, Gäreskog M, Eriksson UJ. Decreased cardiac glutathione peroxidase levels and enhanced mandibular apoptosis in malformed embryos of diabetic rats. Diabetes. 2008 Dec;57(12):3344-52
84. Whitcomb DC, Block GD. Association of acetaminophen hepatotoxicity with fasting and ethanol use JAMA. 1994 Dec 21; 272(23):1845-50.
85. Wu PY. Infant of diabetic mother: a continuing challenge for perinatal-neonatal medicine Zhonghua Min Guo Xiao Er Ke Yi Xue Hui Za Zhi. 1996 Sep-Oct; 37(5):312-9.
86. Yang X, Borg LA, Eriksson UJ. Altered mitochondrial morphology of rat embryos in diabetic pregnancy Anat Rec. 1995 Feb; 241(2):255-67.
87. Zabihi S1, Loeken MR Understanding diabetic teratogenesis: where are we now and where are we going? Birth Defects Res A Clin Mol Teratol. 2010 Oct;88(10):779-90
88. Zhong J, Wang S, Shen WB, Kaushal S, Yang P The current status and future of cardiac stem/progenitor cell therapy for congenital heart defects from diabetic pregnancy. Pediatr Res. 2018 Jan; 83(1-2): 275-282
89. Zhou X, Lu X. The role of oxidative stress in high glucose-induced apoptosis in neonatal rat cardiomyocytes Exp Biol Med (Maywood). 2013 Aug 1;238(8):898-902

© 2020 Global Journals