



GLOBAL JOURNAL OF MEDICAL RESEARCH: E
GYNECOLOGY AND OBSTETRICS
Volume 23 Issue 1 Version 1.0 Year 2023
Type: Double Blind Peer Reviewed International Research Journal
Publisher: Global Journals
Online ISSN: 2249-4618 & Print ISSN: 0975-5888

A Study to Find Out the Efficacy of Strip Immunoassay Test for Insulin Like Growth Factor Binding Protein-1 in Amniotic Fluid for Detection of Premature Rupture of Membranes

By Dr. Akansha Kumawat, Dr. Pushpa Nagar, Dr. Sana Tak,
Dr. Aditi Bansal & Dr. Bhavini

Abstract- Background: It is an obstetric conundrum which is poorly defined with an obscure etiology, difficulty in diagnosis, association with significant maternal and neonatal morbidity and mortality, with diverse and controversial management strategies.

Aim and Objectives: To know the efficacy of strip immunoassay test in amniotic fluid for detection of premature rupture of membranes.

Materials and Methods: A hospital based observational study carried out on 60 pregnant women attending emergency and OPD with complaints of leaking per vaginum. Strip immunoassay test was performed on all the participants along with a conventional method like ferning and the results obtained were analysed for calculating the diagnostic accuracy of the test.

Keywords: premature rupture of membranes, ferning, strip immunoassay test, insulin like growth factor binding protein-1.

GJMR-E Classification: DDC Code: 618.2 LCC Code: RG524



Strictly as per the compliance and regulations of:



© 2023. Dr. Akansha Kumawat, Dr. Pushpa Nagar, Dr. Sana Tak, Dr. Aditi Bansal & Dr. Bhavini. This research/review article is distributed under the terms of the Attribution-NonCommercial-NoDerivatives 4.0 International (CC BY-NC-ND 4.0). You must give appropriate credit to authors and reference this article if parts of the article are reproduced in any manner. Applicable licensing terms are at <https://creativecommons.org/licenses/by-nc-nd/4.0/>.

A Study to Find Out the Efficacy of Strip Immunoassay Test for Insulin Like Growth Factor Binding Protein-1 in Amniotic Fluid for Detection of Premature Rupture of Membranes

Dr. Akansha Kumawat ^α, Dr. Pushpa Nagar ^σ, Dr. Sana Tak ^ρ, Dr. Aditi Bansal ^ω & Dr. Bhavini [¥]

Abstract- Background: It is an obstetric conundrum which is poorly defined with an obscure etiology, difficulty in diagnosis, association with significant maternal and neonatal morbidity and mortality, with diverse and controversial management strategies.

Aim and Objectives: To know the efficacy of strip immunoassay test in amniotic fluid for detection of premature rupture of membranes.

Materials and Methods: A hospital based observational study carried out on 60 pregnant women attending emergency and OPD with complaints of leaking per vaginum. Strip immunoassay test was performed on all the participants along with a conventional method like ferning and the results obtained were analysed for calculating the diagnostic accuracy of the test.

Results: Out of 60 participants (N=60), 38 had PROM (Premature Rupture of Membranes) and; strip immunoassay test was able to diagnose PROM in 34 women with a sensitivity, specificity, positive predictive value ,negative predictive value and diagnostic accuracy of 90%, 91%, 94%, 83% and 90% respectively.

Conclusion: The present study shows that the strip immunoassay test using IGFBP-1 (insulin like growth factor binding protein-1) on the cervicovaginal fluid is an accurate method to diagnose premature rupture of membranes.

Keywords: premature rupture of membranes, ferning, strip immunoassay test, insulin like growth factor binding protein-1.

I. INTRODUCTION

Premature rupture of membranes (PROM) refers to rupture of fetal membranes prior to the onset of labour, regardless of the gestational age. It is seen in 10% of term pregnancies and 2- 4% of preterm pregnancies ⁽¹⁾.

Diagnosis of rupture of membranes depends on documentation of three clinical signs on sterile speculum examination: - 1) Visual pooling of fluid in the

posterior fornix of vagina or leakage of fluid from the cervical os; (2) An alkaline pH of the cervicovaginal discharge; and (3) Microscopic ferning pattern of the cervicovaginal discharge on drying (fern test)⁽²⁾.

Because of the limitations with the current gold standard for the diagnosis of premature rupture of membranes such as- 1)invasiveness 2)risk of chorioamnionitis and 3)pregnancy loss with intra amniotic dye instillation, 4)long duration of leaking leading to non-visualization of pooling of fluid in the vagina and 5)alkaline pH of the cervicovaginal fluid in conditions other than leaking, investigators have long been searching for an alternative and more objective test with a good diagnostic accuracy which are primarily based on the identification of one or more biochemical markers in the cervicovaginal discharge like Insulin like growth factor binding protein-1 (IGFBP-1), Alpha FetoProtein, Placental Alpha Microglobulin(PAMG-1), prolactin, HCG, Urea and creatinine etc. that are present in the setting of rupture of membranes, but absent in women with intact membranes.

The present study has been perpetrated to find out the efficiency of strip immunoassay test for insulin like growth factor binding protein-1 in amniotic fluid so that timely obstetric intervention can be done to minimise the fetomaternal risk, especially in a low resource setting.

II. AIM AND OBJECTIVES

The aim of the study is to know the efficacy of detection of premature rupture of membranes by strip immunoassay test by detecting insulin like growth factor binding protein-1 (IGFBP-1) in amniotic fluid.

The objective of the present study is to assess the sensitivity, specificity, positive predictive value (PPV) and negative predictive value (NPV) of strip immunoassay test on amniotic fluid to diagnose PROM.

III. MATERIAL AND METHODS

The study was conducted in the Department of Obstetrics and Gynaecology of SMS Medical College, Jaipur. Pregnant women attending OPD and emergency with complaints of leaking per vaginum were included in

Author ^α [¥]: Resident, Department of Obstetrics and Gynaecology, SMS Medical College, Jaipur. e-mail: akanshakumawat95@gmail.com

Author ^σ: Senior Professor, Department of Obstetrics and Gynaecology, SMS Medical College, Jaipur.

Author ^ω: Associate Professor, Department of Obstetrics and Gynaecology, SMS Medical College, Jaipur.

the study with written informed consent. A detailed history and thorough examination and routine investigations were done. Sterile per speculum examination to detect amniotic fluid pooling through cervical canal was done. In all cases both Strip immunoassay test for insulin like growth factor binding protein-1 test and Fern test were performed. *Strip immunoassay test for insulin like growth factor binding protein-1*- sample of leaking fluid was taken by speculum examination by keeping a polyester swab stick in posterior vaginal fornix for about 10 second and swab was then rinsed in a buffered solution for about 5 seconds, yellow area of the dipstick provided in the kit was placed in the tube for 20 seconds then removed and placed on a flat surface. The stick contains monoclonal antibodies to insulin like growth factor binding protein-1 and absorbs the extracted specimen. If the extracted sample contains insulin like growth factor binding protein-1 in the extracted sample, two blue lines appeared on the stick. It meant test was positive, if no blue line was seen up to 5 min then test was negative. *Fern test*- sample of leaking fluid taken by speculum examination with a swab placed in posterior vaginal fornix and spread on a slide. Then the slide was dried and examined under low power microscope for crystallization of amniotic fluid to form fern like pattern which was considered as positive test.

The diagnostic values of the tests were determined by calculating sensitivity, specificity, positive

predictive value, negative predictive value and diagnostic accuracy.

IV. STATISTICAL ANALYSIS

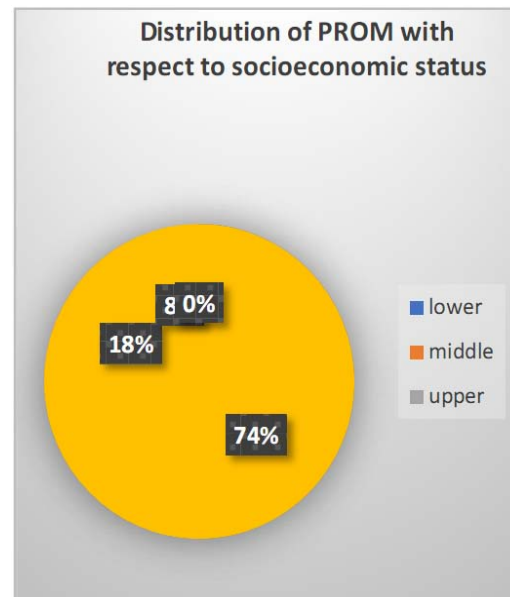
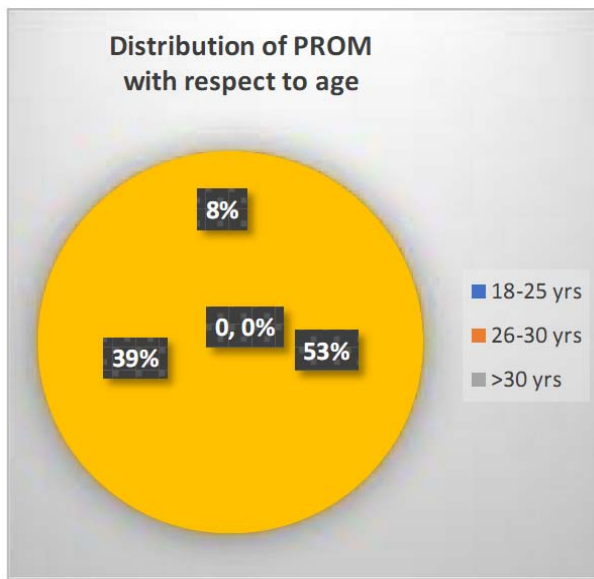
Data was summarized and entered in MS Excel sheet. Continuous variables were summarized as mean and standard deviation were analyzed by using unpaired t test. Nominal / categorical variables were summarized as proportions and were analyzed by using chi-square/ Fischer exact test, p-value<0.05 was taken as significant. The diagnostic value of the tests will be determined by calculating sensitivity, specificity, positive predictive value and negative predictive value and diagnostic accuracy and comparisons made. p-value <0.05 will be taken as significant.

V. OBSERVATIONS AND DISCUSSIONS

In present study, among women who had complaints of leaking PV (n=60) on examination, 35 of the participants had leaking Per vaginum and 25 did not have leaking per vaginum. On further examination, it was found that out of 25, 3 had membranes ruptured (PROM-Present) and 22 had membranes intact (PROM-absent). So, 38 participants had ruptured membranes and the rest 22 had intact membranes. Out of these 38, 34 were diagnosed by Strip immunoassay test for insulin like growth factor binding protein-1 and only 18 were ferning Positive.

Table 1

Age	Ruptured membranes	Membranes intact	p value- 0.563
18-25 yrs	20 (52.6%)	13 (59.1%)	
26-30 yrs	15 (39.5%)	9 (40.9%)	
>30 yrs	3 (7.9%)	0(0.0%)	
Residence	Ruptured membranes	Membranes intact	p value- 0.554
Urban	16 (42.1%)	11 (50.0%)	
Rural	22 (57.9%)	11 (50.0%)	
Socioeconomic status	Ruptured membranes	Membranes intact	p value- 0.014
Upper	3 (7.9%)	1 (4.5%)	
Middle	7 (18.4%)	12 (54.5%)	
Lower	28 (73.7%)	9 (40.9%)	



In present study, the mean age (years) in PROM cases was 25.66 ± 4.31 . In a similar study by Evrim Erdemoglu et al³ and Abdelazim et al⁴ the mean age of participants with PROM was 25.6 ± 5.5 years and 31.5 ± 9.52 years respectively. There was no statistically significant difference between women with ruptured membranes and intact membranes with respect to age group. 42.1% of women with PROM were from rural areas and 57.9% were from urban areas. There was no significant difference between the two groups in terms of distribution of residence ($p = 0.554$). Further studies are

required to investigate the common occurrence of PROM in rural population. Majority (73.7%) of the participants who had ruptured membranes belonged to lower Socioeconomic Status and the majority (54.5%) of them who had intact membranes belonged to middle socioeconomic status. The present study suggested that occurrence of PROM was more common in women belonging to lower socioeconomic status and it was statistically significant ($p=0.014$). In a study by Spinillo et al⁵, low social class was a significant risk factor for preterm PROM.

Table 2: Association between 'Ferning' and 'Duration Of Leaking (Hours):

Duration of Leaking (Hours)	Ferning		P value
	Positive	Negative	
Mean (SD)	4.72	7.64	0.022
Duration of Leaking (Hours)	Strip immunoassay test		P value
	Positive	Negative	
Mean (SD)	5.53	8.62	0.010

In Table 2, The mean (SD) of duration of leaking in hours in the Strip immunoassay test for insulin like growth factor binding protein-1 Positive Group was 5.53, Strip immunoassay test for insulin like growth factor binding protein-1 negative group was 8.62 whereas that in the Ferning Positive group was 4.72 and Ferning Negative Group was 7.64. Both values were significant but Strip immunoassay test for insulin like growth factor binding protein-1 can detect ruptured membranes of longer duration than Ferning.IGFBP-1 has been shown to be degraded by proteases in the vagina and it has been reported as being unreliable if > 12 hours have elapsed from the time of membrane rupture⁶, however, In the present study Strip immunoassay test for insulin like growth factor binding protein-1 could even diagnose 2 cases who had leaking of more than 12 hours.

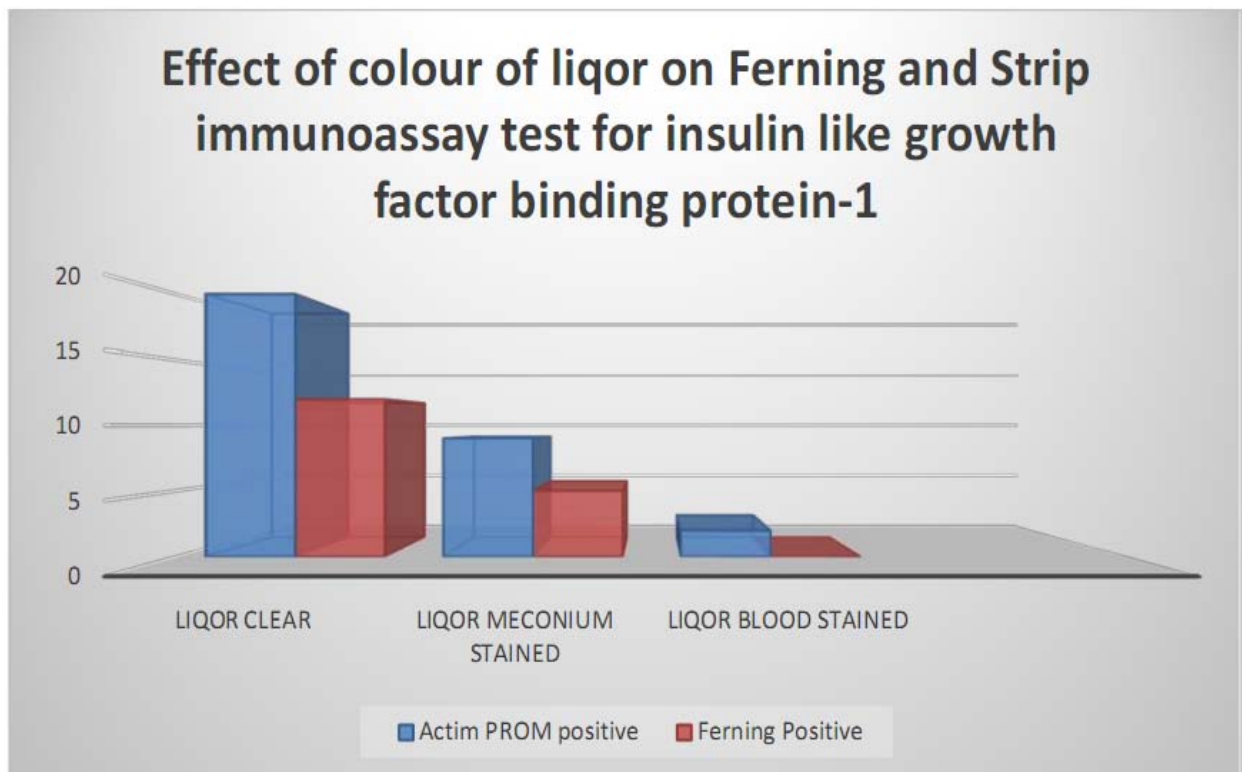


Table 3: Effect of Colour of liqor on Ferning and Strip immunoassay test for insulin like growth factor binding protein-1:

Ferning	Colour of Liqor		
	Clear	Meconium	Blood Stained
Positive	12	5	0
Negative	11	5	2
Actim PROM	Colour of Liqor		
	Clear	Meconium	Blood Stained
Positive	20	9	2
Negative	3	1	0

Upon performing both the tests on all the participants, the following results were obtained:

- Among the participants who had clear liqor, Ferning test was Positive in 52.2% whereas 87.0% of the participants had STRIP IMMUNOASSAY TEST FOR INSULIN LIKE GROWTH FACTOR BINDING PROTEIN-1 Positive.
- Among the participants who had liquor meconium stained, 50.0% of the participants gave positive ferning whereas 90.0% of the participants had Strip immunoassay test for insulin like growth factor binding protein-1 Positive.
- Among those who had liquor blood stained no participants had positive ferning whereas all the participants had positive Strip immunoassay test for insulin like growth factor binding protein-1 test.



To demonstrate the presence of amniotic fluid in the vagina, test results should not be influenced by the contamination of blood, urine, seminal fluid or cervical mucus and meconium. Rutanen et al⁷ have reported that the IGFBP1 concentration in urine and seminal fluid are significantly lower than that in serum. And even if amniotic fluid is contaminated by blood, the contamination is negligible, because the serum: amniotic fluid ratio of IGFBP-1 concentration is

substantially high. Also, ferning may give false-positive results due to fingerprints, contamination with semen and cervical mucus as well as false negative results due to technical error where a dry swab is used to collect the sample or contamination with blood^{8,9,10}.

Table 4: Association between Amniotic Fluid Index with Ferning and Strip immunoassay test for insulin like growth factor binding protein-1:

Ferning	AFI		
	<5 cm	5-20 cm	P value- 0.004
Positive	15	3	
Negative	18	24	
Strip immunoassay test for insulin like growth factor binding protein-1			
p value <0.001			
Positive	30	6	
Negative	3	21	

In present study, mean AFI (cms) in women with PROM and without PROM were 2.74 (1.46) and 8.91±2.14, respectively. AFI<5 cm was seen in 84.2% women with ruptured membranes and 4.5% of the participants with intact membranes. Our study observed that women with PROM had a decreased AFI, which was statistically highly significant (p<0.001). Similar findings were observed in a study by Erdemoglu E et al³.

Also, in this study, it was found that the participants who had AFI <5 cm, Strip immunoassay test for insulin like growth factor binding protein-1 was found to be positive in 30 cases whereas, Ferning was positive only in 15 cases (p value-0.004) which was significant with both the testing methods but more significant with Strip immunoassay test for insulin like growth factor binding protein-1.

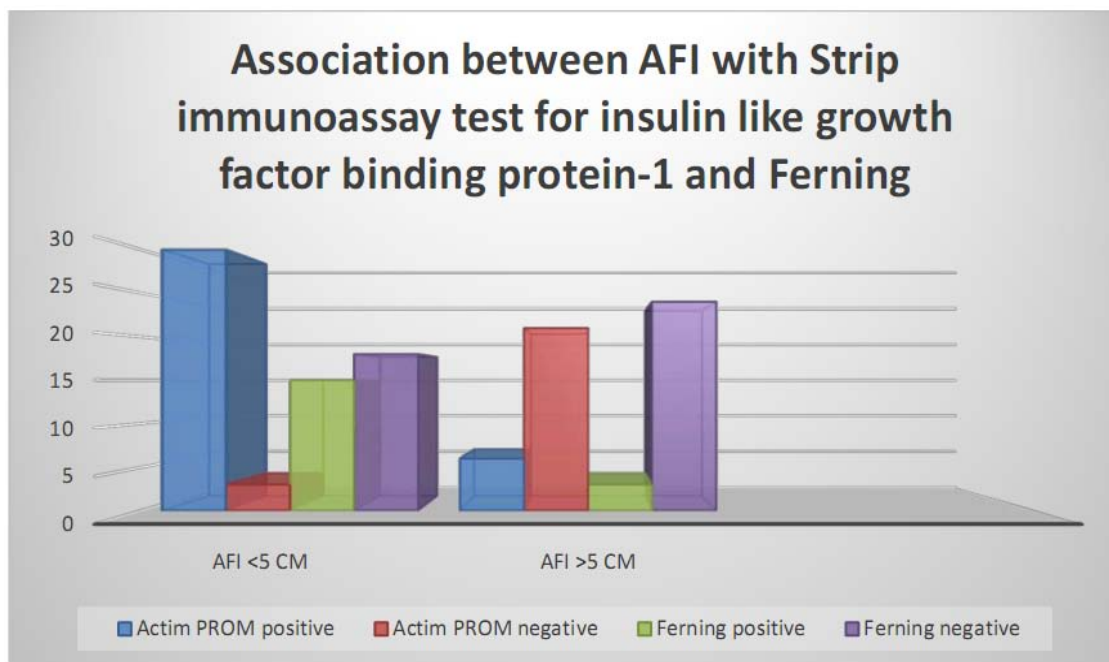


Table 5: The comparison between efficacies of both the tests in our study

VARIABLE	STRIP IMMUNOASSAY TEST	FERNING
Sensitivity	90%	47%
Specificity	91%	100%
Positive Predictive Value	94%	100%
Negative Predictive value	83%	52%
Diagnostic Accuracy	90%	67%

VI. CONCLUSIONS AND RECOMMENDATIONS

PROM is one of the most troublesome issues in today's obstetrics. Our data shows that IGFBP-1 is an ideal marker of Amniotic fluid and that rapid, simple test for the measurement of this protein in vaginal secretion by a dipstick method has a diagnostic potential in the diagnosis or exclusion of rupture of fetal membranes. The high sensitivity, specificity, PPV, NPV of strip immunoassay test using IGFBP-1 (Strip immunoassay test for insulin like growth factor binding protein-1) makes it a useful test when in doubt of PROM. It is easily performed in clinical setting and no extra staff is required.

The correct diagnosis of PROM is critical for both maternal and foetal concerns, it's high sensitivity and specificity will not only protect the mother from the deleterious effects of intraamniotic infections, post-partum infections and endometritis, but will also prevent the preterm birth by unnecessary induction of labor or cesarean section thus decreasing the burden of neonatal ICU admissions, thereby reducing the maternal morbidity and neonatal mortality and morbidity.

Informed Consent Statement: All subjects here were already informed and gave consent.

Provenance and Peer Review: not commissioned, externally peer-reviewed.

Declaration of Competing Interest: None.

ACKNOWLEDGEMENT

The authors would like to thank everyone who supported and assisted throughout all aspects of our study and for their help in writing the manuscript.

BIBLIOGRAPHY

1. Mercer BM, Goldenberg RL, Meis PJ, et al. The Preterm Prediction Study: prediction of preterm premature rupture of membranes through clinical findings and ancillary testing. The National Institute of Child Health and Human Development Maternal-Fetal Medicine Units Network. *Am J ObstetGynecol*2000; 183: 738–745.
2. Caughey AB, Robinson JN, Norwitz ER. Contemporary diagnosis and management of preterm premature rupture of membranes. *Rev ObstetGynecol* 2008; 1(1): 11–22.
3. Erdemoglu E, Mungan T. Significance of detecting insulin like growth factor binding protein-1 in cervicovaginal secretions: comparison with nitrazine test and amniotic fluid volume assessment. *Acta ObstetGynecolScand*2004; 83: 622– 626.
4. Abdelazim, Ibrahim A. "Insulin-like growth factor binding protein-1 (Strip immunoassay test for insulin like growth factor binding protein-1 test) for detection of premature rupture of fetal membranes."

5. *The journal of obstetrics and gynaecology research* vol. 40, 4 (2014): 961-7. doi:10.1111/jog.12296
6. A. Spinillo, S. Nicola, G. Piazzzi, K. Ghazal, L. Colonna, F. Baltaro: Epidemiological correlates of preterm premature rupture of membranes, *Int. J. Gynecol. Obstet.*1994; 47: 7-15.
7. College of Obstetricians and Gynecologists, authors. *Obstetrician and Premature Rupture of Membranes*. Washington, DC: American College of Gynecologists; 1998. (ACOG Practice Bulletin No. 1).
8. Kallioniemi, H, Rahkonen, L, Heikinheimo, O, Stefanovic, V, Paavonen, J. Usefulness of the insulin-like growth factor binding protein-1 bedside test for ruptured fetal membranes. *Acta ObstetGynecolScand* 2014; 93: 1282– 1289.
9. Friedman ML, McElin TW. Diagnosis of ruptured fetal membranes. Clinical study and review of the literature. *Am J ObstetGynecol*1969; 104: 544–550.
10. Rosemond RL, Lombardi SJ, Boehm FH. Ferning of amniotic fluid contaminated with blood. *Obstet Gynecol.* 1990; 75: 338-340.
11. Mercer BM. Preterm rupture of the membranes: diagnosis and management. *Clin Perinatol*2004; 31: 765–782.