Volume 23 Issue 28
Originally issued as E2



Global Journal of Medical Research: E
Gynecology and Obstetrics
Volume 23 Issue 2 Version 1.0 Year 2023
Type: Double Blind Peer Reviewed International Research Journal
Publisher: Global Journals
Online ISSN: 2249-4618 & Print ISSN: 0975-5888

Retrospective Review of Outcomes in Patients with Endometriosis and Colonic Segmental Resection (CSR) or Low Anterior Resection (LAR)

By Linda Li, MD, FACOG, Sonia Hafiz, BA, Christy Stetter, BS & Kristin Riley, MD, FACOG

500 University Drive Suite

Abstract- *Objective:* To further the understanding of long-term outcomes of endometriosis patients requiring colonic segmental resection (CSR) or low anterior resection (LAR). To improve counseling of patients with bowel endometriosis.

Methods: Retrospective chart review at a single academic institution between 2000-2018 with 3-year follow-up of patients with CSR/LAR for endometriosis.

21 patients aged 18-45 at single academic institution between 1/1/2000 and 12/31/2018 with ICD9&10 codes of endometriosis AND CSR/LAR were included; 9 met criteria for endometriosis as indication for CSR/LAR were reviewed.

Results: Pre- and post-operative symptoms were categorized into GI (hematochezia, dyschezia, tenesmus, incontinence, incomplete evacuation of bowel, and pre-operative colonoscopy), GYN (dysmenorrhea, dyspareunia, pelvic pain, and infertility), and GU (dysuria, frequency, urgency, incontinence, and incomplete emptying).

GJMR-E Classification: *UDC: 618*



Strictly as per the compliance and regulations of:



© 2023. Linda Li, MD, FACOG, Sonia Hafiz, BA, Christy Stetter, BS & Kristin Riley, MD, FACOG. This research/review article is distributed under the terms of the Attribution-NonCommercial-NoDerivatives 4.0 International (CC BY-NC-ND 4.0). You must give appropriate credit to authors and reference this article if parts of the article are reproduced in any manner. Applicable licensing terms are at https://creativecommons.org/licenses/by-nc-nd/4.0/.

Retrospective Review of Outcomes in Patients with Endometriosis and Colonic Segmental Resection (CSR) or Low Anterior Resection (LAR)

Linda Li, MD, FACOG [α], Sonia Hafiz, BA [σ], Christy Stetter, BS [ρ] & Kristin Riley, MD, FACOG [ω]

Abstract- Objective: To further the understanding of long-term outcomes of endometriosis patients requiring colonic segmental resection (CSR) or low anterior resection (LAR). To improve counseling of patients with bowel endometriosis.

Methods: Retrospective chart review at a single academic institution between 2000-2018 with 3-year follow-up of patients with CSR/LAR for endometriosis.

21 patients aged 18-45 at single academic institution between 1/1/2000 and 12/31/2018 with ICD9&10 codes of endometriosis AND CSR/LAR were included; 9 met criteria for endometriosis as indication for CSR/LAR were reviewed.

Results: Pre- and post-operative symptoms were categorized into GI (hematochezia, dyschezia, tenesmus, incontinence, incomplete evacuation of bowel, and pre-operative colonoscopy), GYN (dysmenorrhea, dyspareunia, pelvic pain, and infertility), and GU (dysuria, frequency, urgency, incontinence, and incomplete emptying).

Pre-operatively, GI symptoms: 33.33% endorsed hematochezia and underwent a colonoscopy, 77.78% dyschezia, and 11.11% fecal incontinence. GYN: 77.78% endorsed dysmenorrhea, 55.56% dyspareunia, 100% pelvic pain. GU: 11.11% endorsed urinary incontinence.

Intraoperatively, 100% underwent anastomosis, 33.33% concurrent hysterectomy and 66.67% oophorectomy. Average operative time was 165.8 minutes. Median EBL 50cc. Median days spent inpatient 3.

Post-operatively, 1 patient underwent a reoperation for GYN excision of endometriosis in the 3 year follow up.

There was 88.89% decrease in pelvic pain and complete resolution of all other pre-operative symptoms of hematochezia, dyschezia, fecal incontinence, dysmenorrhea, dyspareunia and urinary incontinence.

Discussion: We found a clinically significant reduction in symptoms of hematochezia, dyschezia, fecal incontinence, dysmenorrhea, pelvic pain, dyspareunia and urinary incontinence in patients who underwent bowel resection for the indication of endometriosis. In all patients who had hematochezia and underwent a colonoscopy with positive findings of lesions or masses, the pathology also returned positive for endometriosis. Therefore, if a patient has hematochezia on presentation or review of systems, it is important to consider a colonoscopy in work up and CSR/LAR.

Corresponding Author α: Division of Minimally Invasive Gynecologic Surgery, Department of Obstetrics and Gynecology Penn State Health, 500 University Drive Suite, Hershey, PA.
e-mail: lindali@pennstatehealth.psu.edu
Author ω: Division of Minimally Invasive Gynecologic Surgery, Department of Obstetrics and Gynecology, Penn State Health, Hershey, PA.
Author σ: College of Medicine, Penn State University, Hershey, PA.
Author ρ: Department of Public Health Sciences, Penn State University, Hershey, PA.

I. Introduction

Endometriosis affects 10% of reproductive age women with common presenting symptom of pelvic pain.[1-2] The most common extragenital site of deep infiltrative endometriosis (DIE) is the GI tract, the rectum and sigmoid colon, and affects up to 15% of women with endometriosis and commonly present with hematochezia, dyschezia, tenesmus, incontinence, or obstruction.[3-4] Pathogenesis of bowel endometriosis is multifactorial but mostly due to proximity in the Pouch of Douglas to ovarian endometriomas and gravitational deposits.[5] It is widely agreed that surgical management is the primary treatment of bowel DIE.[4] A meta-analysis showed shaving is associated with lower rates of complications than discoid/segmental resection; however, due to variation of invasion, size, and location, shaving/discoid resection may not completely treat the disease.[6-8] Laparoscopic or robotic approach is safe and efficient, with complication rates of anastomotic leakage, rectovaginal fistula, stricture, and low anterior resection syndrome to be 2-5%, 3%, 21%, and 38% respectively.[9-14]

There is limited information on long-term outcomes of patients with endometriosis and bowel resection from a comprehensive gastrointestinal (GI), genitourinary (GU) and gynecologic (GYN) standpoint. Retrospective studies have shown up to a 71-94% reduction of pelvic symptoms especially with concurrent GYN surgeries.[9,12,13,15] One prospective study involving 128 patients who underwent low anterior resection (LAR) for endometriosis showed improvement in bladder pain, sexual function, and defecation frequency.[17] Our study will further investigate the long-term outcomes of endometriosis patients requiring LAR or colonic segmental resection (CSR) to improve counseling of patients with bowel endometriosis.

II. Methods

This study is a retrospective chart review at a single academic institution, Penn State Hershey Medical Center, between 2000-2018 with 3-year follow-up of patients with CSR/LAR for the indication of endometriosis. Inclusion criteria consisted of age 18-45, ICD-9 and ICD-10 codes for endometriosis AND low anterior bowel resection (colectomy laparoscopic, or

© 2023 Global Journals

open), and surgical diagnosis with direct visualization or histopathologic confirmation of endometriosis. Exclusion criteria included pregnancy. Out of 21 charts generated from the ICD-9 and ICD-10 codes, 9 patients met criteria for specific indication of bowel resection being endometriosis and age (Figure 1).

The chart review consisted of gathering information regarding demographics (age, gravidity, parity, race, insurance, body mass index (BMI)). Endometriosis suppression regimen was also recorded (oral hormone - progestin or combination estrogen and progestin, IUD, Lupron, Orlissa). Preoperative and postoperative symptoms were recorded for GYNsymptoms (dysmenorrhea, dyspareunia, pelvic pain, infertility), GI symptoms (hematochezia, dyschezia, tenesmus, incontinence, incomplete evacuation of bowel, colonoscopy), and GU symptoms (dysuria, frequency, urgency, incontinence, incomplete emptying of bladder). Intraoperative details such as colorectal surgery route (laparoscopic, robotic, or open) and type (anastomosis or divert), and gynecology (concurrent hysterectomy and oophorectomy - unilateral or bilateral) were recorded. Operative time (incision to end time in minutes), estimated blood loss, and days inpatient were also recorded.

On pathology review, gastrointestinal pathology (endometriosis presence, primary focal layer invasion, number of satellite lesions) and gynecology (endometriosis presence) were recorded. Postoperative outcomes were recorded for gastrointestinal outcomes such as complications (leak, fistula, reoperation), Low Anterior Resection Syndrome (LARS: frequency or urgency of stools, clustering of stools, fecal incontinence, increased flatus), and recurrence of endometriosis lesions. Postoperative outcomes were recorded for gynecological outcomes as well, including suppression medication changes (addition/reduction), pain medication changes (addition/reduction), and complications (cuff dehiscence, reoperation). Lastly, follow up duration (in months) was also recorded.

Descriptive statistical analysis was conducted on the cohort of 9 patients. This study was IRB approved for exemption prior to data collection.

III. Results

Patient demographics are reported in Table 1. Nine patients met inclusion criteria with an average age of 40 (range: 28-45 years). Six patients (66.7%) had follow up to36 months; the duration of follow up for the remaining 3 patients was 10 months, 15 months, and 21 months. Pre-operatively, GI symptoms: 3 (33.3%) endorsed hematochezia and underwent a colonoscopy pre-operatively, 7 (77.8%) endorsed dyschezia, and 1 (11.1%) fecal incontinence; GYN: 7 (77.8%) endorsed dysmenorrhea, 5 (55.6%) dyspareunia, 9 (100%) pelvic pain; GU: 1 (11.1%) endorsed urinary incontinence.

Intraoperatively, the route of resection was: 4 (44.4%) laparoscopic, 2 (22.2%) robotic, and 3 (33.3%) open. All patients underwent anastomosis. Six patients (66.7%) underwent concurrent gynecologic procedures: 3 hysterectomy with oophorectomy and 3oophorectomy. The average operative time was 165.8 minutes (range: 111-264 minutes) and median estimated blood loss 50cc (range: 20-800cc). Amedian of 3 days was spent inpatient (range: 1-7 days). Post-operatively, there were no GI complications including anastomotic leak, fistula, LARS, GI recurrence or reoperation. One subject had a GYN reoperation for excision of endometriosis within 3 years of follow up. Two subjects (22.2%) had a reduction in pain medication use.

With regards to symptom change after bowel resection, pelvic pain resolved for 8/9 patients (88.9%) and there was complete resolution of all other preoperative symptoms of hematochezia, dyschezia, fecal incontinence, dysmenorrhea, dyspareunia and urinary incontinence (Figure 2).On pathology, endometriosis was present on the resected bowel segment in 5 patients (55.6%) with 3 having primary focal layer invasion. Of those who underwent concurrent GYN resection, all had endometriosis present on GYN pathology.

IV. Discussion

Our study's findings on improvement of GI, GYN, and GU symptoms are consistent with previous literature.[20] Specifically, CSR for the indication of endometriosis has been shown to significantly reduce fecal incontinence for flatus, liquid stools, clustering of stools, and fecal urgency. Improvement of GI, GU, and GYN symptoms were also found in patients who underwent LAR with the indication of DIE similar to that of our study. A key finding worth noting from our study is that in all patients who had hematochezia and underwent a colonoscopy with positive findings, the pathology also returned positive for endometriosis. Therefore, if a patient has hematochezia on presentation, it is important to obtain a colonoscopy preoperatively and discuss potential need for CSR/LAR as treatment. Therefore, our study's findings regarding the improvement of GI and GYN symptoms post-operatively contribute and corroborate the existing literature giving strength in counseling of patients with DIE requiring bowel resection.[21]

Previous studies on this topic have looked at short-term effects postoperatively, specifically within a year of the procedure.[18,19] Our study extended follow up to three years with the average follow-up in our cohort being 29.11 months. Therefore, the results from this study provide insight into long-term effects of CSR/LAR on patients with DIE specifically, the decrease in use of pain medication postoperatively and decrease risk of

© 2023 Global Journals

recurrence. There was no reoperation within the three-year follow-up.

Interestingly, our demographics showed an average age of 40 with the vast majority 8/9 (88.89%) of the patients not on any hormonal therapy likely the reason being that 6/9 were status post hysterectomy while the remaining 3/9 had concurrent hysterectomy. The two patients who had uterus in situ and not on hormonal therapy presented with chief complaints of GI symptoms. The older age and post-surgical treatment of endometriosis is suggestive that DIE, especially of the bowel presents later in the manifestation of endometriosis disease progression. Therefore, clinicians need to continue to be vigilant of endometriosis as a chronic disease.

This study contributes to the existing literature which shows that the use of CSR and LAR with the indication of endometriosis can significantly decrease GI, GYN, and GU symptoms. LAR has been found to be a safe and feasible operation for those experiencing DIE, especially for patients with complex endometriosis.[23-24] Although post-operatively, no GI or GYN complications were seen including anastomotic leak, fistula, or reoperation, transanal minimally invasive rectal (TAMIS) resection has been found to lead to significantly fewer complications.[25] A study found that when TAMIS was performed, patients were less likely to experience a change in the quality of life when compared to LAR. This is due to higher chances of complications from LAR. Therefore, future studies may compare changes in GI, GYN, and GU symptoms and complications postoperatively from LAR compared to other surgical methods and minimally invasive resections such as TAMIS.

In addition to the small patient sample, another limitation of our study lies in the retrospective nature of the data collection. Other studies found the presence of more pre- and post-operative symptoms when conducting phone surveys directly with the patients. Therefore, future prospective studies could be conducted to gather a more thorough record of symptoms pre and postoperatively. Previous studies have found that there is a lower risk of gastrointestinal dysfunction when patients underwent LAR due to the preservation of the rectal reservoir and protection of the presacral nerves when compared to those with CSR.[23] Therefore, future research should focus on evaluating changes in symptoms of patients stratified based on the type of resection to allow clinicians to best determine treatment for patients experiencing DIE and provide detailed counseling when selecting the best resection method.

We found a clinically significant reduction in symptoms of hematochezia, dyschezia, fecal incontinence, dysmenorrhea, pelvic pain, dyspareunia and urinary incontinence in patients who underwent bowel resection for the indication of endometriosis. In all patients who had hematochezia and underwent a colonoscopy with positive findings of lesions or masses, the pathology also returned positive for endometriosis. Therefore, if a patient has hematochezia on presentation or review of systems, it is important to consider a colonoscopy in work up and CSR/LAR as potential treatment planning.

References Références Referencias

1. Burney, R. O., & Giudice, L. C. (2012). Pathogenesis and pathophysiology of endometriosis. *FertilSteril,* 98(3), 511-519. https://doi.org/10.1016/j.fertnstert.2012.06.029
2. Giudice, L. C., & Kao, L. C. (2004). Endometriosis. *Lancet, 364*(9447), 1789-1799. https://doi.org/10.1016/S0140-6736(04)17403-5
3. Bai, H. Y., & Yang, Z. Q. (2017). Effect of transcutaneous electrical nerve stimulation therapy for the treatment of primary dysmenorrheal. *Medicine (Baltimore), 96*(36), e7959. https://doi.org/10.1097/MD.0000000000007959
4. Kim, J. S., Hur, H., Min, B. S., Kim, H., Sohn, S. K., Cho, C. H., et al. (2009). Intestinal endometriosis mimicking carcinoma of rectum and sigmoid colon: a report of five cases. Yonsei Med J, 50(5), 732-735.
5. Ruffo, G., Sartori, A., Crippa, S., Partelli, S., Barugola, G., Manzoni, A., et al. (2012). Laparoscopic rectal resection for severe endometriosis of the mid and low rectum: technique and operative results. Surg Endosc, 26(4), 1035-1040.
6. Yong, P. J., Bedaiwy, M. A., Alotaibi, F., &Anglesio, M. S. (2021). Pathogenesis of bowel endometriosis. Best Pract Res Clin ObstetGynaecol, 71, 2-13.
7. Bendifallah, S., Puchar, A., Vesale, E., Moawad, G., Daraï, E., & Roman, H. (2021). Surgical Outcomes after Colorectal Surgery for Endometriosis: A Systematic Review and Meta-analysis. J Minim Invasive Gynecol, 28(3), 453-466.
8. Donnez, O., & Roman, H. (2017). Choosing the right surgical technique for deep endometriosis: shaving, disc excision, or bowel resection? FertilSteril, 108(6), 931-942.
9. Ip, J. C. Y., Chua, T. C., Wong, S. W., & Krishnan, S. (2020). Rectal disc resection improves stool frequency in patients with deep infiltrating endometriosis: A prospective study. Aust N Z J ObstetGynaecol, 60(3), 454-458.
10. Ferrero, S., Stabilini, C., Barra, F., Clarizia, R., Roviglione, G., & Ceccaroni, M. (2021). Bowel resection for intestinal endometriosis. Best Pract Res Clin ObstetGynaecol, 71, 114-128.
11. Lim, P. C., Kang, E., & Park, d. H. (2011). Robot-assisted total intracorporeal low anterior resection with primary anastomosis and radical dissection for treatment of stage IV endometriosis with bowel

© 2023 Global Journals

involvement: morbidity and its outcome. J Robot Surg, 5(4), 273-278.
12. Klugsberger, B., Shamiyeh, A., Oppelt, P., Jabkowski, C., Schimetta, W., & Haas, D. (2015). Clinical Outcome after Colonic Resection in Women with Endometriosis. Biomed Res Int, 2015, 514383.
13. Moawad, N. S., Guido, R., Ramanathan, R., Mansuria, S., & Lee, T. (2011). Comparison of laparoscopic anterior discoid resection and laparoscopic low anterior resection of deep infiltrating rectosigmoid endometriosis. JSLS, 15(3), 331-338.
14. Keckstein, J., & Wiesinger, H. (2005). Deep endometriosis, including intestinal involvement--the interdisciplinary approach. Minim Invasive Ther Allied Technol, 14(3), 160-166.
15. Bokor, A., Hudelist, G., Dobó, N., Dauser, B., Farella, M., Brubel, R., et al. (2020). Low anterior resection syndrome following different surgical approaches for low rectal endometriosis: A retrospective multicenter study. Acta ObstetGynecol Scand.
16. Campagnacci, R., Perretta, S., Guerrieri, M., Paganini, A. M., De Sanctis, A., Ciavattini, A., et al. (2005). Laparoscopic colorectal resection for endometriosis. Surg Endosc, 19(5), 662-664.
17. Urbach, D. R., Reedijk, M., Richard, C. S., Lie, K. I., & Ross, T. M. (1998). Bowel resection for intestinal endometriosis. Dis Colon Rectum, 41(9), 1158-1164.
18. Riiskjaer, M., Greisen, S., Glavind-Kristensen, M., Kesmodel, U. S., Forman, A., & Seyer-Hansen, M. (2016). Pelvic organ function before and after laparoscopic bowel resection for rectosigmoid endometriosis: a prospective, observational study. BJOG, 123(8), 1360-1367.
19. G. Ruffo, F. Scopelliti, M. Scioscia, M. Ceccaroni, P. Mainardi, and L. Minelli, “Laparoscopic colorectal resection for deep infiltrating endometriosis: analysis of 436 cases,” Surgical Endoscopy and Other Interventional Techniques, vol. 24, no. 1, pp. 63–67, 2010.
20. P. Houtmeyers, W. Ceelen, J.-M. Gillardin, M. Dhondt, and P. Pattyn, “Surgery for gastrointestinal endometriosis: indications and results,” Acta ChirurgicaBelgica, vol. 106, no. 4, pp. 413–416, 2006.
21. Bray-Beraldo, F., Pellino, G., Ribeiro Jr, M. A. F., Pereira, A. M. G., Lopes, R. G. C., Mabrouk, M., & Di Saverio, S. (2021). Evaluation of bowel function after surgical treatment for intestinal endometriosis: a prospective study. Diseases of the Colon & Rectum, 64(10), 1267-1275.
22. Darai, E., Thomassin, I., Barranger, E., Detchev, R., Cortez, A., Houry, S., &Bazot, M. (2005). Feasibility and clinical outcome of laparoscopic colorectal resection for endometriosis. American journal of obstetrics and gynecology, 192(2), 394-400.
23. Ruffo, G., Scopelliti, F., Manzoni, A., Sartori, A., Rossini, R., Ceccaroni, M., ... & Falconi, M. (2014). Long-term outcome after laparoscopic bowel resections for deep infiltrating endometriosis: a single-center experience after 900 cases. BioMed Research International, 2014.
24. Ng, A., Yang, P., Wong, S., Vancaillie, T., & Krishnan, S. (2016). Medium to long-term gastrointestinal outcomes following disc resection of the rectum for treatment of endometriosis using a validated scoring questionnaire. Australian and New Zealand Journal of Obstetrics and Gynaecology, 56(4), 408-413.
25. Jatan, A. K., Solomon, M. J., Young, J., Cooper, M., & Pathma-Nathan, N. (2006). Laparoscopic management of rectal endometriosis. Diseases of the colon & rectum, 49(2), 169-174.
26. Vlek, S. L., Lier, M. C. I., Koedam, T. W. A., Melgers, I., Dekker, J. J. M. L., Bonjer, J. H., ... & Tuynman, J. B. (2017). Transanal minimally invasive rectal resection for deep endometriosis: a promising technique. Colorectal Disease, 19(6), 576-581.

© 2023 Global Journals

Table 1: Demographics

Age	**40 (6.2)**
BMI	33.8 (5.4)
Reproductive History	
Gravidity	2.4 (2.4)
Parity	1.8 (1.7)
Non-Hispanic Ethnicity	9 (100.0%)
Race	
Black	1 (11.1%)
White	8 (88.9%)
Insurance	
Private	8 (88.9%)
Medicare or Medicaid	1 (11.1%)
Endometriosis Suppression Regimen	
PO Hormone (Combination) Estrogen and Progestin	1 (11.1%)
None	8 (88.9%)

Data reported as mean (standard deviation) or n (%)

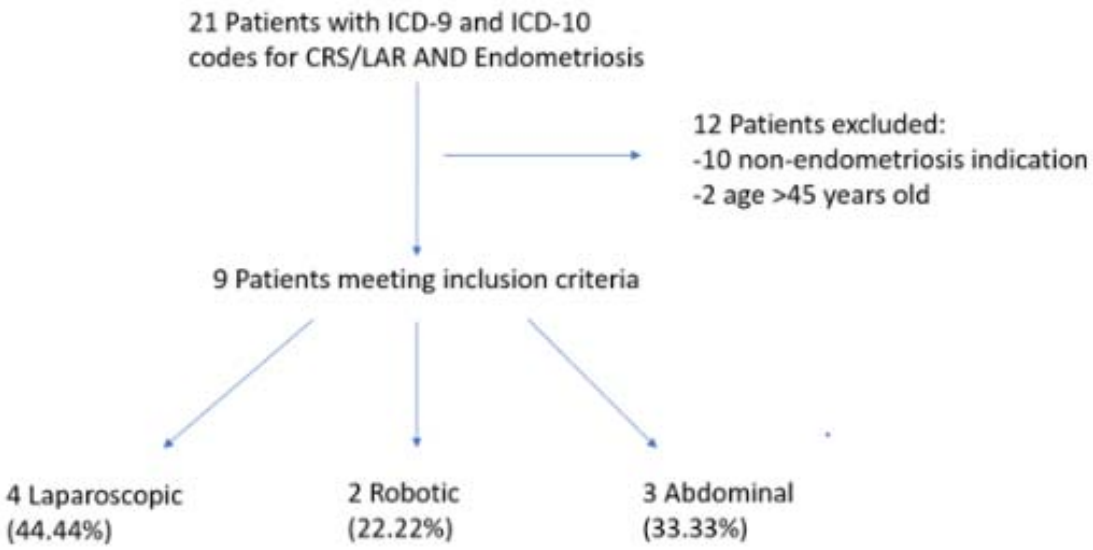

Figure 1: Patient Selection Inclusion and Exclusion

© 2023 Global Journals

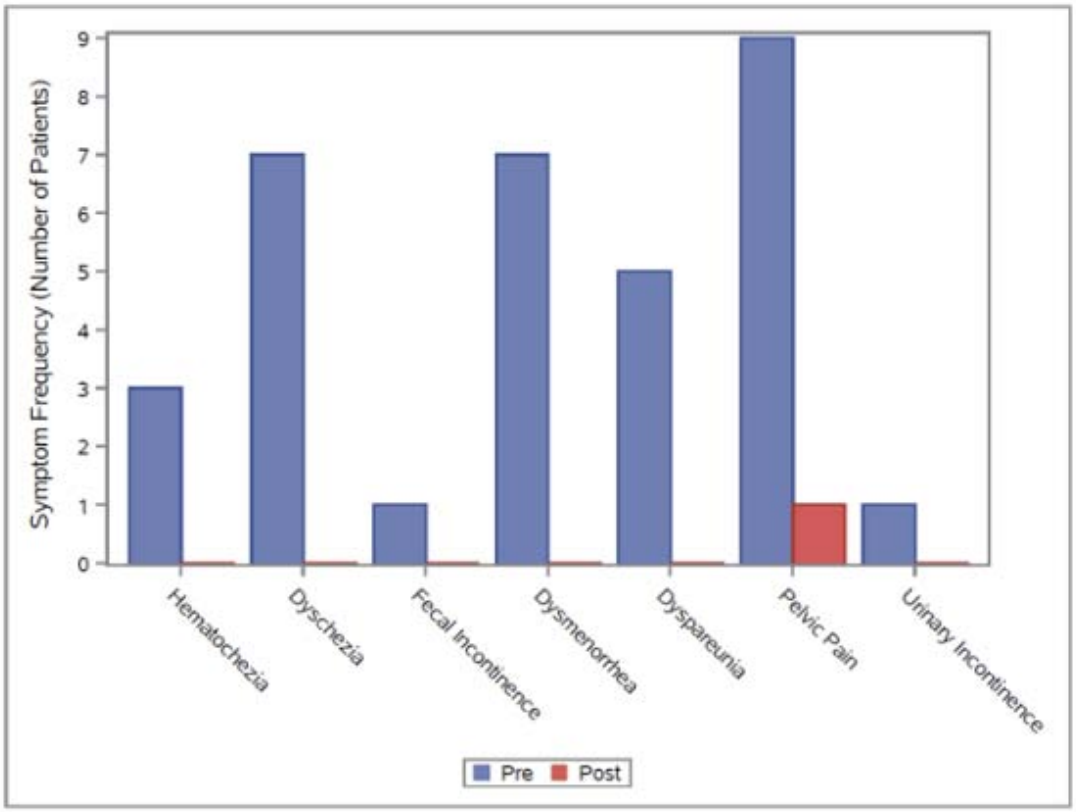

Figure 2: Change in GI, GYN, and GU symptom frequency pre vs. post operative

© 2023 Global Journals