



GLOBAL JOURNAL OF MEDICAL RESEARCH: B
PHARMA, DRUG DISCOVERY, TOXICOLOGY & MEDICINE
Volume 23 Issue 3 Version 1.0 Year 2023
Type: Double Blind Peer Reviewed International Research Journal
Publisher: Global Journals
Online ISSN: 2249-4618 & Print ISSN: 0975-5888

Chronic Ankle Ligament Injury and its Clinical Management, A Literature Review

By Amanda Gomes Quiroga, Jose Pereira da Silva Filho, Joaquim Lucas Silva Cardoso, Valter Oliveira da Silva, Ana Beatriz de Matos Berg Abrantes, Rebeca Mendes Peres, Fabiana Caroline Coelho Carvalho Firme, Isabella Menezes Batista, Eduarda Monteiro Machado, Ana Laura Passos de Magalhães, Ulisses Tomaz Monteiro, Bruna Daher Fonseca, Marina Mota de Oliveira Madruga, Caio Lopes Oliveira, Rayssa Blenda Martins, Victor de Oliveira Bessa, Maria Alice Silva Vasconcelos, Pollyane Vieira de Almeida, Eduardo Fernandes Rodrigues, Raphael Vinicius Mendes Abreu, Adeni Ferreira dos Santos Junior, Pedro Henrique Rodrigues & Karllos Adryano Priscinotte Rodrigues Lima

Abstract- Introduction: It's important to comprehend the key concepts of chronic ligament injuries to the ankle, which occur when there is deterioration or weakening and can result from recurrent or untreated trauma (AMODIO, 2013). Chronic ligament damage typically results from frequent ankle sprains. Ligaments are fibrous tissues that connect bones and provide stability for joints. In the ankle, the ligaments most commonly affected are the anterior talofibular ligament and the calcaneofibular ligament.

Keywords: *ligament injury; ankle; chronic injury.*

GJMR-B Classification: NLM: QZ 220



Strictly as per the compliance and regulations of:



© 2023. Amanda Gomes Quiroga, Jose Pereira da Silva Filho, Joaquim Lucas Silva Cardoso, Valter Oliveira da Silva, Ana Beatriz de Matos Berg Abrantes, Rebeca Mendes Peres, Fabiana Caroline Coelho Carvalho Firme, Isabella Menezes Batista, Eduarda Monteiro Machado, Ana Laura Passos de Magalhães, Ulisses Tomaz Monteiro, Bruna Daher Fonseca, Marina Mota de Oliveira Madruga, Caio Lopes Oliveira, Rayssa Blenda Martins, Victor de Oliveira Bessa, Maria Alice Silva Vasconcelos, Pollyane Vieira de Almeida, Eduardo Fernandes Rodrigues, Raphael Vinicius Mendes Abreu, Adeni Ferreira dos Santos Junior, Pedro Henrique Rodrigues & Karllos Adryano Priscinotte Rodrigues Lima. This research/review article is distributed under the terms of the Attribution-NonCommercial-NoDerivatives 4.0 International (CC BY-NC-ND 4.0). You must give appropriate credit to authors and reference this article if parts of the article are reproduced in any manner. Applicable licensing terms are at <https://creativecommons.org/licenses/by-nc-nd/4.0/>.

Chronic Ankle Ligament Injury and its Clinical Management, A Literature Review

Amanda Gomes Quiroga ^α, Jose Pereira da Silva Filho ^σ, Joaquim Lucas Silva Cardoso ^ρ, Valter Oliveira da Silva ^ω, Ana Beatriz de Matos Berg Abrantes [¥], Rebeca Mendes Peres [§], Fabiana Caroline Coelho Carvalho Firme ^χ, Isabella Menezes Batista ^ν, Eduarda Monteiro Machado ^θ, Ana Laura Passos de Magalhães ^ζ, Ulisses Tomaz Monteiro ^ε, Bruna Daher Fonseca ^ε, Marina Mota de Oliveira Madruga ^{fr}, Caio Lopes Oliveira ^θ, Rayssa Blenda Martins ^ζ, Victor de Oliveira Bessa ^α, Maria Alice Silva Vasconcelos ^α, Pollyane Vieira de Almeida ^π, Eduardo Fernandes Rodrigues ^ε Raphael Vinicius Mendes Abreu ^ε Adeni Ferreira dos Santos Junior ^ε Pedro Henrique Rodrigues ^δ & Karlos Adryano Priscinotte Rodrigues Lima [§]

Abstract- Introduction: It's important to comprehend the key concepts of chronic ligament injuries to the ankle, which occur when there is deterioration or weakening and can result from recurrent or untreated trauma (AMODIO, 2013). Chronic ligament damage typically results from frequent ankle sprains. Ligaments are fibrous tissues that connect bones and provide stability for joints. In the ankle, the ligaments most commonly affected are the anterior talofibular ligament and the calcaneofibular ligament.

Methodology: This is a literature review whose bases were taken from the SciELO and PubMed data platforms. The research period was July 2023, meeting the inclusion criteria, which were articles from the years 2000 to 2023, in Portuguese and English, online texts, and full texts. The following health descriptors (DeCS) were employed as evaluation techniques for the texts: "ligamentous injury," "ankle," and "chronic."

Results: An ankle sprain, which is particularly prevalent in athletes and in those who lead active lives, is an injury that is produced, in most cases, by the eversion or inversion of the foot as a result of fast and forceful movements, with or without tearing of the ligaments (BARONI, 2010). An ankle sprain can occur with or without tearing of the ligaments. Acute ankle ligament injuries are common, with injuries to the lateral ligament complex being the most prevalent. The bone structure of the ankle joint provides stability in a neutral state. Compressive pressures applied in the weight-bearing posture increase the stability of the bone. The majority of ankle lateral ligament injuries heal on their own with conservative care, and in many instances, this type of care results in mechanical stability of the joint (LYNCH, 1999). On the other hand, persistent problems after ankle ligament injuries are not uncommon. After both conservative and surgical treatment, 10% to 30% of patients with lateral ligament injuries may experience chronic symptoms (Lynch, 1999).

Conclusion: By comprehending the various treatment modalities, it is clear that while cases of chronic ligament injuries to the ankle require surgical intervention in acutely serious cases, cases of more extensive injuries over the course of time indicate the need for different treatment modalities in order to prevent the patient's instability and progression.

Keywords: ligament injury; ankle; chronic injury.

I. INTRODUCTION

Understanding the fundamentals of chronic ligament injuries to the ankle is essential (AMODIO, 2013). These injuries occur when there is damage or weakening and can result from frequent or unresolved injuries. Typically, repetitive ankle sprains lead to chronic ligament damage. Ligaments, which are fibrous fibers that link bones, provide joint stability. The anterior talofibular ligament and the calcaneofibular ligament are the two ligaments most frequently injured in the ankle. Without medical attention or follow-up after an accident, the ligaments' natural ability to repair is greatly hampered, and the scar tissue that forms is often brittle or irregular, leading to a chronic and unstable condition (MARTINS, 2020). The treatment for this kind of damage includes conservative treatment as well as chronic treatment, which are the two types of treatment that hover over the most significant issues and situations. It is acknowledged that surgical procedures are for more serious situations where instability continues despite conservative treatment (AMODIO, 2013).

Lateral View

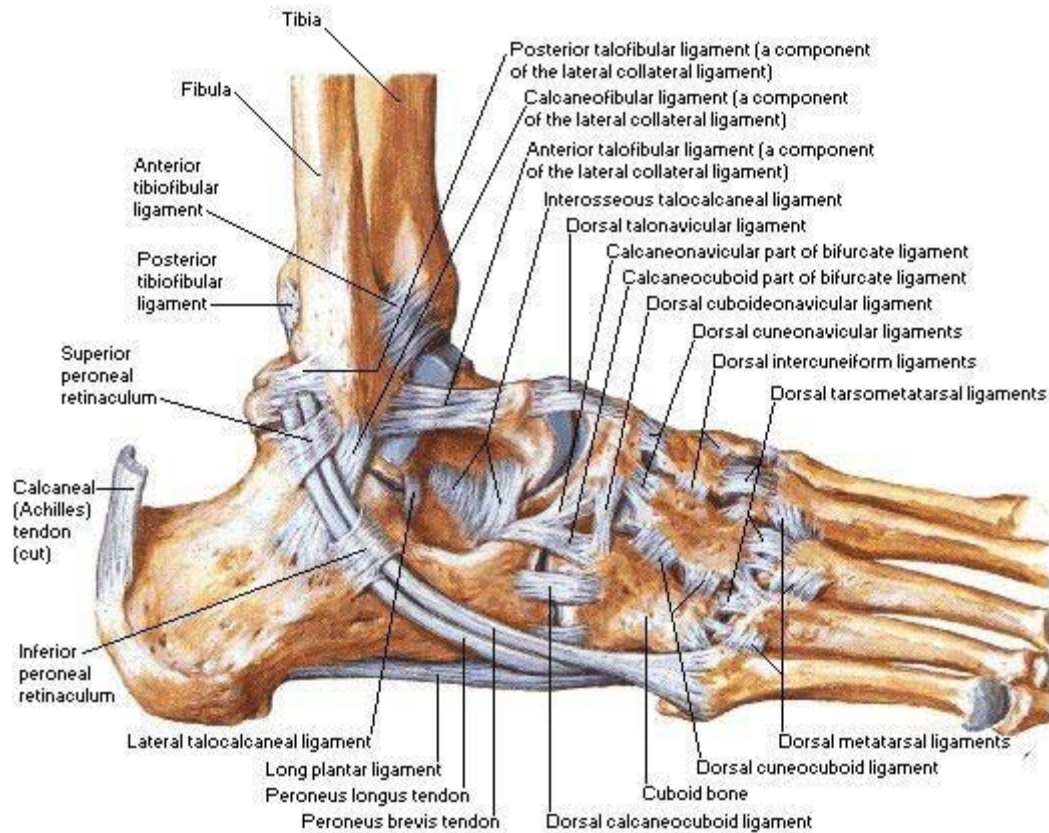


Figure 1: Ligament View, Netter 2019

II. METHODOLOGY

This study is a literature review whose bases were taken from the SciELO and PubMed data platforms. The research period was July 2023, meeting the inclusion criteria of articles from the years 2000 to 2023, in Portuguese and English, online texts, and full texts. As strategies for better evaluation of the texts, the following health descriptors (DeCS) were used: "Ligament injury", "Ankle" and "Chronic".

III. RESULTS AND DISCUSSION

Ankle sprains are common injuries among athletes and those who lead busy lives. It typically results from the foot being forced in or out suddenly and violently, and ligaments may or may not be torn (BARONI, 2010).

Acute ankle ligament injuries are frequent, with injuries to the lateral ligament complex being the most frequent. The ankle joint's bone structure provides stability in the neutral position. Compressive pressures in the body-loaded position improve bone stability. According to LYNCH (1999), the majority of lateral ankle ligament injuries heal on their own with conservative care, and according to AMODIO (2013), conservative care frequently results in mechanical stability of the joint. However, after ankle ligament injuries, lingering issues

are not uncommon. After both conservative and surgical treatment, 10% to 30% of patients with lateral ligament injuries may experience chronic symptoms (Lynch, 1999).

Chronic ankle instability brought on by lateral ligament complex injury sequelae is rather uncommon and most frequently seen after an acute ligament injury that was probably not well handled (CILLO, 1996). Other issues, such as stress fractures (especially Jone's fracture), osteochondral fractures, osteochondritis dissecans, midfoot sprains, tendinitis, or subluxation of the peroneus muscles, should be taken into consideration in individuals with persistent issues or unique symptoms (Lynch, 1999).

Six months after receiving treatment for acute ligament damage, some individuals may experience discomfort or instability. Chronic instability, osteochondral lesion, impingement with distal tibiofibular inflammatory process, and anterior impingement with exostosis are the various associated ailments that might occur, usually in decreasing order of frequency (GUIDELINES, 2008). Sistent synovitis or tendonitis, ankle stiffness, swelling, pain, muscular weakness, and repeated misalignments are among the typical symptoms. The instability of the ankle is a common factor in many of these issues. It's critical to recognize the difference between mechanical and functional ankle

instability. Mechanical instability refers to abnormal laxity of the ligament stabilizers, and functional instability refers to normal but abnormally functioning ligament stabilizers with recurrent episodes of misalignment. Isolated mechanical instability is of minimal clinical importance, but often mechanical and functional instability occur together. It is also important to consider the subtalar joint as part of the cause of instability (Lynch, 1999). Conflict syndrome is frequently present in people with CTI who have chronic pain, which affects about 60% of them. Failure to effectively treat may cause an inflammatory process to develop, which will then cause the creation of scar tissue that will occupy the area between the ligaments of the CLL (meniscoid lesion), perhaps causing local pain and inflammation to worsen (MARTINS, 2020).

It is challenging to distinguish between lateral ankle ligament instability and subtalar instability, and these issues might coexist. Chronic occurrences of ankle misalignment during physical activity, together with a history of repeated injuries and/or discomfort, edema, and stiffness, are symptoms of both conditions (Lynch, 1999).

Misdiagnosis regarding the severity of the injury, as well as patient omission of their injury, can lead to inadequate treatment and consequently chronic instability of the ATPA (CILLO, 1996). Ligament injuries are classified according to severity into grade 1, stretching of the affected ligament, and grade 2, partial injuries, without joint instability. Complete injuries are classified as grade 3, when joint stability is impaired (AMODIO, 2013).

The main goal of ankle sprain treatment is to prevent chronic ankle instability, which will later lead to fractures, ligament injuries, or both. In order to treat an ankle sprain, physiotherapeutic resources (conservative treatment) are used to promote an early return to daily activities, preventing the patient from undergoing a more aggressive surgical procedure (CRISTINA, 2001).

For the treatment of grade I and II lesions, the prognosis is excellent. Resources are used to reduce edema, such as cryotherapy, bandages, and limb elevation, followed by a period of immobilization with bands or orthoses. Subsequently, with the reduction of pain, flexibility movements begin with progressive load and proprioception (CRISTINA, 2001).

In grade III sprains, both conservative and surgical treatment are used, depending on the clinical picture. Conservative treatment is based on the use of cryotherapy, bandaging, positioning, and early mobilization. Surgical treatment consists of ligament sutures or ligament reconstruction, according to the level of rupture and joint instability (CRISTINA, 2001).

Although anamnesis and a physical exam are crucial for making a diagnosis, it's also critical to do an imaging scan to describe the lesions that are present and rule out any related illnesses. Given this, and

depending on the objective, we can turn to arthroscopy, ultrasound, MRI, and X-rays taken during load and stress (MARTINS, 2020).

Conservative treatment involves using the RICE concept (rest, ice, compression, and elevation), followed by a brief (1–2 week) period of immobilization, early joint mobilization, a gradual increase in load, and muscle strengthening activities with proprioception. This approach is usually sufficient for patients to resume their daily and sporting activities once the injury is healed. When conservative treatment does not have the desired results, or in the case of a high-level athlete, surgical treatment should be considered (MARTINS, 2020).

The need for and duration of immobilization depend on the degree of injury. A grade I sprain does not require immobilization, so we can only recommend the use of an elastic bandage for a few days. For grade II sprains, more rigid immobilization may be necessary during the first few days until the pain resolves. In cases of fractures or grade III sprains, we must control the range of motion of the joint by applying a plaster cast or immobilizing boot. (MARTINS, 2020).

To increase range of motion and lessen the possibility of muscle atrophy, physiotherapy should be started as soon as possible. This should last three to six weeks and consist of proprioception training and range-of-motion activities (MARTINS, 2020). Although there is a lack of literature concerning clinical trials related to the topic in theory, proprioceptive training's responses to stimuli cover physiological effects and provide evidence of its effectiveness in increasing joint stability and neuromuscular and balance control (ROCHA, 2023).

Final Consideration

It is clear from understanding the various treatment modalities that cases involving more extensive injuries over time necessitate different treatment modalities in order to prevent the patient's instability and progression of their ankle ligament injuries, which are chronic in nature and necessitate surgical treatment in severe cases.

REFERENCES RÉFÉRENCES REFERENCIAS

1. Renström PAFH, Lynch SA. Lesões ligamentares do tornozelo. Rev Bras Med Esporte [Internet]. 1999 Jan; 5(1): 13–23. Available from: <https://doi.org/10.1590/S1517-86921999000100004>
2. BARONI, Bruno Manfredini. Adaptações neuromusculares de flexores dorsais e plantares a duas semanas de imobilização após entorse de tornozelo. Rev Bras Med Esporte, v.16, n.5, set./out.2010. Disponível em: <http://www.scielo.br/scielo.php?script=sci_arttext&pid=S1517-86922010000500008>.
3. Horizonte B. ENTORSE DE TORNOZELO: MELHORES CONDUTAS TERAPÊUTICAS-uma

revisão narrativa [Internet]. 2016. Available from: https://repositorio.ufmg.br/bitstream/1843/BUBD-AQCGLT/1/tcc_finalizado_29_12_2016.pdf

4. Diretrizes P. Entorse de Tornozelo Autoria: Sociedade Brasileira de Ortopedia e Traumatologia [Internet]. 2008. Available from: https://amb.org.br/files/_BibliotecaAntiga/entorse-de-tornozelo.pdf
5. Cillo R. Tratamento cirúrgico das lesões ligamentares crônicas laterais do tornozelo pela técnica de Bröstrom. Revista Brasileira de Ortopedia [Internet]. 1996; 31(10). Available from: <https://www.rbo.org.br/detalhes/1888/pt-BR/tratamento-cirurgico-das-lesoes-ligamentares-cr-onicas-laterais-do-tornozelo-pela-tecnica-de-brostrom>
6. Amodio M. INSTABILIDADE MECÂNICA PÓS LESÃO LIGAMENTAR AGUDA DO TORNOZELO. COMPARAÇÃO PROSPECTIVA E RANDOMIZADA DE DUAS FORMAS DE TRATAMENTO CONSERVADOR. Revista Brasileira de Ortopedia [Internet]. 2013 [cited 2023 Jul 2]; 48(4): 307–16. Available from: <https://rbo.org.br/detalhes/1543/pt-BR/instabilidade-mecanica-pos-lesao-ligamentar-aguda-do-tornozelo-comparacao-prospectiva-e-randomizada-de-duas-formas-de-tratamento-conserva-dor->
7. Cristina E, Garcia B, Oliveira R, Patrizi V, Fernando O, Ferrari P, et al. MECANISMOS DE LESÃO DAS ENTORSES DE TORNOZELO NAS PRÁTICAS ESPORTIVAS ESPECÍFICAS [Internet]. 2001. [cited 2023 Jul 12]. Available from: <https://www.multitemas.ucdb.br/multitemas/article/download/1001/965>
8. Martins D. Instabilidade Crônica do Tornozelo [Internet]. 2020. Available from: <https://repositorio-aberto.up.pt/bitstream/10216/128479/2/411972.pdf>
9. ROCHA, Alessandra Lima da. Efeitos dos exercícios proprioceptivos na prevenção de lesões no tornozelo: uma revisão integrativa. 2023.
10. ROCHA, Alessandra Lima da. Efeitos dos exercícios proprioceptivos na prevenção de lesões no tornozelo: uma revisão integrativa. 2023.
11. BOCHI, Gabriela Silva; ALFENAS, Federal de Alfenas; GERAIS, Minas. Fatores de risco nas entorses de tornozelo em crianças e adolescentes atletas: uma revisão integrativa.
12. FERREIRA, Matheus Pouquiqui et al. FISIOTERAPIA DESPORTIVA: PREVENÇÃO E TRATAMENTO DAS ENTORSES DE TORNOZELO. Revista Multidisciplinar Saberes da Faculdade Estácio do Pantanal, v. 10, n. 1, 2022.