Volume 22 Issue 22
Originally issued as J2



Global Journal of Medical Research: J
Dentistry & Otolaryngology
Volume 22 Issue 2 Version 1.0 Year 2022
Type: Double Blind Peer Reviewed International Research Journal
Publisher: Global Journals
Online ISSN: 2249-4618 & Print ISSN: 0975-5888

Comparative Study between Endoscopic Assisted Microdebrider Adenoidectomy (EAMA) and Endoscopic Assisted Coblation Adenoidectomy (EACA): Analyzing the Intraoperative Parameters & Post-Operative Recovery

By Dr. Shrinivas S. Chavan, Dr. Naveen Kumar Singh, Dr. Vitthal D. Kale, Dr. Abhishek D. Khond, Dr. Elton C. Mendonca & Dr. Priyanka Singh

Abstract- *Background:* Adenoid hypertrophy is one of the most common causes of nasal blockage in childrento seek an otorhinolaryngologist, which is often presented as recurrent acute otitis media, sleep disordered breathing including obstructive sleep apnea (OSA), hypo apnea syndrome and chronic rhinosinusitis. Surgical adenoidectomy is a common Otolaryngology procedure recommended in children with adenoid hypertrophy not responding to medical line of management. Conventional adenoidectomy is performed blindly without visualizing the nasopharynx; which leads to complications like inadequate adenoid tissue removal, eustachian tube scarring, bleeding. This has led to development of alternate surgical methods with visualization of nasopharynx via nasal endoscopes. With the recent introduction of microdebrider and coblation in rhino surgery many surgeons prefer endoscopic guided microdebrider adenoidectomy and endoscopic guided coblation adenoidectomy.

Keywords: *nasal obstruction, adenoid hypertrophy, adenoidectomy, microdebrider, coblation.*

GJMR-J Classification: *DDC Code: E LCC Code: RF484.5*



Strictly as per the compliance and regulations of:



© 2022. Dr. Shrinivas S. Chavan, Dr. Naveen Kumar Singh, Dr. Vitthal D. Kale, Dr. Abhishek D. Khond, Dr. Elton C. Mendonca & Dr. Priyanka Singh. This research/review article is distributed under the terms of the Attribution-NonCommercial-NoDerivatives 4.0 International (CC BY-NC-ND 4.0). You must give appropriate credit to authors and reference this article if parts of the article are reproduced in any manner. Applicable licensing terms are at https://creativecommons.org/licenses/by-nc-nd/4.0/.

Comparative Study between Endoscopic Assisted Microdebrider Adenoidectomy (EAMA) and Endoscopic Assisted Coblation Adenoidectomy (EACA): Analyzing the Intraoperative Parameters & Post-Operative Recovery

Dr. Shrinivas S. Chavan [α], Dr. Naveen Kumar Singh [σ], Dr. Vitthal D. Kale [ρ], Dr. Abhishek D. Khond [ω], Dr. Elton C. Mendonca [¥] & Dr. Priyanka Singh [§]

Abstract- ***Background:*** Adenoid hypertrophy is one of the most common causes of nasal blockage in childrento seek an otorhinolaryngologist, which is often presented as recurrent acute otitis media, sleep disordered breathing including obstructive sleep apnea (OSA), hypo apnea syndrome and chronic rhinosinusitis. Surgical adenoidectomy is a common Otolaryngology procedure recommended in children with adenoid hypertrophy not responding to medical line of management. Conventional adenoidectomy is performed blindly without visualizing the nasopharynx; which leads to complications like inadequate adenoid tissue removal, eustachian tube scarring, bleeding. This has led to development of alternate surgical methods with visualization of nasopharynx via nasal endoscopes. With the recent introduction of microdebrider and coblation in rhino surgery many surgeons prefer endoscopic guided microdebrider adenoidectomy and endoscopic guided coblation adenoidectomy.

Aim: To compare intra operative parameters and post operative recovery in patients undergoing endoscopic assisted microdebrider adenoidectomy (EAMA) and endoscopic assisted coblation adenoidectomy (EACA).

Methods and results: A prospective interventional comparative clinical study between endoscopic assisted microdebrider adenoidectomy (EAMA) and endoscopic assisted coblation adenoidectomy (EACA) was conducted. A total of 30 patients were included in the study. Patients were randomized in pool A and pool B by random number allocation technique. Patients in pool A underwent EAMA and in pool B underwent EACA. Comparisons were made between pre and post operative endoscopic grades of adenoids, pre and post operative relief of associated symptoms of adenoid hypertrophy, intra operative time, intra operative blood loss along and post operative pain, results were statistically significant for EACA.

Conclusion: Even though the comfort and adequate training of surgeon as well as cost affordability by the patients would determine the choice of technique to be used for endoscopic guided adenoidectomy over conventional method as both the procedures compared in our study do justice in the completeness of removal as well as in rate of complications still we can conclude that endoscopic assisted coblation adenoidectomy (EACA) produce better results in treatment of adenoid hypertrophy not relieved with medical line of management both in intra operative and post operative parameters as compared to endoscopic assisted microdebrider adenoidectomy (EAMA). Limitations of this study was that different causes of adenoid hypertrophy were not taken into consideration and adenoid hypertrophy with associated symptoms not responding to medical line of management between the age group of 5 to 15 years were included in this study. Another limitation of this study was that objective method of nasal patency assessment like rhinomanometry was not used due to cost restraints and instead subjective method of visual analog scale of 10-point scale was used for the same. A more elaborate larger randomized studies with use of rhinomanometry would definitely be helpful to confirm or refute the same.

Keywords: nasal obstruction, adenoid hypertrophy, adenoidectomy, microdebrider, coblation.

I. Introduction

In today's era adenoidectomy & tonsillectomy are the two most commonly performed pediatric otorhinolaryngological procedures and are associated with variety of potential complications [1-3] As we all know adenoids exist as a rectangular mass of lymphatic tissue in the nasopharynx. Meyer first described this mucosa-associated lymphoid tissue in 1868 [4].They form part of the Waldeyer's ring. Adenoids with other lymphatic tissue in the nasopharynx act as the first line of defense against ingested or inhaled pathogens.[1][2] Adenoid hypertrophy is more common in children than in adults. In children, the prevalence of adenoid hypertrophy has been estimated at 34.5 percent [5]. Adenoid's hypertrophy occurs physiologically in children between the age of 6–10 years, then later regresses by the age of 16 years [6].

Author σ: Department of Otorhinolaryngology, Grant Government Medical College and Sir J.J. group of hospitals, Mumbai, India.
e-mail: drnaveen0505@gmail.com

© 2022 Global Journals

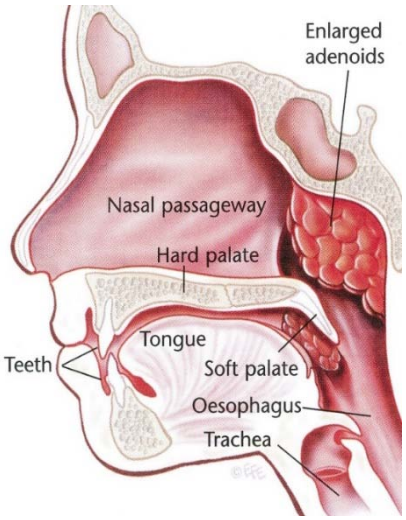

Figure 1: Adenoid hypertrophy

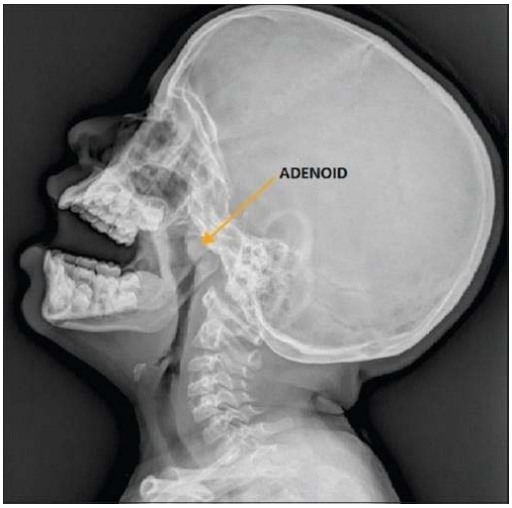

Figure 2: Endoscopic view enlargedadenoids

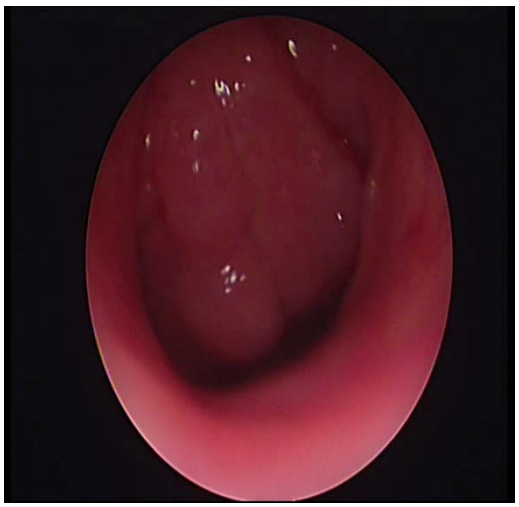

Figure 3: Lateral soft tissue radiograph X-raynasopharynx

Adenoid hypertrophy is an obstructive condition, with its symptomatology depending on the obstructed structure. Nasal obstruction by hypertrophic adenoid tissue can cause rhinorrhea, difficulty breathing through the nose, post-nasal drip, snoring, and/or sleep-disordered breathing in children like Obstructive Sleep Apnea (OSA) and hypo apnea syndrome. If the nasal obstruction is significant, the patient can suffer from sinusitis as a result and may complain of facial pain. Obstruction of the Eustachian tube can lead to symptoms consistent with Eustachian tube dysfunction such as muffled hearing, otalgia, and/or recurrent middle ear infections [7]. Although in many cases, the adenoid hypertrophy regresses with age but some cases require active intervention. Initially, these cases are managed medically but sometimes surgical intervention in form of adenoidectomy becomes mandatory in patients not responding to medical management.

Basic principle of adenoidectomy surgery is to debulk the hypertrophied adenoids and to decrease associated obstructive symptoms. The conventional adenoidectomy using saint claire Thompson adenoid curette was first described in 1885 [6]. This procedure is performed blindly without visualizing the nasopharynx; which leads to uncommon complications such as inadequate adenoid tissue removal, eustachian tube scarring, bleeding and nasopharyngeal stenosis. This has led to development of alternate surgical method where visualized resection of adenoid tissue can be done like endoscopic assisted adenoidectomy.

Canon et al. [1] popularized endoscopic assisted adenoidectomy (EAA) calling it “natural progression of endoscopic technology to allow a more complete adenoidectomy”.

With advent of endoscopic assisted adenoidectomy many newer techniques have been used for surgical debridement of adenoid tissue which includes microdebrider, diathermy, coblation. Because

© 2022 Global Journals

of the availability of varied techniques of surgical debridement under endoscopic guidance there is lack of consensus for optimal endoscopic assisted adenoidectomy (EAA). Hence in this study we would like to compare and contrast endoscopic assisted microdebrider adenoidectomy (EAMA) and endoscopic assisted coblation adenoidectomy (EACA).

II. Study Design

This is a prospective interventional and comparative study conducted between December 2020 to December 2021 in Department of Otorhinolaryngology, Grant Government Medical College and Sir J.J. group of Hospitals, Mumbai, India.

a) Inclusion criteria

1. Male and female individuals of age 5 years to 15 years suffering from associated symptoms due to adenoid hypertrophy and not getting relieved with medical line of management.
2. Individuals presenting with symptoms of chronic mouth breathing, snoring, persistent nasal discharge, recurrent upper respiratory tract infection, recurrent acute suppurative otitis media and adenoid facies.
3. Individuals with radiological and endoscopic evidence of adenoid hypertrophy.
4. Individuals willing to enroll in the study meeting the above criteria.

b) Exclusion criteria

1. Individuals with congenital facial anomalies like cleft lip, cleft palate etc.
2. Individuals with other nasal pathology like Sino nasal polyposis, Sino nasal mass etc.
3. Individuals with syndromes like Down's syndrome etc.
4. Previously operated individuals for the similar pathology.
5. Individual with bleeding disorders like sickle cell anemia, abnormal coagulation profile.
6. Individuals not willing to enroll in the study.

c) Methodology and techniques

Patients attending Otorhinolaryngology OPD in Grant Government Medical College and Sir J.J. Group of Hospitals, Mumbai, India with complaints of rhinorrhea, post-nasal drip, mouth breathing, snoring, sleep-disordered breathing, recurrent middle ear infections, recurrent upper respiratory tract infections and adenoid facies were initially screened based on inclusion and exclusion criteria as stated before. After screening, chosen patients were subjected to detailed clinical history followed by thorough clinical ENT examination after taking informed valid written consent. During ENT examination patients showing bulge / soft tissue mass in nasopharynx during posterior rhinoscopy were subjected to X ray nasopharynx lateral view for radiological evidence of adenoid hypertrophy. Diagnostic nasal endoscopy was done to rule out any other endonasal pathology other than adenoid hypertrophy and grades of adenoid hypertrophy were documented.

A total of 112 patients with above symptoms were screened and examined out of which 69 patients were found to have adenoid hypertrophy. All these patients were subjected to medical line of management in form of topical and oral nasal decongestants along with topical corticosteroids nasal spray. Among these 36 patients responded to medical line of management after 6 weeks. Remaining 33 patients were thoroughly explained about their condition, and were given an option of adenoidectomy under this study design, procedure to be performed, associated risks& need for postoperative follow up. So out of the 33 patients 3 patients gave negative consent for surgery, remaining 30 patients after receiving informed valid written consent were randomized into two pools based on random number allocation technique. Patients with odd number were allocated into POOL-A, where the patients underwent endoscopic assisted microdebrider adenoidectomy (EAMA) with irrigating blades of angle 45 degrees. Patients with even number were allocated into POOL-B, where the patients underwent endoscopic assisted coblation adenoidectomy (EACA) with PROCISE MAX wand. All the patients were operated by the same surgeon who was blinded with respect to study designs and study details.

Diagnostic nasal endoscopies of pool A and pool B along with data analysis for pre-operative and post-operative gradings of adenoid hypertrophy was performed by same investigator. Intra operative time for adenoid excision, along with blood loss was noted and compared. Pre-operative clinical signs and symptoms were compared with post-operative clinical signs and symptoms. All the patients in pool A and pool B received the same post-operative care. Patients were examined on 2nd, 7th,15th and 30th post-operative day for signs and symptoms with post-operative nasal endoscopy for grading of adenoids. Patients were examined for pre- and post-surgery for nasal patency percentage based on visual analogue scale score (VAS Score)- patients were instructed to indicate the point on the scale (1-10) that best corresponds to their severity of nasal obstruction, higher score indicates worse obstruction.

Visual Analogue Scale (VAS). VAS score out of 10 X10= VAS Score out of 100.

© 2022 Global Journals



Figure 4: Visual Analogue Scale for nasal patency percentage

Post operative pain was also measured on follow up days i.e. 2nd, 7th, 15th and 30th based on Visual Analogue Scale. It consists of a 10 cm line with two anchor points of no pain and worst pain imaginable which is self-assessed by patient.

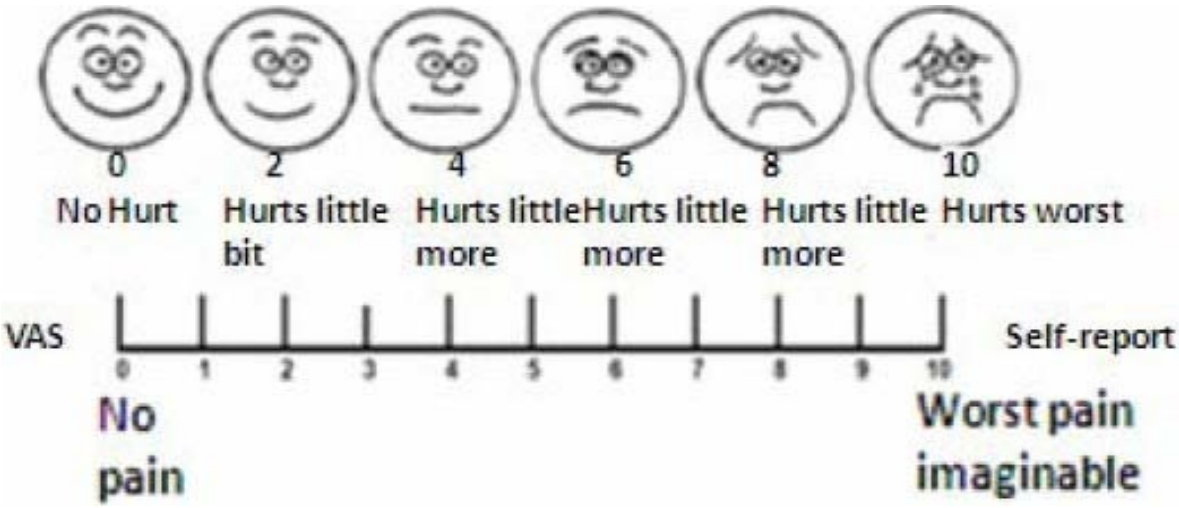

Figure 5: Visual Analogue Scale for post operative pain

d) Procedure

All procedures were performed under general anesthesia. Patients taken in supine position, painted and draped. Zero degree endoscope with a video attachment is introduced through nose and grade of adenoid hypertrophy noted and accordingly.

In Pool A,0-degree endoscope is introduced through the nose to visualize the nasopharynx, microdebrider with a 45 degrees curved blade with cutting window of which is on the convex side, is also introduced through the mouth. The instrument is connected to an aspirator and is programmed to alternate rotations, with a rotational speed of 1200 rpm. Removal of the adenoid tissue starts from the choanal vegetations and proceeds backwards along the vault towards the posterior wall of the nasopharynx. At the end of the resection, a post nasal pack is placed in that cavity for 5 minutes. After hemostasis is achieved, post nasal pack is removed under direct vision.

© 2022 Global Journals



Figure 6: Endoscopic view of microdebrider blade and its position

In Pool B, 0-degree endoscope is introduced along with coblation PROCISE MAX wand, which is connected to the controller with the default settings of 7 and 3 on the coblation and coagulation LEDs respectively. Foot pedal ablation of the adenoid tissue was activated as soon as the wand is close to the inferior edge of the adenoid, avoiding direct contact. It was made sure that wand is carefully inserted and removed without injury to uvula or soft palate.

Endoscopic check of nasopharynx was performed to ensure removal of all adenoid tissue. And if any bleeding areas were present, then they were coagulated with the wand by pressing directly on the bleeder for 2-3 seconds.



Figure 7: Procise Max Wand

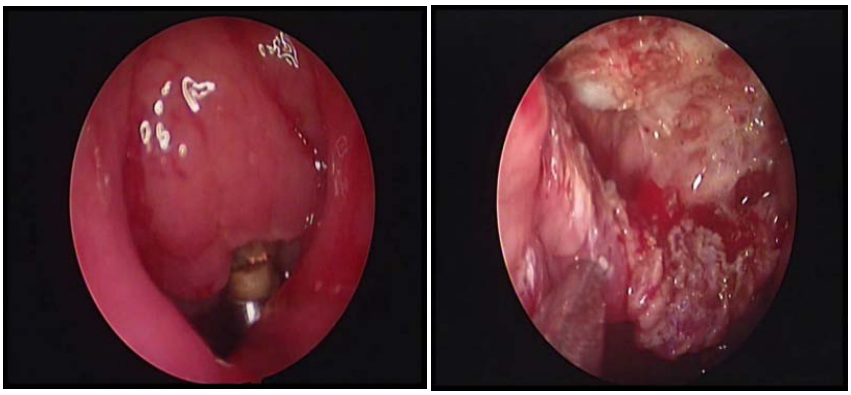

Figure 8: Endoscopic view of coblator during start of adenoidectomy and post adenoidectomy

In both pools A and B, at the end of procedure intra operative time, intra operative blood loss was recorded check nasal endoscopy was done for any residual adenoid tissue and for any bleeding points. There after similar check nasal endoscopy was done on post op day 2before discharging the patient and on subsequent follow ups that is on 7th, 15th 30th day. Similarly post op pain, post op nasal patency based on VAS score was recorded on same follow-up days.

e) Data analysis and statistical tests

All the collected data was entered in Microsoft Excel sheet. It was then transferred to SPSS ver. 17 software for statistical analysis. Quantitative data was presented as mean and standard deviation and comparison of the two study groups was done using unpaired t-Test. Pre-operative and post -operative quantitative data of each surgical technique was compared using paired t-Test. Qualitative data was presented as frequency and percentage and analyzed using chi-square test. A p-value of < 0.05 was considered as statistically significant.

© 2022 Global Journals

III. Observations and Results

In this study of 11 months duration, 112 patients were assessed in otorhinolaryngology OPD of Grant Medical College and Sir JJ group of Hospitals Mumbai, India, out of which 69 patients were found to have clinical symptoms because of adenoid hypertrophy and thereafter they were subjected to medical line of management.36 patients responded to medical line of management of 6 weeks. And remaining 33 patients whose symptoms didn't subside with medical line of management were given the option of adenoidectomy under this study design of which 3 patients gave negative consent for surgery, remaining 30 patients after receiving informed valid written consent were included in this study.

In pool A, 15 patients were operated of which 08 were males and 07 were females. In pool B, 15 patients were operated of which 09 were males and 06 were females.

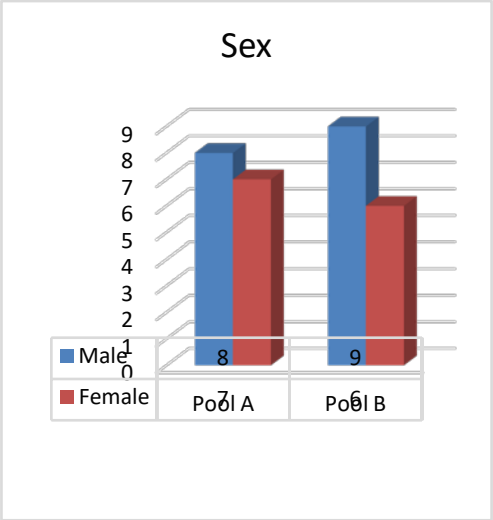

Graph 1: Distribution of patients

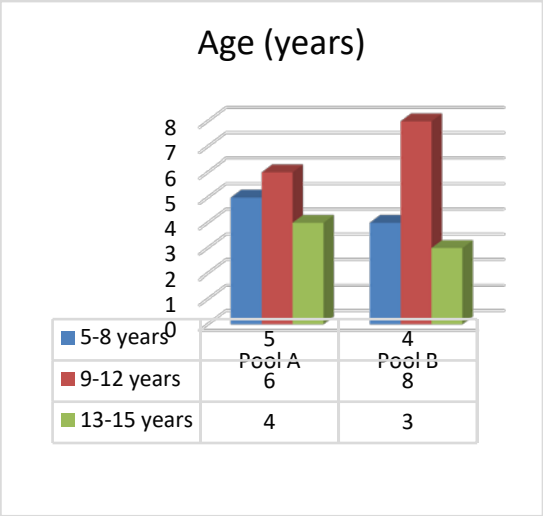

Graph 2: Distribution of patients according to Sex according to Age

Overall, mean age in Pool A was 10.20 ± 3.14 years and in Pool B was 10.27 ± 2.40 years (Graph 2).

a) Visual Analogue Scale (VAS) Score

In this study, VAS score is used for evaluation of Pre and post op nasal patency along with post op pain.

Nasal Patency: The mean pre-operative VAS score percentage in pool A was 84.60% whereas in pool B was 92.4%. During post-operative follow up, VAS score percentage in pool A on day 2nd7th, 15th, 30th were 51%, 50%, 27.80% and 26.63% respectively, and in pool B on aforementioned days were 92.4%,42.30% 40%, 26.70% and 12.70% respectively (Graph 3). The difference in VAS score percentage between pre-op and post-op values in both the groups was statistically significant as per ANOVA test *($p<0.05$).*

© 2022 Global Journals

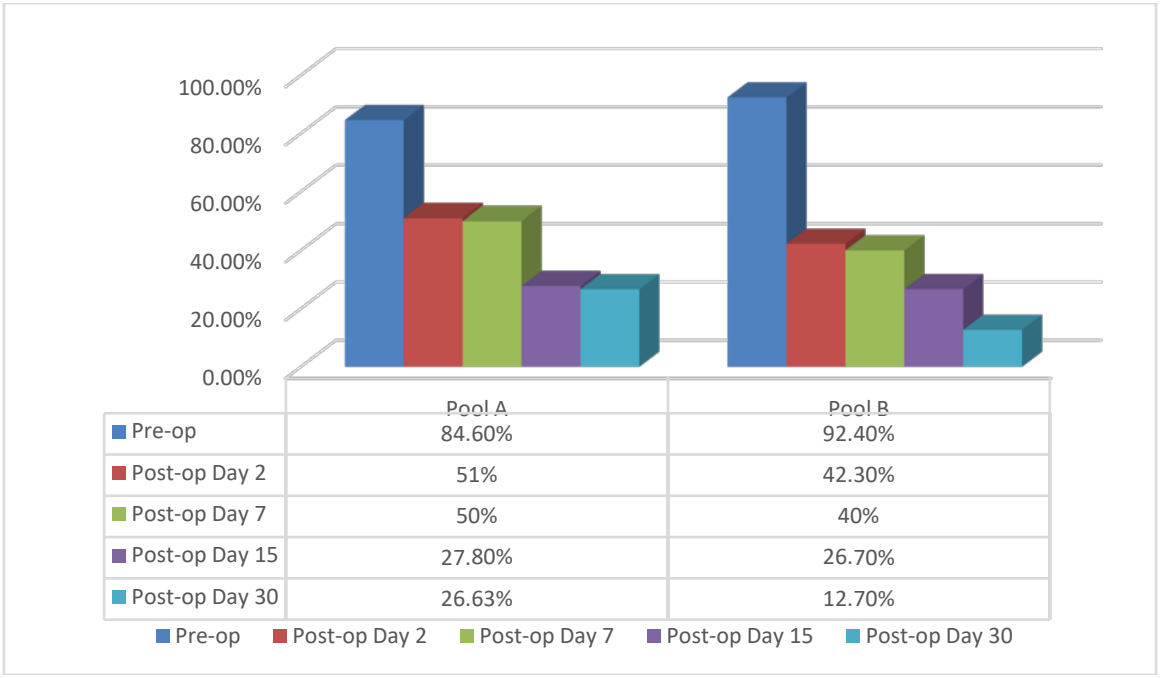

Graph 3: Distribution of patients according to nasal patency of airway based on VAS score for nasal obstruction.

VAS score for post operative pain:- Similarly, the mean VAS score for post operative pain on Post op day 2 in pool A was 7.23 +_ 0.51whereas in pool B was 7.48+_0.46. During post-operative follow ups, VAS score for post op pain in pool A on day 7th was 1.53+_0.26 and in pool B was 1.67+_0.35 which reduced to 0 for both the pools on subsequent follow up days i.e., on post op day 15th and 30th. In both the techniques VAS Score for post operative pain were compared using chi square test and the result of the test were statistically not significant with p-value > 0.05.

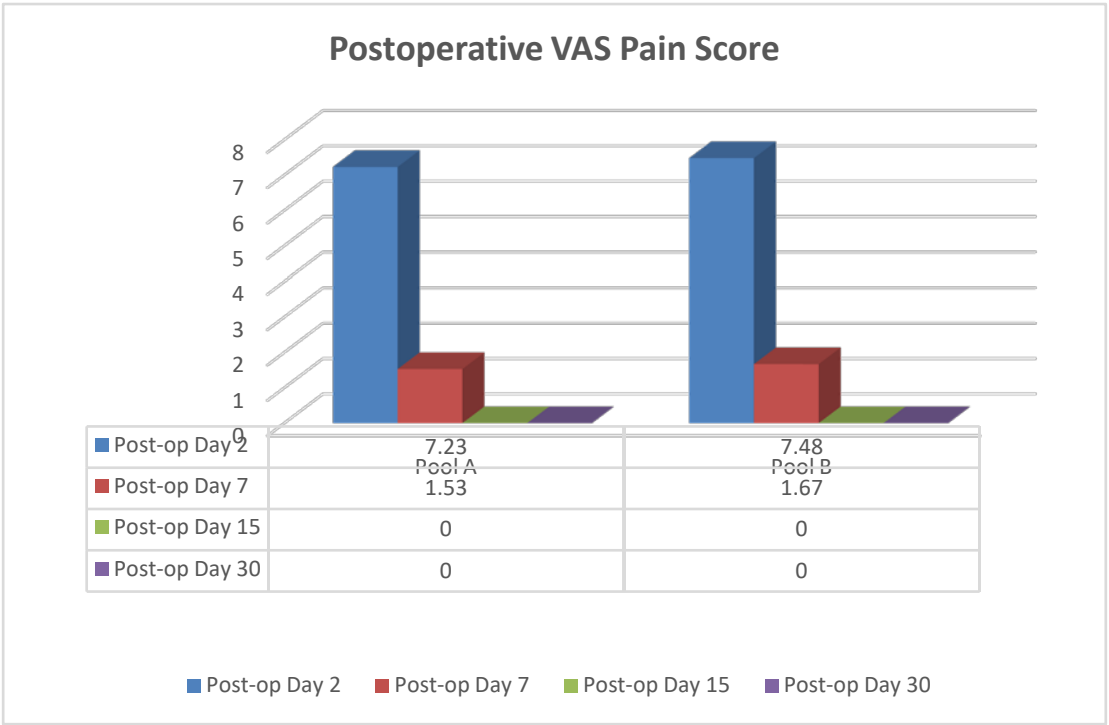

Graph 4: Distribution of patients according to post operative pain based on VAS score.

© 2022 Global Journals

b) *Duration for surgery*

Intra operative time taken in both surgery were recoded and compared, it was found that mean duration of surgery was significantly longer in Pool A compared to Pool B as per Student t-test (25.07 ± 3.79 mins vs. 17.33 ± 2.44 min sp<0.05).

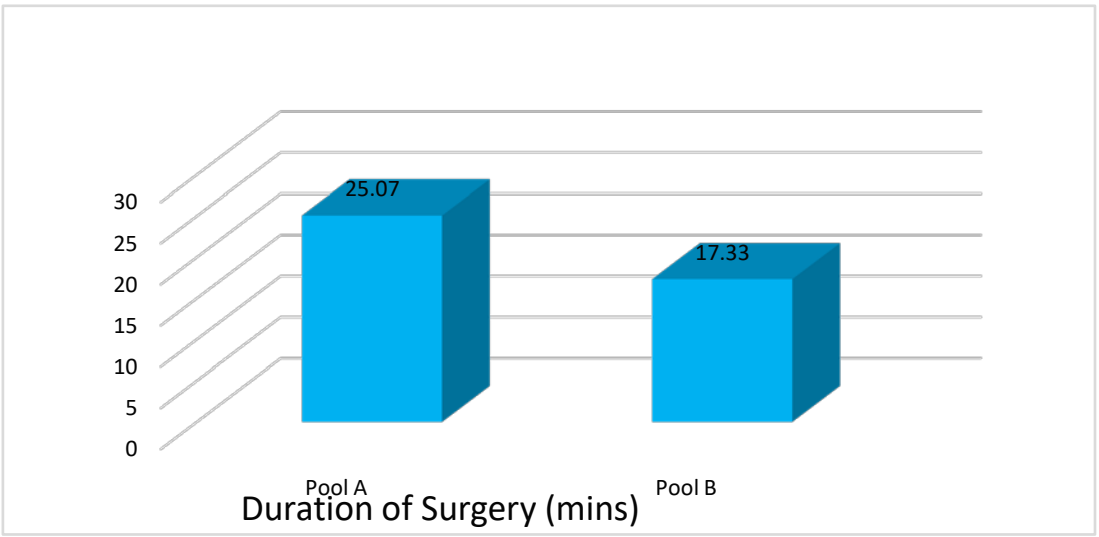

Graph 5: Comparison of Duration of Surgery in both Groups

c) *Intra Operative Blood Loss*

Similarly, intra operative blood loss calculated and it was found that mean intraoperative blood loss was significantly more in Pool A compared to Pool B as per Student t-test (51.27 ± 8.08 ml vs. 24.20 ± 4.74 mlp<0.05)

Table 1: Comparison of Intraoperative Blood Loss in both Groups

	Pool A		Pool B		p value
	Mean	SD	Mean	SD	
Intraoperative Blood Loss (ml)	51.27	8.08	24.20	4.74	<0.05

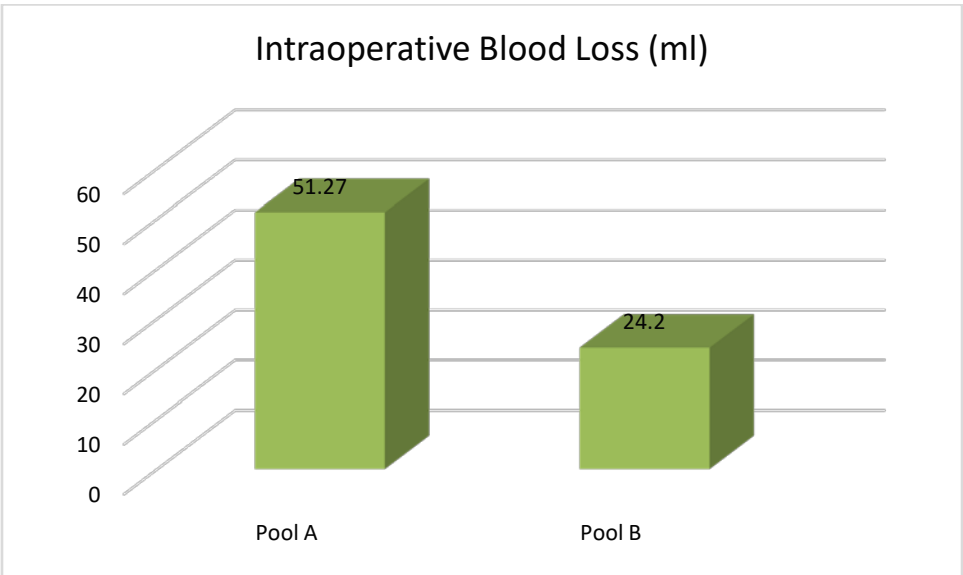

Graph 6: Comparison of Intraoperative Blood Loss in both Groups

© 2022 Global Journals

d) Nasal endoscopic findings

During nasal endoscopy of each patient on pre-operative and post-operative follow up days, Adenoids were categorized into the following 4 grades according to the percentage of adenoid tissue that causes the blockage of posterior choana

Grade I- adenoid tissue obstructs 0% to 25% of posterior choana

Grade II- adenoid tissue obstructs 26% to 50% of posterior choana

Grade III- adenoid tissue obstructs 51% to 75% of posterior choana

Grade IV- adenoid tissue obstructs 76% to 100% of posterior choana [10]

e) Grades of adenoid hypertrophy based of nasal endoscopy

It was observed in our study that Pre operative grading of adenoid hypertrophy in Pool A, by nasal endoscopy was as following, 5 (33.3%) patients was Grade 2 while it was Grade 3 and Grade 4 in 6 (40%) and 4 (26.7%) patients respectively. In Pool B, the grade of the adenoid hypertrophy in 3 (20%) patients was Grade 2 while it was Grade 3 and Grade 4 in 5 (33.3%) and 7 (46.7%) patients respectively. There was no significant difference between the groups as per Chi-Square test ($p>0.05$).

When compared with Post Op Grading on Day 30 Grade 0 were seen in 5 (33.3%) patients in Pool A and 9 (60%) patients in Pool B, grade 1 was seen in 4 (26.7%) patients in Pool A and 6 (40%) in Pool B. Grade 2 was only seen in pool A that too also in 6 (40%) patients. There was no significant difference between the groups as per Chi-Square test ($p>0.05$).

Table 2: Distribution of patients according to Pre-operative Grading of the Adenoids

Pre-operative Grading of the Adenoids	Pool A		Pool B		p value
	N	%	N	%	
Grade 1	0	-	0	-	>0.05
Grade 2	5	33.3%	3	20%	
Grade 3	6	40%	5	33.3%	
Grade 4	4	26.7%	7	46.7%	

Table 3: Distribution of patients according to Post-operative Grading of the Adenoids on Day 2, 7, 15 and 30

Post-op Grading of the Adenoids on POD 2	Pool A		Pool B		p value
	N	%	N	%	
Grade 0	3	20%	7	46.7%	>0.05
Grade 1	10	66.7%	8	53.3%	
Grade 2	2	13.3%	0	-	
Grade 3	0	-	0	-	
Grade 4	0	-	0	-	

Post-op Grading of the Adenoids on POD 7	Pool A		Pool B		p value
	N	%	N	%	
Grade 0	3	20%	7	46.7%	>0.05
Grade 1	10	66.7%	8	53.3%	
Grade 2	2	13.3%	0	-	
Grade 3	0	-	0	-	
Grade 4	0	-	0	-	

© 2022 Global Journals

Post-op Grading of the Adenoids on POD 15	Pool A		Pool B		p value
	N	%	N	%	
Grade 0	5	33.3%	9	46.7%	>0.05
Grade 1	4	26.7%	6	53.3%	
Grade 2	6	40%	0	-	
Grade 3	0	-	0	-	
Grade 4	0	-	0	-	

Post-op Grading of the Adenoids on Day 30	Pool A		Pool B		p value
	N	%	N	%	
Grade 0	5	33.3%	9	60%	>0.05
Grade 1	4	26.7%	6	40%	
Grade 2	6	40%	0	-	
Grade 3	0	-	0	-	
Grade 4	0	-	0	-	

f) Pre-Op evaluation of associated symptoms

Along with VAS score and nasal endoscopic gradings, patients were also evaluated for preoperative symptoms and relief of those symptoms post operatively. In the present study, pre operatively in Pool A all patients showed symptom of mouth breathing while 10 (66.7%) patients had snoring, 8 (53.3%) patients each had recurrent Upper Respiratory Tract Infection (URTI) and Acute Suppurative Otitis Media (ASOM) while 7 (46.7%) patients had general features of the adenoid facies. In Pool B, 12 (80%) patients each showed symptom of mouth breathing and snoring while 9 (60%) patients had URTI. 8 (53.3%) patients had facial features while 7 (46.7%) patients had ASOM. There was no significant difference between the groups as per Chi-Square test ($p>0.05$).

Table 4: Distribution of patients according to Pre-operative Symptoms

Pre-operative Symptoms	Pool A		Pool B		p value
	N	%	N	%	
Mouth Breathing	15	100%	12	80%	>0.05
Snoring	10	66.7%	12	80%	
URTI	8	53.3%	9	60%	
ASOM	8	53.3%	7	46.7%	
Adenoid facies	7	46.7%	8	53.3%	

© 2022 Global Journals

g) Post-Op evaluation of associated symptoms

Thereafter, post-operatively on Day 2, 5 (33.3%) patients in Pool A and 2 (13.33%) patients in Pool B still showed symptom of mouth breathing while 3 (20%) patients in Pool A and 2 (13.33%) patients in Pool B still had snoring. URTI was only seen in Pool A that too also with 3 (20%) patients. 8 (53.3%) patients in pool A and 7 (46.7%) patients in Pool B still had adenoid facies. There was no significant difference between the groups as per Chi-Square test ($p>0.05$).

Post-operatively on Day 7, results were similar to that of Day 2 apart from few differences as shown in the table. There was no significant difference between the groups as per Chi-Square test ($p>0.05$).

On post-operative Day 15,results were similar to that of post op day 7 only difference was in pool A, 6 patients (40%) were having complaints of snoring and in pool B, patients complaining of mouth breathing and snoring reduced to 1 that is 6.7%.There was no significant difference between the groups as per Chi-Square test ($p>0.05$).

Post-operative Day 30, all patients in Pool B continued to show relief of mouth breathing, snoring, URTI and ASOM, while 7 (46.7%) patients still had general facial features of the adenoid hypertrophy (adenoid facies). On contrary in Pool A still patients were showing symptoms like mouth breathing (20%), snoring (20%), URTI (6.7%), ASOM (6.7%), adenoid facies (53.3%). There was no significant difference between the groups as per Chi-Square test ($p>0.05$).

Table 5: Distribution of patients according to Post-operative Symptoms on Day 2, day 7, day 15, day 30

Post-operative Symptoms on Day 2	Pool A		Pool B		p value
	N	%	N	%	
Mouth Breathing	5	33.3%	2	13.33%	>0.05
Snoring	3	20%	2	13.33%	
URTI	3	20%	0	-	
ASOM	0	-	0	-	
Adenoid facies	8	53.3%	7	46.7%	

IV. Discussion

Adenoidectomy pioneered in the 19th century by Hans Wilhelm Meyer, the procedure has radically evolved over the last century [11]. And with the advent of endoscopes, surgeries in the nasal cavities have become much safer as they provide precise a traumatic dissection with lesser complications and faster postoperative healing [12] [13]. Along with many advantages there exist minor disadvantages of EAMA and EACA like the need to have a complete set of endoscopicunit, microdebrider unit and coblator unit which includes setup and maintenance cost along with that there is also longer learning curve as it requires skill and expertise to operate these units in coherence[14]

Yanagisawa and Weaver in 1997 used an endoscope along with a microdebrider through a transnasal approach and concluded that they had a completeness of clearance of adenoid with significantly lesser complications [13]. Costantini et al. in 2008, had used a 70° endoscope with video attachment introduced and a 40° microdebrider blade through the mouth to remove the adenoid and they realized that the limitation of mobility of instruments through the nasal cavity could be overcome with this approach [15]. Anand et al. in 2014 suggested that this difficulty of maneuvering the instruments can be overcome by passing the endoscope through one nostril and straight blade microdebrider through the other [16].

Even though both endoscopic assisted microdebrider adenoidectomy (EAMA) and endoscopic assisted coblation adenoidectomy (EACA) offer similar advantages over the older curettage technique, there exist subtle differences between the two which set them apart. This present study focusses to compare these two adenoidectomy procedures based on different parameters as stated before.

In this study, males outnumbered females, Pool A constituted of 53.3% male and 46.7% female patients while Pool B had 60% male and 40% female patients. Majority of the patients i.e., 40%in Pool A were in the age group of 9-12 years followed by 33.3% in the age

© 2022 Global Journals

group of 5-8 years and 26.7% in the age group of 13-15 years. The mean age of the patients in Pool A was 10.20 ± 3.14 years. Majority of the patients i.e., 53.3% in Pool B were in the age group of 9-12 years followed by 26.7% in the age group of 5-8 years and 20% in the age group of 13-15 years. The mean age of the patients was 10.27 ± 2.40 years.

The difference in the groups was statistically not significant as per Student t-test ($p>0.05$). Our study was comparable to other studies carried out by Abo Elmagd EA et al[17] where the study evaluating micro-debrider-assisted adenoidectomy and conventional curettage method found mean age of the patients was 7.27 ± 2.36 years in group A (micro-debrider-assisted) and 7.43 ± 2.87 years in Group B (conventional) and the M/F ratio was nearly equal in both groups.

In general, both the techniques were well tolerated by the patients the major difference between EAMA and EACA were found in terms of time taken for surgery and blood loss during surgery.

In the present study it was observed that the mean duration of surgery was significantly longer in Pool A compared to Pool B (25.07 ± 3.79 mins vs. 17.33 ± 2.44 mins respectively)as per Student t-test ($p<0.05$) This was also confirmed in study by Mularczyk C et al[18] which is a prospective, single-blinded, randomized controlled trial, showing mean time for coblation as 5.50 mins was significantly lower than mean time for microdebrider adenoidectomy that was 9.47 mins.

It is observed in our study that the mean intraoperative blood loss was significantly more in Pool A compared to Pool B as per Student t-test (51.27 ± 8.08 ml vs. 24.20 ± 4.74 ml $p<0.05$) and it is similar to Jaskaran S et al[19] prospective randomised single blind study which showed mean grade of intraoperative bleeding in coblator group was 1.4 ± 1.04 ml and in microdebrider group was 3.5 ± 0.9ml.

In present study, nasal patency and post operative pain was studied with the help of mean VAS score (visual analogue scale score). Although VAS score is not a standardized test for nasal patency and pain evaluation, this study found that the results of this technique correlate well with the patients' subjective sensation of nasal blockage and pain perception.

The mean pre-operative VAS score percentage for nasal patency in pool A was 84.60% whereas in pool B was 92.4%. During post-operative follow up, VAS score percentage for nasal patency in pool A on day 2nd 7th, 15th, 30th were 51%, 50%, 27.80% and 26.63% respectively, and in pool B on aforementioned days were 92.4%, 42.30% 40%, 26.70% and 12.70% respectively. The difference in VAS score percentage between pre-op and post-op values in both the groups was statistically significant as per ANOVA test ($p<0.05$). Jaskaran S et al[19] prospective randomised single blind study reported coblation group had 69 cases with good–excellent surgical field while only 1 case demonstrated poor–average surgical field. The microdebrider group reported poor–average surgical field in 37 cases while 33 cases showed good–excellent surgical field.

Similarly mean VAS score for post operative pain on Post op day 2 in pool A was 7.23+_ 0.51whereas in pool B was 7.48+_0.46. During post-operative follow ups, VAS score for post op pain in pool A on day 7th was 1.53+_0.26 and in pool B was 1.67+_0.35 which reduced to 0 for both the pools on subsequent follow up days i.e., on post op day 15th and 30th. In both the techniques VAS Score for post operative pain were compared using Student t-test and the result of the test were statistically not significant with p-value > 0.05. Jaskaran S et al[19] prospective randomised single blind study showed post-operative 24 h mean pain score was 2.6 ± 0.99 and 7.14 ± 0.99 in coblation and microdebrider group respectively. The post-operative 72h mean pain score in coblation group was 1.17±1.1 while in microdebrider group was 4.08±1.42.

In the present study, Pre operatively in Pool A, all patients showed symptom of mouth breathing i.e., 15 (100%), patients with snoring were 10 (66.7%), patients with recurrent Upper Respiratory Tract Infection (URTI) and Acute Suppurative Otitis Media (ASOM) were8 (53.3%), patients who had general facial features of adenoid facies were 7 (46.7%). In Pool B, 12 (80%) patients each showed symptom of mouth breathing and snoring while 9 (60%) patients had URTI. 8 (53.3%) patients had adenoid facies while 7 (46.7%) patients had ASOM. There was no significant difference between the groups as per Chi-Square test ($p>0.05$). As per Abo Elmagd EA et al[17] study evaluating micro-debrider-assisted adenoidectomy and conventional curettage method showed most common presenting symptoms were nasal obstruction and sleep-disordered breathing.

On post-operative evaluation on Day 2, 5 (33.3%) patients in Pool A and 2 (13.33%) patients in Pool B still showed symptom of mouth breathing while 3 (20%) patients in Pool A and 2 (13.33%) patients in Pool B still had snoring. URTI was only seen in Pool A that too also with 3 (20%) patients. 8 (53.3%) patients in pool A and 7 (46.7%) patients in Pool B still had adenoid facies. There was no significant difference between the groups as per Chi-Square test ($p>0.05$).

On post-operative Day 7 and 15, results were similar only difference was in pool A, 6 patients (40%) were having complaints of snoring and in pool B, patients complaining of mouth breathing and snoring reduced to 1 that is 6.7%. There was no significant difference between the groups as per Chi-Square test ($p>0.05$).

Post-operative Day 30, all patients in Pool B continued to show relief of mouth breathing, snoring, URTI and ASOM, while 7 (46.7%) patients still had general facial features of the adenoid hypertrophy

© 2022 Global Journals

(adenoid facies). On contrary in Pool A still patients were showing symptoms like mouth breathing (20%), snoring (20%), URTI (6.7%), ASOM (6.7%), adenoid facies (53.3%). There was no significant difference between the groups as per Chi-Square test ($p>0.05$).

This is concordant to the studies of Singh S et al[20] which is a randomized study reported at the 3-month follow-up, no residual disease was found in group II. However, in group I, 23 patients (77%) presented with residual disease causing nasopharyngeal symptoms and sleep-disordered breathing and residual disease were significantly higher with the conventional technique compared to the endoscopic procedure.

It was observed in our study that Pre operative grading of adenoid hypertrophy in Pool A, by nasal endoscopy was as following, 5 (33.3%) patients was Grade 2 while it was Grade 3 and Grade 4 in 6 (40%) and 4 (26.7%) patients respectively. In Pool B, the grade of the adenoid hypertrophy in 3 (20%) patients was Grade 2 while it was Grade 3 and Grade 4 in 5 (33.3%) and 7 (46.7%) patients respectively. There was no significant difference between the groups as per Chi-Square test ($p>0.05$).

When compared with Post Op Grading on Day 30 Grade 0 were seen in 5 (33.3%) patients in Pool A and 9 (60%) patients in Pool B, grade 1 was seen in 4 (26.7%) patients in Pool A and 6 (40%) in Pool B. Grade 2 was only seen in pool A that too also in 6 (40%) patients. There was no significant difference between the groups as per Chi-Square test ($p>0.05$).

Jaskaran S et al[19] prospective randomised single blind study showed average adenoid grade in coblation group was 3 ± 0.7 and in microdebrider group was 2.9 ± 0.6 respectively.

V. Conclusion

Even though the comfort and adequate training of surgeon as well as cost affordability by the patients would determine the choice of technique to be used for endoscopic guided adenoidectomy over conventional method as both the procedures compared in our study do justice in the completeness of removal as well as in rate of complications still we can conclude that endoscopic assisted coblation adenoidectomy (EACA) produce better results in treatment of adenoid hypertrophy not relieved with medical line of management both in intra operative and post operative parameters as compared to endoscopic assisted microdebrider adenoidectomy (EAMA). Limitations of this study was that different causes of adenoid hypertrophy were not taken into consideration and adenoid hypertrophy with associated symptoms not responding to medical line of management between the age group of 5 to 15 years were included in this study. Another limitation of this study was that objective method of nasal patency assessment like rhinomanometry was not used due to cost restraints and instead subjective method of visual analog scale of 10-point scale was used for the same. A more elaborate larger randomized studies with use of rhinomanometry would definitely be helpful to confirm or refute the same.

Acknowledgement

Not applicable.

Authorship contribution

All authors have read and approved the final manuscript. NKS and AK were responsible for investigating and evaluating cases as per inclusion and exclusion criteria. All the cases were operated by SSC. Final drafting of the article was done by NKS and AK under guidance of SSC. Entire research work was co-ordinated and supervised by VDK. Conflict of interest The authors have no conflicts of interest to declare.

Ethics approval and consent to participate

Before starting the study, ethical clearance was taken from the institutional ethical committee.
Informed consent was duly taken from patients.

Consent for publication

Not applicable.

References Références Referencias

1. Stenner M, Rudack C. Diseases of the nose and paranasal sinuses in child. GMS Curr Top Otorhinolaryngol Head Neck Surg. 2014;13:Doc10
2. Bowers I, Shermetaro C. StatPearls [Internet]. StatPearls Publishing; Treasure Island (FL): 2021. Adenoiditis.
3. Goeringer GC, Vidi B. The e mbryogenesis and anatomy of Waldeyer's ring. Otolaryngol Clin North Am. 1987; 20(2): 207-217.
4. Karanov J, Predrag M, Vladan S et al. [Cor pulmonale caused by hypertrophic adenoid glands and tonsils: indications for tonsillectomy and adenoidectomy in a 2-year-old child]. 2000; 128. 208-210.
5. Pereira L, Monyror J, Almeida FT, Almeida FR, Guerra E, Flores-Mir C, Pachêco-Pereira C. Prevalence of adenoid hypertrophy: A systematic review and meta-analysis. Sleep Med Rev. 2018 Apr; 38: 101-112. [PubMed]
6. Thornval A. Wilhelm Meyer and the adenoids. Arch Otolaryngol Head Neck Surg. 1969; 90: 383–86. [Abstract] [Google Scholar]
7. Buzatto GP, Tamashiro E, Proenca-Modena JL, Saturno TH, Prates MC, Gagliardi TB, Carenzi LR, Massuda ET, Hyppolito MA, Valera FC, Arruda E, Anselmo-Lima WT. The pathogens profile in children with otitis media with effusion and adenoid hypertrophy. PLoS One. 2017; 12(2):e0171049. [PMC free article] [PubMed]

© 2022 Global Journals

8. Regmi D, Mathur NN, Bhattarai M. Rigid endoscopic evaluation of conventional curettage adenoidectomy. *J Laryngol Otol.* 2011; 125: 53–58. [PubMed] [Google Scholar]
9. Glade RS, Pearson SE, Zalzal GH, et al. Coblation adenotonsillectomy: an improvement over electrocautery technique? *Otolaryngol Head Neck Surg.* 2006; 134: 852–855. [PubMed] [Google Scholar]
10. Cassano P, Gelardi M, Cassano M, Fiorella ML, Fiorella R. Adenoid tissue rhinopharyngeal obstruction grading based on fiberendoscopic findings: a novel approach to therapeutic management. Int J PediatrOtorhinolaryngol. 2003; 67(12): 1303–9. – PubMed
11. Datta R, Singh VP, Deshpal. Conventional versus endoscopic powered adenoidectomy: A comparative study. Med J Armed Forces India. 2009; 65(4): 308-12. doi: 10.1016/S0377- 1237(09) 80089-0
12. Anil S Harugop,1 Samanvaya Soni,1 Tejaswini J S1Efficacy and Safety of Microdebrider Assisted Adenoidectomy over Conventional Adenoidectomy Bengal Journal of Otolaryngology and Head Neck Surgery Vol. 28 No. 1 April, 2020
13. Yanagisawa E, Weaver EM. Endoscopic adenoidectomy with the microdebrider. Ear Nose Throat J. 1997; 76(2): 72-4
14. Shapiro NL, Bhattacharyya N. Cold Dissection versus coblation-assisted adenotonsillectomy in children. Laryngoscope 2007; 117(3): 406–410.
15. Costantini F, Salamanca F, Amaina T, Zibordi F. Videoendoscopic adenoidectomy with microdebrider. Acta Otorhinolaryngol Ital OrganoUff Della Soc Ital Otorinolaringol E ChirCerv-facc. 2008; 28(1): 26-9
16. Anand V, Sarin V, Singh B. Changing Trends in Adenoidectomy. Indian J Otolaryngol Head Neck Surg. 2014; 66(4): 375-80
17. Abo Elmagd EA, Khalifa MS, Abeskharoon BK et al. Comparative study between conventional adenoidectomy and adenoidectomy using micro-debrider. Egypt J Otolaryngol. 2021; 37: 56.
18. Mularczyk C, Walner DL, Hamming KK. Coblation versus microdebrider in pediatric adenoidectomy. Int J PediatrOtorhinolaryngol. 2018;104:29-31
19. Jaskaran S, Bhardwaj B. "The Comparison between Microdebrider Assisted Adenoidectomy and Coblation Adenoidectomy: Analyzing the Intraoperative Parameters and Post-operative Recovery." Indian journal of otolaryngology and head and neck surgery: official publication of the Association of Otolaryngologists of India 2020; 72(1): 59-65.
20. Singh S. Padiyar BV, Sharma N. Endoscopic-Assisted Powered Adenoidectomy versus Conventional Adenoidectomy: A Randomized Study. Dubai Med J 2019; 2: 41–45.

© 2022 Global Journals