Volume 20 Issue 24
Originally issued as J3

Global Journal of Medical Research: J
Dentistry & Otolaryngology
Volume 20 Issue 3 Version 1.0 Year 2020
Type: Double Blind Peer Reviewed International Research Journal
Publisher: Global Journals Inc. (USA)
Online ISSN: 2249-4618 & Print ISSN: 0975-5888

3D Evaluation of Soft Tissue Changes Following Class III Orthognathic Surgery- A Systematic Review

By Dr. Janani Jayapal, Dr. Abinaya Somaskandhan, Dr. Ratna Parameswaran & Dr. Devaki Vijayalakshmi

Abstract- *Background:* The principle goal of orthognathic surgery is to establish a balanced and stable dento-skeleto facial complex.This mandates the surgeon and the orthodontist to be able to predict the soft tissue changes to the orthognathic surgery precisely, which is accurately possible using 3-D imaging.

Aims: To evaluate the soft tissue changes following class III orthognathic surgery using 3-D imaging. *Settings and Design:*Systematic review.

Methods and Material: This review was conducted according to Preferred Reporting Items for Systematic Reviews and meta-Analyses guidelines systematically searching the six databases including PubMed, Cochrane, Google Scholar, LILACS, Directory of Open Access Journals, and OpenGrey.

Statistical analysis used: Not applicable.

Results: This systematic review comprises of most UpToDate evidence from eleven articles answering the review questions.

Conclusion: Le Fort I advancement shows significant increase in the alar width, alar cinch, upper lip, chelion, labiale superius, crista philtri,pronasale and subnasale. Mandibular setback shows significant backward movement of soft tissue point B, labialeinferius and subnasale and chin.

Keywords: *3-dimensional, class iii skeletal base, soft tissue, orthognathic, systematic review.*

GJMR-J Classification: *NLMC Code: WU 400*

3DEVALUATIONOFSOFTTISSUECHANGESFOLLOWINGCLASSIIIORTHOGNATHICSURGERYASYSTEMATICREVIEW

Strictly as per the compliance and regulations of:

Research | Diversity | Ethics

© 2020. Dr. Janani Jayapal, Dr. Abinaya Somaskandhan, Dr. Ratna Parameswaran & Dr. Devaki Vijayalakshmi. This is a research/review paper, distributed under the terms of the Creative Commons Attribution-Noncommercial 3.0 Unported License http://creativecommons.org/licenses/by-nc/ 3.0/), permitting all non-commercial use, distribution, and reproduction in any medium, provided the original work is properly cited.

3D Evaluation of Soft Tissue Changes Following Class III Orthognathic Surgery– A Systematic Review

Dr. Janani Jayapal [α], Dr. Abinaya Somaskandhan [σ], Dr. Ratna Parameswaran [ρ] & Dr. Devaki Vijayalakshmi [ω]

Abstract- ***Background:*** The principle goal of orthognathic surgery is to establish a balanced and stable dento-skeleto facial complex.This mandates the surgeon and the orthodontist to be able to predict the soft tissue changes to the orthognathic surgery precisely, which is accurately possible using 3-D imaging.

Aims: To evaluate the soft tissue changes following class III orthognathic surgery using 3-D imaging. Settings and Design:Systematic review

Methods and Material: This review was conducted according to Preferred Reporting Items for Systematic Reviews and meta-Analyses guidelines systematically searching the six databases including PubMed, Cochrane, Google Scholar, LILACS, Directory of Open Access Journals, and OpenGrey.

Statistical analysis used: Not applicable

Results: This systematic review comprises of most UpToDate evidence from eleven articles answering the review questions.

Conclusion: Le Fort I advancement shows significant increase in the alar width, alar cinch, upper lip, chelion, labiale superius, crista philtri,pronasale and subnasale. Mandibular setback shows significant backward movement of soft tissue point B, labialeinferius and subnasale and chin. Bi-jaw surgery for skeletal class III correction shows significant backward movement of chelion, pronasale and lower lip region whereas nasal prominence and transverse upper lip prominence significantly increased.

Keywords: 3-dimensional, class iii skeletal base, soft tissue, orthognathic, systematic review.

I. Introduction

The main intent of any orthognathic surgery is to normalize the skeletal discrepancies and facial disharmony. Orthognathic surgery, with the movement of skeletal tissues restores occlusal function and induces soft tissue changes which establishes the facial harmony which is the ultimate goal. It is of utmost importance to properly analyse and correctly diagnose the case for best treatment planning to achieve better prognosis. [1, 2] The results so obtained are known to be more stable and reliable.

Author α σ: BDS, Post graduate, Dept of orthodontics and dentofacial orthopeadics, Meenakshi Ammal Dental College, Chennai, Tamil Nadu, India. e-mails: jjanani93@gmail.com, abi.kandhan@gmail.com

Author ρ ω: BDS, MDS, Professor, Dept of orthodontics and dentofacial orthopeadics, Meenakshi Ammal Dental College, Chennai, Tamil Nadu, India. e-mails: rathu70@yahoo.com, devsara@gmail.com

Surgery for mandibular prognathism began early in the 20th century with treatment that consisted of a body ostectomy, removing a molar or premolar tooth and an accompanying block of bone. Edward Angle, described how the treatment outcomes would have been better if orthodontic appliances and occlusal splints were used. The introduction of sagittal split ramus osteotomy in 1957 marked the beginning of modern era in orthognathic surgery. Le-Fort I down fracture technique that allowed maxilla to be repositioned in all the three planes of space was a modification of the American surgeons for maxillary surgery that had earlier been developed in Europe in 1960s. By 1980s, it was possible to reposition either or both jaws in all the planes of space and acquire stable results.

Being able to predict soft tissue changes that will be encountered following surgery has been precisely possible with the advent of 3-D imaging. Movements of the jaws during surgery leads to changes in all the 3 dimensions which makes it important to analyse and interpret the treatment outcome using 3-D imaging. 3-D imaging is the best way available which gives accurate measurements in anteroposterior, supero-inferior and mesiodistal planes. Analysing the hard and soft tissues of the face in three dimensions is needed to achieve good post-operative results. [3,4] Two-dimensional analysis by radiographs and cephalometry have its own limitations as it gives the data in only 2 axis. Until now, many techniques for 3-dimensional (3D) soft-tissue analysis have been developed, including methods of moire stripes, stereophotogrammetry, 3D computed tomography, and 3D laser scanning. [5-7]

The primary objective of this systemic review is to systematically investigate and evaluate 3 dimensionally the soft-tissue changes in Class III orthognathic patients which includes Le Fort I maxillary advancement, Bilateral sagittal split osteotomy with mandibular setback and a combination of these. The study was divided into 2 parts: (1) evaluating the relationship between soft tissue and skeletal movements in class III orthognathic surgeries, and (2) to determine which of the soft tissue region undergo most changes.

© 2020 Global Journals

II. Materials and Methods

a) Protocol and Registration

This review was based on a specific protocol developed and piloted following the guidelines outlined in the Preferred Reporting Items for Systematic Reviews and Meta-Analyses (PRISMA) P statement.[8-10]

b) Eligibility Criteria

Eligibility criteria was based on the research question defined in the PICO format. Do patients who have undergone mandibular setback or maxillary advancement or a combination of both (P) and evaluated using 3D imaging techniques (I) exhibit before and after (C) changes in the facial soft tissues(O).

The inclusion criteria primarily composed of human clinical trials, patients of either sex who were over the age of 18 years, who had undergone single jaw and bi-jaw orthognathic surgeries for class III correction, had 3-D records, Data published in 2009-2019 which have been published in English.

The exclusion criteria included animal or in vitro studies, narrative or literature reviews, and case reports and series, patients who have cleft lip and palate, craniofacial disorders, degenerative conditions, trauma, temporomandibular joint pain, previous orthognathic surgery, inflammatory conditions, degenerative conditions, facial asymmetries.

c) Search Strategy for Identification of Studies

A detailed search was carried out in two parts. Firstly, an electronic search was carried out based on a search strategy developed on PICO format and was checked using the PRESS checklist for systemic reviews. The search terms include controlled vocabulary, author keywords, Boolean operators, and truncations which were appropriately used and revised for each database, considering the differences in controlled vocabulary and syntax rules. The following electronic databases were searched: PubMed, Google Scholar, LILIACS, Cochrane registry of clinical trials, and Directory of Open Access Journals, and unpublished literature was searched on opengrey.eu.

The second part of the search was hand search of the relevant orthodontic journals. The following journals were searched:

- American Journal of Orthodontics and Orthopedics
- British Journal of Orthodontics (Journal of Orthodontics)
- European Journal of Orthodontics
- Journal of Indian Orthodontic Society
- Korean Journal of Orthodontics
- The Angle Orthodontist
- World Journal of Orthodontics
- Journal of Cranio-Maxillo-Facial Surgery
- American association of oral and maxillofacial surgeons
- International Journal Oral and Maxillofacial Surgery

The hand search included screening of contents, title, and abstracts done to identify all relevant studies in the above-mentioned journals from January 2009 to December 2019. The reference lists of all eligible studies were hand searched for additional studies (Figure 1). Study selection after the duplicate references were removed using references software (MENDELEY 1.19.2, Elsevier, 2018, New York, USA).

© 2020 Global Journals

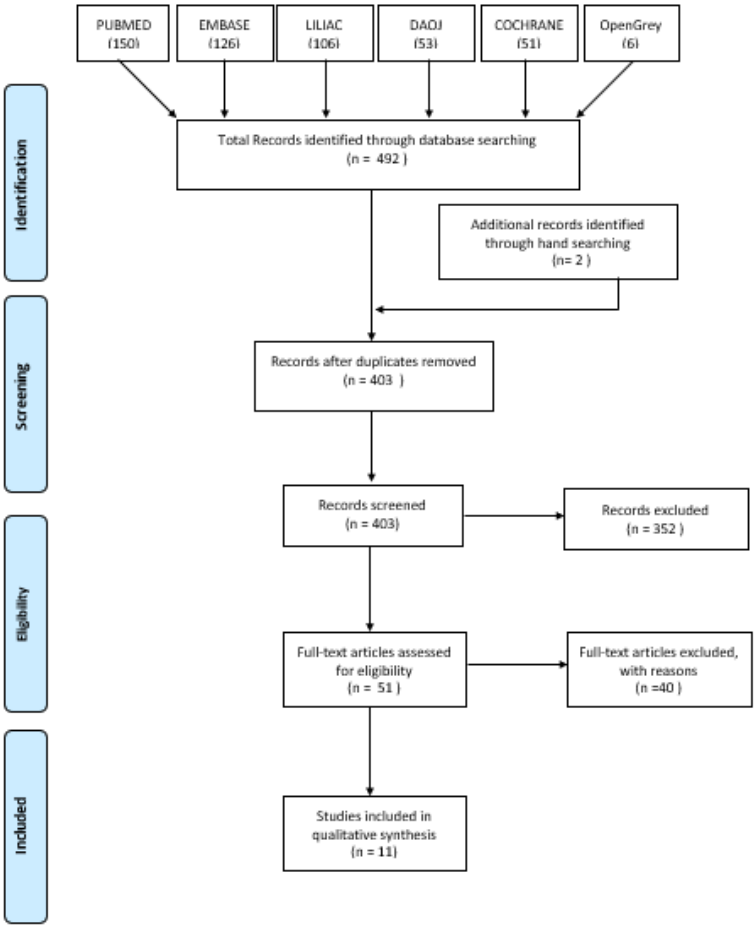

Figure 1: Prisma Flow Chart

d) Assessment of Risk of Bias

Two review authors (J.J and A.S) independently assessed the risk of bias of the eligible trials according to the Cochrane Collaboration's risk of bias tool. In cases of discrepancy, consensus was obtained by consulting a third reviewer (R.P). The domains assessed were (1) random sequence generation; (2) allocation concealment; (3) blinding of participants; (4) blinding of personnel; (5) blinding of outcome assessment; (6) incomplete outcome data; (7) selective reporting; (8) other biases (baseline imbalance, similarity in using cointerventions between groups, and inadequate statistical analysis). The potential risk of bias for each study was classified as high, unclear, or low. (Figure 2)

© 2020 Global Journals



Figure 2: Risk of Bias

e) Data Extraction

The studies were assessed for inclusion independently by two authors (J.J. and A.S.) who were not blinded to the identity of the authors of the studies, their institutions, or the results of their research. Study selection procedures comprised reading of titles, abstracts, and full texts. After they excluded non-eligible studies, the full report of publications considered eligible for inclusion by either author was obtained and assessed independently. In case of disagreements between the authors (J.J. and A.S.), consultations with another author (R.P) was held. A record of all decisions on study identification was kept.

© 2020 Global Journals

III. Results

The results of this systematic review are detailed and tabulated in Table 1 with eleven included articles which answer the review questions.

S. No	Author	Journal name/ Year	Aim	Sample	Intervention	Results
1	Hyoung-SeonBaik et al.[1]	American Journal of orthodontics and Dentofacial Orthopedics (2010)	The purpose of this study was to use a 3-dimensional laser scanner to evaluate the soft-tissue changes after the correction of skeletal Class III malocclusions with orthognathic surgery.	20 Korean patients with skeletal Class III malocclusion who underwent LeFort I osteotomy with maxillary advancement and posterior nasal spine impaction, along with bilateral intraoral vertical ramus osteotomy for mandibular setback. -10 patients (group1) had 2-jaw surgery with genioplasty, and the other 10 (group 2) had 2-jaw surgery without genioplasty.	Three-dimensional images of thepatients were acquired with a 3D laser scanner.	-There was no significant difference between the groups in the horizontal ratios of the soft-tissue to hard-tissue changes. -There was no significant difference between the groups in the horizontal ratios of the soft-tissue to hard-tissue changes. -In both groups, the ratios of the horizontal changes in the paranasal area were higher than in the subnasale area. There were more changes in the subalar area than in the supracommissural area, and more changes in the chin and labiomental areas than in the subcommissural area. -Ala moved anterolaterally, and cheilion moved posteroinferiorly. The distance between upper-lip point and cheilion increased significantly. -In the 3D angles, transverse nasal prominence and transverse upper lip prominence increased significantly.
2.	Yong-Kyu Lim et al.[6]	Angle Orthodontist (2010)	To evaluate whether mandibular setback surgery for Class III patients would produce gradients of three-dimensional soft tissue changes in the vertical and transverse aspects.	26 Class III patients treated with mandibular setback surgery using bilateral sagittal split ramus osteotomy.	Lateral cephalograms and 3D facial scan images were taken before and 6 months after the surgery, and changes in landmarks and variables were measured.	-Landmarks of the nose, mouth, and lips did not show any significant changes in position in the transverse direction. However, in the vertical direction and anteroposterior direction, there were significant changes in the positions of the landmarks with different patterns.
3.	Kyung-Min Oh et al.[12]	Journal of Cranio-Maxillo-Facial Surgery (2012)	To evaluate Post-operative soft tissue changes in patients with mandibular prognathism after bimaxillary surgery.	25 patients before bimaxillary surgery (T0), at 2 months after surgery (T1) and at 6 months after surgery (T2).	Cephalometric variables from the reoriented volumetric images were measured and compared at T0, T1, and T2.	-The soft tissue in middle third of face moved forward at T1 and significantly moved backward from T1 toT2. -Most of the soft tissue changes from T1 toT2 were not correlated with the hard tissue changes, while the cheeks were positively correlated with the soft tissue around them.
4.	Bo-Ram Kim et al.[11]	International Journal of Oral Maxillofacial surgeons (2013)	The purpose of the study is to quantify the soft tissue changes after orthognathic surgery in 1 and 2 jaw surgery, in mandibular prognathism patients.	25 patients were assessed, who had undergone bimaxillary surgeries and those who had only undergone mandibular setback surgery.	Superimposition of pre and post volumetric images. (CBCT)	-Soft tissue changes were more evident in the midfacial area in 2-jaw group. -Soft tissue in lower third changed in both groups but not significantly.
5.	Verdenik et al.[13]	International Journal of Oral Maxillofacial Surgeons (2014)	To verify post operative changes within those regions not directly affected by surgical movements of underlying jaw bones.	83 young adults with skeletal class III deformities divided into 3 groups- BSSO setback, Le Fort I advancement of maxilla and a combination of both.	Pre and post optical scans were used and their difference were measured.	-Difference between left and right sides were very minimal. -Lefort I group encountered significantly greater changes in the cheek, nose and upper lip regions as compared to the combination group. -In contrast, chin and lower lip region was shown to encounter changes both in BSSO and combination and also in the Le Fort group, but was significantly smaller. -In the submandibular region, soft tissue changes was greater in the combination group, followed by BSSO and Le Fe Fort I respectively.

© 2020 Global Journals

© 2020 Global Journals

6.	Raghu Devanna et al.[14]	Journal of Dentistry and Oral Biology (2017)	To compare and evaluatehard and soft tissue midface dimensions of Class I and Class III individuals using CBCT	30 Class I and 30 Class III CBCT images between the age group of 14-20 years were included in the study.	The CBCT images were analyzed with creation of hard and soft tissue slices.	The Class I male horizontal slices had smaller measurements ($P<0.05$) in both the soft and hard tissue than Class III by 0.4 mm to 1.5 mm at nearly nine measurements of PPA. The Class III sample pattern profile measurements were larger by 0.6 mm to 1.7 mm. The laterality measurements also found to be larger for the Class III as compared to Class I.
7.	Junho Jung et al.[2]	Head & Face Medicine (2018)	To evaluate the nasolabial soft tissue change three-dimensionally after orthognathic surgery, using a structured light scanner.	Thirty-two malocclusion patients, who underwent orthognathic surgery, were evaluated	CBCT and 3D facial scans were obtained before surgery and 3 months after surgery.	-In the Le Fort I advancement patients, the nasal tip moved 17% forward, compared to the maxillary bony movement, but the nasal prominence decreased 15%. -The alar width increased 4 mm after the advancement. -The relative ratio of the soft tissue movement to the bony movement after bilateral sagittal split osteotomy was about 21% at the Li point in the anteroposterior direction.
8.	Lun-Jou Lo et al.[7]	PLOS ONE (2018)	To investigate the relationship between soft and hard tissue movements in different facial regions through CBCT.	24 patients with class III malocclusion, and the status of undergoing two-jaw orthognathic surgery	Preoperative and postoperative CBCT images were superimposed using the surface registration method	-Changes in the upper lip, upper vermillion, chin region in the bijaw group was found to be significant.
9.	Rahul Tiwari et al.[15]	The Open Dentistry Journal (2018)	To assess and compare pre and post-operative perioral soft tissue changes of lip width, nasolabial and mentolabial angle using CBCT.	10 patients for evaluation requiring orthognathic surgical procedures maxillary or mandibular anteroposterior excess or deficiency, transverse deformities, vertical maxillary excess and facial asymmetry.	Using Three Dimensional Computed Tomography scan before and after surgery.	-Significant changes were observed in nasolabial angle after maxillary advancement (1.81°). -The mentolabial angle was significantly increased with mandibular setback procedures (3.27°).
10.	Vittert Katina et al.[16]	Int. J. Oral Maxillofac. Surg. (2018)	The aim of this study was to perform a Systematic analysis Of images from post Surgical orthognathic surgery.	40 orthognathic surgery patients were included, who underwent three different types of surgical correction: Le Fort I maxillary advancement, bilateral Sagittal split mandibular advancement, And bimaxillary advancement surgery.	Using 3d facial images of CBCT.	-The primary characteristic of the difference in shape was found to be residual mandibular prognathism in patients who underwent Le Fort I maxillary advancement.
11.	Kyung-A Kim et al.[5]	Progress in Orthodontics (2019)	To determine 3-dimensional soft tissue changes according to skeletal changes after mandibular setback surgery by using CBCT	Twenty-eight adult Korean patients with skeletal Class III malocclusion treated by mandibular setback were evaluated.	CBCT and facial scan images were recorded one week before and six months after surgery.	-In the transverse axis, there were significant changes and correlations in the lips and chin and an increasing gradient of ratios from the lower lip to the chin. In the anteroposterior axis, the lower lip and chin moved backward significantly. -In the vertical axis, significant upward movement was observed in the landmarks related to the chin.

IV. Discussion

Orthognathic correction of malocclusion is intended to improvise the overlying soft tissue discrepancies chiefly. Wherefore, estimation of soft tissue correction that will be achieved post movement of skeletal tissue following orthognathic surgery becomes crucial. In the present systematic review, soft tissue changes have been estimated using the studies which made use of the 3-dimensional x-ray imaging in orthognathic correction of class III skeletal base with Le Fort I maxillary advancement, bilateral sagittal split osteotomy with mandibular setback and a combination of both.

Three studies of the eleven evaluated the soft tissue changes post Le-Fort I advancement surgery, by Verdenik et al. (2014) using optical scans, Vittert et al. (2018) and Junho Jung et al.(2018) using 3-D facial images of CBCT have shown to acquire significant changes in the alar width, alar cinch,pronasale, subnasale, upper lip, chelion, labiale superius, crista philtri.[2,13,16] Study by Junho et al. have reported 2.4 mm of forward movement in point 'A'. In the upper lip, the percentage of the soft tissue movement compared to the bony movement was 14–31%. In the nasal area, the ratio was 18–48%, which was higher than the lip area. However, the nasal tip movement was the least among the nasal areas. The relative ratio of the soft tissue movement to the bony movement in the anteroposterior direction after Le Fort I advancement osteotomy was found to be 18% in the pronasale, 33% in the alar area, 29% in the alar cinch area, 21% in the labiale superius, 31% in the crista philtri, 47% in the chelion, 8% in the lateral vermilion border of the lower lip.[2]And the vertical parameters revealed that there was significant amount of lower facial height reduction.[13,16]

Six out of the 11 studies evaluated by Yong-Kyu Lim et al. (2010) using lateral cephalograms and 3-D facial scans, Bo-Ram Kim et al. (2013) using CBCT images, Verdenik et al. (2014) using optical scans, Vittert et al. (2018),Junho Jung et al.(2018) and, KyungA Kim et al. (2019) using 3-D facial images of CBCT assessed thesoft tissue changes following BSSO setback surgery.[2,5,6,11,13,16] Of the 6 studies, 2 studies, 1done by Bo-Ram Kim et al. which compared 1-jaw (mandibular setback) and 2-jaw (combination) and one by Junho Jung et al, which compared Le Fort I advancement and BSSO setback surgeries reported significant backward movement of soft tissue point B, labialeinferius and subnasale.[2,11] Junho Jung et al reported 4.85mm of point 'B' and 4.3mm of labialeinferius positioned backwards post surgery.[2] Two other studies, by Yong-Kyu Lim et al. and Kyung-A Kim et al., assessed soft tissue changes post mandibular setback in all the 3 planes of space.[5,6] In the transverse plane, significant changes were encountered in lips (labiale superius, stomion, chelion, labialeinferius) and chin (B', Pg', Me') but there was no significant change found in the nose and cheek region. In the sagittal plane, significant backward movement of lip and chin was evident (labiale superius, stomion, chelion, labialeinferius, Pg', B') but no change in the nose and cheek region. In the vertical plane, there was significant upward movement of chin (B', Pg', Me') and no change in the nose, lip and cheek. Significant decrease in the lower facial height (-2.17) and lip width (1.97) was evident.[5,6]And 2 studies by Verdenik et al. and Vittert et al. assessed all the three surgeries and reported significant changes in the nose, cheek and the upper lip areas in the combination group, however not significant. Lower lip and chin region showed significant changes in the BSSO and combination surgery groups. [13,16]

Six out of eleven studies assessed changes in response to bi-jaw surgery for correction of skeletal class III.[1,7,11,12,13,16]3 of the 6 studies by Lun-Jou Lo et al. (2018), Kyung-Min Oh et al. (2013) using volumetric images evaluated 2-jaw surgical correction of skeletal class III patients, Bo-Ram Kim et al. (2013) using CBCT images compared 1-jaw and 2-jaw surgeries and found significant changes in the upper lip, upper vermillion region and cheeks.[7,11,12] Bo-Ram et al. reported 1.5mm of forward movement of upper lip, 3mm of cheeks and 1.2mm of backward movement of chelion and 0.7mm by pronasale.[11] One study of the six, Hyoung-Seon Baik et al. (2010) evaluated soft tissue changes following 2- jaw surgery with and without genioplasty using 3-D laser scan reported no significant changes in the horizontal plane between the two groups. As presumed, Pg and Me movement was smaller in the group without genioplasty. In both the groups, inter-endocanthion distance, nasal width and lower two thirds significantly decreased and nasal prominence and transverse upper lip prominence significantly increased. On comparing pre and post-surgery, significant changes were seen in stomion, labialeinferius, B', Pg', Go'.[1] Only 2 of the 6 studies assessed by Verdenik et al. (2014) and Vittert et al. (2018), compared all the three surgical modalities undertaken for correction of skeletal class III using optical scans and 3-D facial images of CBCT respectively and reported significant changes in the nose, cheek and the upper lip areas following surgery, however not significant. Lower lip and chin region showed significant changes in the bi-jaw groups.[13,16]

V. Conclusion

The following conclusions can be made:

– Le Fort I advancement shows significant increase in the alar width, alar cinch, upper lip, chelion, labiale superius, crista philtri, pronasale and subnasale.

© 2020 Global Journals

– Mandibular setback shows significant backward movement of soft tissue point B, labialeinferius and subnasale and chin (B', Pg', Me').
– Bi-jaw surgery for skeletal class III correction shows significant backward movement of chelion, pronasale and lower lip region whereas nasal prominence and transverse upper lip prominence significantly increased.

Bibliography

1. Hyoung-SeonBaik and Soo-Yeon Kim. Facial softtissue changes in skeletal Class III orthognathic surgery patients analyzed with 3-dimensional laser scanning. American Journal of Orthodontics and Dentofacial Orthopedics 2010; 2:167–178.
2. Junho Jung, Chi-Heun Lee, Jung-Woo Lee and Byung-Joon Choi. Three-dimensional evaluation of soft tissue after orthognathic surgery. Head & Face Medicine 2018; 14:21.
3. Jan Rustemeyer and Alice Martin. Soft tissue response in orthognathic surgery patients treated by bimaxillary osteotomy: cephalometry compared with 2-D photogrammetry. Oral Maxillofac Surg. 2013; 1:33–41.
4. Chun-MingChen. Soft-tissue profile changes after orthognathic surgery of mandibular prognathism. The Kaohsiung Journal of Medical Sciences. 2012; 4:216-219.
5. Kyung-A Kim, Ye-Jin Chang, Su-Hyun Lee, HyunJoon An and Ki-Ho Par. Three-dimensional soft tissue changes according to skeletal changes after mandibular setback surgery by using conebeam computed tomography and a structured light scanner. Progress in Orthodontics 2019; 1:20:25.
6. Yong-Kyu Lim; Eun-Hye Chu; Dong-Yul Lee; IlHyung Yang; Seung-HakBaek. Three-dimensional evaluation of soft tissue change gradients after mandibular setback surgery in skeletal Class III malocclusion. Angle Orthodontist, 2010;5:896-903
7. Lun-Jou Lo, Jing-Ling Weng, Cheng-Ting Ho, HsiuHsia Lin. Three-dimensional region-based study on the relationship between soft and hard tissue changes after orthognathic surgery in patients with prognathism. PLOS ONE, 2018; 8:1-15.
8. Shamseer L, Moher D, Clarke M, Ghersi D, Liberati A, Petticrew M, et al. Preferred reporting items for systematic review and meta-analysis protocols (PRISMA-P) 2015: Elaboration and explanation. BMJ 2015; 349:1-25
9. Higgins JP, Green S. Cochrane Handbook for Systematic Reviews of Interventions Version 5.1.0. Cochrane Collaboration; 2011; 8:1-674.
10. Liberati A, Altman DG, Tetzlaff J, Mulrow C, Gøtzsche PC, Ioannidis JP, et al. The PRISMA statement for reporting systematic reviews and meta-analyses of studies that evaluate health care interventions: explanation and elaboration. J Clin Epidemiol 2009; 10:1-34.
11. Bo-Ram kim, Oh KM, Cevidanes LH, Park JE, Sim HS, Seo SK, Reyes M, Kim YJ, Park YH. Analysis of 3-D soft tissue changes after 1 and 2-jaw orthognathic surgery in mandibular prognathism patients. American association of oral and maxillofacial surgeons 2013;71:151-161
12. Kyung-Min Oh, Sung-Kyung Seo, Jeong-Eon Park, Hyoung-Seob Sim, Lucia H.S. Cevidanes, Yoon-Ji R. Kim, Yang-Ho Park. Post-operative soft tissue changes in patients with mandibular prognathism after bimaxillary surgery. Journal of Cranio-MaxilloFacial Surgery 2013;41:204-211
13. M. Verdenik, N. IhanHren. Differences in three dimensional soft tissue changes after upper, lower, or both jaw orthognathic surgery in skeletal class III patients. Int. J. Oral Maxillofac Surg. 2014; 6:1-7.
14. Raghu Devanna*, Yousef Al-thomali. Comparative Evaluation of Hard and Soft Tissue Midface Dimensions of Class I and Class III Individuals Using CBCT.IP Indian Journal of Orthodontics and Dentofacial Research.2017;2:92-97.
15. Rahul Tiwari, P. Srinivas Chakravarthi. A Perioral Soft Tissue evaluation after Orthognathic Surgery Using Three-Dimensional Computed Tomography Scan. The Open Dentistry Journal, 2018, 12, 366-376.
16. L. Vittert, S. Katina, A. Ayou, B. Khambay. Assessing the outcome of orthognathic surgery by three dimensional soft tissue analysis. Int. J. Oral Maxillofac. Surg. 2018; 12:1587-1595.

© 2020 Global Journals