Volume 20 Issue 34
Originally issued as H3

Global Journal of Medical Research: H
Orthopedic and Musculoskeletal System
Volume 20 Issue 3 Version 1.0 Year 2020
Type: Double Blind Peer Reviewed International Research Journal
Publisher: Global Journals Inc. (USA)
Online ISSN: 2249-4618 & Print ISSN: 0975-5888

Removal of Broken Intramedullary Femoral Nail with Broken Distal Locking Bolt- A Case Report

By Prof. Sanjeev Sharma, Dr. Suman Sharma, Dr. Manorma Singh & Dr. Rahul Sharma

Abstract- Non-union after closed femoral interlock nailing is an uncommon complication and occurs when a patient starts early weight-bearing, due to faulty surgical technique or after re-trauma. Removal of broken with broken locking bolt is a difficult and challenging procedure. The present case report deals with a case of the broken intramedullary nail with a broken distal locking bolt. A 30 years male patient was inserted interlocking nail for fracture shaft femur five years back. He presented with pain with instability and inability in weight-bearing after re-trauma. An X-ray revealed a broken nail with a broken distal locking bolt. The far fragment of the broken bolt was engaging bone and nail both and was the main obstacle. His nail with the broken bolt removed and re-nailing did in a single sitting. Steinmann pin (St.pin) was inserted through the distal piece of the nail to push the trapped small screw piece.

Keywords: *broken nail, broken locking bolt, implant removal.*

GJMR-H Classification: *NLMC Code: WE 185*

REMOVALOFBROKENINTRAMEDULLARYFEMORALNAILWITHBROKENDISTALLOCKINGBOLTACASEREPORT

Strictly as per the compliance and regulations of:

Open Association of Research Society, USA
Research | Diversity | Ethics

© 2020. Prof. Sanjeev Sharma, Dr. Suman Sharma, Dr. Manorma Singh & Dr. Rahul Sharma. This is a research/review paper, distributed under the terms of the Creative Commons Attribution-Noncommercial 3.0 Unported License http://creativecommons.org/licenses/by-nc/3.0/), permitting all non-commercial use, distribution, and reproduction in any medium, provided the original work is properly cited.

Removal of Broken Intramedullary Femoral Nail with Broken Distal Locking Bolt– A Case Report

Prof. Sanjeev Sharma [α], Dr. Suman Sharma [σ], Dr. Manorma Singh [ρ] & Dr. Rahul Sharma [ω]

Abstract- Non-union after closed femoral interlock nailing is an uncommon complication and occurs when a patient starts early weight-bearing, due to faulty surgical technique or after re-trauma. Removal of broken with broken locking bolt is a difficult and challenging procedure. The present case report deals with a case of the broken intramedullary nail with a broken distal locking bolt. A 30 years male patient was inserted interlocking nail for fracture shaft femur five years back. He presented with pain with instability and inability in weight-bearing after re-trauma. An X-ray revealed a broken nail with a broken distal locking bolt. The far fragment of the broken bolt was engaging bone and nail both and was the main obstacle. His nail with the broken bolt removed and re-nailing did in a single sitting. Steinmann pin (St.pin) was inserted through the distal piece of the nail to push the trapped small screw piece.

Keywords: broken nail, broken locking bolt, implant removal.

I. Introduction

Interlock nailing is a widespread procedure for femoral shaft fractures. Occasionally due to early weight-bearing or re-trauma nail is broken and locking bolt may also give way. Removal of such a broken nail and bolt becomes a challenging procedure. Various methods to remove the nails and bolts have been reported in the literature. In the present case, open method was adopted to remove a broken nail with broken distal locking bolt, followed by re-nailing. The far broken fragment of distal locking bolt was pushed back into the bone by inserting Steinmann Pin in the slot of distal nail fragment.

II. Case Report

A 30 years old male patient was inserted interlocking nail for fracture shaft femur five years back. After five years, he sustained another road traffic accident and presented with deformity, pain around left thigh and inability to put the weight. On examination, pain, tenderness, and movement at old fracture site were present. X-rays revealed hypertrophic non-union with complete breakage of the nail just below the fracture site and broken distal locking bolt. The far broken fragment of the locking bolt was probably engaging both nail and bone (Figure (Fig.) 1, 2). The intramedullary rod was of 360mm x 9mm size (Fig. 6).



Fig. 1: X-Ray Anterior Posterior view – broken nail and bolt.



Fig. 2: X-Ray Lateral view Broken nail and bolt.

Author: e-mail: rahulsharma5rs@yahoo.com

© 2020 Global Journals

III. Operative Technique

Removal of broken implant and exchange nailing was the planning. Removal of the proximal fragment was not difficult, as it was protruding through the entry point at the greater trochanter. But approach and taking away of distal nail fragment was a problem due to broken locking bolt and its far piece engaging both nail and bone. Furthermore, the distal nail fragment was broken slightly below the bone margin (Fig. 3, 5A) and was difficult to grasp with a plier. It was impossible to remove the distal fragment of the broken nail without dislodging the bolt. So, it was decided to adopt the open method under spinal anesthesia and C-arm control. In the supine position and pillow beneath the left gluteal region, the proximal fragment was removed with the help of standard nail extractor set after removing the proximal locking bolt (Fig. 5B-C). For removal of the distal fragment, fracture site was opened through lateral approach, and dissected out fibrous tissue of pseudo-arthrosis. Loose distal locking bolt fragment was removed by applying skin incision directly on the protruding head of the bolt (Fig. 5D-E). The proximal end of the broken distal nail fragment was approximately 4 mm below the bone margin and approached by trimming the bone sufficient to explore the nail fragment and to make the hold of plier on it. But pulling off the piece was not successful as the small broken locking bolt fragment was gripped. To push this small broken fragment of the bolt, a Steinmann Pin (St. Pin) was inserted in the slot of nail fragment from proximal to the distal direction (Fig. 5F). This pin insertion in the nail slot pushed the bolt fragment back to the bone and freed the nail fragment. After taking out the St. Pin, the piece could be simply taken out (Fig. 5G). Standard nailing technique was adopted to exchange nail (Fig. 4, 5H-I). A small piece of the broken bolt was still in situ as such. It did not produce any hindrance for the insertion of the exchange nail as it was in the bone substance and was not protruding in the medullary canal (Fig.4).



Fig. 3: Before Surgery



Fig. 4: After Surgery

IV. Discussion

The whole procedure was lengthy and technically demanding but was safe at the same time. Removal of the broken nail with indwelling broke locking bolt either proximal or distal is a not easy procedure & a potential challenge in orthopedic surgery. Removal of nail piece with the use hooks, olive wires, St. Pins, or other special instruments are not available usually every time in the general orthopedic setup. Even sometimes surgeon opens the non-union part and changes the surgical approach to remove the nail fragment with damaging the surrounding tissue. So many complications do arise during and after surgery like lengthy surgery and exposure to the image intensifier, test the surgeon's patience, and increase the risk of postoperative complications, respectively. Levy et al mentioned the use of complete nail of smaller diameter to impact in a distal broken femoral nail to achieve antegrade extraction and local impaction [1]. Middleton et al. has been recommended to filling multiple wires in the slot of the intramedullary rod to remove distal broken fragments in anterograde fashion [2]. Marwan and Ibrahim described a technique of using metallic wire passed through a middle piece of the nail up to its distal hole and make an incision at the level of the distal outlet to fasten this wire [3]. The technique of creating a hole just distal to the proximal locking bolt of distal fragment for the removal of the distal nail fragment has been used successfully by Kretteck et al. [4]. They then placed a Hohmann-type lever into this opening to push the piece in the direction of the fracture focus. In the case of subtrochanteric fracture, distal fragment removed by retrograde impulsion and fractured proximal femoral nail by medial arthrotomy, as mentioned by Milia et al., the patients were follow upto a year of this kind of surgery but they had no knee pain and any other problems [5].

© 2020 Global Journals

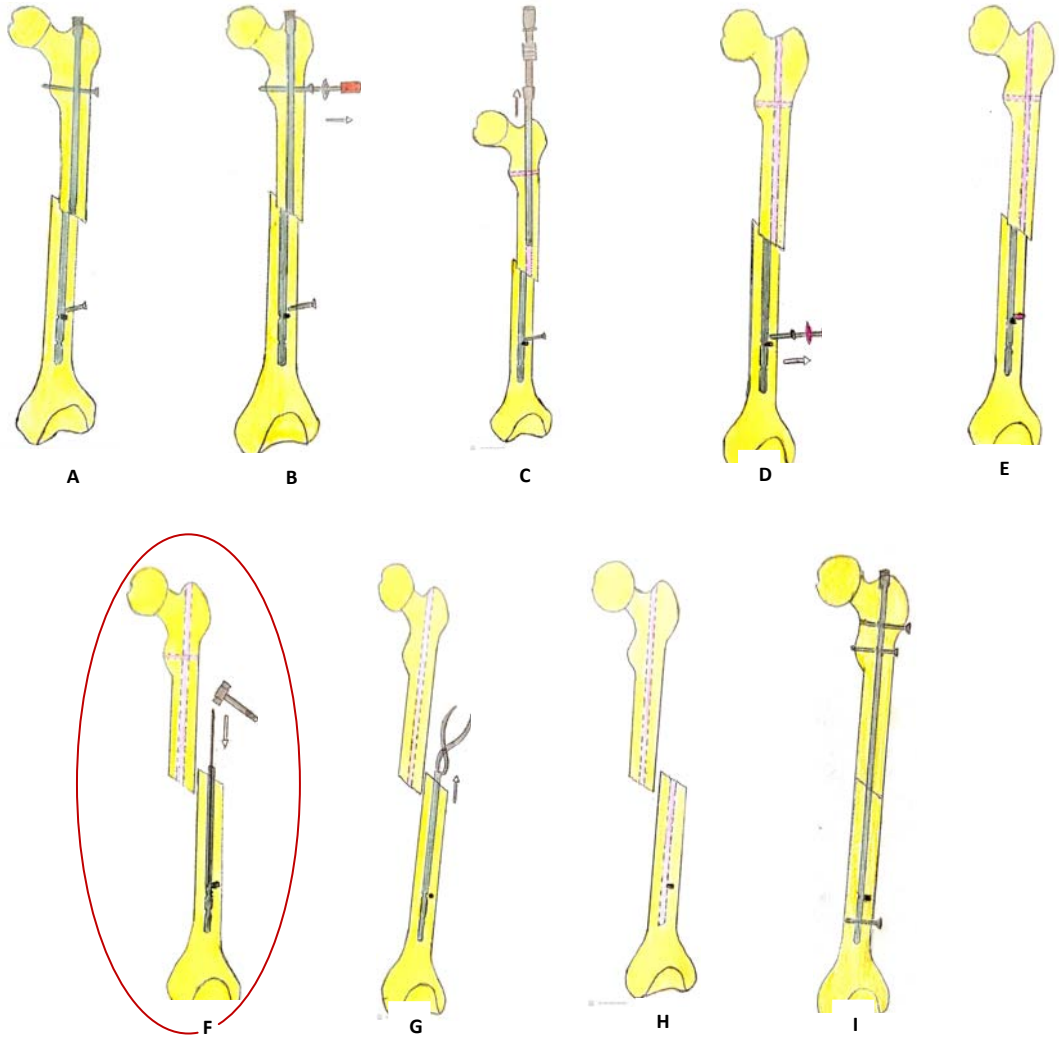

Fig. 5: Pictorial presentation of whole operative procedure with different stage



Fig. 6: Removed broken Implant

V. Conclusion

In case of the broken bolt with one fragment of it holding the nail fragment with the bone, the present method of pushing it back by insertion of St. Pin is a valuable technique and successful. Hence, a method to be used for removal of broken nail and bolt varies from case to case, the experience of the surgeon, and armamentarium available. Before embarking on the removal procedure, one should go through published various case reports and case series and should ensure the availability of required instruments.

Conflict of interest

The authors declare that they have no conflict of interest.

Ethical approval

This case report does not contain any studies with human participants or animal performed by any of the authors.

Disclosure of Funding

No funds have been received in support of this work. No benefits in any form have been or will be received from a commercial party related to, directly or indirectly, the subject of this article.

© 2020 Global Journals

Declaration of patient consent

The authors certify that they have obtained consent of the patient and his attendants for the clinical history and images to be reported in the journal while maintaining confidentiality.

Acknowledgement

Authors are thankful to the authorities of Rajiv Gandhi Government Ayurvedic post graduate college and hospital, Paprola, District Kangra, Himachal Pradesh, India for providing working facilities.

References Références Referencias

1. Levy O, Amit Y, Velkes S, Horoszowski H. A simple method for removal of a fractured intramedullary nail. J Bone Joint Surg Br 1994; 76:502-3.
2. Middleton RG, McNab IS, Hashemi-Nejad A, Noordeen MH. Multiple guide wire technique for removal of the short distal fragment of a fractured intramedullary nail. Injury 1995; 26:531-2.
3. Marwan M, Ibrahim M. Simple method for retrieval of distal segment of the broken interlocking intramedullary nail. Injury 1999; 30:333-5.
4. Krettek C, Schandelmaier P, Tscherne H. Removal of a broken solid femoral nail: a simple push-out technique- A case report. J Bone Joint Surg Am 1997; 79:247-51.
5. Milia MJ, Vincent AB, Bosse MJ. Retrograde removal of an incarcerated solid titanium femoral nail after subtrochanteric fracture. J Orthop Trauma 2003; 17:521-4.

© 2020 Global Journals