Volume 21 Issue 28
Originally issued as J2

Global Journal of Medical Research: J
Dentistry & Otolaryngology
Volume 21 Issue 2 Version 1.0 Year 2021
Type: Double Blind Peer Reviewed International Research Journal
Publisher: Global Journals
Online ISSN: 2249-4618 & Print ISSN: 0975-5888

Comprehensive Diagnosis of an Invaginated Tooth Prior to Endodontic Treatment – A Clinical Case

By Igor Noenko & Volodymyr Fedak

Abstract- The article expores currently available ways of differential diagnosis of external and internal resorption in the presence of a related developmental abnormality, dens invaginatus (DI), to the maximum extent possible; whereas DI genuine etiology is still open to debate.

In different regions, the DI prevalence varies to a considerable extent. The non-occurrences are attributed to flawed diagnosis; therefore, not all DI cases are included in the statistics.

Meanwhile, such an invagination may lead to complications developing in the pulp and periapical tissues, and thereby it may significantly impede endodontic treatment.

Objective: The current study aims to study the intricacies of the dens invagination (DI) abnormality in routine dental practice. An attempt has been made to better understand the clinical signs of invagination and their impact on complications, and to systematize the criteria for diagnosing this abnomality.

Keywords: *etiology, dens invaginatus, dens in dente, classification.*

GJMR-J Classification: *NLMC Code: WU 230*



Strictly as per the compliance and regulations of:

© 2021. Igor Noenko & Volodymyr Fedak. This is a research/review paper, distributed under the terms of the Creative Commons Attribution-Noncommercial 3.0 Unported License http://creativecommons.org/licenses/by-nc/3.0/), permitting all non-commercial use, distribution, and reproduction in any medium, provided the original work is properly cited.

Comprehensive Diagnosis of an Invaginated Tooth Prior to Endodontic Treatment– A Clinical Case

Igor Noenko [α] & Volodymyr Fedak [σ]

Abstract- The article expores currently available ways of differential diagnosis of external and internal resorption in the presence of a related developmental abnormality, dens invaginatus (DI), to the maximum extent possible; whereas DI genuine etiology is still open to debate.

In different regions, the DI prevalence varies to a considerable extent. The non-occurrences are attributed to flawed diagnosis; therefore, not all DI cases are included in the statistics.

Meanwhile, such an invagination may lead to complications developing in the pulp and periapical tissues, and thereby it may significantly impede endodontic treatment.

Objective: The current study aims to study the intricacies of the dens invagination (DI) abnormality in routine dental practice. An attempt has been made to better understand the clinical signs of invagination and their impact on complications, and to systematize the criteria for diagnosing this abnomality.

Keywords: etiology, dens invaginatus, dens in dente, classification.

I. Introduction

Dens invaginatus, or dens in dente, is a tooth maldevelopment with bizarre dental hard tissue arrangement due to the enamel organ invasion into the tooth pulp chamber before the dental tissues have become mineralized. It begins at the crown and sometimes extends into the root with formation of a pocket or dead space, or it is an accentuation of the lingual pit of an incisor before calcification sets in (Hegde et al.) Dens invaginatus is a rarther frequent malformation (2—3 %) (Grahnen et al., 1953).

The clinical case below illustrates the importance of comprehensive diagnosis in determining the tactics of endodontic treatment and revealing the cause of the endopathology.

Female patient K., 23 years old, was referred by an orthodontist. Orthodontic treatment was being planned and it was necessary to come up with the tactics of managing tooth 22. The following diagnostic tools were used:

1. Periapical X-rays;
2. Cone beam CT scans
3. Instrumental diagnostics was also employed, of which the cold test turned out to be the most informative.

Corresponding Author α: Inodent Dental Clinic, Kyiv, Ukraine.
e-mail: bban@i.ua
Author σ: VivaDent Dental Center, Chernivtsi, Ukraine.

The X-ray snapshots showed signs of internal resorption in tooth 2.2.

The CBCT revealed intraroot perforating resorption on the vestibular root surface. In addition, a possible cause of resorption was identified as Oehlers' Type I invagination (1957), which was based on the radiological findings. According to the classification, Type I invagination is covered with enamel and is located within the coronal part, extending no further than the enamel-dentin junction. The authors believe that the infected invagination zone with subsequent creeping infection of the root pulp brought about the resorption. The response to the cold stimulus was very insignificant, especially in comparison with tooth 12. This made it clear that an irreversible destructive process is going on in the damaged tooth. Since the patient was planning orthodontic treatment and the resorption process could grow worse, it was decided to conduct endodontic treatment.

The diagnosis presented some difficulties and it was necessary to discriminate between internal and external resorption, as they require dififerent treatment tactics. While external resorption provides for either observation or surgery, depending on the extent of the defect and location, internal resorption often implies endodontic treatment.

The criteria for differential diagnosis included the following:

The radiographic findings were very similar to external resorption, but some moments were not typical of it.

In favor of external resorption was the shape of the defect, with the wider defect facing the bone, the shape of the defect was not rounded, which would be characteristic of internal resorption.

Also, there were signs in favor of internal resorption. The defect was below the cervical part, which is not typical of external cervical resorption. The response to cold stimuli reduced, which is not characteristic of external resorption, as it affects the pulp only in the last stages of tooth structures decay. Furthermore, the X-ray obliteration of the root canal beyond the resorption area is not characteristic of external resorption.

Visit 1: Pre-op X-ray plus anesthesia with sol. Ubisthesini 4% - 1 ml, isolation with rubberdam. The access was made as close as possible to the incisal edge. When opened, at first glance the pulp chamber looked quite

© 2021 Global Journals

vital. But after passing the canal orifice, a heavy bleeding started and granulation tissue was found. Another access was made through the invagination. Both the invagination canal and the main one converged at the orifice. The visit was completed by irrigation with NaOCl 5.25%, and obturation with Ca(OH)2 to reduce granulation tissue volume.

Pics 1,2,3,4,5



© 2021 Global Journals





© 2021 Global Journals

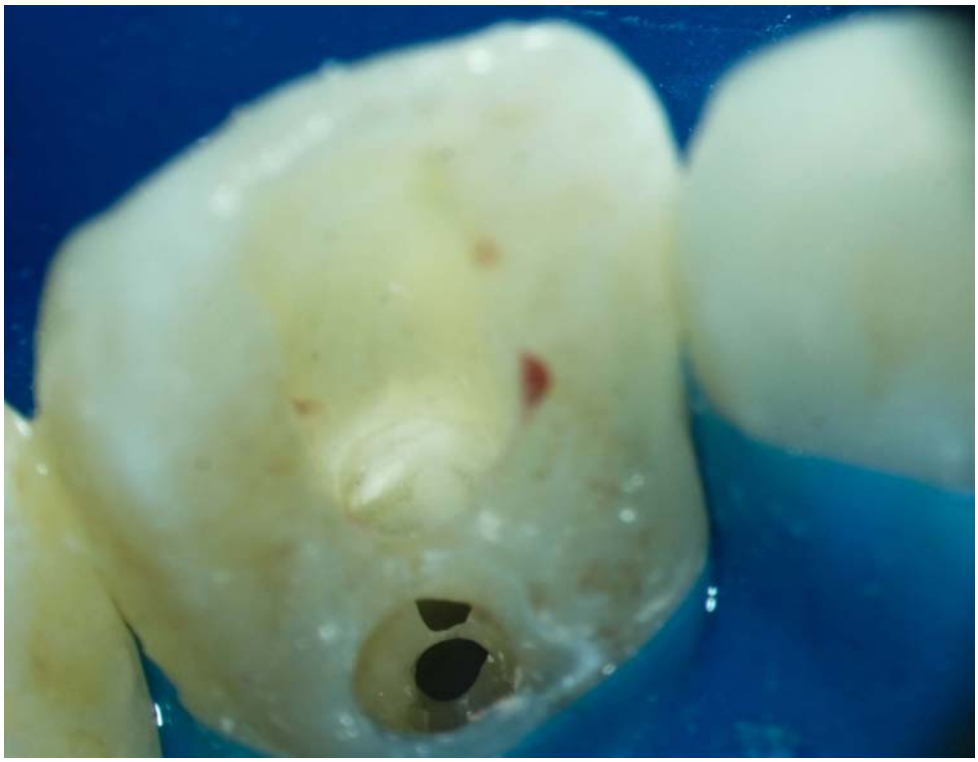



© 2021 Global Journals

Visit 2: In 2-week time, treatment was carried out with NaOCl 5.25%, followed by obturation with Ca (OH)2 due to inability to dry the root canals; though no bleeding was observed at the second visit, exudation persisted.

Pics 6,7

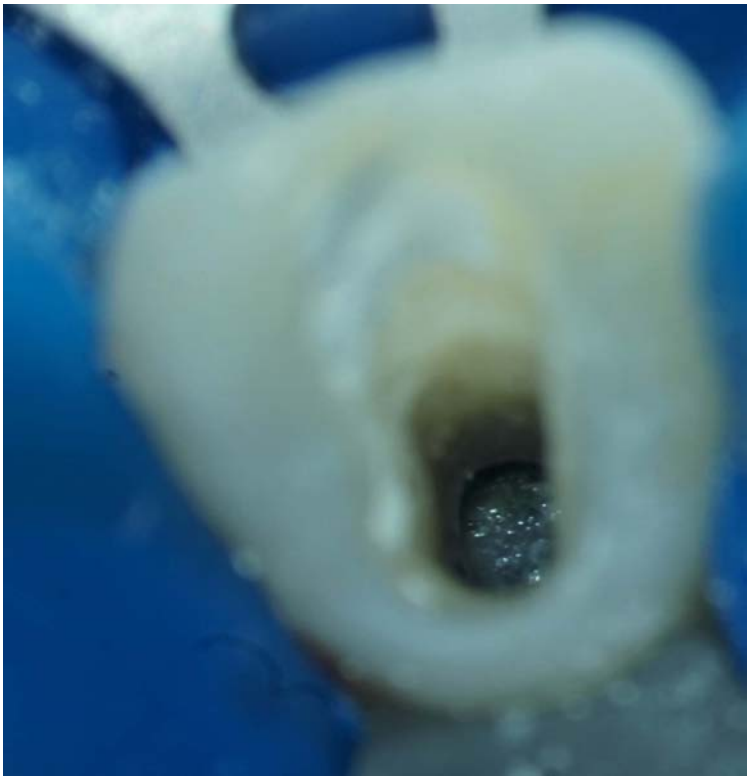



© 2021 Global Journals

Visit 3: Took place4 weeks after the start of treatment. During the visit the apical part of the root canal was accessed. The entrance to the apical part was closed, i.e. obliterated. The access had to be carried out using a DTE ultrasound scaler and a SANI U file size 20. The final instrumental processing of the apical part was performed with Soco Sc 35-04 files. Due to the complex anatomy and the lack of time, the final obturation was postponed to the next visit.

Pics 8,9





© 2021 Global Journals

Visit 4: Took place in 6 weeks since the treatment beginning. The apical third was obturated using vertical condensation of gutta-percha. The root was sealed with liquid.
composite, followed by treatment with NaOCl 5,25 % and obturation with Ca(OH)2.

Pic 10

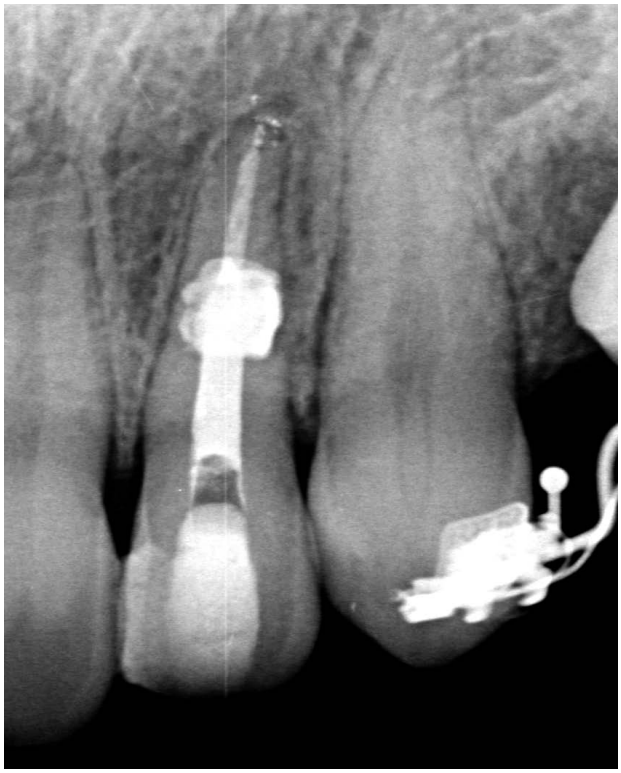

Visit 5: The root canal was obturated with biocearamic sealer and a central pin. The approach was chosen only owing to the fluid properties of the sealer. Inserting and adapting MTA would have been extremely challenging under those conditions.

Pic 11

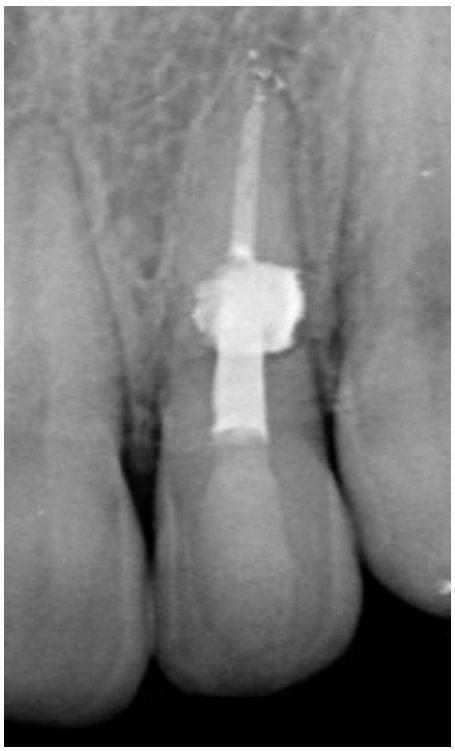

© 2021 Global Journals

Visit 6: Ten weeks passed since the beginning of the treatment. Material hardening was controlled, and a permanent filling was inserted.

Pic 11a

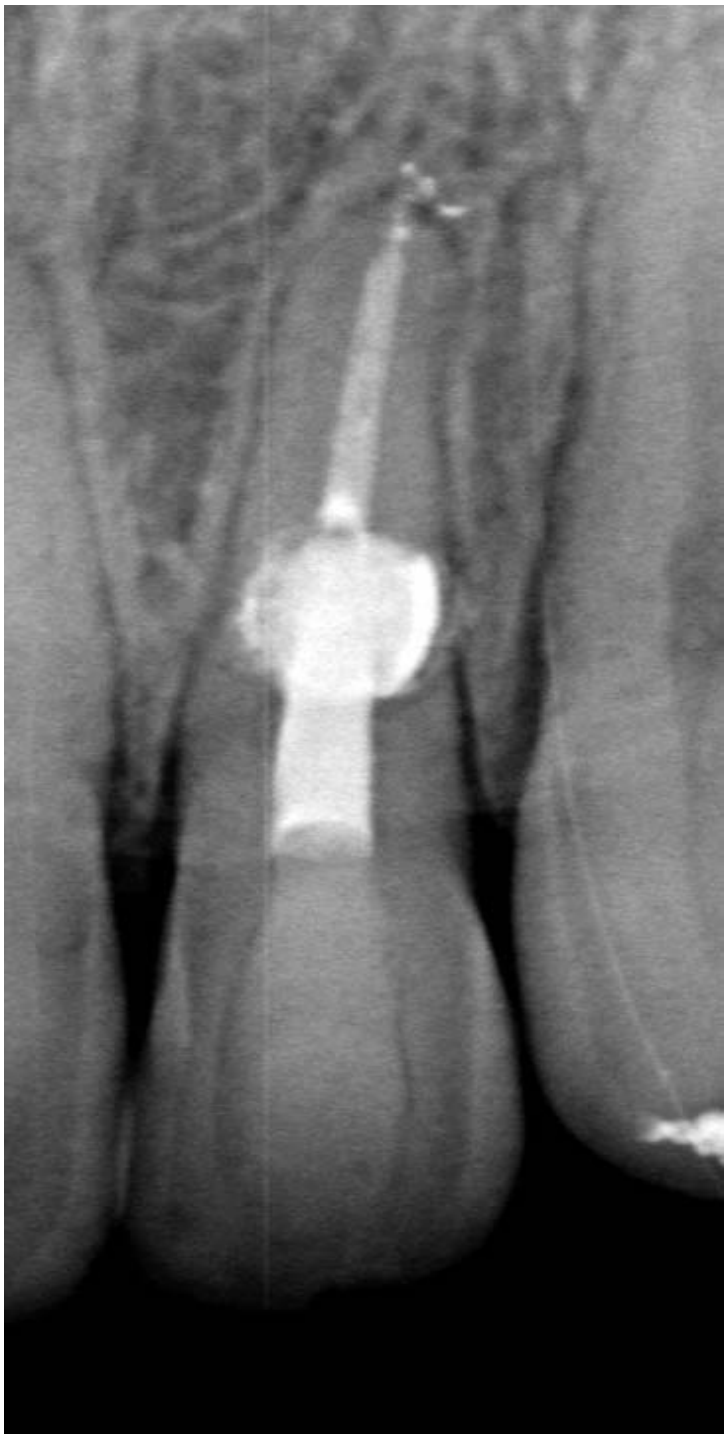

© 2021 Global Journals

Post-op recall in 1 year

Pic 12,13.

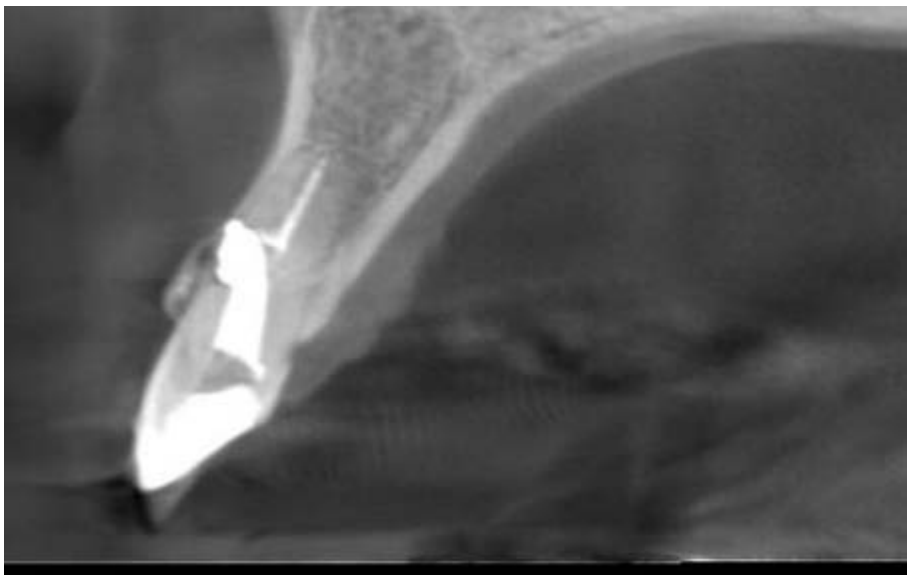



II. Response to the Endodontic Treatment

The patient started orthodontic treatment, however, tooth 2.2 was temporarily not included in the orthodontic therapy at the endodontist's request, who was willing to observe it for a year. Furthermore, increased resorption could have been provoked. As of today, the tooth is included in the orthodontic treatment and is being followed up.

In eighteen-month time, the stabilized process is observed, meaning that the diagnosis has been correct and the manual work has been performed without problems.

No complaints are observed.

© 2021 Global Journals

Pic 14



III. Conclusions

The difference between internal and external resorption lies in the fact that high-quality removal of granulation tissue by mechanical and chemical (calcium hydroxide) techniques allows for achieving a high level of recuperation. Also, an accurate DI diagnosis makes it possible to seal the invaginated area at the early stages before pulp-associated complications occur, which would later require comprehensive endodontic treatment. Other approaches and tactics for treating teeth with invaginations are described in previous articles by the authors.

© 2021 Global Journals