

# A Tiny Incredible Urethral Carcinoma: Dimension may be Deceptive-A Case Report

Sujata Sarangi<sup>1</sup>, Sanghamitra Mukherjee<sup>2</sup>, Manisha Mahata<sup>3</sup>, Gopinath Barui<sup>4</sup> and Tushar Kanti Das<sup>5</sup>

<sup>1</sup> RG Kar Medical College, Kolkata, West Bengal

*Received: 12 December 2015 Accepted: 31 December 2015 Published: 15 January 2016*

---

## Abstract

Primary urethral carcinoma is a very rare urinary tract cancer with very few reported cases all over the world. Owing to limited trials and research work due to the rarity there is no standardization of the treatment protocol. We report a case of a 60 yrs female presenting with hematuria who underwent surgical resection of urethra and was diagnosed to be a case of Primary Urethral adenocarcinoma.

---

**Index terms**— urethra, adenocarcinoma, primary.

## 1 I. Introduction

Primary urethral cancer is an extremely rare lesion comprising less than 1% of the total incidence of all genitourinary malignancies. [1] The age of presentation is generally above 75 years and a female predominance [2,3] has been reported with urethral carcinoma taking up only 0.02% of all female cancers. [4] It presents most commonly with hematuria, infections and urethral diverticulum. Location of tumor origin, as well as histology, can affect management and prognosis. The rarity of the disease prevents prospective studies in order to determine the best treatment outcomes.

## 2 II. Case Report

A 60 year old female presented to the surgery outdoor with complaints of frank bleeding per urethra for 5 days. The patient did not have any burning sensation while micturition, no lower abdomen pain and was afebrile at the time of examination. Apart from the hematuria patient was otherwise stable, had no other significant past history of disease apart from being hypertensive for 10 years.

Routine work up of the patient showed the blood parameters to be normal. Urine examination under microscope showed plenty of RBCs. The urine culture report was insignificant. Straight X-ray and transabdominal ultrasonography did not reveal the presence of any stone or any obvious abnormality in the urinary tract.

Plain MRI of Pelvis revealed a small ill-defined, altered signal intensity area involving the anterior urethra at the level of the vaginal vault with maintained fat planes with adjacent structures. (Fig 1)

Biopsy was taken from this part of the urethra and on histopathological examination, it was proved to be urethral adenocarcinoma, enteric type (Fig ??

**3 , Fig 3). The patient underwent surgical resection of the urethra**

Author ? ? ? ? ¥: e-mail: justsujata@gmail.com and the specimen was sent for histopathological examination along with the proximal urethral margin.

Gross examination of the specimen showed a single grayish white tubular structure measuring 2.5x1.0x1.0 cm. The proximal urethral margin was sent separately in two pieces altogether measuring 1x0.8x0.5 cm. Whole of the sent tissue was processed.

Microscopic examination revealed histological structure of urethra lined by squamous epithelium with focal areas of ulceration and partly by transitional epithelium along with dense chronic infiltrate in submucosa and muscle. No residual tumour tissue was seen. The proximal margin was unremarkable. Patient is under close follow up.

## 4 III. Discussion

Primary urethral cancer is an extremely rare and aggressive condition with less than 2000 reported cases. [5] The overall incidence is less than 1% of the total incidences of malignancies [5] and 0.02% of the female malignancies [6]. This carcinoma has female predominance. [7] The origin of this carcinoma is debatable. It may be from Mullerian duct, urethritis glandularis, Skene's glands or mixed origin. Because of the limited knowledge, it is often difficult to manage this malignancy. There is difference in anatomy of urethra of male and female hence it leads to individualized approach for each patient. The etiology of urethral adenocarcinoma mainly includes irritative stimuli like urinary tract infection or diverticula which leads to epithelial metaplasia, dysplasia and finally carcinoma. [8] The symptoms vary but it presents most commonly with bleeding followed by other presentations like irritative voiding, dyspareunia, an extra urethral mass, pelvic pain and complaints of obstruction or incontinence in advanced cases. A detailed history, physical examination, urine cytology, urethrocystoscopy, intravenous urography, urethrocytography, CT scan and MRI are very useful diagnostic tools. [8] A careful physical examination should be done comprising of palpation of external genitalia for any abnormalities, pelvic examination with careful inspection and palpation of urethra especially in case of females, bimanual examination under general anaesthesia and digital rectal examination [9]. The role of urine cytology is limited. Diagnostic urethrocystoscopy and biopsy is the primary mode for diagnosis of a urethral tumour in terms of tumour extent, location and underlying histology. [10] The urethra consists of five layers-mucosa submucosa and three muscle layers. For in females, as in our case the histological type depends on the location of the tumour in the urethra. Distal tumours are generally Squamous cell carcinoma as that part has squamous lining and proximal part generally has urothelial or adenocarcinoma as it is lined by transitional epithelium. The most common type of urethral carcinoma is the urothelial type(54-65%), [9] followed by Squamous Cell Carcinoma and Adenocarcinoma. The adenocarcinoma of urethra may show enteric, colloid or signet ring histology. All of them may be present singly or in combination. Clear cell type is another very rare variety. The confirmatory diagnosis is made by urethrocystoscopy, biopsy and histopathological examination. MRI and CT scan help in assessing local tumour extent and lymphatic and distant metastasis. The stage of the disease is an important prognostic factor. In advanced stages, it has been reported that the 3 year survival rates is 56% and there is no five-year survival rate. [2,3] It has also been reported that the squamous type has better prognosis than adenocarcinoma. [7] The treatment protocol of urethral adenocarcinoma is controversial as very less research has been done due to rarity of the disease. The treatment options include local excision to anterior pelvic exenteration along with neo or adjuvant chemotherapy or radiotherapy. Local excision has shown high incidences of metastasis and recurrence. In case of posterior urethral involvement, radical cystectomy with pelvic diversion and pelvic lymphadenectomy is the preferred course whereas in anterior urethral involvement, partial or total urethrectomy can be tried. [2,3] For less than 2cm lesions radiation along with surgery and adjuvant chemotherapy has been suggested, whereas for bigger lesions brachytherapy/ extended beam radiation can be tried. [2]. Despite all this, the treatment protocols of urethral carcinoma remain debatable but combination therapy has proved to be useful according to some studies.

## 5 IV. Conclusion

As urethral carcinoma has been found to be a very rare and aggressive tumour prone to recurrence and distant metastasis, it is highly essential that the tumour be diagnosed, staged and treated as early as possible as the advanced cases are known to show slim chances of survival. Hence, we report this case to increase awareness about this fatal tumour and to focus on the importance of histopathology for its diagnosis. <sup>1</sup>

---

<sup>1</sup>© 2016 Global Journals Inc. (US)



Figure 1: Figure 1 :

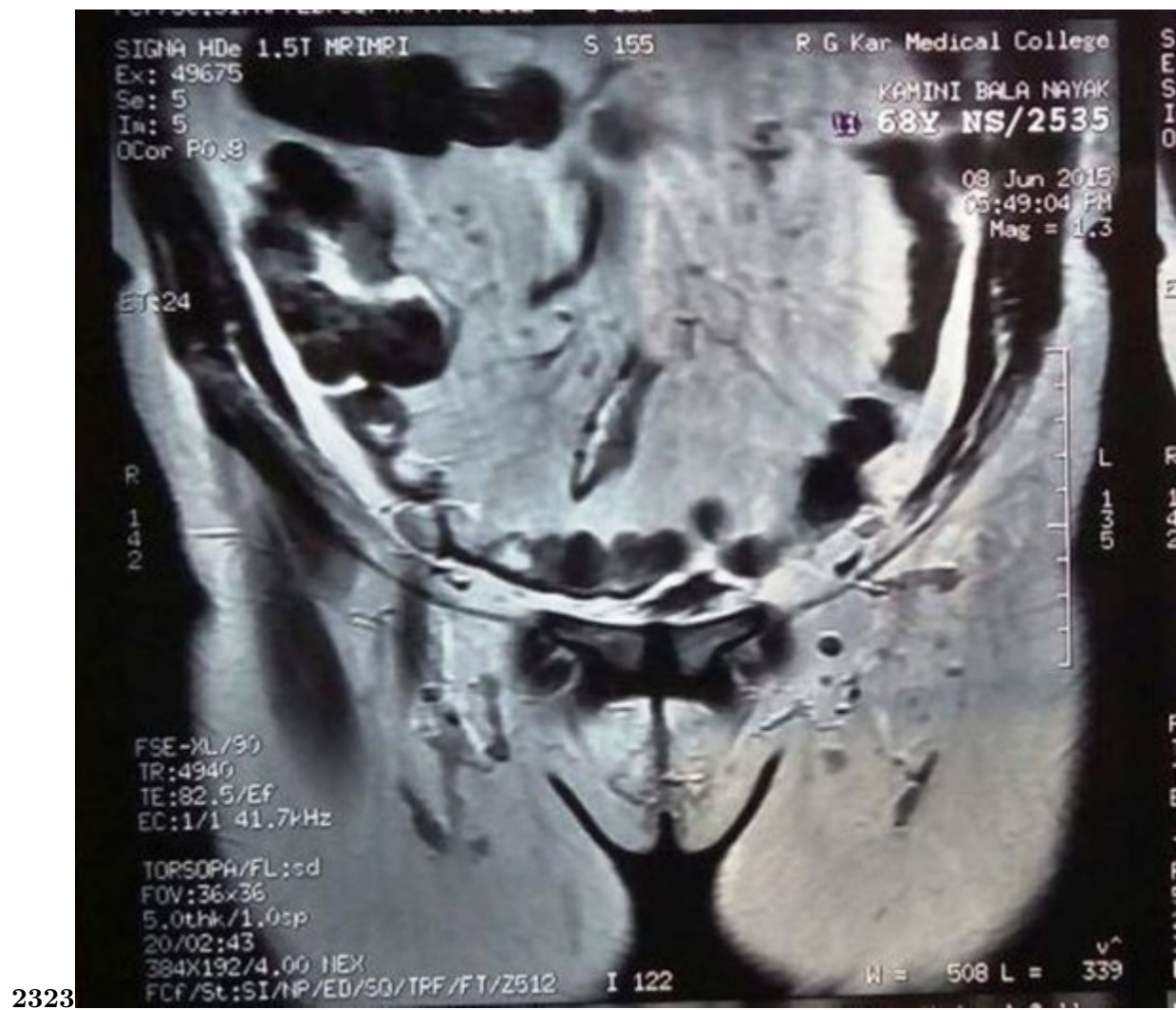

Figure 2: Figure 2 GlobalFigure 3 Figure 2 and 3 :

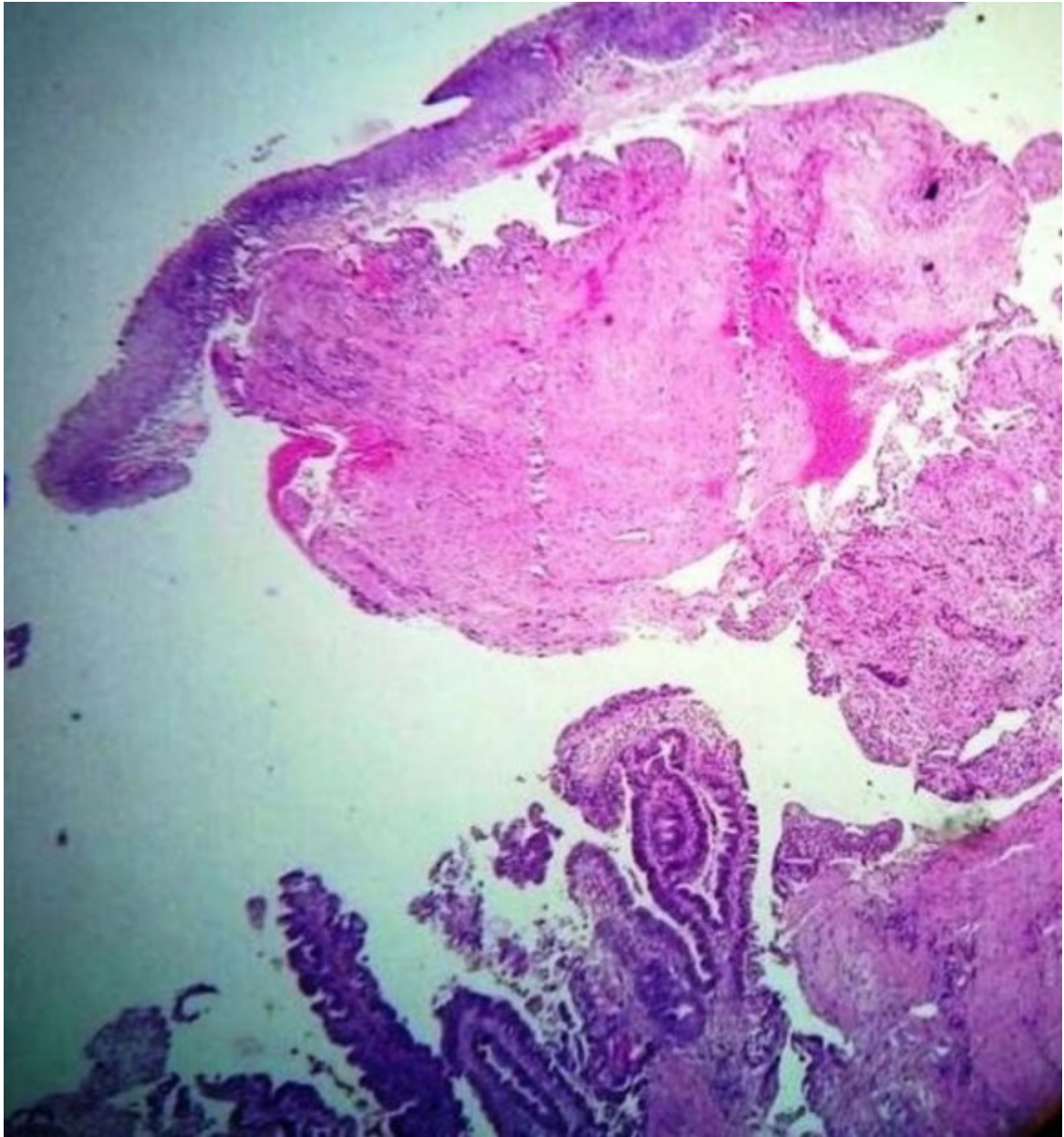


Figure 3:



- 
- 87 [Emedicine] , Emedicine . (Internet)
- 88 [ Urology Nephrology Open Access Journal ()] , *Urology & Nephrology Open Access Journal* 2015.
- 89 [Barreras et al.] ‘Adenocarcinoma de urethra femenina: presentation de dos casos y revision de la literature’.
- 90 García Barreras , S Fiter-Gómez , L Telles-Martínez , M . *Arch ESP Urol* 2014 (8) p. .
- 91 [Ochoa (2005)] ‘Adenocarcinoma de uretra femenina: presentación de dos casos y revisión de la literatura’. Jaf
- 92 Ochoa . *Arch. Esp. Urol* Sep 2005. (v.58 n.7)
- 93 [Manning ()] ‘Case report: transitional cell carcinoma in situ within a urethral diverticulum’. J Manning .
- 94 *International Urogynecology Journal* 2012. 23 (12) p. .
- 95 [Gakis et al. ()] ‘Guidelines on Primary Urethral Carcinoma’. G Gakis , J A Witjes , E Compérat , N C Cowan
- 96 , De Santis , M Lebreton , T . *European Association of Urology* 2015.
- 97 [Guidos (2013)] Joseph Guidos . *Urethral Cancer: Background, History of the Procedure, Problem*, Oct 17. 2013.
- 98 (Updated)
- 99 [Miller and Karnes ()] ‘Primary clear-cell adenocarcinoma of proximal female urethra: Case report and review
- 100 of literature’. J Miller , R J Karnes . *Clin Genitourin Cancer* 2008. 6 (2) p. .
- 101 [Charry et al.] *Primary Female Urethral Carcinoma A Case Report. A Review of the Diagnosis and Treatment*,
- 102 Paula Charry , G\* , Ramiro Cabello , B , Carlos Simón , R , Carmen González Enguita .
- 103 [Boorjian et al. (2011)] ‘Risk factors and outcomes of urethral recurrence following radical cystectomy’. S A
- 104 Boorjian , S P Kim , C J Weight . *Eur Urol* 2011 Dec. 60 (6) p. .
- 105 [Karnes et al. (2010)] ‘Surgery for urethral cancer’. R J Karnes , R H Breau , D J Lightner . *Urol Clin North*
- 106 *Am* 2010 Aug. 37 (3) p. .
- 107 [Gatta et al. (2011)] ‘The RARECARE working group. Rare cancers are not so rare: The rare cancer burden in
- 108 Europe’. G Gatta , J M Van Der Zwan , P G Casali . *Eur J Cancer* 2011. Nov. 47 (17) p. .