

Primary Hydatid Cyst of the Spleen

Abraham Gampel Cohen¹, Fabiola Romero Ruperto², Maria Luz Parra Gordo³,
Francisco Javier Gonzalez Sendra⁴ and Claudio Lagana⁵

¹ La Princesa University Hospital

Received: 7 December 2015 Accepted: 2 January 2016 Published: 15 January 2016

Abstract

A 87 years old woman, natural and from a rural area of the province of Cordoba, Spain. Personal history of depressive disorder (treated with lorazepam, bupropion, triazolam and escitalopram), hypertension and transient ischemic attack 10 years ago (in treatment with acetylsalicylic acid) and advanced glaucoma for 4 years (treated with latanoprost and timolol). Visits with abdominal pain of insidious onset, diffuse, intermittent, with a month of evolution, located in the stomach region without irradiation, associated with nausea and intermittent vomiting. Patient refers long-standing loss of appetite. She denies urinary clinic. The last deposition was 2 days ago, with usual constipated habit. During the clinical examination she maintains its stable vital functions and remains conscious and oriented. The abdomen is soft and depressible, tenderness in the stomach region to touch without mass or organ enlargement or peristalsis. The rest of the exam without significant alterations.

Index terms—

Visits with abdominal pain of insidious onset, diffuse, intermittent, with a month of evolution, located in the stomach region without irradiation, associated with nausea and intermittent vomiting. Patient refers long-standing loss of appetite. She denies urinary clinic. The last deposition was 2 days ago, with usual constipated habit.

During the clinical examination she maintains its stable vital functions and remains conscious and oriented. The abdomen is soft and depressible, tenderness in the stomach region to touch without mass or organ enlargement or peristalsis. The rest of the exam without significant alterations.

The blood count values are: hemoglobin 16.7, VCM 85.7, HCM 28, platelets 302,000, 11,000 leukocytes, neutrophils 78.2%, 16.4% lymphocytes and eosinophils 0.5%. Biochemical values are within normal parameters.

In the posteroanterior and lateral chest radiographs (Figures 1 and 2) can be seen a nodular lesion with left infradiaphragmatic peripheral calcification. In plain abdominal radiography (Figure ??) abundant stool and gas in the colon, distal presence of gas are evident; the presence of a round 5 cm in diameter calcified lesion, located in the left upper quadrant is confirmed.

It is given metamizol, metoclopramide and ranitidine in 100 ml of physiological saline and 0.5 mg sublingual alprazolam. Clinical response is favorable and the pain disappears.

Home treatment consists in a soft laxative diet regimen, chamomile tea, rectal enema to achieve effectiveness, and she is referred to his family physician for control.

A month later, the patient was referred to a doctor specialist in digestive tract with a presumptive diagnosis of calcified hydatid cyst. During the consultation an abdominal ultrasound is done in which was not identified the lesion displayed on the radiograph, so computerized tomography (CT) scan was requested for further study.

The radiologist previously performed a new abdominal ultrasound (Figure ??), confirming the presence of a splenic injury, therefore he completes the study with abdominal CT with and without intravenous contrast.

Author ? ? ? ? ¥ § ? ? : Alto Guadalquivir Hospital, Andújar, Jaen, Spain Primary Care ZBS, Cordoba, Spain La Princesa University Hospital, Madrid, Spain. e-mails: drgampel@hotmail.com, fromeroruperto@gmail.com, lparrag@telefonica.net, gonzalezsendra@yahoo.es, claudiolaga@hotmail.it,

joluchsinger@gmail.com, estela_ale@hotmail.com There is confirmation of the presence of a localized mass in the upper pole of the spleen, with rounded morphology, 49 mm in length, heterogeneous solid-cystic, grossly calcified and well-defined edges, which is not enhanced with contrast (Figure 5). The rest of the study does not show significant alterations.

The patient is discharged with a diagnosis of calcified splenic hydatid cyst. Periodic clinical and imaging controls are scheduled.

1 I. Comment

Hydatid disease is a parasitic zoonosis caused by *Echinococcus granulosus*. It can affect any organ of the host. Primarily infects the liver (approximately 75% of cases), followed by lung (25%), kidney (4%) and peritoneum (4%); splenic location constitutes 1% of cases.

Due to its low frequency, the clinical diagnosis of splenic hydatid disease can be challenging, especially in non-endemic areas. However, when the size of the cyst is large enough, the patient may feel a painful mass in the left upper quadrant; it can even compress the renal artery and cause systemic hypertension. Sometimes, there can be complications and breakage thereof, accompanied by bleeding or infection later.

Diagnosis is mainly done through Imaging studies (ultrasound or CT). Usually, the image can be described as a single cystic lesion or multiple, well defined. Some show membranes or daughters vesicles inside, or they can present their walls calcified.

Immunological tests are a support for the diagnostic but their efficiency is variable. The most sensitive and specific are ELISA, indirect immunofluorescence and double diffusion arc 5 Capron (DDA5). However, a negative serological result does not exclude infection.

The treatment of choice is surgery, often related with increased risk of complications derived to the cyst breakage, which can produce peritoneal dissemination. Not all cases are eligible for surgery, as our patient, either by baseline conditions of the own patient or the characteristics of the cyst. Calcified cysts (Dead cyst), with diameter less than 5cm, negative serological test and / or casual diagnosis during a radiological study, are sufficient justifications to rule out surgery, but is not an exemption from clinical and radiological control over the years.



Figure 1: H

2

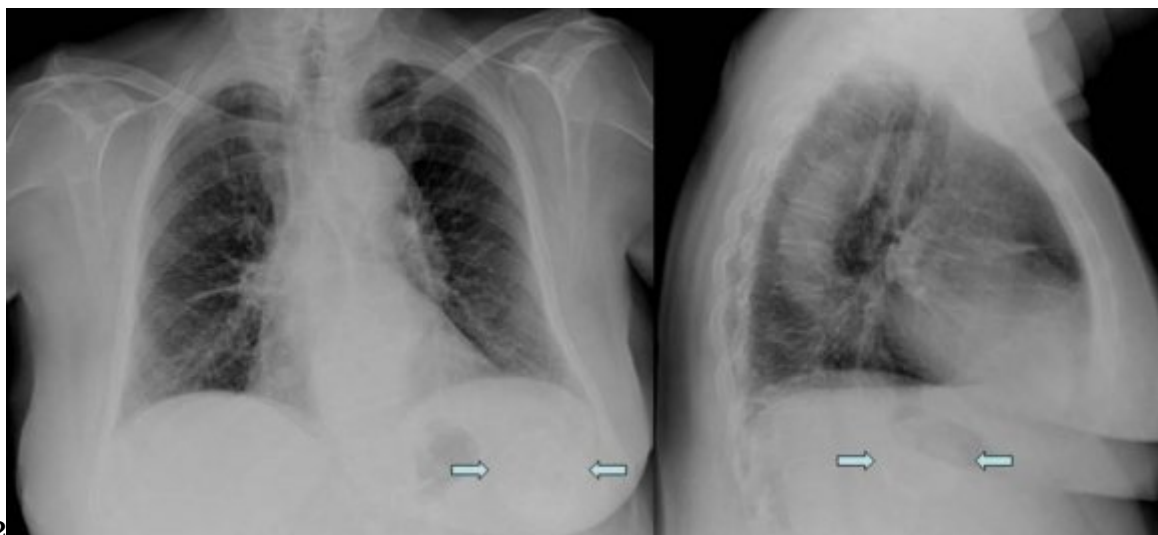


Figure 2: Figure 1 and 2 :

34

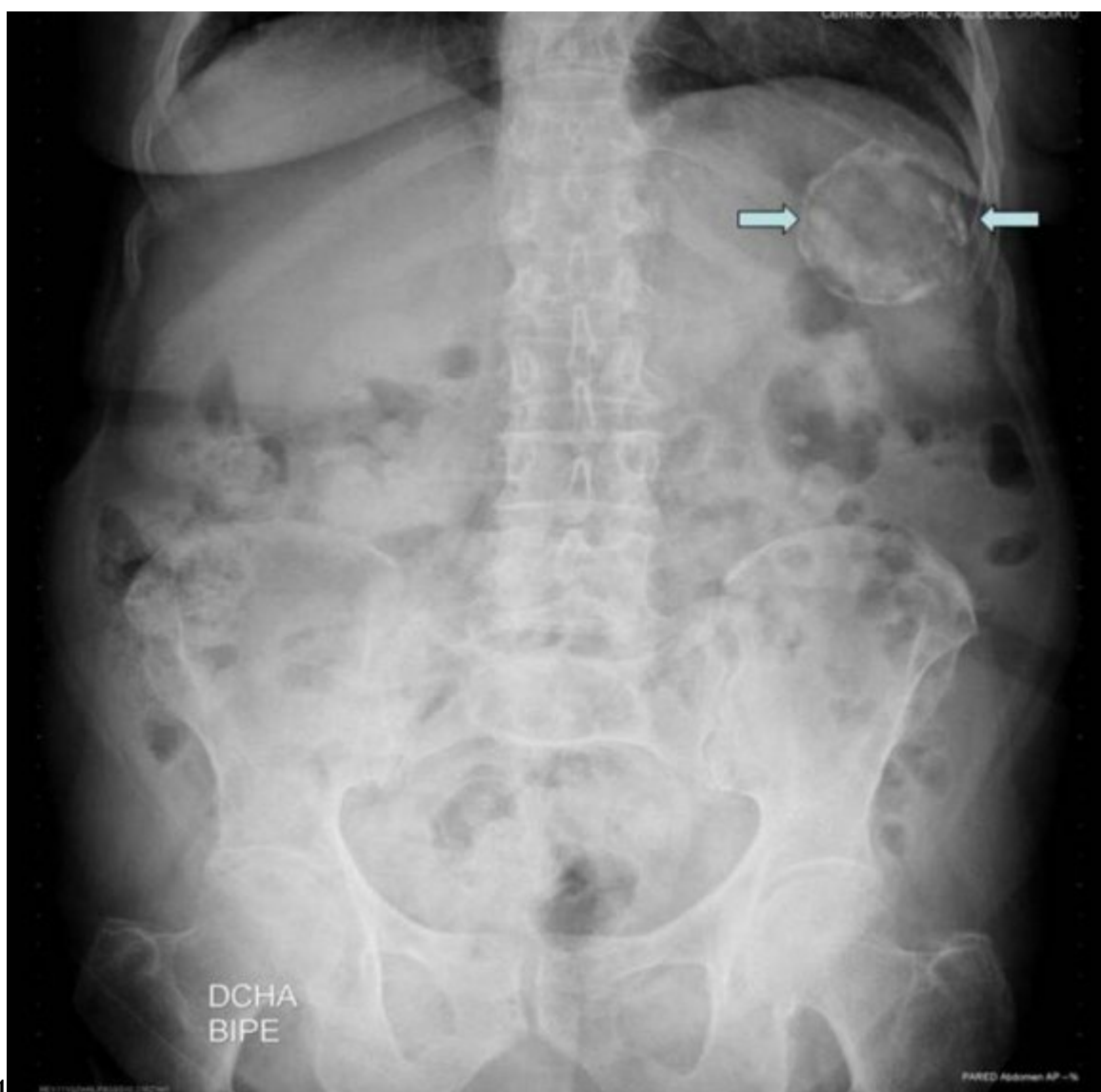

Figure 3: Figure 3 :Figure 4 :

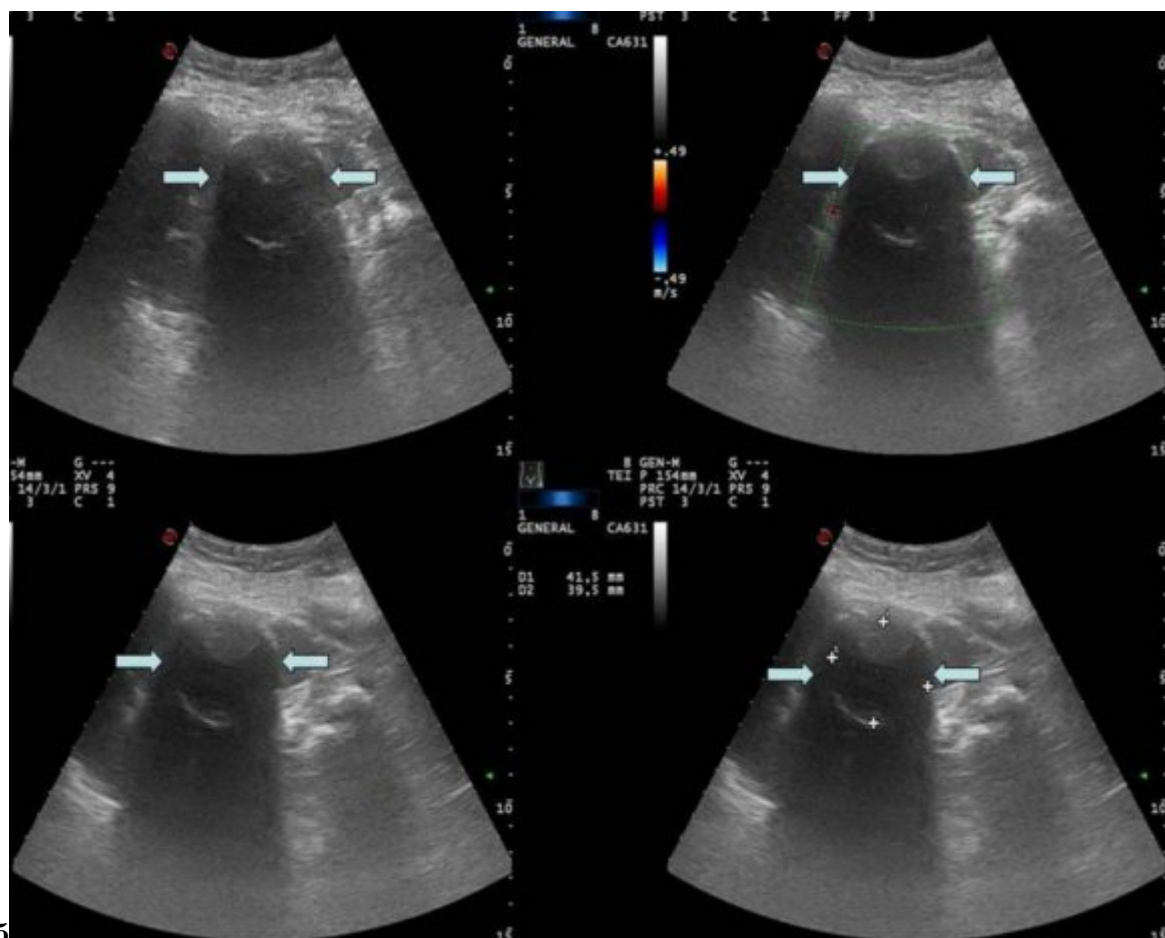


Figure 4: Figure 5 :

-
- 72 [Polat et al. ()] 'Hydatid disease from head to toe'. P Polat , M Kantarci , F Alper , S Suma , M B Koruyucu ,
73 A Okur . *Radiographics* 2003. 23 p. .
- 74 [Cebolero et al. ()] 'Hydatidcyst of spleen'. M P Cebolero , E Córdoba , J Escartín , S Cantín , J M Artigas , J
75 M Esarte . *J Clin Gastroenterol* 2001. 33 p. .
- 76 [Kiresi et al. ()] 'Uncommon locations of hydatidcysts'. D A Kiresi , A Karabacakoglu , K Odev , S Karaköse .
77 *Acta Radiol* 2003. 44 p. .