



GLOBAL JOURNAL OF MEDICAL RESEARCH: K
INTERDISCIPLINARY
Volume 17 Issue 2 Version 1.0 Year 2017
Type: Double Blind Peer Reviewed International Research Journal
Publisher: Global Journals Inc. (USA)
Online ISSN: 2249-4618 & Print ISSN: 0975-5888

Prevalence of Indigestible Foreign Bodies in the Rumen and Reticulum of Sheep Slaughtered at Jimma Municipal Abattoir, Southwestern Ethiopia

By Nejash Abdela, Feyissa Begna Deressa, Abdi Hassan & Endale Teshome
Jimma University

Abstract- Background: Indigestible foreign bodies ingestion predisposed by environmental pollution is becoming a major global problem in ruminants. Even though, the impacts on cattle have gained some attention, shoats are neglected.

Methods: Cross-sectional study was conducted from September 2016 to December 2016 on 200 sheep slaughtered at Jimma municipal abattoir with the objective to determine the prevalence of indigestible foreign body in rumen and reticulum of sheep. The study population was sheep coming for slaughter from different districts of Jimma zone. Slaughtered sheep (study unites) were followed to collect their stomach and foreign body (indigestible materials) were assessed in the rumen and reticulum. Questionnaire was used to collect some hypothetical risk factors and data were recorded during stomach investigation. Logistic regression was used to determine the association of risk factors with occurrence of for foreign body.

Keywords: *indigestible foreign bodies, jimma municipal abattoir, sheep.*

GJMR-K Classification: *NLMC Code: QW 70, WC 900*



Strictly as per the compliance and regulations of:



Prevalence of Indigestible Foreign Bodies in the Rumen and Reticulum of Sheep Slaughtered at Jimma Municipal Abattoir, Southwestern Ethiopia

Nejash Abdela ^α, Feyissa Begna Deressa ^ο, Abdi Hassan ^ρ & Endale Teshome ^ω

Abstract- Background: Indigestible foreign bodies ingestion predisposed by environmental pollution is becoming a major global problem in ruminants. Even though, the impacts on cattle have gained some attention, shoats are neglected.

Methods: Cross-sectional study was conducted from September 2016 to December 2016 on 200 sheep slaughtered at Jimma municipal abattoir with the objective to determine the prevalence of indigestible foreign body in rumen and reticulum of sheep. The study population was sheep coming for slaughter from different districts of Jimma zone. Slaughtered sheep (study unites) were followed to collect their stomach and foreign body (indigestible materials) were assessed in the rumen and reticulum. Questionnaire was used to collect some hypothetical risk factors and data were recorded during stomach investigation. Logistic regression was used to determine the association of risk factors with occurrence of for foreign body.

Results: From total of 200 sheep examined for the presence of indigestible foreign bodies, 22(11%) were found to be positive for indigestible foreign bodies in their rumen and/or reticulum. The types of different indigestible foreign bodies recovered were plastics (6.5%), cloth (2%), wire (1%) and leather (0.5) with plastics being 59.0% of the case. Prevalence of indigestible foreign body in thin, medium and good body conditioned sheep was 35.7%, 11.2 and 3.2%, respectively. Furthermore, the prevalence recorded in sheep > 3 years, 2-3 years and < 2 years was 24.3%, 8.8% and 5.2%, respectively. Age and body condition difference were significantly associated with indigestible foreign bodies ingestion. The prevalence was significantly higher in sheep of age >3 years compared to that of <2 years (OR) = 5.160, (CI: 1.234 - 21.573, $P \leq 0.031$), and the prevalence in thin animals was significantly higher than good body conditioned animals (OR= 24.165, CI: 4.787-121.989, $P= 0.000$). Out of 22 sheep positive for indigestible foreign materials higher proportion was found in rumen (86.36%) than in reticulum (13.63%). This variation is also significantly different statistically (OR= 6.893, CI: 2.0062 to 23.6843, $P=0.0022$).

Conclusion: This study revealed that indigestible foreign body ingestion by sheep in the study area is prevalent which may indicate poor environmental protection and pollution with

plastics and other indigestible foreign bodies. This may pose serious health problem for extensively reared animals and negatively affect their overall productivity and production. Thus, to prevent animals from accessing indigestible foreign bodies strict regulation regarding the proper waste disposal practices and good husbandry methods are required.

Keywords: indigestible foreign bodies, jimma municipal abattoir, sheep.

1. INTRODUCTION

Ethiopia has the largest livestock population in Africa with sheep and goat populations exceeding 58 million, which is one of the largest populations of small ruminants in Africa (CSA, 2016). Sheep and goat are integral to the livestock production systems in crop-livestock mixed agriculture in the highlands and in the pastoral and agro-pastoral livestock production. They are particularly important resources of the country as they provide more than 30% of the local meat consumption and form a vital source of income for small-scale farmers (ILCA, 2007).

There is also a growing export market for live sheep and meat in the Middle Eastern Gulf states and some African countries. At optimum off take rates, Ethiopia can export 700,000 sheep annually, and at the same time supply 1,078,000 sheep for the domestic market (Alemu and Marke, 2008). However, the benefits obtained from sheep to date do not match their tremendous potential and significant losses result each year from the death of animals as a result of lack of appropriate veterinary services, lack of attention from government, wide spread endemic disease and recurrent drought which are considered as bottleneck for development of this sector in the country (Abdela and Jilo, 2016; Jilo et al., 2016). Indigestible foreign bodies are reported to be a common cause of surgical emergency in Veterinary Medicine and have been implicated as among common causes of sudden death (Radostitis et al., 2007; Anwar et al., 2013).

Indigestible foreign bodies in the rumen and reticulum predisposed by environmental pollution are fast becoming a major global problem in ruminants worldwide (Kumar and Dhar, 2013). Furthermore, Industrialization and mechanization of agriculture have

Author α σ ω: School of Veterinary Medicine, College of Agriculture and Veterinary Medicine, Jimma University, Jimma, Ethiopia P. O. Box. 307 Jimma, Ethiopia. e-mails: nejash.abdela@gmail.com, fey_abe2009@yahoo.com, endaleteshome23@gmail.com
Author ρ: College of Veterinary Medicine, Haramaya University. e-mail: abdisahassan3@gmail.com

increased the incidence of foreign body ingestion (Semieka, 2010). When ingested by animals foreign bodies get lodged in the rumen thereby compromising ruminal space and interfering with normal physiological functions of the rumen leading to weight loss with or without an enlarged abdomen or death (Anwar et al., 2013; Kumar and Dhar, 2013; Bwala et al., 2016).

Extensive plastic materials disposal is an increasing phenomenon (Arash et al., 2012), and a concern in view of the possible damage to the animals' wellbeing, particularly around urban settings in Ethiopia. The foreign bodies, especially large plastic, influence the digestion process by occupying space and blocking ingesta movement, which ultimately impair the health and productivity of animals. Plastics and other materials that are not able to decompose have no only direct effect on the animals, but also can remain in the environment for a long time which ultimately affects the soil fertility and thus may reduce the quality and quantity of pasture in the environment (Sheferaw et al., 2014).

In cattle indigestible foreign bodies was reported to be condition of great economic importance and causes severe loss of production and high mortality rates (Radostitis et al., 2007). However, Ingestion of large quantities of indigestible materials occurs in small ruminant during periods of drought, food scarcity, nutritional deficiency, pica and massive environmental pollution (Igbokweet al., 2003; Ghurashi et al., 2009; Otsyina et al., 2015). This condition is common especially in developing countries where the standard of animal management is unsatisfactory (Fasil, 2016).

Sheep are the second most important livestock species next to cattle in Ethiopia (Gizaw *et al.*, 2007) and the ingestion and lodgment of foreign bodies are common in the sheep than goats primarily due to indiscriminate feeding habits of sheep and selective nature of goats while grazing (Semieka, 2010; Fromsa and Mohammed, 2011). It has been indicated that, sheep reared in urban and peri-urban areas are more prone to indigestible foreign bodies than those reared in rural areas (Remi-Adewunmi et al., 2004). In Ethiopia small ruminants are left to roam and seek their own feed as the raising system is mainly extensive type. The areas available for grazing particularly in the case for animals reared in the urban and sub-urban areas are polluted with plastics, ropes, hair, wool and metals. This pollution may be predicated as a growing problem for grazing animals because of the poor waste management system and inadequate availability of feed during the dry season (Fromsa and Mohammed, 2011; Fasil, 2016).

Several investigation were conducted on indigestible foreign bodies in cattle in Ethiopia (Dawit et al. 2012; Tesfaye and Chanie, 2012; Nugusu et al. 2013; Sheferaw et al., 2014; Negash et al., 2015). However, there are limited studies on sheep despite free grazing system of animals in contaminated environments. Thus, there is scarcity of information on indigestible foreign

bodies in sheep. Therefore, the main objectives of this study were to estimate the prevalence of foreign body in rumen and reticulum of sheep slaughtered at Jimma municipal abattoir and to assess the possible risk factors associated with the ingestion of different foreign bodies.

II. MATERIALS AND METHODS

a) Study area

The study was conducted from September, 2016 to December, 2016 in Jimma municipal abattoir. Jimma municipal abattoir is located in Jimma town of Jimma zone. The town is located in the south western part of the Ethiopia in Oromia Regional State (figure 1). It is found at distance of about 352 km from Addis Ababa, the capital city of Ethiopia. Geographically, it is located at 7° 13' and 8° 56' N latitude and 35° 52' and 37° E longitude. The area has an altitude ranging between 880 and 3358 meter above sea level. The annual rainfall is ranging between 1200 mm to 2000 mm; and the annual temperature of the area ranges 7 °C to 30 °C. Jimma zoone has about 2,212,962 cattle, 866,561 sheep, 457,311 goats, 96,782 horses, 17,644 mules, 77,767 donkeys, 1,951,129 poultry and 546,722 beehives (CSA, 2016).

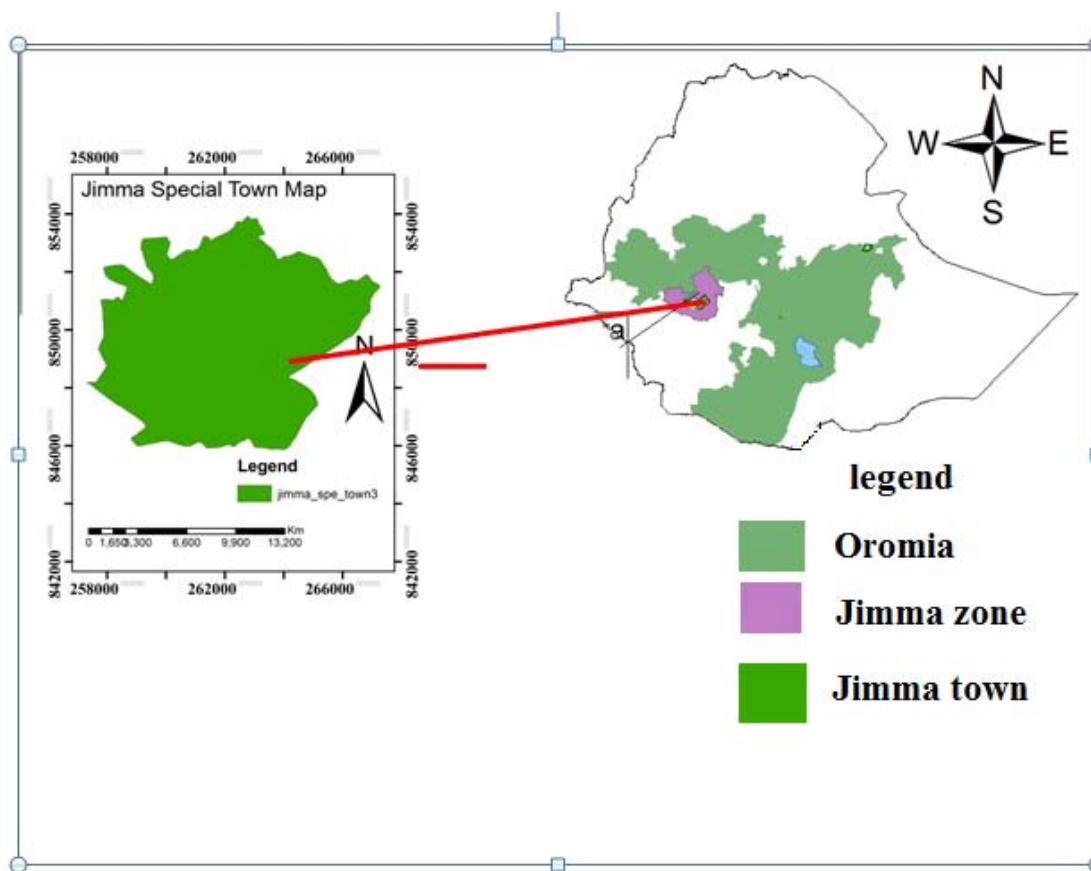


Figure 1: Map of the study area

b) Study Population and Study Design

A cross-sectional study design was employed for estimating the prevalence of indigestible foreign body types in the rumen and reticulum of sheep and to assess the possible risk factors associated with different indigestible foreign body. The study was conducted on local breed sheep with different age groups slaughtered at Jimma municipal abattoir. All animals considered in this study were males as female were not slaughtered in Jimma municipal abattoir during study period. The animals were brought from different areas including Dedo, Asandabo, Serbo, Mana, Seka, and Bilida. Most of these animals are managed under an extensive management system.

c) Sampling Techniques and Sample size determination

A simple random sampling technique was used for sampling sheep brought for slaughter from various localities to Jimma municipal abattoir. On average about 6 sheep were selected pre-slaughter and followed to collect their stomach and diagnose the indigestible foreign bodies. The abattoir was visited twice weekly and averagely the numbers of daily sheep slaughtered in the abattoir were around eight sheep. The required samples size for the study were determined by the formula given by Thrusfield (2005) based on the expected prevalence (9.7%) (Tesfaye et al., 2012) of

sheep indigestible foreign bodies and the 5% desired absolute precision and 95% confidence interval (CI). Accordingly, the required number of animals was 134. However, to increase precision the sample size was increased to 200.

The following formula was used to determine sample size

$$N = \frac{1.96^2 \times P_{exp} (1 - P_{exp})}{d^2}$$

Where, N= required sample size

P_{exp} = expected prevalence = 9.7%

d = Desired absolute precision = 5%

1.96 = the value of z at 95% confidence interval

d) Ante mortem and Post-mortem examination

During ante mortem examination, each study units selected randomly was given temporary identification number and data like body condition score and age of each study animals were recorded. The age grouping was based on eruption patterns as described by Steel (1996) and the sheep were grouped to <2 years, 2-3 years and > 3 years. The body condition was recorded as thin, medium and good based on the appearance of the animal and manual palpation of the spinus and transverse processes of the lumbar vertebrae as described by Thompson and Meyer (1994). After slaughtering, the stomach was removed carefully from the abdominal cavity and the rumen and reticulum

were incised to examine their contents. Rumen and reticulum of each study animals were thoroughly examined by visual inspection and palpation for the presence of indigestible foreign bodies during post-mortem examination. When the positive animas encountered, the location and type of the foreign bodies was recorded on format prepared for this purpose.

e) Data Management and Analysis

The data was entered and managed in a Microsoft Excel spread sheet and analysed using Statistical Package for Social Sciences version 20. Descriptive statistics was used to determine frequencies and over all prevalence. The prevalence of indigestible foreign bodies was determined as a proportion of affected animals out of the total animal examined. The differences or association between risk factors were analysed by binary logistic regression and OR and p-values were used to describe statistical significance associations and p-value of <0.05 was considered as statistically significant.

III. RESULTS

A total of 200 sheep were examined for presence of indigestible foreign bodies in their rumen

Table 1: Proportion of indigestible foreign body types in the rumen and reticulum

Organs	Frequency of indigestible foreign body						Association			
	Plastic (%)	Cloth (%)	Wire (%)	Leather (%)	Cloth, plastic and rope (%)	Overall (%)	Prevalence (%)	OR	(95% CI)	P-Value
Rumen	12(54.5)	4(18.1)	-	1(4.5)	2(9.0)	19(86.3)	9.5	6.8	2.0062 -	0.0022
Reticulum	1(4.5)	-	2(9.0)	-	-	3(13.6)	1.5	93	23.6843	
Total	13(59.0)	4(18.1)	2(9.0)	1(4.5)	2(9.0)	22 (100)				

b) Risk factor associated with foreign body ingestion

From total of 200 sheep examined, higher foreign body prevalence was observed in the older animals (> 3 years) 10(24.3%) followed by 2-3 years 9(8.8%) and lower prevalence was observed in young age groups (<2 years) 3 (5.2%) (table2). The odd of foreign body occurrence in sheep > 3 years was 5.160 times more likely than sheep under 2 years. This variation in the foreign body prevalence was found statistically significant (p<0.05) (table 2).

Thin body conditioned sheep were found to have highest prevalence of harbouring indigestible foreign body (10(35.7 %)) and in contrary good body conditioned sheep were found to have lowest indigestible foreign body prevalence 3(3.2%). The most prevalent foreign body were a plastic (6.5%) which was the most frequently recovered foreign body type in thin and medium body conditioned sheep. Cloth was encountered in medium and good body condition sheep. Leather was encountered only in single thin sheep and good body conditioned sheep were found to

and reticulum. Out of these, 22 (11%) were found to have various types of indigestible foreign bodies in the rumen and/or reticulum. The types of foreign bodies detected were plastic, cloth, leather, wire, and rope (Figure 2). The most commonly observed foreign bodies were plastics 13(59.0%) followed by cloth 4(18.1%); cloth, plastic and rope 2(9.0%), wire 2(9.0%) and leather 1(4.54) in order of occurrence.

a) Prevalence of indigestible foreign body types in the rumen and reticulum

From 22 positive cases of foreign body, 19(86.36%) were occurred in rumen while only 3(13.63%) in reticulum. The types of foreign bodies encountered and their frequency of occurrence was summarized in table 1. Significantly higher prevalence (p= 000) of indigestible foreign bodies was found in rumen (9.5%) than reticulum (1.5%). The odd of occurrences of indigestible foreign bodies in rumen was 6.893 times more likely than reticulum (Table 1).

have only plastic and cloth. The odd of foreign body occurrence in thin sheep was 24.165 more likely than good body condition sheep (Table 2). There was significant statistical difference (p = 0.000) between different body condition categories.

Table 2: Prevalence of different foreign body and multivariable logistic regression analysis of factors associated foreign body ingestion

Risk factors		No. examined	Frequency and prevalence of occurrence						Association		
			Plastic (%)	Cloth (%)	Wire (%)	Leather (%)	Cloth, Plastic, rope (%)	Overall (%)	OR	(95% CI)	P-value
Age	<2 years	57	2(3.5)	1(1.7)	-	-	-	3(5.2)	1.578	(0.376, 6.627)	0.031
	2-3 years	102	5(4.9)	1(0.9)	1(0.9)	-	2(0.9%)	9(8.8)			
	>3 years	41	6(14.6)	2(4.8)	1(2.4)	1(2.4)	-	10(24.3)			
Body Condition	Thin	28	6(21.4)	-	2(7.1)	1(3.5)	1(3.5)	10(35.7)	5.320	(4.787, 121.989)	0.000
	Medium	80	6(7.5)	2(2.5)	-	-	1 (1.2%)	9(11.2%)			
	Good	92	1(1.0)	2(2.1)	-	-	-	3(3.2)			
Total		200	13(6.5)	4(2)	2(1%)	1(0.5)	2(1)	22(11)			

IV. DISCUSSIONS

Ingestion of indigestible foreign materials by ruminants is a common worldwide problem and has been reported from different area of Ethiopia in both cattle and small ruminant (Tiruneh and Yesuwork, 2010; Fromsa and Mohammed, 2011; Negash et al., 2015; Fasil, 2016). This study showed an overall rumen and reticulum foreign body prevalence of 11% (22/200) in sheep slaughtered at Jimma municipal abattoir. This is in agreement with the finding in Kenya by (Otsyina et al., 2015) who reported 10.1% of foreign body prevalence. This result is larger to report by Fromsa and Nura, (2011) who reported 7.5% rumen foreign body in sheep Slaughtered at Luna Export Abattoir, East Shoa, Ethiopia and report from Jordan by Hailat et al (1996) who reported a prevalence rate of 8.9%.

This finding is relatively lower compared to 56.7% report from eastern Ethiopia at Haramaya University and Haramaya municipal abattoirs (Negash et al., 2015), 34.4 % at Jigjiga Municipal Abattoir (Fasil, 2016), 53.1% at Addis Ababa Municipality Abattoir (Tiruneh and Yesuwork, 2010) and 20.6% at Bahirdar municipality abattoir and hotels in Bahirdar town (Sheferaw et al., 2014). It also disagrees with study In Nigeria by Remi-Adewunmi et al., 2004, in South Darfur (Ghurashi et al., 2009) and Ghana (Atawalna et al., 2015) who reported 77%, 87% and 17.4%, respectively. This difference in prevalence may be due to the differences in origin of the animals slaughtered accompanied by feed availability and the type of waste management system between the study areas. Furthermore, this difference could also be due to the difference in the sex composition as all sheep slaughtered at Jimma municipal abattoir during study period are males. Higher prevalence rate of foreign body in the female animals was reported (Tiruneh and Yesuwork, 2010). If there is shortage of feed in the area this may predispose the animals to negative energy balance and force them to feed on unusual materials including plastics, clothes, ropes and even wire. On other hand, if there is no or less waste management

system in the area the chance of animals to ingest foreign bodies is high.

The current study indicated as larger number of foreign bodies occurred in the rumen (86.3%) than reticulum (13.6%) of sheep. this may be due to the fact that many ingested feed goes to the rumen due to its larger size as compared to reticulum. In agreement with this finding, different scholars have reported higher frequency of foreign bodies from rumen than from the reticulum (Tiruneh and Yesuwork, 2010, Fromsa and Mohammed, 2011; Negash et al., 2015; Fasil, 2016).

This study revealed that plastics were more common (59%) indigestible foreign body in the rumen and reticulum of sheep. The wide spread use and improper disposal of plastic which is bio non degradable could be the reason for it high prevalence. Similar findings were reported in different area of Ethiopia (Tiruneh and Yesuwork, 2010; Fromsa and Mohammed, 2011; Sheferaw et al., 2014; Negash et al., 2015; Fasil, 2016) and other countries like Nigeria (Remi-Adewunmi et al., 2004) and Jordan (Hailat et al, 1996). Extensive plastic materials disposal is an increasing phenomenon (Arash et al. 2012), and a concern in view of the possible damage to the animals' wellbeing, particularly around urban settings in Ethiopia. The foreign bodies, especially large plastic, negatively influence the digestion process by occupying space and blocking ingesta movement, which ultimately impair the health and productivity of animals. Plastics and other materials that are not able to decompose have not only direct effect on the animals, but also can remain in the environment for a long time which ultimately affect the soil fertility and thus may reduce the quality and quantity of pasture in the environment (Sheferaw et al., 2014).

Older sheep (> 3 years) (24.3 %) and sheep having thin body condition (35.7%) were found to be more frequently harbouring indigestible foreign body. In agreement with this finding there are reports from different area of Ethiopia and other country that older and thin animals to be more harbouring indigestible foreign body (Hailat et al. 1996; Remi-Adewunmi et al., 2004; Fromsa and Mohammed, 2011; Tiruneh and Yesuwork, 2010; Negash et al., 2015; Fasil, 2016) and

this difference are also statistically significant. The finding of significantly more foreign bodies in older animals than the young ones may be due to the gradual ingestion of indigestible materials over the prolonged period of time. The more frequent occurrence of rumen and reticulum indigestible foreign body in thin sheep might be attributed to the interference of the foreign body with the absorption of volatile fatty acids causing reduced weight gain (Remi- Adewunmi et al., 2004).

The finding of 11% prevalence of indigestible rumen and reticulum indigestible foreign body shows the widespread distribution of plastic bags in the environment as a result of improper disposal of waste. Unless appropriate measure is taken increased ingestion of indigestible foreign bodies could pose serious health problem for free grazing sheep particularly in urban and peri-urban areas and negatively affect their overall productivity and production. Proper waste disposal practices and good husbandry methods are required to prevent animals from accessing indigestible foreign bodies. Policy makers, veterinarians and environmental health experts are expected to work conjointly in reducing its adverse effect in animals. Furthermore, in order to reduce the problems associated with plastic bag wastes, it is recommended to aware the community not to use plastic bags, and to use ecologically-friendly alternative materials.

V. ACKNOWLEDGEMENTS

We would like to thanks Jimma municipal abattoir workers for their cooperation while conducting this research. Authors are also thankful to Jimma University for provision of required facility.

RÉFÉRENCES

1. Abdela, N., and Jilo, K. (2016). Impact of Climate Change on Livestock Health: A Review. *Global Veterinaria*, 16(5): 419-424.
2. Anwar K., Khan I., Aslam A., Mujtaba M., Din A., Amin Y. and Ali Z. (2013). Prevalence of indigestible foreign bodies in Achai cattle at different regions of Khyber Pakhtunkhwa. *Journal of Agricultural and Biological Science*, 8(8): 580-586.
3. Atawalna, J., Attoh-Kotoku, V., and Ewura, S. (2015). Prevalence of Indigestible Foreign Materials in Small Ruminants Slaughtered At the Kumasi Abattoir of Ghana. *International Journal of Livestock Research*, 5(11), 1-7.
4. Bwala, D. A., Peter, I. D., Eze, C. A., & Maryam, Y. (2016). A Study on Rumen Foreign Body Impaction in Sheep Slaughtered at the Maiduguri Metropolitan Abattoir, Maiduguri, Nigeria. *International Journal of Livestock Research*, 6(3), 16-23.
5. CSA (2003). Federal Democratic Republic of Ethiopia. Central Statistical Authority, Agricultural Sample Survey, Volume II, Addis Ababa, Ethiopia.
6. CSA, 2016. Federal democratic republic of Ethiopia. Central statistical agency. Agricultural sample survey, Volume II, Report on livestock and livestock characteristics. Statistical bulletin 583, Addis Ababa, Ethiopia.
7. Dawit, T., Diriba, D., Birhanu, M., and Amene, F., 2012. The Problem of environmental pollution as reflected in the fore stomach of cattle: A postmortem study in eastern Ethiopia, *Global Journal of Environmental Research*, 6(2), 61–65.
8. Fasil N (2016) Assessment of Sheep and Goat Foreign Bodies in Rumen and Reticulum in the Jigjiga Municipal Abattiar. *J Adv Dairy Res* 4: 157.
9. Fromsa, A., and Mohammed, N. (2011). Prevalence of indigestible foreign body ingestion in small ruminants slaughtered at Luna export abattoir, East Shoa, Ethiopia. *Journal of Animal and Veterinary Advances*, 10(12), 1598-1602.
10. Ghurashi M. A. H, Seri H. I., Bakheit A. H. and Ashwag E. A. M. (2009).Effect of surgical removal of foreign body from goat's rumen with special reference to the prevalence of foreign body in goats in Southern Darfur. *Australian Journal of Basic and Applied Sciences*, 3: 664-668.
11. Gizaw, S., Van Arendonk, J. A., Komen, H., Windig, J. J., & Hanotte, O. (2007). Population structure, genetic variation and morphological diversity in indigenous sheep of Ethiopia. *Animal Genetics*, 38(6), 621-628.
12. Hailat, N., Nouh, S., Al-Darraj, A., Lafi, S., Al-Ani, F. and, Al-Majali, A., 1996.Prevalence and pathology of foreign bodies (plastics) in Awassi sheep in Jordan, *Small Ruminant Research*, 24, 43–48.
13. Igbokwe, I.O., Kolo, M.Y., and Egwu, G.O., 2003. Rumen impaction in sheep with indigestible foreign body in the semi-arid region of Nigeria, *Small Ruminant Research*, 49, 141–147.
14. ILCA, (2007) International livestock center for Africa annual report, 2006. Addis Ababa, Ethiopia.
15. Jilo, K., Abdela, N., Adem. A. (2016). Insufficient Veterinary Service as a Major Constrants in Pastoral Area of Ethiopia: A Review. *Journal of Biology, Agriculture and Healthcare*. 6(9): 94- 101.
16. Kumar V. and Dhar P. (2013). Foreign body impaction in a captive Sambar (Rusa unicolor), *Veterinary World* 6(1): 49-50.
17. Negash, S., Sibhat, B., & Sheferaw, D. (2015).A postmortem study on indigestible foreign bodies in the rumen and reticulum of ruminants, eastern Ethiopia. *Onderstepoort Journal of Veterinary Research*, 82(1), 01-05.
18. Nugusu, S., Velappagounder, R., Unakal C., and Nagappan, R., 2013. Studies on Foreign Body Ingestion and their Related Complications in Ruminants Associated with Inappropriate Solid Waste Disposal in Gondar Town, North West

- Ethiopia, *International Journal of Animal and Veterinary Advances*, 5(2), 67–74.
19. Otsyina, H. R., Nguhiu-Mwangi, J., Mogoa, E. G. M., Ogara, W. O., & Mbutia, P. G. (2015). Prevalence of Indigestible Rumen Foreign Bodies in Sheep and Goats at Dagoretti and Kiserian Abattoirs, Kenya. *International Journal of Veterinary Science*, 4(2): 75-80.
 20. Radostits, O.M., Gay, C.C., Hinchcliff, K.W., and Constable, P.D., 2007. *Veterinary Medicine: A text book of diseases of cattle, sheep, pigs, goats, and horses*, 10th edition (Saunders Elsevier, Edinburgh London, pp. 313–522).
 21. Remi-Adewunmi, B.D., Gyang, E.O., and Osinowo, A.O., 2004. Abattoir survey of foreign body rumen impaction in small ruminants, *Nigerian Veterinary Journal*, 25, 32–38.
 22. Semieka MA (2010) Radiography of unusual foreign body in ruminants. *Veterinary World* 13: 473-475.
 23. Sheferaw, D., Gebru, F., Asrat, M., Tesfaye, D., & Debela, E. (2014). Ingestion of indigestible foreign materials by free grazing ruminants in Amhara Region, Ethiopia. *Tropical animal health and production*, 46(1), 247-250.
 24. Steele M (1996). *Goats: The tropical agriculturalist*. London: Macmillan education ltd. ACCT. Pp.79-83.
 25. Tesfaye, D., and Chanie, M. (2012). Study on rumen and reticulum foreign bodies in cattle slaughtered at Jimma Municipal Abattoir, South West Ethiopia. *American-Eurasian Journal of Scientific Research*, 7(4), 160-167.
 26. Tesfaye, D., Yismaw, S., & Demissie, T. (2012). Ruminant and reticular foreign bodies in small ruminants slaughtered at Jimma Municipal Abattoir, Southwestern Ethiopia. *Journal of Veterinary Advances*, 2(8), 434-439.
 27. Thompson, J. and Meyer, H. (1994): Body condition scoring of sheep and goats.
 28. Thrusfield, M. (2005): *Veterinary epidemiology*. 3rd ed. Singapore, Black well Science, Pp. 233.
 29. Tiruneh, R., & Yesuwork, H. (2010). Occurrence of rumen foreign bodies in sheep and goats slaughtered at the Addis Ababa Municipality Abattoir. *Ethiopian Veterinary Journal*, 14(1), 91-100.





Figure 2 and 3: Plastic, cloth and rope removed from rumen of three years old sheep