



GLOBAL JOURNAL OF MEDICAL RESEARCH: J  
DENTISTRY & OTOLARYNGOLOGY  
Volume 17 Issue 1 Version 1.0 Year 2017  
Type: Double Blind Peer Reviewed International Research Journal  
Publisher: Global Journals Inc. (USA)  
Online ISSN: 2249-4618 & Print ISSN: 0975-5888

# Cone Beam Computed Tomography Study of Intra-Sinus Calcifications

By Amine Khadija, Yassine Lahlou, Siham Chemlali, Jamila Kissa, Amina Gharibi  
& Mohammed Baite

**Summary- Introduction:** The intra-sinus calcifications are quite rare clinical entities and may be responsible for some sinus pathologies. The purpose of our work is to describe the intra-sinus calcifications, to identify their features and also the various sinus lesions in relation.

**Material and methods:** In this retrospective descriptive study, we reviewed radiological images obtained from cone beam acquisitions at a dental radiology center. The following variables were evaluated: the number, the shape, the location, the dimension, the nature and the localization of intra-sinus calcifications.

**Results:** 300 cone beam images were examined. 3% of cases of intra-sinus calcifications were found. The prevalence is as follows: Women accounted for 77.8% of the sample compared to 22.2% of men. A single calcification was found in 22.2% of cases, two calcifications in 44.4% of cases, and more than two calcifications in 33.4% of cases. The calcifications are located at the peripheral level in 88.9% of cases and at the central level in 11.1% of cases. The survey revealed that 35.7% of the calcifications are measuring less than 1 mm. 14.3% between 1 and 2 mm, 21.4% between 2 and 5 mm and 28.6% greater than 5 mm.

**Keywords:** maxillary sinus, calcifications, cone beam computed tomography.

**GJMR-J Classification:** NLMC Code: WV 340



CONE BEAM COMPUTED TOMOGRAPHY STUDY OF INTRA SINUS CALCIFICATIONS

Strictly as per the compliance and regulations of:



# Cone Beam Computed Tomography Study of Intra-Sinus Calcifications

Amine Khadija <sup>α</sup>, Yassine Lahlou <sup>σ</sup>, Siham Chemlali <sup>ρ</sup>, Jamila Kissa <sup>ω</sup>, Amina Gharibi <sup>¥</sup> & Mohammed Baite <sup>§</sup>

**Summary- Introduction:** The intra-sinus calcifications are quite rare clinical entities and may be responsible for some sinus pathologies. The purpose of our work is to describe the intra-sinus calcifications, to identify their features and also the various sinus lesions in relation.

**Material and methods:** In this retrospective descriptive study, we reviewed radiological images obtained from cone beam acquisitions at a dental radiology center. The following variables were evaluated: the number, the shape, the location, the dimension, the nature and the localization of intra-sinus calcifications.

**Results:** 300 cone beam images were examined. 3% of cases of intra-sinus calcifications were found. The prevalence is as follows: Women accounted for 77.8% of the sample compared to 22.2% of men. A single calcification was found in 22.2% of cases, two calcifications in 44.4% of cases, and more than two calcifications in 33.4% of cases. The calcifications are located at the peripheral level in 88.9% of cases and at the central level in 11.1% of cases. The survey revealed that 35.7% of the calcifications are measuring less than 1 mm. 14.3% between 1 and 2 mm, 21.4% between 2 and 5 mm and 28.6% greater than 5 mm. The shape of calcifications is round in 21.4%, nodular in 42.9%; linear in 7.1%, and punctate in 28.6% of cases. The calcifications are in a single sinus in 66.7% of cases and bilaterally in 33.3% of cases. The intra-sinus calcifications are idiopathic in 77.8% of cases. On the other hand, they are linked to dental paste overflow in 11.1% of cases and to a residual root in 11.1% of cases.

**Discussion and conclusion:** The intra-sinus calcifications show great variability. The cone beam is highly beneficial in finding incidental radiological images and the diagnosis of intra-sinus calcifications.

**Keywords:** maxillary sinus, calcifications, cone beam computed tomography.

## I. INTRODUCTION

Several sinus lesions reported in the literature are related to a great inter-individual anatomical variability (1,2). Among them are intra-sinus calcifications, which are defined as calcified masses in the maxillary sinus (3). Bowerman has introduced the term maxillary "antrolith" to distinguish it from nasal calcifications called "rhinoloth" (4). The study of intra-sinus calcifications has two major interests. They are found in maxillary sinusitis, especially in non-invasive

fungal sinusitis type "fungal ball" (5, 6,7). They also constitute an element to be noted during the preoperative radiological assessment for maxillary sinus augmentation surgery. To reduce per- and post-augmentation surgery. To reduce per- and post-operative complications during bone augmentation surgery, it is essential to be knowledgeable of the anatomy of the maxillary sinus but also of the various incidental findings including intra-sinus calcifications (8). The promising advances of cone beam allow a better understanding of the cases, a more precise diagnosis and therefore a better treatment (9).

The aim of this work was to carry out a descriptive study of intra-sinus calcifications in a Moroccan adult population using cone beam acquisitions. This description included the number, shape, location, size and nature of intra-sinus calcifications. The loco-regional environment of these calcifications has also been studied. From these elements, the pathogenesis responsible for these intra sinus calcifications has been discussed.

## II. MATERIALS AND METHODS

We performed a retrospective descriptive study carried out on the basis of cone beam images. The patients were examined between 2014 and 2016 at a dental radiology center for suspicion of included canines, implant surgery, ODF treatment, or sinusitis. The inclusion criteria were full visibility of the two maxillary sinuses on cone beam, and a sufficient images quality. The exclusion criteria were patients under 12 years of age, low resolution images, and the presence of metallic artefacts. All cone beam radiographic examinations were performed at a dental radiology center. The device has the following properties: setting 90 Kv, 10 Ma. The exposure time was 18. 402s. To collect the data necessary for our work, we have prepared a questionnaire with different parameters in order to study the two maxillary sinuses of each cone beam:

- 1) Sex
- 2) The shape of calcifications

We deduced four categories of shapes of intra-sinus calcifications from coronal sections: fine punctate, linear, round or nodular. When the shape of calcification was similar to a polygon or rectangle, it was classified as nodular. When the calcification was globular, it was

**Author α:** Professor, head of periodontics department of Casablanca dental school, Morocco. e-mail: aminekhadija@gmail.com

**Author ρ ω ¥:** Periodontics Department, Casablanca Dental School, Casablanca, Morocco.

**Author σ §:** Private practice, Casablanca, Morocco.

classified as round. When the calcification was similar to a straight, it was considered as linear.

- 3) *The location of the calcifications in the maxillary sinus*: central, peripheral.
- 4) *The number of calcifications*.
- 5) *The size of calcifications*: Four proposals were chosen for this variable: Less than 1 mm, between 1 and 2 mm, between 2 and 5 mm, greater than 5 mm. The value was determined by the measurement tool at scale 1; The largest according to coronal sections.
- 6) *Unilaterality*
- 7) *The nature of intra-sinus calcification*: pathological calcifications of dental origin found in aspergillus sinusitis as a result of an overflow of dental paste, calcifications related to dental residues displaced in the sinus, and idiopathic intra-sinus calcifications incidentally found whose circumstances of occurrence are unknown.

Characteristics of associated lesions:

- *Thickening of Schneider's membrane*: The measurement was performed between the point where the mucous thickening was maximal and the sinus floor.
- *Sinus ventilation*: has been evaluated by the freedom of the ostium of the maxillary sinus.
- Polyp and cyst: were determined by the presence of homogeneous, mono or poly-geodic sinus opacity with a regular contour.
- *Oro-antral communication (OAC)*: has been determined by the sinus membrane perforation.
- Presence or not of an inflammatory process of dental origin: was determined by the presence or not of a peri-apical lesion.

- Extra-sinus location of the calcifications: maxillary, mandibular.
- Condition of the sinuses with calcifications: healthy or pathological. A sinus is considered normal if there is no mucous thickening or a thickening less than 2 mm is observed. The underlying tooth may be healthy, decayed, extracted, with or without peri-apical reaction.

A descriptive statistical analysis was performed using the epi software. Info 7.

### III. RESULTS

The study involved cone beam images of 300 adult patients, including 194 women (64.67%) and 106 men (35.33%). 3% of intra-sinus calcifications were found. The prevalence of intra-sinus calcification was as follows (Table I): Women accounted for 77.8% of the sample compared to 22.2% of men. A single calcification was found in 22.2% of cases, two calcifications in 44.4% of cases, more than two calcifications in 33.4% of cases (fig 1). The calcifications were located at the peripheral level in 88.9% of cases and at the central level in 11.1% of cases (fig.2). 35.7% of calcifications were less than 1 mm, 14.3% between 1 and 2 mm, 21.4% between 2 and 5 mm and 28.6% were more than 5 mm (Figure 3). The shape of the calcifications was round in 21.4% of cases, nodular in 42.9% of cases, linear in 7.1% of cases and punctate in 28.6% of cases (fig.4). The calcifications were in a single sinus in 66.7% of cases and bilaterally in 33.3% of cases. Intra-sinus calcifications were idiopathic in 77.8% of cases. On the other hand, they were linked to an overflow of dental paste in 11.1% of cases and to a residual root in 11.1% of cases.

Table 1: Prévalence of lesions

Type de lésion	Pourcentage(%)
Thickening of the Schneider membrane	88.9
Polyp	44.4
Cyst	0
Oro-Antral Communication (OAC)	0
Inadequate Sinus Ventilation	77.78
Inflammatory process of dental origin	55.56
Pathological sinus condition	88.89
Maxillary position	11.11
Mandibular position	11.11

### IV. DISCUSSION

Maxillary sinusitis of dental origin are frequent affections of the ENT sphere, consisting of 10-12% of all maxillary sinusitis (10). The posterior maxillary teeth maintain an intimate relationship with the sinus floor; The latter extends from the first premolar to the maxillary tuberosity (9). The meta-analysis carried out in 2010 by Arias et al (11) reported that the major factor responsible

for odontogenic sinusitis was caused by iatrogenic maneuvers: dental avulsion, intra-sinus implant placement, overflow of root canal filling materials. The presence of foreign bodies in the sinus cavity constitutes a chronic irritation of sinus mucosa and can induce a thickening of the Schneider membrane as well as the formation of polyps and cysts (12). These foreign bodies create an environment conducive to the development of intra-sinus calcifications (13,14).

On the other hand, the edentulous posterior maxillary region challenges the practitioner with several difficulties; the most important one is the reduction of bone volume in this region. This is due to two concomitant phenomena; The first is the resorption of the post-extraction alveolar bone and the second is the pneumatization of the maxillary sinus (15,16,17). In order to overcome these constraints, several techniques have been developed: bone augmentation (18), short implants (19) or inclined implants (20). However, the stability of the latter is compromised due to the large occlusal forces (21). To prevent these complications, maxillary sinus augmentation with bone grafts has been approved as an interesting solution for reconstructing the deficient bone of the maxillary posterior region provided that the sinus is healthy (22).

The percentage of intra-sinus calcifications reported in this survey was 3%. This limited number is consistent with that found in another study that reported a prevalence of 3.2% (23). Detecting calcifications in the sinus depends on several factors. First, it depends on the radiologist's potential and experience in interpreting volumetric images (24). All radiopacity in the maxillary sinuses does not correspond to intra-sinus calcification. A differential radiological diagnosis must be established. It includes dental fragments, mucous retention cysts, follicular cysts, condensing osteitis, odontome, cementome, fibrous dysplasia, osteogenic sarcomas and foreign bodies (25, 3).

Calcifications may be single or multiple (23). In our study, one calcification was found in 22.2% of cases, two calcifications in 44.4% of cases and more than two calcifications in 33.3% of cases. These results are not in concordance with those found in the literature review of Güneri et al in 2005, which reported that of 26 cases 80.1% had a single calcification, 11.5% had two calcifications and 38.4 % had more than 2 calcifications (25). These differences can be explained by the size of the sample, the nature of the target population whose reason for consultation is predominantly dental, and the radiological interpretation that was performed by different radiologists.

The study found a higher percentage of women than men: 77.8% versus 22.2%. A large incidence in women or an equal distribution is reported (3). However, the study by Nass Duce et al found a frequency of 65% in men and 35% in women (23). These differences are explained by the inclusion and exclusion criteria chosen but also by the size of the sample.

The location of calcifications was a factor analyzed in this work: 88.9% of calcifications were located at the peripheral level while 11.1% at the central level. The location of intra-sinus calcifications has been studied by several authors mainly to distinguish fungal sinusitis from non-fungal (6, 7, 24). All concluded that the calcifications located at the central level would be in favor of a fungal sinusitis whereas those at the

peripheral level would direct the diagnosis towards a non-fungal chronic sinusitis. This factor is important, it allows ENT specialists to diagnose chronic fungal sinusitis type "fungal ball" faster and reduce treatment time and complications in immunocompromised patients (7).

The study of the shape of calcifications is just as important as the location. Round calcifications were reported in 21.4%, nodular in 42.9%, linear in 7.1% and punctate in 28.6% of cases. Different other studies described dissimilar values not only to our values but to each other (26,7,24).

Indeed, the punctate shape was found in 53.8%, 3.8% and 50% of cases in three different studies respectively, while we found it in 28.6% of cases in this work. These differences would be due to the fact that the shape is a subjective qualitative variable that depends on the interpretation of each radiologist according to the chosen cut. However, round calcifications are found only in non-fungal sinusitis whereas fine punctate calcifications are reported only in non-invasive fungal sinusitis type "fungal ball" (7). Also, it has been reported that the metaplastic para-parietal linear calcifications show a slow and ancient evolution in favor of chronic sinusitis. These calcifications must be distinguished from those caused by the presence of an aspergilloma (26).

This study revealed that the size of intra-sinus calcification was highly variable: 35.7% was less than 1%; 14.3% between 2 and 5 mm, 21.4% between 2 and 5 mm and 28.6% greater than 5 mm. No study has assessed the distribution of intra-sinus calcifications according to their size. Only isolated cases of calcifications found incidentally occur, the size of which can reach 3 cm (27). Other studies refer to small calcifications or even micro-calcifications (28). However, if small calcifications are often asymptomatic, large calcifications are accompanied by facial pain, nasal obstruction, epistaxis and require surgery (29,25).

In our study, the distribution of intra-sinus calcifications according to their location showed that in 66.7% of cases one maxillary sinus (FIG. 5) was involved, whereas in 33.3% of cases both maxillary sinuses were involved. Nass Duce et al. And Güneri et al. studied the unilateral or bilateral localization of intra-sinus calcifications (23,25). They reported a higher frequency of unilaterality compared to bilateral location, which agrees with our results. The presence of intra-sinus calcifications in a single sinus would be considered as a major sign in favor of non-invasive fungal sinusitis type "fungal ball" (5).

The distribution of calcifications according to their nature revealed that 11.1% of cases were related to an overflow of paste, 11.1% were related to residual root and 77.8% of calcification cases were considered idiopathic. The presence of foreign bodies in the sinus was strongly incriminated in intra-sinus calcifications



(30). Nass Duce et al reported that of 26 cases of intra-sinus calcification, 16 had a history of dental extraction, 61.5% versus 11.1% in our study. (23) The comparison is difficult given the lack of information in patient records. The overflow of dental paste in the sinus and its consequences has been widely discussed in several studies. Haanaes et al showed that toxins from a necrotic pulp could cause decalcification of the bony wall between the periapical region and the maxillary sinus, which would increase the risk of extrusion of root canal filling materials into the maxillary sinus (31).

Dental paste in the maxillary sinus may favor the development of a fungal infection with aspergillus called aspergillosis (32). Non-invasive aspergillosis of maxillary sinus is associated with 50% of the presence of endodontically propelled root canal filling cement. (30) Two types of cement were the most implicated: zinc oxide eugenol and calcium hydroxide (33,34). Zinc is considered as a growth factor of aspergillus. It leads to impaired epithelial function by mucociliary paralysis associated with edema and soft tissue hyperaemia, which will disrupt the sinus drainage and lead to an accumulation of calcium salts causing intra-sinus calcification (30). On the other hand, calcium hydroxide constitutes both a chemical irritant and a foreign body. The calcification process is due to subsequent tissue necrosis (31). Its anti-inflammatory and antibacterial effect would explain the absence of symptoms in patients with intra-sinus calcification (13,25).

Intra-sinus calcifications are classified as true and false calcifications depending on the origin of the nucleus. The source of true calcifications is an endogenous nucleus such as mucus, pus or mycoses, whereas the origin of false calcifications is exogenous, that is to say foreign bodies such as residual roots or paste overflow (29). Calcifications of exogenous origin have been the subject of several studies (23,25). However, no consensus has yet been reached to explain the process responsible for the occurrence of endogenous calcifications.

Several theories are put forward. First, the ventilation of the maxillary sinus would be responsible. The ventilation of the maxillary sinus via its ostium is essential to maintain its biological balance. It was found decreased in 78% of the cases in our work. Mucus in the sinus plays a major role as a protective colloid so that the salts do not concentrate. (36) However, once the inflammation is established, sinus ventilation is impaired, sinus drainage is compromised, mucous secretions accumulate, increase PH, change the mineral environment and lead to the precipitation of calcium salts which would lead to the formation of intra-sinus calcifications. (29)

Second, the formation of idiopathic calcifications of endogenous origin is linked to the osteogenic power of the Schneider membrane. Srouji et al. analyzed the osteogenic potential of the human

maxillary sinus Schneider membrane using in vitro and in vivo assays. (37) Samples of the membrane were used to prepare cell cultures for histological studies. The results showed that the cells derived from these membrane extracts grow in culture and express markers of osteoprogenitor cells (alkaline phosphatase, protein 2 specific to bone morphogenesis, osteopontin, osteonectin and osteocalcin). Mineral deposits have also been found including phosphate and calcium ions. Once differentiated, these membrane-derived cells were transplanted in vivo. Therefore, histological evidence of osteogenesis has been found at the site of transplantation. The results of this study showed the presence of osteoprogenitor cells at the Schneider membrane and asserted its osteogenic potential. However, the precise location of these osteoprogenitor cells among the layers constituting the Schneider membrane was not determined. The authors have referred to the richly vascularized chorion but also to the connective tissue similar to the periosteum next to the maxillary bone. The osteogenic potential of the Schneider membrane has been approved by several authors and in several studies. (38,39) It would explain the significant success of dental implants (93.5%) placed in the atrophied maxillary posterior region; With a residual bone of 5 mm to 9 mm: these implants are placed "in a tent pole" without using bone substitutes but only by providing space for the blood clot (40). This technique eliminates the high cost of bone substitutes but also reduces the risk of post-operative complications related to bone grafting (41). Indeed Schneider's membrane plays the role of framework for the multiplication of bone cells and their maturation (42). More studies are needed to be able to predict bone formation by focusing on the individual potential of each patient. (40)

The thickness of the sinus mucosa was measured in several studies. In the present study, thickening of the sinus mucosa was reported when the thickness of the mucosa was greater than 1 mm. (FIG. 6). Its prevalence was 88.9%. Other studies have reported a prevalence ranging from 48.4% to 66% (2,8). This difference may indicate that the presence of intra-sinus calcification is a contributing factor to the thickening of the sinus mucosa. It should be noted, however, that thickening of the sinus mucosa is not necessarily a sign of pathology. Allergic reactions and smoking are factors correlated with an increase in the thickness of the sinus mucosa. (43)

Antral polyps are the most common benign pathologies of the maxillary sinus. Their prevalence varies between 1.4% and 25% (2,8). Our study found a prevalence of 44%. This high frequency would indicate a relationship between the presence of antral polyps and intra-sinus calcifications.

In our study, 55% of calcifications were related to inflammatory processes of dental origin. A study of

sinus abnormalities reported that 64.3% of these abnormalities were related to dental inflammatory lesions. (44) This value is in accordance with the results of our work. Estrela et al report large bone formation in the maxillary sinus associated with periapical inflammatory lesions of endodontic origin (45). These periapical lesions would act on the periosteum constituting the internal surface of Schneider's membrane. They would result in osteolysis leading to bone formation through immature bones containing a high number of osteocytes and collagen fibers. (46) These reactive osseous formations are to be distinguished from intra-sinus calcifications.

The study of the state of maxillary sinus revealed that in 88.9%, the sinus is pathological. This result is consistent with another study that reported 80.8% of the sinuses containing calcifications were pathological. (23) The inflammatory and pathological condition of the sinus is essential for planning for sinus augmentation surgery. It involves effective communication with the ENT specialist in order to avoid post-operative complications specific to each pathology (26).

In addition to intra-sinus calcifications, this study made it possible to identify calcifications in the

maxillary (11.1%) and the mandible (11.1%). Radiopaque alterations in the maxillary and mandibular region are often found incidentally. They always raise the question of diagnostic and therapeutic consequences. It should be noted that radiological signs guide the differential diagnosis but it is the clinical signs and especially histological examinations that confirm the definitive diagnosis. (47)

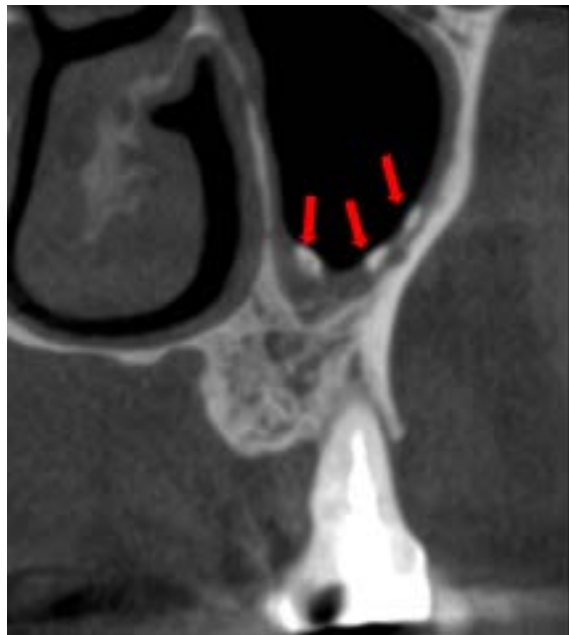## V. LIMITATIONS OF THE STUDY

This study has been limited by a number of factors:

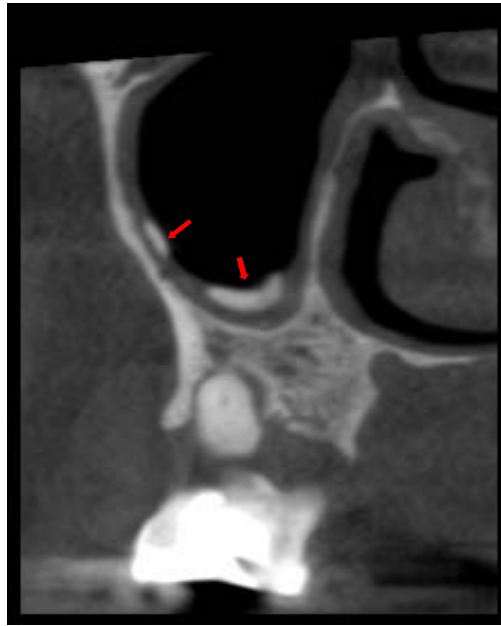
- The study was conducted retrospectively in a dental radiology center. The reasons for consultation were mainly implant surgery, an inclined canine suspicion and an ODF treatment, hence the low prevalence of intra-sinus calcifications found.
- Only adult patients were included in the study; but, analysis by age group was not possible given the lack of information on patient records.

*Competing interests:*

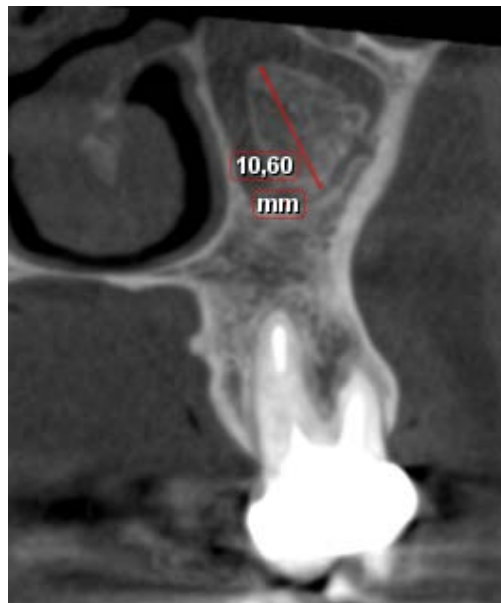
"The author(s) declare(s) that there is no conflict of interest regarding the publication of this paper."



*Fig.1:* Three calcifications in the left maxillary sinus

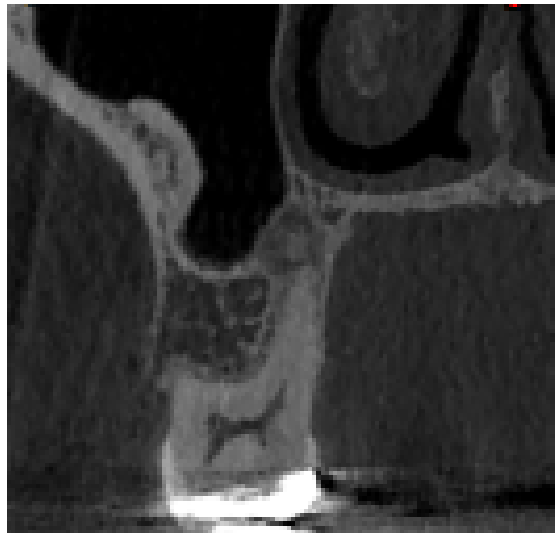

*Fig. 2:* Peripheral location of intra sinus calcifications

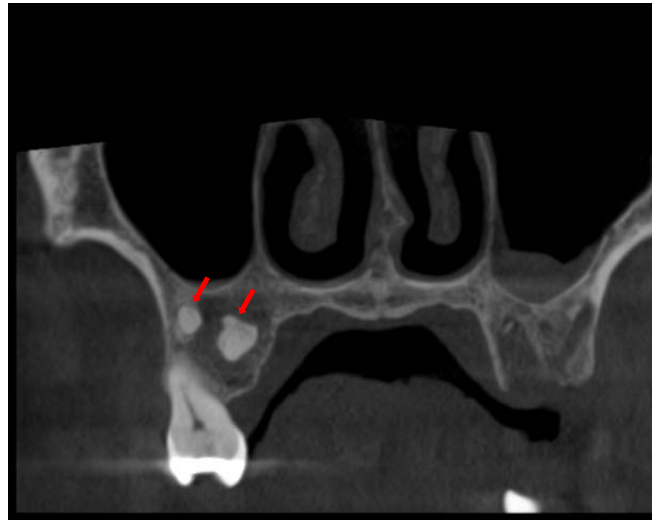


*Fig. 3:* Intra-sinus calcification greater than 5 mm

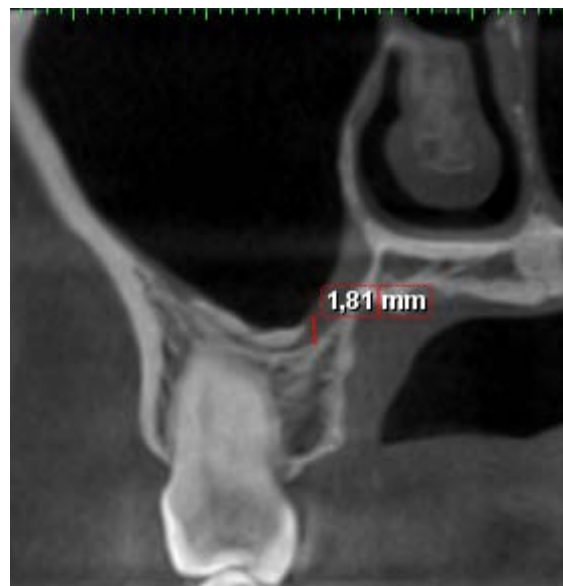



*Fig. 4:* Intra-sinus calcification of nodular shape



*Fig. 5:* Unilateral localization of calcifications



*Fig. 6:* Mucous thickening of the Schneider membrane associated with intra-sinus calcification



## REFERENCES RÉFÉRENCES REFERENCIAS

- Sahlstrand-Johnson P, Jannert M, Strombeck A, Abul-Kasim K. Computed tomography measurements of different dimensions of maxillary and frontal sinuses. *BMC Medical Imaging* 2011; 11(8).
- Lana JP, Carneiro PM, Machado Vde C, de Souza PE, Manzi FR, Horta MC. Anatomic variations and lesions of the maxillary sinus detected in cone beam computed tomography for dental implants. *Clin Oral Implants Res.* 2012 Dec; 23 (12): 1398-403.
- Karges MA, Eversole LR, Poindexter BJ Jr. Antrolith: report of case and review of literature. *J Oral Surg.* 1971 Nov; 29 (11): 811-4.
- Bowerman JE. The maxillary antrolith. *J Laryngol Otol.* 1969 Sep; 83 (9): 873-82.
- Dhong HJ, Jung JY, Park JH. Diagnostic accuracy in sinus fungus balls: CT scan and operative findings. *Am J Rhinol.* 2000 Jul-Aug; 14 (4) :227-3.
- Seo YJ, Kim J, Kim K, Lee JG, Kim CH, Yoon JH. Radiologic characteristics of sinonasal fungus ball: an analysis of 119 cases. *Acta Radiol.* 2011 Sep 1; 52 (7): 790-5.
- Yoon JH, D GN, Hong SB, Young HK, Seung KC, Dong HJ. Calcification in Chronic Maxillary Sinusitis: Comparison of CT Findings with Histopathologic Results; *AJNR Am J Neuroradiol* 20: 571–574, April 1999.
- Rege IC1, Sousa TO, Leles CR, Mendonça EF. Occurrence of maxillary sinus abnormalities detected by cone beam CT in asymptomatic patients. *BMC Oral Health.* 2012 Aug 10; 12: 30.
- Maillet M, Bowles WR, McClanahan SL, John MT, Ahmad M. Cone-beam computed tomography evaluation of maxillary sinusitis. *J. Endod.* 2011 Jun; 37 (6): 753-7.
- Itzhak B. Sinusitis of odontogenic origin. *Otolaryngol. –Head and Neck Surgery* 2006 sep, Vol 135, No 3.
- Arias-Irimia O, Barona-Dorado C, Santos-Marino JA, Martínez-Rodríguez N, Martínez-González JM. Meta-analysis of the etiology of odontogenic maxillary sinusitis. *Med Oral Patol Oral Cir Bucal.* 2010 Jan 1; 15 (1): e70-3.
- Vishniakov VV, Makarova NV, Pashovkina OV. Changes in the mucous membrane of the patients with chronic maxillary sinusitis caused by foreign bodies. *Vestn Otorinolaringol.* 2014; (1): 12-4.
- Cohen MA1, Packota GV, Hall MJ, Steinberg J. Large asymptomatic antrolith of the maxillary sinus. Report of a case. *Oral Surg Oral Med Oral Pathol.* 1991 Feb; 71 (2): 155-7.
- Shenoy V, Maller V, Maller V. Maxillary Antrolith: A Rare Cause of the Recurrent Sinusitis. *Case Reports in Otolaryngol.* 2013; 2013: 527152.
- Hansson S, Halldin A. Alveolar ridge resorption after tooth extraction: A consequence of a fundamental principle of bone physiology.
- J. of Dent. Biomechanics.* 2012; 3.
- Van den Bergh JP1, ten Bruggenkate CM, Disch FJ, Tuinzing DB. Anatomical aspects of sinus floor elevations. *Clin Oral Impl Res* 2000; 11: 256–265.
- Sharan A, Madjar D. Maxillary sinus pneumatization following extractions: a radiographic study. *Int J Oral Maxillofac Implants* 2008 Jan Feb, 23 (1): 48-56.
- Chiapasco M1, Casentini P, Zaniboni M. Bone augmentation procedures in implant dentistry. *Int J Oral Maxillofac Implants.* 2009; 24 Suppl: 237-59.
- Monje A, Chan HL, Fu JH, Suarez F, Galindo-Moreno P, Wang HL. Are short dental implants (<10mm) effective? A meta analysis on prospective clinical trials. *J Periodontol.* 2013 Jul; 84 (7): 895-904.
- Monje A, Chan HL, Suarez F, Galindo-Moreno P, Wang HL. Marginal bone loss around tilted implants in comparison to straight implants: a meta-analysis. *Int J Oral Maxillofac Implants.* 2012 Nov-Dec; 27 (6): 1576-83.
- Friberg B, Jemt T, Lekholm U. Early failures in 4. 641 consecutively placed Brainemark dental implants: a study from stage 1 surgery to the connection of completed prostheses. *Int J Oral Maxillofac Implants.* 1991 Summer; 6 (2): 142-6.
- Wallace SS, Froum SJ. Effects of maxillary sinus augmentation on the survival of endosseous dental implants. A systematic review. *Ann Periodontol.* 2003 Dec; 8 (1): 328-43.
- Nass Duce M, Talas DU, Ozer C, Yildiz A, Apaydin FD, Özgür A. Antrolithiasis: a retrospective study. *J Laryngol Otol.* 2003 Aug; 117 (8): 637-40.
- Chen CM, SUIH, Yeow KM. Unilateral Paranasal Sinusitis Detected by Routine Sinus Computed Tomography: Analysis of Pathology and Image Findings. *J RadiolSci* 2011; 36: 99-104.
- Güneri P1, Kaya A, Çalışkan MK. Antroliths: survey of the literature and report of a case. *Oral Surg Oral Med Oral Pathol Oral RadiolEndod.* 2005 Apr; 99 (4): 517-21.
- Hodez C, Griffaton-Taillandier C, Bensimon J-L. Imagerie par faisceau conique « conebeam ». Applications en ORL. *Annales fr. d'Orl et de pathol. cervico-fac.* (2011): 128, 77-91.
- Cohen MA1, Packota GV, Hall MJ, Steinberg J. Large asymptomatic antrolith of the maxillary sinus. Report of a case. *Oral Surg Oral Med Oral Pathol.* 1991 Feb; 71 (2): 155-7.
- Jiang Z, Zhang K, Huang W, Yuan Q. A Preliminary Study on Sinus Fungus Ball with MicroCT and X-Ray Fluorescence Technique. *PLoS One.* 2016 Mar 15; 11 (3): e0148515.

30. Davis O, Wolff A. Rhinolithiasis and maxillary antrolithiasis. *Ear Nose Throat J.* 1985 Sep; 64 (9): 421-6.
31. Delbet C., Barthélémy I., Teitelbaum J., Devoize L. Mycoses aspergillaires des sinus maxillaires. *Encycl. Med. Chir., Médecine buccale*, 2011, 28-275-I-10.
32. Haanaes HR, Høpse HU, Stenvik A, Stermer Beyer-Olsen EM, Bjørnland T. Effect of calcium hydroxide implantation in maxillary sinus in macaques.
33. Endod, Dent, Traumatol. 1987 Oct; 3 (5): 229-32.
34. Wu CW, Tai CF, Wang LF, Tsai KB, Kuo WR. Aspergillosis: a nidus of maxillary antrolith. *Am J Otolaryngol.* 2005 Nov-Dec; 26 (6): 426-9.
35. Kim J-W, Cho K-M, Park S-H, Park S-R, Lee S-S, Lee S-K. Chronic maxillary sinusitis caused by root canal overfilling of Calcipect II. *Rest. Dent. Endod.* 2014 Feb; 39 (1): 63–67.
36. Odell E, Pertl C. Zinc as a growth factor for *Aspergillus* sp. and the antifungal effects of root canal sealants. *Oral Surg Oral Med Oral Pathol Oral Radiol Endod.* 1995 Jan; 79 (1): 82-7.
37. Shenoy V, Maller V, Maller V. Maxillary Antrolith: A Rare Cause of the Recurrent Sinusitis. *Case Reports in Otolaryngology.* 2013; 2013: 527152.
38. Montaudon M, Blachère H, Laurent F. Sinus de la face : technique d'imagerie, résultats normaux et pathologie inflammatoire. *La lettre d'Oto-rhinolaryngologie et de lachirurgie cervico-faciale.* 2001 JAN; 259.
39. Srouji S, Kizhner T, Ben David D, Riminucci M, Bianco P, Livne E. The Schneiderian membrane contains osteoprogenitor cells: in vivo and in vitro study. *Calcif Tissue Int.* 2009 Feb; 84 (2): 138-45.
40. Berbéri A, Al-Nemer F, Hamade E, Noujeim Z, Badran B. Mesenchymal stem cells with osteogenic potential in human maxillary sinus membrane: an in vitro study. *Clin Oral Investig.* 2016 Sep.
41. Srouji S, Ben-David D, Lotan R, Riminucci M, Livne E, Bianco. The innate osteogenic potential of the maxillary sinus (Schneiderian) membrane: an ectopic tissue transplant model simulating sinus lifting. *Int J Oral Maxillofac Surg.* 2010 Aug; 39 (8): 793-801.
42. Ginnady P, Juodzbalys G. Graft-Free Sinus Augmentation Procedure: a Literature Review *J Oral Maxillofac Res.* 2014 Jan-Mar; 5 (1): e1.
43. Pérez-Martínez S, Martorell-Calatayud L, Peñarrocha-Oltra D, García-Mira B, Peñarrocha-Diogo M. Indirect sinus lift without bone graft material: Systematic review and meta-analysis. *J. of Clin. and Experimental Dentist.* 2015; 7 (2): e316-e319.
44. Rahpeyma A, Khajehahmadi S, Khalife HH. Decellularized human Schneiderian membrane: electron microscopic study as a bioscaffold and preliminary cell seeding. *Pathol Res Pract.* 2014 Dec; 210 (12): 965-70.
45. Zitzmann NU, Dagassan-Berndt DC, Lambrecht JT, Weiger R, Walter C. Is the Schneiderian membrane thickness affected by periodontal disease? A cone beam computed tomography based extended case series. *J Int Acad Periodontol* 2013; 15: 75-82.
46. Nunes CA, Guedes OA, Alencar AH, Peters OA, Estrela CR, Estrela C. Evaluation of Periapical Lesions and Their Association with Maxillary Sinus Abnormalities on Cone-beam Computed Tomographic Images. *J Endod.* 2016 Jan; 42 (1): 42-6.
47. Estrela C, Porto OC, Costa NL, Garrote Mda S, Decurcio DA, Bueno MR, Silva BS. Large Reactional Osteogenesis in Maxillary Sinus Associated with Secondary Root Canal Infection Detected Using Cone-beam Computed Tomography. *J Endod.* 2015 Dec; 41 (12): 2068-78.
48. Liao J, Shahrini MA, Al-Habibi M, et al. Cells isolated from inflamed periapical tissue express mesenchymal stem cell markers and are highly osteogenic. *J Endod* 2011; 37:1217–24.
49. Lanzer M, Yildirim A, Kruse A, Grätz K, Lübbers H-T. Calcifications radiologiques anormales en médecine dentaire. *Swiss dent.j.* 2015 Mar; 125: 315-31.