



GLOBAL JOURNAL OF MEDICAL RESEARCH: K
INTERDISCIPLINARY
Volume 17 Issue 3 Version 1.0 Year 2017
Type: Double Blind Peer Reviewed International Research Journal
Publisher: Global Journals Inc. (USA)
Online ISSN: 2249-4618 & Print ISSN: 0975-5888

Bacterial Endogenous Endophthalmitis

By Francis Kwasi Obeng, Vipin Kumar Vig, Preetam Singh, Rajbir Singh,
Kanwardeep Singh & Nikhil Sahajpal

Abstract- Background: Bacterial endogenous endophthalmitis (BEE) is uncommon and severe. Few patients who have this disease are initially misdiagnosed. Its victims usually have an underlying disease which predisposes them to infection. Blood and vitreous cultures are the most frequently used media of establishing the diagnosis. Staphylococcus aureus, group B streptococci, Streptococcus pneumonia and Listeria monocytogenes are the commonly found Gram positive organisms. The most common Gram negative causative bacteria are Klebsiella spp., Escherichia coli, Pseudomonas aeruginosa, and Neisseria meningitidis. Gram negative organisms are responsible for the majority of cases reported from East Asian hospitals, but Gram positive organisms are more common in the developed world. Apart from being rare, BEE has very little literature and there has not been any publication on it in Northern India emphasizing on its management to the best of our knowledge.

Keywords: endophthalmitis, metastatic, bacterial, ocular barriers, vitreous inflammation.

GJMR-K Classification: NLMC Code: QW 180



Strictly as per the compliance and regulations of:



Bacterial Endogenous Endophthalmitis

Francis Kwasi Obeng ^α, Vipan Kumar Vig ^σ, Preetam Singh ^ρ, Rajbir Singh ^ω, Kanwardeep Singh ^{*}
& Nikhil Sahajpal [§]

Abstract- Background: Bacterial endogenous endophthalmitis (BEE) is uncommon and severe. Few patients who have this disease are initially misdiagnosed. Its victims usually have an underlying disease which predisposes them to infection. Blood and vitreous cultures are the most frequently used media of establishing the diagnosis. *Staphylococcus aureus*, group B streptococci, *Streptococcus pneumoniae* and *Listeria monocytogenes* are the commonly found Gram positive organisms. The most common Gram negative causative bacteria are *Klebsiella* spp., *Escherichia coli*, *Pseudomonas aeruginosa*, and *Neisseria meningitidis*. Gram negative organisms are responsible for the majority of cases reported from East Asian hospitals, but Gram positive organisms are more common in the developed world. Apart from being rare, BEE has very little literature and there has not been any publication on it in Northern India emphasizing on its management to the best of our knowledge. To fill in this gap in research, we evaluated the use of systemic antibiotics with intravitreal antibiotics and steroids (SAIAS) and/or pars plana vitrectomy (PPV) in treating patients diagnosed with BEE.

Aim: To assess the complication rate and visual outcomes of BEE after the use of SAIAS and/or PPV in a cohort of Indian patients who visited our hospital in Northern India.

Material and Method: Records of all patients who were diagnosed with BEE and managed at our hospital from 2007 to 2015 were reviewed retrospectively for visual outcomes and complications. Patients' demographic data, predisposing medical conditions, ocular features, extraocular manifestation of infection, Gram staining, treatment, best corrected visual acuity (BCVA) before and after treatment, indications for any further surgical procedures and length of follow up were collected and analysed.

Results: 31 eyes of 29 patients (19 males and 10 females) were identified. Mean age at presentation was 41.8 ± 18 years (range 3 – 81 years) with a mean follow up 11.1 ± 22.7 months (range 1- 96 months). 54.84%, 32.26% and 12.90% of eyes had maintenance, improvement and worsening of BCVA respectively at the last review. 16 (51.61%) of 31 eyes had complications from BEE the most common of which was rhegmatogenous retinal detachment (RRD).

Conclusion: Timely use of SAIAS and/or PPV in treating patients with BEE is a preferred method. The visual outcomes and complication profile of our centre are better compared to other case series. Although patients have benefitted massively from our therapeutic regimen, they should be informed on diagnosis that BEE itself is fraught with complications with baseline reporting BCVA being the best visual prognostic factor.

Keywords: endophthalmitis, metastatic, bacterial, ocular barriers, vitreous inflammation.

1. INTRODUCTION

A gist of protective structures whose breakdown leads to intraocular infection and inflammation helps in better understanding of BEE. There are two main blood ocular barriers (BOB): blood aqueous barrier (BAB) and blood retinal barrier (BRB). Whereas the former is made up of non-pigmented ciliary epithelium and endothelium of iris vessels, the latter is further categorized into an inner and outer parts. The inner portion comprises tight junctions between endothelial cells of retinal capillaries and the outer, tight junctions between hexagonally shaped retinal pigment epithelial cells. Being similar to blood brain barrier, the BRB is restrictive and regulates ion, protein and water flux into and out of the retina.¹

Endophthalmitis refers to purulent inflammation of vitreous and aqueous due to infection as a result of breakdown of BOB paving way for microbial invasion into the eye.² Depending on its causative organism, it can be classified into bacterial, fungal, protozoal, parasitic and viral although the first two are the most common. The route of infection can make it endogenous, in which the causative agent is from within the body or exogenous, characterized by external invasion.

Rare though it is, BEE is potentially devastating resulting in guarded visual prognosis. Albeit patients generally present with underlying systemic infections such as liver abscess, sinusitis, endocarditis or any other infection in any part of the body, in 44% of cases no source of infection is found according to a study published by Binder *et al.*³ Jackson *et al* also documented in their study that in 70% of cases the source of infection is known inferring that the etiology is not known in 30%.⁴ Another study has emphasized that the great majority of individuals with BEE have either diabetes mellitus, heart disease or malignancy as the main etiology.⁵ Due to its hematogenous spread from a focus of infection, a systemic work up for detection of the source of infection is critical in its management. It is important that prompt diagnosis is made and appropriate treatment started to preserve vision and avoid mortality. A high index of suspicion, accuracy and clinical judgment with collaborative input from the ophthalmologist, physician specialist and microbiologist are therefore paramount to the successful management of BEE.

Author ^{α σ ρ ω §}: Vitreo-Retinal Center, Sadar Bahadur Dr. Sohan Singh Eye Hospital, Amritsar, India. e-mail: fobeng37@yahoo.com

II. MATERIALS AND METHODS

A 9-year retrospective study from 2007 to 2015 was conducted in our hospital with a minimum follow-up of 1 month. We have three experienced vitreoretinal surgeons, a physician specialist who helps in the management of systemic diseases with ocular complications and a microbiologist. Institutional ethical approval was required for this research and in a wider dimension, the tenets of Declaration of Helsinki applied in an attempt to respect human rights of the participants. Patients' demographic data, predisposing medical conditions, ocular features, extraocular manifestation of infection, Gram staining, treatment, BCVA before and after treatment, indications for any further surgical procedures and length of follow up were collected and analysed. Out of the 40 patients whose medical records were reviewed, 11 were excluded from the study because they were either followed up for less than 1 month, lost to follow up, had had intraocular surgery within 1 year of presentation or involved in recent trauma to the eye. The vitreoretinal surgeons made all major decisions in consultation with the physician specialist and microbiologist.

Blood and vitreous samples for culture were taken from all patients with provisional diagnosis of BEE. Being rare contaminants of blood and vitreous cultures, Gram negative bacteria were very significant if isolated in either of the two fluids. On the other hand, Gram positive infection was significant if it was isolated in more than one culture plate. Our incubation period was up to 7 days at a temperature of 37°C.

All specimens were taken under sterile conditions in operating theatre after the last non-infected case of the day. 0.2 ml of vitreous was taken by entering the eye through a sclera point 3.5 mm away from the limbus. Depending on microscopy report which we got

in few minutes, we chose the appropriate antibiotic and injected it intravitreally. If the causative organism was not identified by the laboratory, we routinely used 2 mg in 0.1 ml of vancomycin against Gram positive and 2 mg in 0.1 ml of ceftazidime against Gram negative bacteria. All patients also received intravitreal injection of 0.1 ml of dexamethasone to combat against the associated inflammation. If the presenting visual acuity was perception of light, we primarily performed 3 port PPV, a procedure which was also utilized as second line treatment for patients who did not respond to the initial SAIAS. Patients who had associated retinal detachment had belt buckling (BB) in addition to the PPV.

Positive blood cultures coupled with antibiotics capable of crossing the BOB helped us make systemic antibiotic choice. Patients in whom blood cultures were negative were put on systemic ciprofloxacin tablets (cifran) 500, 750 mg or less twice daily depending on their body weight for 14 days.

The Snellen BCVA was converted into logarithm of minimum angle of resolution (log MAR) units for statistical analysis. Patients whose visual acuities were hand motion and light perception were assigned the equivalence of 1.7 log MAR units. The χ^2 test was used to determine relationships between categorical variables and the paired t test, normally distributed variables. All tests were considered to be statistically significant if the p value was 0.05 or less.

Table 1: BCVA after Treatment

SRL	Quality	Number of Eyes	Percentage
1	Maintenance	17	54.84
2	Improvement	10	32.26
3	Worsening	4	12.90
	Total	31	100.00

Table 2: Underlying Diseases Causing BEE

SRL	Disease	Number of Patients	Percentage
1	Type 2 Diabetes Mellitus	11	37.93
2	Urinary Tract Infection	5	17.24
3	Pneumonia/Bronchopneumonia	4	13.79
4	Ischaemic Heart Disease	3	10.35
5	Hepatitis C	2	6.90
6	Infected Skin Wound	2	6.90
7	Tuberculosis	1	3.45
8	No Focus of Infection	1	3.45
	Total	29	100

Table 3: Complications of BEE and Management

SRL	Complication	Number	Percentage	Management
1	Rhegmatogenous Retinal Detachment	8	50.00	BB+PPV+FLUID AIR EXCHANGE+ ENDOLASER+SILICONE OIL
2	Complicated Cataract	3	18.75	BB+LENSECTOMY+PPV
3	Phthisis	2	12.50	REFERRAL TO ORBIT AND OCULOPLASTIC SPECIALIST
4	Multifocal Choroiditis	2	12.50	SYSTEMIC STEROIDS+TREATMENT OF UNDERLYING DISEASE
5	Macular Scar	1	6.25	OBSERVATION
	Total	16	100	

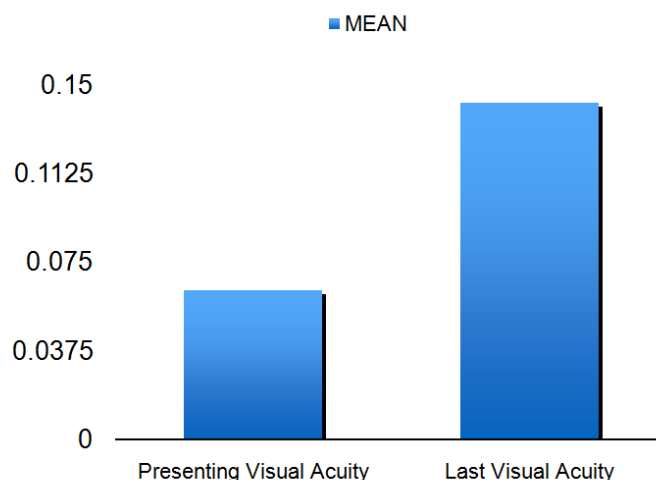
III. RESULTS

During the study, 29 patients (31 eyes) were diagnosed with BEE. There were 19 (65.52%) males and 10 (34.48%) females with a mean age of 42 years (SD 18; range 3-81). There was right eye (n=15; 51.73%) preponderance over left (n=12; 41.38%) but in all the condition was bilateral in 2 (6.89%) patients. The most common presenting and last follow up visual acuities were light perception and counting fingers at 1 metre

respectively. The mean difference between the final postoperative BCVA at last visit and presenting visual acuity was 1.1 ± 0.9 log MAR units which was significant statistically. ($p = 0.04$) This is shown in the graph pad below with its corresponding table. All data are expressed as Mean \pm SD. The graph pad software version 5.0 was used to analyze data. The numerical data was compared using t test.

Presenting Visual Acuity	Last Visual Acuity	P VALUE
0.06 ± 0.17	0.14 ± 0.30	0.04 *

All values expressed as Mean \pm SD.



As at the last visit after all therapeutic interventions, 17 (54.84%), 10 (32.26%) and 4 (12.90%) eyes had maintenance, improvement and worsening of their visual acuities respectively as shown in table 1. Fifteen eyes had hypopyon and ocular hypertension at presentation. Other clinical features in our case series included ocular pain, blurred vision, swollen eyelids, injected and chemosed conjunctiva, anterior chamber inflammation as well as poor red reflex and fundal view due to intraocular inflammation. The examination of patients with ocular medial opacification was complemented with B-scan ultrasonography. Initially misdiagnosed as having acute anterior uveitis, 4

(13.79%) patients had a 3-day delay in appropriate diagnosis and effective treatment of the disease. 28 (96.55%) patients had an underlying medical condition which made them vulnerable to infection and in 12 (41.38%), the underlying disease was previously undiagnosed. As shown in table 2, organized from most to least common predisposing systemic diseases detected in our study were type 2 diabetes, urinary tract infection, pneumonia/bronchopneumonia, ischaemic heart disease, hepatitis C, infected wound and tuberculosis.

All patients had positive vitreous or blood cultures. Vitreous culture was positive in 50% of cases

and blood, 60%. In all, Gram positive organisms were found in 21 (67.74%) eyes with the remaining 10 (32.26%) being Gram negative. Prognosis was guarded in the Gram negative group. The most common Gram positive and negative bacteria found were *Staphylococcus aureus* and *Klebsiella* respectively. All our patients did not only receive appropriate treatment of underlying diseases but also oral ciprofloxacin as well as intravitreal vancomycin, ceftazidime and dexamethasone. Out of the total number, however, 16 (51.61%) eyes had further treatment with PPV on not responding to the previous management. Table 3 shows the complications we had and their management. The visual outcome was generally poor with count fingers at 1 metre or worse in 25 (80.65%) eyes. Patients who presented with visual acuity of 6/36 or better retained useful vision. Eyes which underwent vitrectomy had markedly reduced chances for evisceration and enucleation.

IV. DISCUSSION

Being rare, BEE has a prevalence rate of 2 to 8% of all endophthalmitis.⁵

The use of SAIAS and/or PPV is the best approach in the management of patients with BEE compared to other therapeutic regimen: intravitreal antibiotics with steroids alone or intravitreal treatment with systemic antibiotics or PPV alone. The aim of this study was to assess the complication rate and visual outcome of BEE after the use of SAIAS and/or PPV in a cohort of Indian patients who presented to our facility. In general our results show favorable outcomes compared to other studies. We did not register any mortalities from systemic complications of the underlying diseases. BCVA was maintained, improved and worsened in 54.84%, 32.26% and 12.90% of eyes respectively.

a) Patients' Details

The mean age of incidence of BEE, according to a study published by Wong *et al*, is 52 years.⁶ In our study the mean age was 41.83 years, a parameter which does not differ much from other case series. As reported in other publications, our research showed more males (65.52%) affected by BEE than females (34.48%).^{4, 5} The reason for this difference could be that men, unlike women, are more willing to travel when referred to specialized hospitals. A recent research result published by Zeng *et al* has established that men have thicker choroid than women.⁷ They may therefore have bigger choriocapillaries which transport more bacteria to the vitreous than women albeit more studies are needed to corroborate it.

Our study as shown in table 2, like what has been published in other reviews, has demonstrated that the extraocular foci mostly affected are liver, lung, endocardium and urinary tract.⁴ According to Binder *M et al*, a diagnosis of BEE merits systemic workup for the

source of infection although in 44% of cases no source is found.³ In the publication made by Jackson *et al*, it was also revealed that 40% of BEE patients may not have an underlying systemic disease and if they do, then type 2 diabetes, intravenous drug use, HIV infection and malignancies are the most commonly found causes but there are several other etiologies.⁴ Our study also revealed type 2 diabetes as the most common cause as shown in table 2. Since it is a scientific fact that without focus of infection or immunodeficiency the diagnosis of BEE becomes ambiguous, we delivered almost free medical services to our patients majority of whom were poor with the aim to not only preventing them from using lack-of-funds as an excuse to refuse tests but also enhancing our diagnostic yield. As shown in table 2, only 1 (3.45%) participant did not have an underlying disease in our study. The patient in question missed an appointment. We, therefore, strongly believe that expensive medical bills may act as a hindrance in detecting systemic entities associated with BEE although further studies are needed to establish this fact.

The only brachiocephalic artery in the cardiovascular system and the biggest branch of aortic arch is situated at the right making blood volume and bacterial load sent from it to the right carotid and eye more than the left.⁸ Based on this fact, Greenwald *et al* suggested that BEE occurs more in right than left eye.⁹ In an attempt to emphasize this scientific fact, Forster *et al* concluded in their study that the reason behind right eye predominance is that the only brachiocephalic artery which is right sided in the body directly takes blood and infective pathogens from aortic arch to the right eye through other arteries, an anatomical feature which the left eye does not possess.¹⁰ Other researchers, however, upon finding left eye preponderance, have categorically stated that blood flow is equal to both eyes and the extra transit time to the left carotid is unlikely to have an important effect on bacterial survival.⁴ Although with marginal difference, our study revealed right eye predominance (51.73%) substantiating previously found evidence in scientific armamentarium. Bilaterality is rare but when detected, the most commonly associated systemic disease and causative organisms are diabetes and *klebsiella pneumoniae* respectively.¹¹⁻¹⁶ Other characteristics of both eyes involvement include liver abscess and poor visual prognosis.¹¹⁻¹⁶ In our study we detected bilateral disease in 2 patients one of whom had diabetes and the other, tuberculosis. The final BCVA was worse in the patient with diabetes.

b) Clinical Features

The most common eye symptom in our patients was blurred vision (n=24; 82.76%) followed by eye pain (n=16; 55.17%). The signs we commonly detected were absence of red reflex (n=17; 58.62%), anterior chamber inflammation (n=13; 44.83%), vitritis (n=12; 41.38%) and

hypopyon (n=10; 34.48%). Many patients had systemic features like fever (n=13; 44.83%) and influenza-like symptoms (n=6; 20.69%) which accompanied or preceded the ocular symptomatology. These findings are similar to what has been detected in other case series.⁴ Depending on the predominant focus of inflammation, there are five main types of BEE: anterior focal, anterior diffuse, posterior focal, posterior diffuse and panophthalmitis.⁹ Anterior means aqueous and posterior refers to vitreous humor and retina. Focal and diffuse represent part of whole area and whole area respectively.

c) Diagnosis

i. Errors In Diagnosis

Albeit BEE has its own clinical symptoms and signs, many of them might be nonspecific making its diagnosis difficult. The diagnostic error is compounded by its very low incidence rate. According to Greenwald *et al*,⁹ errors in diagnosis occurred in 11 out of 67 patients representing 16%. Jackson *et al*, however, are of the opinion that the error rate ranges from 22 to 63% emphasizing that physicians may not report all the diagnostic errors they make.⁴ Our rate was 13.79% after having misdiagnosed 4 patients as having acute anterior uveitis. Index of suspicion should therefore be very high in order not to miss the diagnosis.

ii. Differential Diagnoses

Entities which can easily mimic BEE may be categorized into intraocular and eyelid. Intraocular entities include acute anterior noninfectious uveitis due to formation of keratic precipitates, acute angle closure glaucoma owing to trabecular meshwork clogging with inflammatory cells and fungal endophthalmitis from intravenous drug abuse.⁴ Whereas there is enough scientific evidence explaining immunocompromised state of intravenous drug abusers making them prone to fungal endophthalmitis in general, such an evidence is not clearly established between them and BEE. This can bring about diagnostic dilemma.

In children under 2 years of age, the most common differential diagnosis is retinoblastoma due to pseudohypopyon and inflammatory cells appearing as leukocoria.^{17, 18} Cataract and uveitis in a child is another mimicking entity to consider according to Auerbach *et al*.¹⁹ Eyelid swelling may mimic orbital cellulitis.⁴ The youngest patient in our study was 3 years.

d) Ancillary Tests

i. Microscopy and culture

a. Blood Culture

Blood culture, unlike vitreous, constitutes the most reliable medium for making the diagnosis as established in other case series with as high as 75% culture positivity.^{5, 20, 21} In our study, 17 (58.62%) out of 29 patients had their blood cultures positive.

b. Intraocular Culture

Useful though they are, blood cultures cannot be relied upon entirely for the diagnosis of BEE. In the absence of positive blood cultures, it is advisable to get intraocular samples, be it vitreous or aqueous. Although some authorities advocate for aqueous samples when the inflammation is predominantly anterior,⁹ clinical and experimental studies have concluded that vitreous samples are more reliable in exogenous endophthalmitis, a finding which has not been well established in BEE.^{22, 23, 24} In our centre, we usually take vitreous and aqueous specimens in each patient suspicious of BEE. More than 65% of organisms grown were from the vitreous. This made us arrive at the conclusion that vitreous is more reliable than aqueous. Vitreous sample can be obtained through needle aspiration or cutter. Donahue *et al*, after investigating to find out which method of getting vitreous specimen yielded more culture positivity, ended their study concluding that use of a cutter is better than needle aspiration.²⁵ In our hospital the observation we have made is that whereas needle aspiration sometimes results in dry tap, use of a cutter always gives us a specimen. Another difference we have observed is that the needle may not aspirate enough sample but the cutter is very reliable in giving us the amount of sample we need. We, therefore, usually use the cutter in getting vitreous samples due to its advantages. Although we incubate pathogens up to 7 days, majority of our pathogens were detected within 24 hours.

ii. Polymerase Chain Reaction

Polymerase Chain Reaction (PCR) also plays an important role in the diagnosis of BEE. Its advantages include ability to detect unusual organisms,²⁶ augmentation of bacterial DNA for better detection of single organism,²⁷ and detection of organisms in culture-negative specimens after antibiotics have been initiated.²⁸ It is also faster than the traditional culturing of samples.²⁹

Its main disadvantage in our hospital is cost. Other demerits substantiated by studies include cross contamination, false negative results, inability to detect capacity of an organism to replicate, difficulty in matching organism sensitivity to specific antibiotics and not being useful in infections caused by multiple organisms.^{30, 31, 27} Due to these imperfections associated with it, PCR is used to complement the traditional microscopy and culture in our hospital.

e) Causative Organisms

It is a well known fact, according to Wong *et al*, that the most common cause of BEE in East Asia is *Klebsiella* which is a Gram negative bacterium.⁶ Another publication from Okada *et al* has established that in the developed world it is Gram positive bacteria which predominantly cause BEE.⁵ However, it is now accepted that the most common cause of BEE in both developed

and developing countries is *Klebsiella Pneumoniae* (KP).⁴ Recent studies have revealed that apart from its capsule capable of protecting it against immunogenicity of the host, the organism in question has hypermucoviscosity and mag A gene which make it more virulent and metastatic in nature.^{32, 33, 34} There is a strong association among diabetes, KP, liver abscess and BEE.^{32, 35} This means that a good number of patients with diabetes with compromised immune system are easily infected by KP with affinity to the liver and eye causing liver abscess and BEE. In our study, diabetes was the underlying disease mostly found as shown in table 2 and KP, the most commonly isolated Gram negative pathogen. Although we never had liver abscess as an underlying disease, 6.90% of our patients had hepatitis C, a discovery which still makes the liver a sine qua non being the nidus of settlement of KP to set the pace for the development of BEE. Further research is needed to help establish the association between hepatitis C and BEE.

Pseudomonas aeruginosa (PA) causes BEE in the old and young. In the former, the risks increase if there is immunodeficiency or urinary catheterization whereas in the latter, affected individuals are usually neonates or below age 25 years.⁴ We neither had neonates nor catheterization in our research but the second most common underlying disease was PA urinary tract infection.

Other uncommon pathogens capable of causing BEE are *N meningitidis* usually found in children and *Bacillus cereus*, in intravenous drug users.^{9, 36, 37}

f) Pathogenesis

There are two major branches of the ophthalmic artery which help in ocular blood circulation: the posterior ciliary artery provides blood supply to the posterior uvea whereas central retinal artery does the retina.³⁸ BEE can only occur when the blood ocular barrier (BOB) is debilitated allowing entrance of offensive microorganisms usually from a focus of infection in the body to the eye through any of the 2 circulatory pathways.² We believe that 3 factors may play a role in the pathogenesis of BEE: disruption of BOB, compromised immune system of the host and virulence of the pathogen involved. Adequate integrity of BOB may not allow BEE to occur even when there is bacteremia.

Roth's spots are septic emboli on the retina which may occur in only 1% of patients with bacteremia.³⁹ We can therefore infer that it is not all patients with septicemia who progress to BEE depending on the tightness of their BOB. This fact was confirmed when out of 202 patients with septicemia none of them developed BEE with only 12 developing minute retinal hemorrhages and cotton wool spots thought to be Roth's spots.⁴⁰ We could not substantiate

this fact because all patients referred to our centre already had an eye problem which finally turned out to be BEE.

The triad of diabetes, hepatic abscess and BEE with possible choroidal abscess needs to be highlighted. Diabetes is known to interfere with chemotaxis of polymorphonuclear leukocytes bringing about unopposed devastating effects of KP exo and endotoxins.⁴¹ Serotype K1 of KP, which is the most common of all its serotypes, produces toxins which have affinity for the liver and vitreous after travelling through blood to reach and break down the BOB.⁴² Owing to the fact that 70% of ocular blood circulation occurs at the choroid,⁴³ it should therefore not be a surprise that some patients with BEE develop choroidal and retinal abscesses. KP toxins can also cause irreversible photoreceptor damage within 24 hours to result in rapid decline in visual acuity.⁴⁴

g) Treatment

i. Systemic Antibiotics

Although BOB is impermeable to antibiotics under non-inflammatory conditions, it becomes permeable to a few of them when there is ocular inflammation.^{45, 46} Systemic fluoroquinolones, which are mostly utilized to treat infections caused by Gram positive and negative bacteria, have good ocular penetration against many bacteria and it improves with repeated doses.⁴⁵ Albeit all types of systemic fluoroquinolones may work well in BEE, the fourth generation class like moxifloxacin and levofloxacin are the best known antibiotics in crossing the BOB.^{46, 47} Since ciprofloxacin is not as good as the fourth generation group in terms of ocular penetration, it is recommended that it be supplemented with intravitreal antibiotics (IA) in the treatment of BEE.^{47, 48}

Ceftazidime, a third generational cephalosporin, is the best choice against Gram negative organisms but has poor ocular penetration.⁴⁶ Aminoglycosides like gentamicin and amikacin have poor intraocular therapeutic levels against Gram negative bacteria.⁴⁸

Intravenous vancomycin is usually used in treatment of infections caused by Gram positive bacteria but its ocular penetration is poor.⁴⁶

Though other routes of treatment are available, systemic antibiotics should always be used in the management of BEE to help reduce or eliminate the bacterial load in the eye, systemically and treat the primary focus of infection.^{45, 46, 47} All the patients in our study received systemic oral ciprofloxacin supplemented with IA because they could not afford the fourth generation fluoroquinolones. If there were patients who could afford better oral antibiotics, we would still administer the IA to locally potentiate and augment ocular therapeutic effects.

ii. Intravitreal Antibiotics

According to Barza *et al* many systemic, subconjunctival and topical antibiotics have poor vitreous penetration.⁴⁹ After detailed research, Wong *et al* also realized IA did not improve visual acuity but reduced the rates of evisceration and enucleation as compared to those who did not receive it.⁶ Other studies have accepted that the first line of treatment of BEE is systemic antibiotics such that if they fail, then IA can be used.⁵⁰ Although other authorities advocate for the use of IA,⁴ Greenwald *et al* concluded in their research that IA are not required for most patients with BEE.⁹ In our study, since we took vitreous sample for microscopy, culture and sensitivity from all our patients, we only thought it was logical to inject antibiotics into the vitreous cavity just after taking the specimen at least to depopulate the quantum of micro-organisms in all patients. None of our participants had evisceration nor enucleation, a success which we attribute to the IA.

a. Choice of IA

Vancomycin (1.0mg/0.1 mL) and ceftazidime (2.25mg/ 0.1 mL) are the best IA used against Gram positive and negative organisms respectively in BEE.⁵¹ Whereas gentamicin causes macular infarction, amikacin can bring about retinal toxicity.^{52, 53, 54} This means that aminoglycosides are not safe for intravitreal use. In our study we used vancomycin and ceftazidime intravitreally for all our patients.

iii. Intravitreal steroids

The purpose of using intravitreal steroids (IS) is to reduce intraocular tissue destruction as a result of host inflammatory response to bacterial toxins.⁵⁵ Many experiments have substantiated that intravitreal dexamethasone (0.4 mg/0.1mL) is capable of preserving retinal structure and function.^{56, 57, 58} Meredith *et al*, on the contrary, had poor results when they treated BEE patients with IS.⁵⁹ In our hospital from the year 2000 up to 2006 out of the 10 cases of BEE diagnosed, 8 (80%) were treated with only IA but the other 2 (20%) had combination of IA with IS. 6 (75%) of those without IS had final BCVA of light perception. The remaining 2 (25%) of non-steroid group finally needed evisceration. On the other hand, the combination therapy group had final BCVA of 6/36 without any of them needing evisceration. After having had better visual and anatomical outcomes with the combination therapy, we have made it our policy to treat all cases of BEE with IS in addition to IA when microscopy rules out fungal infection. All our patients in this study had IS in addition to IA. In our candid opinion, our anatomical and visual outcomes could have been worse had we not used IS in addition to IA in this research.

a. Reinjection

Second IA and IS should be considered 48 hours after the first therapy if the response is not adequate but since a third injection makes the rate of

retinal toxicity almost 100% irrespective of the antibiotic used, it is recommended that patients get vitrectomy performed if the second injection is not beneficial.^{60, 61, 62} We had 3 patients who, on not responding well to the second IA and IS, were booked for PPV but were lost to follow up and therefore excluded from the study.

iv. Vitrectomy

PPV is performed with the aim to objectively removing the offensive micro-organisms together with their endo and exotoxins, vitreous membranes capable of leading to retinal detachment as well as vitreous inflammatory particles apart from helping to get abundant specimen for culture and appropriate dissemination of IA and IS.⁶⁰ A systematic review of 342 cases of BEE revealed that eyes treated with PPV and IA were 2 times more likely to have vision better than 6/60 and 3 times less likely to need evisceration or enucleation when compared with IA alone.⁵¹

The question of whether all patients with BEE should have immediate PPV remained unanswered prior to our research. In our center, however, out of the 51.61% of the patients we vitrectomised, the various indications were poor response to initial SAIAS, severe vitritis, retinal infiltration, worsening of vision and presenting visual acuity of light perception.

h) Prognosis

The prognosis of BEE has been poor since time immemorial. In a study published by Greenwald *et al*, 29% of patients required evisceration or enucleation, 26% were blind and 41% had visual acuity of counting fingers or better.⁹ Shammass *et al* had similar results in their research.⁶³ Other publications have recorded mortality rate of 32% from the associated systemic diseases.⁴⁰ Our experience was better than what has been reported in other case series. The final BCVA we recorded were such that 70.96% of eyes had counting fingers at 1 metre or better, 9.69% had nil perception of light and 19.35%, light perception. None of our patients had evisceration, enucleation nor mortality till the last review. We ascribe this comparatively better outcomes to lower rates of KP etiology, our combination therapy and multidisciplinary collaborative efforts.

Poor prognosis can result from delay in diagnosis,⁹ wrong choice of antibiotics,⁶⁴ diffuse infection of vitreous and retina or panophthalmitis,⁹ infection with virulent organisms and Gram negative bacterial infection.⁶ KP may cause choroidal and retinal abscess, bilateral BEE and poor visual prognosis.¹¹⁻¹⁶ The most common guarded prognostic factors in our centre for this study were poor presenting visual acuity and Gram negative infection with Klebsiella.

V. CONCLUSION

The poor prognosis of BEE which has not improved over several decades has underlying factors. It mimics several common ocular diseases such that it

easily leads to initial misdiagnosis setting the pace for rapid disease progression, delayed therapy and invariably unwanted outcomes. Physician specialists may hardly focus on the eye, a situation which is further compounded by the ophthalmologist overlooking the systemic implications and concentrating only on the eyes. There have not been large prospective trials whose purpose it is to determine the real advantages of systemic antibiotics, IA, IS and vitrectomy either in isolation or combination. The question of whether combination therapy involves double, triple or all the 4 remained unanswered before our study was initiated. KP etiology which is on the ascendency, has poor visual prognosis.

In our center, all patients are treated with systemic antibiotics, initial IA and IS while the physician specialist manages the systemic disease. If there is no improvement after 48 hours, we repeat intravitreal injections. PPV is performed 48 hours after the second intraocular injection if there is poor response. Should the patient meet the criteria for PPV on the first day, we perform it without going through this algorithm. A few aspects account for the limitations of our study: retrospective nature, one centre focus, 3 vitreoretinal specialists management of patients and small sample size.

We believe that our algorithm, fewer KP infective cases coupled with team work with the physician specialist and microbiologist, made us have appealing results compared to other case series owing to the fact that we did not record any eviscerations, enucleations nor mortalities apart from our visual outcomes being comparatively better.

Contribution

FKO commenced the project, implemented and completed the data collection, wrote the statistical analysis plan, analysed the data, drafted and revised the paper. NS contributed to the statistical analysis. VKV, PS, RS and KS contributed to the management of cases and revised the paper. VKV, PS, RS and KS are guarantors.

Competing interest-None.

REFERENCES RÉFÉRENCES REFERENCIAS

1. European Ophthalmic Review, 2009,3(2):105-8 DOI: <http://doi.org/10.17925/EOR.2009.03.02.105>
2. Hassan, I.J, MacGowan, A.P, and Cook, S.D. Endophthalmitis at the Bristol Eye Hospital: an 11-year review of 47 patients. *J Hosp Infect.* 1992; 22: 271–278
3. Binder M et al. *Medicine.* 2003; 82(2): 97-105.
4. Jackson TL, Eykyn SJ, Graham EM, Stanford MR. Endogenous bacterial endophthalmitis: A 17-year prospective case series and review of 267 reported cases. *Surv Ophthalmol.* 2003; 48(4): 403-423. doi:10.1016/S0039-6257(03)00054-7.
5. Okada, A.A, Johnson, R.P, Liles, W.C et al. Endogenous bacterial endophthalmitis: report of a ten-year retrospective study. *Ophthalmology.* 1994; 101: 832–838.
6. Wong, J.S., Chan, T.K., Lee, H.M. et al. Endogenous bacterial endophthalmitis: an east Asian experience and a reappraisal of a severe ocular affliction. *Ophthalmology.* 2000; 107: 1483–1491.
7. Zeng J, Liu R, Zhang XY,. Relationship between gender and posterior pole choroidal thickness in normal eyes [in Chinese]. *Zhonghua Yan KeZaZhi.* 2012; 48(12): 1093–1096. Google Scholar.
8. https://en.wikipedia.org/wiki/Brachiocephalic_artery
9. Greenwald, M.J, Wohl, L.G, and Sell, C.H. Metastatic bacterial endophthalmitis: a contemporary reappraisal. *Surv Ophthalmol.* 1986; 31: 81–101.
10. Forster R.K. Endophthalmitis. In: Tasman W., Jaeger E. A., editors. *Duane's Clinical Ophthalmology.* Philadelphia: JB Lippincott, v.4, chapter 24, 1998.
11. Margo CE, Mames RN, Guy JR (1994) Endogenous Klebsiella endophthalmitis. Report of two cases and review of the literature. *Ophthalmology* 101: 1298–1301. Google Scholar.
12. Irvine WD, Flynn HW, Miller D, et al. (1992) Endophthalmitis caused by gram-negative organisms. *Arch Ophthalmol* 110: 1450–1454. Open Url Cross Ref Pub Med Web of Science Google Scholar.
13. Lee CC, Chen CY, Chen FH, et al., (1998) Septic metastatic endophthalmitis from Klebsiella pneumoniae liver abscess: CT and MR imaging characteristics—report of three cases. *Radiology* 207: 411–416. Open Url Pub Med Google Scholar.
14. Yarnig SS, Hsieh CL, Chen TL (1997) Vitrectomy for endogenous Klebsiella pneumoniae endophthalmitis with massive subretinal abscess. *Ophthalmic Surg Lasers* 28:147–150. Open Url Pub Med Google Scholar.
15. Chee SP, Ang CL (1995) Endogenous Klebsiella endophthalmitis—a case series. *Ann Acad Med Singapore* 24: 473–478. Open Url Pub Med Google Scholar.
16. Cheng DL, Liu YC, Yen MY, et al. (1991) Septic metastatic lesions of pyogenic liver abscess. *Arch Intern Med* 151:1557–1559. Open Url Cross Ref Pub Med Web of Science Google Scholar.
17. Harrison, S.A and Bateman, J.B. Endogenous endophthalmitis caused by Streptococcus mitis. *Am J Ophthalmol.* 1997; 123: 260–261.
18. Shields, J.A, Shields, C.L, Eagle, R.C.J et al. Endogenous endophthalmitis simulating retinoblastoma. The 1993 David and Mary Seslen Endowment Lecture. *Retina.* 1995; 15: 213–219.

19. Auerbach, S.B, Leach, C.T, Bateman, B.J et al. Meningococcal endophthalmitis without concomitant septicemia or meningitis. *Pediatr Infect Dis J.* 1989; 8: 411–413
20. Chou, F.F and Kou, H.K. Endogenous endophthalmitis associated with pyogenic hepatic abscess. *J Am Col Surg.* 1996; 182: 33–36.
21. Liao, H.R, Lee, H.W, Leu, H.S et al. Endogenous *Klebsiella pneumoniae* endophthalmitis in diabetic patients. *Can J Ophthalmol.* 1992; 27: 143–147.
22. Rowsey, J.J, Newsom, D.L, Sexton, D.J et al. Endophthalmitis: current approaches. *Ophthalmology.* 1982; 89: 1055–1066.
23. Callegan, M.C, Booth, M.C, Jett, B.D et al. Pathogenesis of gram-positive bacterial endophthalmitis. *Infect Immunity.* 1999; 67: 3348–3356.
24. Koul, S, Philipson, A, and Arvidson, S. Role of aqueous and vitreous cultures in diagnosing infectious endophthalmitis in rabbits. *Acta Ophthalmologica.* 1990; 68: 466–469.
25. Donahue, S.P, Kowalski, R.P, Jewart, B.H et al. Vitreous cultures in suspected endophthalmitis—biopsy or vitrectomy?. *Ophthalmology.* 1993; 100: 452–455.
26. Rickman, L.S, Freeman, W.R, Green, W.R et al. Brief report: uveitis caused by *Tropherymawhipplii* (Whipple's bacillus). *N Eng J Med.* 1995; 332: 363–366.
27. Okhravi, N, Adamson, P, Matheson, M.M et al. PCR-RFLP-mediated detection and speciation of bacterial species causing endophthalmitis. *Invest Ophthalmol Vis Sci.* 2000; 41: 1438–1447.
28. Van Gelder, R.N. Applications of the polymerase chain reaction to diagnosis of ophthalmic disease. *Surv Ophthalmol.* 2001; 46: 248–258.
29. Lohmann, C.P, Gabel, V.P, Heep, M et al. *Listeria monocytogenes*-induced endogenous endophthalmitis in an otherwise healthy individual: rapid PCR-diagnosis as the basis for effective treatment. *Eur J Ophthalmol.* 1999; 9: 53–57.
30. Lohmann, C.P, Linde, H.J, and Reischl, U. Improved detection of microorganisms by polymerase chain reaction in delayed endophthalmitis after cataract surgery. *Ophthalmology.* 2000; 107: 1047–1051.
31. Knox, C.M, Cevallos, V, Margolis, T.P et al. Identification of bacterial pathogens in patients with endophthalmitis by 16S ribosomal DNA typing. *Am J Ophthalmol.* 1999; 128: 511–512.
32. Yang, C.S., Tsai, H.Y., Sung, C.S., Lin, K.H., Lee, F.L., and Hsu, W.M. Endogenous *Klebsiella* endophthalmitis associated with pyogenic liver abscess. *Ophthalmology.* 2007; 114: 876–880.
33. Keynan, Y. and Rubinstein, E. Endogenous endophthalmitis caused by hypermucoviscous *Klebsiella pneumoniae*: An emerging disease in Southeast Asia and beyond. *Curr Infect Dis Rep.* 2008; 10: 343–345.
34. Wiskur, B.J., Hunt, J.J., and Callegan, M.C. Hypermucoviscosity as a virulence factor in experimental *Klebsiella pneumoniae* endophthalmitis. *Invest Ophthalmol Vis Sci.* 2008; 49: 4931–4938.
35. McDonald, M.I, Corey, G.R, Gallis, H.A et al. Single and multiple pyogenic liver abscesses: natural history, diagnosis and treatment, with emphasis on percutaneous drainage. *Medicine.* 1984; 63: 291–302.
36. Cowan, C.L.J, Madden, W.M, Hatem, G.F et al. Endogenous *Bacillus cereus* panophthalmitis. *Ann Ophthalmol.* 1987; 19: 65–68.
37. Hemady, R, Zaltas, M, Paton, B et al. *Bacillus*-induced endophthalmitis: new series of 10 cases and review of the literature. *Br J Ophthalmol.* 1990; 74: 26–29.
38. https://en.wikipedia.org/wiki/Ophthalmic_artery
39. Neudorfer, M, Barnea, Y, Geyer, O et al. Retinal lesions in septicemia. *Am J Ophthalmol.* 1993; 116: 728–734
40. Bouza, E, Cobo-Soriano, R, Rodríguez-Créixems, M et al. A prospective search for ocular lesions in hospitalized patients with significant bacteremia. *Clin Infect Dis.* 2000; 30: 306–312.
41. Mowat, A.G. and Baum, J. Chemotaxis of polymorphonuclear leukocytes from patients with diabetes mellitus. *N Engl J Med.* 1971; 284: 621–627.
42. Fung, C.P., Chang, F.Y., Lee, S.C. et al. A global emerging disease of *Klebsiella pneumoniae* liver abscess: is serotype K1 an important factor for complicated endophthalmitis?. *Gut.* 2002; 50: 420–424.
43. Parver, L.M, Anker, T, and Carpenter, D.O. Choroidal blood flow as a heat dissipating mechanism in the macula. *Am J Ophthalmol.* 1980; 89: 641.
44. Meyers–Elliot, R.H and Dethlefs, B.A. Experimental *Klebsiella* induced endophthalmitis in the rabbit. *Arch Ophthalmol.* 1982; 100: 1959–1963.
45. Smith A et al. *Drugs.* 2001; 61(6): 747–761.
46. Ahmed S et al. *J Ocul Pharmacol Ther.* 2014; 30(10): 823–830.
47. García-Sáenz MC et al. *J Cataract Refract Surg.* 2001; 27(12): 1969–1974.
48. Davis JL. *Am J Ophthalmol.* 1996; 122(5): 724–726.
49. Barza, M, Kane, A, and Baum, J. Intraocular penetration of gentamicin after subconjunctival and retrobulbar injection. *Am J Ophthalmol.* 1978; 85: 541–547.
50. Brod, R.D and Flynn, H.W Jr. Endophthalmitis: current approaches to diagnosis and treatment. *Curr Opin Infect Dis.* 1993; 6: 628–637



51. Jackson TL et al. *Surv Ophthalmol.* 2014; 59(6): 627-635.
52. Campochiaro, P. A and Conway, B.P. Aminoglycoside toxicity—a survey of retinal specialists. Implications for ocular use. *Arch Ophthalmol.* 1991; 109: 946–950.
53. Campochiaro, P.A and Lim, J.I. Aminoglycoside toxicity in the treatment of endophthalmitis. The Aminoglycoside Toxicity Study Group. *Arch Ophthalmol.* 1994; 112: 48–53.
54. Jackson, T.L and Williamson, T.H. Amikacin retinal toxicity. *Br J Ophthalmol.* 1999; 83: 1199–1200
55. Schulman, J.A and Peyman, G.A. Intravitreal corticosteroids as an adjunct in the treatment of bacterial and fungal endophthalmitis: a review. *Retina.* 1992; 12: 336–340.
56. Maxwell, D.P, Brent, B.D, Diamond, J.G et al. Effect of intravitreal dexamethasone on ocular histopathology in a rabbit model of endophthalmitis. *Ophthalmology.* 1991; 98: 1370–1375.
57. Park, S.S, Samiy, N, Ruoff, K et al. Effect of intravitreal dexamethasone in treatment of pneumococcal endophthalmitis in rabbits. *Arch Ophthalmol.* 1995; 113: 1324–1329.
58. Smith, M.A, Sorenson, J.A, D'Aversa, G et al. Treatment of experimental methicillin-resistant *Staphylococcus epidermidis* endophthalmitis with intravitreal vancomycin and intravitreal dexamethasone. *J Infect Dis.* 1997; 175: 462–466.
59. Meredith, T.A, Aguilar, H.E, Drews, C et al. Intraocular dexamethasone produces a harmful effect on treatment of experimental *Staphylococcus aureus* endophthalmitis. *Trans Am Ophthalmol Soc.* 1996; 94: 241–252.
60. Endophthalmitis Vitrectomy Study Group. Results of the Endophthalmitis Vitrectomy Study. A randomized trial of immediate vitrectomy and of intravenous antibiotics for the treatment of postoperative bacterial endophthalmitis. *Arch Ophthalmol* 1995; 113: 1479–1496.
61. Endophthalmitis, a review of current evaluation and management. Lemley et al. *Retina* 27: 662-680, 2007.
62. Das T, Sharma S; Hyderabad Endophthalmitis Research Group. Current management strategies of acute post-operative endophthalmitis. *Semin Ophthalmol.* 2003; 18(3): 109-115.
63. Shammass, H.F. Endogenous *E. coli* endophthalmitis. *Surv Ophthalmol.* 1977; 21: 429–435.
64. Wang, L.S, Lee, F.Y, Cheng, D.L et al. *Klebsiella pneumoniae* bacteremia: analysis of 100 episodes. *J Formos Med Assoc.* 1990; 89: 756–763.