

Plastination of Major Organs of Miniature Pigs: Alternatives for Educational Purpose

Jin Soo Han¹, Yoon Ju Cho² and Jin Soo Han³

¹ Konkuk University

Received: 9 December 2016 Accepted: 2 January 2017 Published: 15 January 2017

Abstract

Veterinary science have been influenced by the increasing demand for veterinary schools or research facilities in animal welfare. Thus, there have been new approaches to veterinary education based on 'Three Rs' (3Rs; Replacement, Reduction and Refinement). Plastination, one of the new approaches, is certainly potential method in respect of learning tool for gross anatomy. We performed the plastination of miniature pig's major organs (liver, heart, lung, kidney, and pancreas) for alternative in anatomic instruction. Silicone impregnated method keeps thoroughly dissected specimens from deteriorating and maintained many of the important surrounding structures. After entire process, organs became dry, odorless, and durable specimens that could be handled without gloves and kept without any special storage conditions or care.

Index terms— plastination, miniature pig, alternative.

1 I. Introduction

Plastination is the most important technique that enables biological specimens to be completely preserved without deteriorating. Plastination process consists of slowly replacing tissue fluids with reactive plastics under specialized vacuum. 1 Plastinated specimens are clean, dry, odorless and graspable, therefore, they are convenient to access the interior of the body in any circumstance. [2][3][4] The potential value of this technique is in the application of a various fields of anatomical specimens for education, in particular, plastination has been considered a most important tool for instruction of gross anatomy. 1 In addition, plastinated specimens are permanently reusable, thus, the demand of real bodies for cadavers could be reduced. Indeed, practical application of plastination has been influenced on research and education areas in many ways. 4 We performed the plastination of miniature pigs. Miniature pigs have been proposed for suitable candidate source animal for clinical xenotransplantation. 5 Shortages in the availability of suitable human donors have limited the possibilities of being transplanted, which has stimulated interest in the possibility of animal-to-human transplantation. 6 Particularly, Xenotransplantation using miniature pig has been considered that could potentially overcome limitations in organ transplantation resulting from insufficiency of human organs. 7 Unlike domestic pigs, miniature pigs have a great majority in organ size similar to human organ. 8 In addition, Miniature pigs are similar to human in physiological features and provide several breeding, handling, and reproduction-related advantages compared to non-human primates. Hence, miniature pigs are already extensively used in biomedical research, and it is anticipated that miniature pigs will be more used notably in teaching and research areas, along with advancement of genetically engineering technique. 9 However, increasing needs of miniature pigs for educational objects have had a strong possibility of leading to sacrifice it in increasing numbers. This problem is not correlated with recent trend in animal use. In recent decades, the use of animals in veterinary education has show a significant tendency to decline. Consideration for laboratory animals, the Animal Protection Act, and growing availability of alternative resources have enabled this valuable trend to be proceeded. 10 Also, the use of live animals in education requires a protocol review and permission by Institutional Animal Care and Use Committee (IACUC) for reducing and

replacing the sacrificed animals. In several countries including Korea, however, not a few veterinary schools have showed the not enough try to comply with the regulations strictly, and the lack of interests and efforts. 11 By contrast, human medical schools have been utilized outstanding alternative methods such like plastination more effectively. 4 Hence, for more successful fulfillment of 3Rs in veterinary education, feasible alternatives are requested for that supplant animal realistically. Accordingly, we attempted plastination of miniature pigs, growing need for education on which has been required. This study suggests plastinated organs of miniature pig are valuable alternative material of cadaver on anatomic instruction. Furthermore, it is considered that this nonliving specimen largely contribute to humane veterinary education and research.

2 MATERIALS AND METHOD

Two male miniature pigs (Micro-pig, PWG Genetics Korea) scheduled to be sacrificed at the termination of the other research, were used in this study. Application of the plastination process to these miniature pigs was approved by the Institutional Animal Care and Use Committee of Konkuk University. Pigs were deeply anesthetized by Telazol(Zoletil50 ® , Virbac) and Xylazine (Rompun ® , Bayer). Warm saline and 10% neutral buffered formalin (NBF) are injected through carotid artery in sequence for perfusion and fixation, respectively.

After fixation, major organs of miniature pigs (lung, heart, liver, pancreas and kidney) are trimmed to remain the connected anatomic structures and carefully removed from the body. The connection among trachea, bronchi and lung lobes was remained. Heart was maintained leaving the vessels related the systemic and pulmonary circulation. Caudal vena cava, portal vein, diaphragm, gall bladder and bile duct were also remained with connected liver. Pancreas was dissected including duodenum to maintain pancreatic ducts between pancreas and duodenum. Bilateral kidneys were remained containing descending aorta, caudal vena cava, renal artery, renal vein and ureter.

Until initiation of the plastination process, trimmed organs were stored in 10% NBF. Plastination was carried out in four main stages. (Table 1) After embalming with formalin, the body fluids and soluble fats were dissolved from the organs by placing it into the acetone bath. During forced impregnation, vacuum chamber removed the acetone from the organs, and liquid silicone replaced acetone that had been placed in organs. In the final step, organs were hardened with heat. For visualization of internal structure of organs, each one heart and kidney among the organs were sliced into four sheets and two sheets, respectively.

3 III. Results

Plastinated specimens made in our study are shown in Figures 1-5. Silicone impregnated method keeps thoroughly dissected specimens from deteriorating and maintained many of the important surrounding structures. After entire process, organs became dry, odorless, and durable specimens that could be handled without gloves and kept without any special storage conditions or care.

4 a) Heart and kidney

External structure of heart was completely preserved. (Figure 1) Ventricles, atriums, auricles, and grooves were well discriminated, and vascular structures including aortic arch, brachiocephalic trunk, pulmonary artery and vein, and vena cava were distinctly exhibited. In sliced specimens, internal structures containing valves, chorda tendinaes, papillary muscles, septums and coronary artery were clearly identified. Besides, the properties of inner, outer, and sectioned surface of vascular tissues and myocardium were ascertained.

Bilateral kidneys were kept in the connection state with blood-vessels. Renal arteries were maintained to the both side kidneys from the descending aorta, and connection between caudal vena cava and renal veins was also maintained. (Figure 2) In addition, adrenal glands as well as ureter from the renal pelvis were easily shown. In sliced specimens, the discrimination among the renal medulla, cortex and pelvis structure was obvious.

5 b) Lung, liver, and pancreas

Each lobes and the overall shape of the lung were soundly maintained. Trachea and its bifurcation to both side lobes were shown, and lymph node positioned in bifurcation site was identified. (Figure ??) In the dorsal aspect of the plastinated liver, gall bladder, portal vein, hepatic artery and caudal vena cava were maintained without deformation. (Figure ??) Particular, pancreatic ducts was clearly shown, because the connection between duodenum and pancreas was completely preserved. (Figure 5)

6 IV. Discussion

Veterinary science have been influenced by the increasing demand for veterinary schools or research facilities in animal welfare. Thus, there have been new approaches to veterinary education based on 'Three Rs'(3Rs; Replacement, Reduction and Refinement). Plastination, one of the new approaches, is certainly potential method in respect of learning tool for gross anatomy. 3 We performed the plastination of major organs of miniature pig for alternative in anatomic instruction. The organ structures and spatial relationships of the surrounding tissues were not altered during the plastination. In addition, fine structures including vessels or ducts were also kept thoroughly, enough to replace the embalmed cadavers. The method using silicone as impregnant we performed,

is largely used on dissected specimens. 3 Organ specimens plastinated with silicone had merits of being resilient and flexible, and above all, these organs were suitable for teaching

The miniature pig has stood out as the most suitable donor for animal-to-human xenotransplantation because of the similar size and physiological capacity of its organs. 9 This study is designed to suggest that the plastination of miniature pig could become an alternative for its actual use on veterinary anatomic teaching and xenotransplantation surgery instruction. Even though it was difficult to evaluate the impact of practical application accurately, through the literature search, we could predict that the properties of these plastinated specimens accommodate needs of student and researcher at various levels.

We believe that the plastination model can be can be applied to other laboratory animals, including rats, guinea pigs, and rabbits. We also believe this set of data will be of great help in education about the miniature pig and make significant contributions towards progress of research on xenotransplantation and the miniature pig.

This study suggests plastinated organs of miniature pig are valuable alternative material of cadaver on anatomic instruction. Furthermore, it is considered that this non-living specimen largely contribute to humane veterinary education and research.

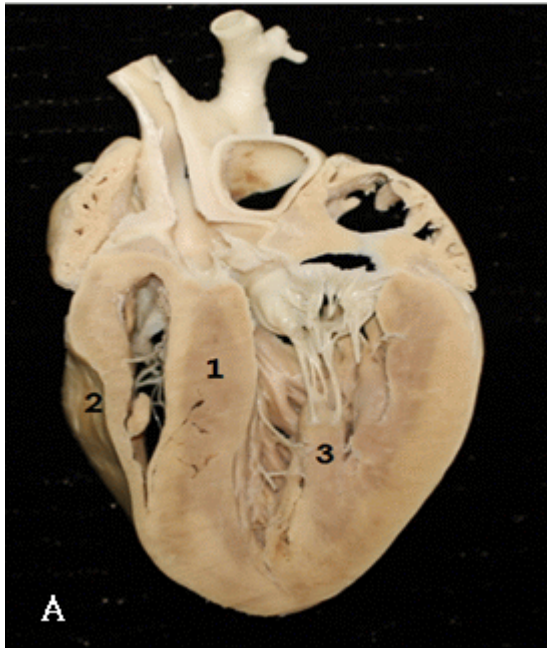


Figure 1: P

¹© 2017 Global Journals Inc. (US)Year 2017

²© 2017 Global Journals Inc. (US)

³© 2017 Global Journals Inc. (US) Year 2017

⁴Plastination of Major Organs of Miniature Pigs: Alternatives for Educational Purpose

⁵© 2017 Global Journals Inc. (US)Year 2017

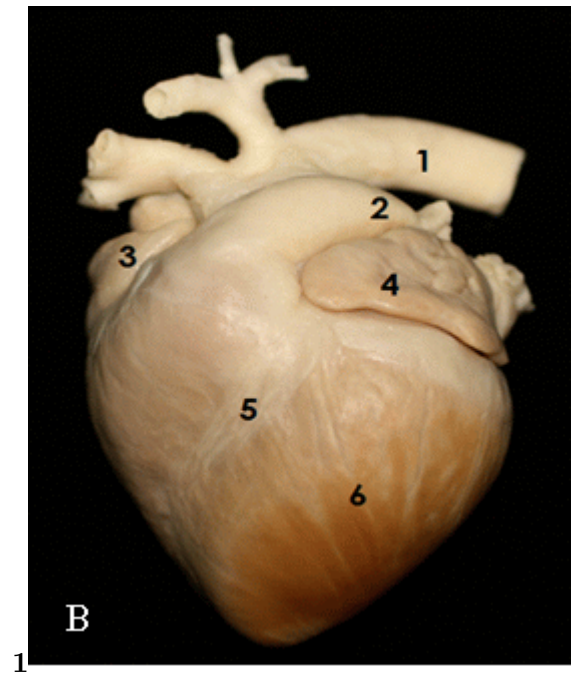


Figure 2: Fig. 1 :

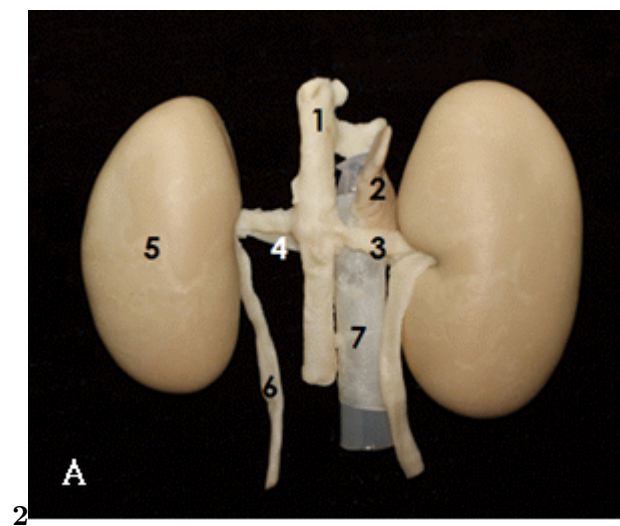
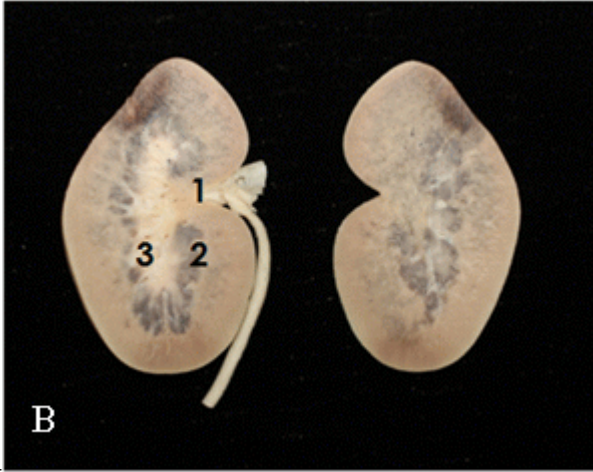
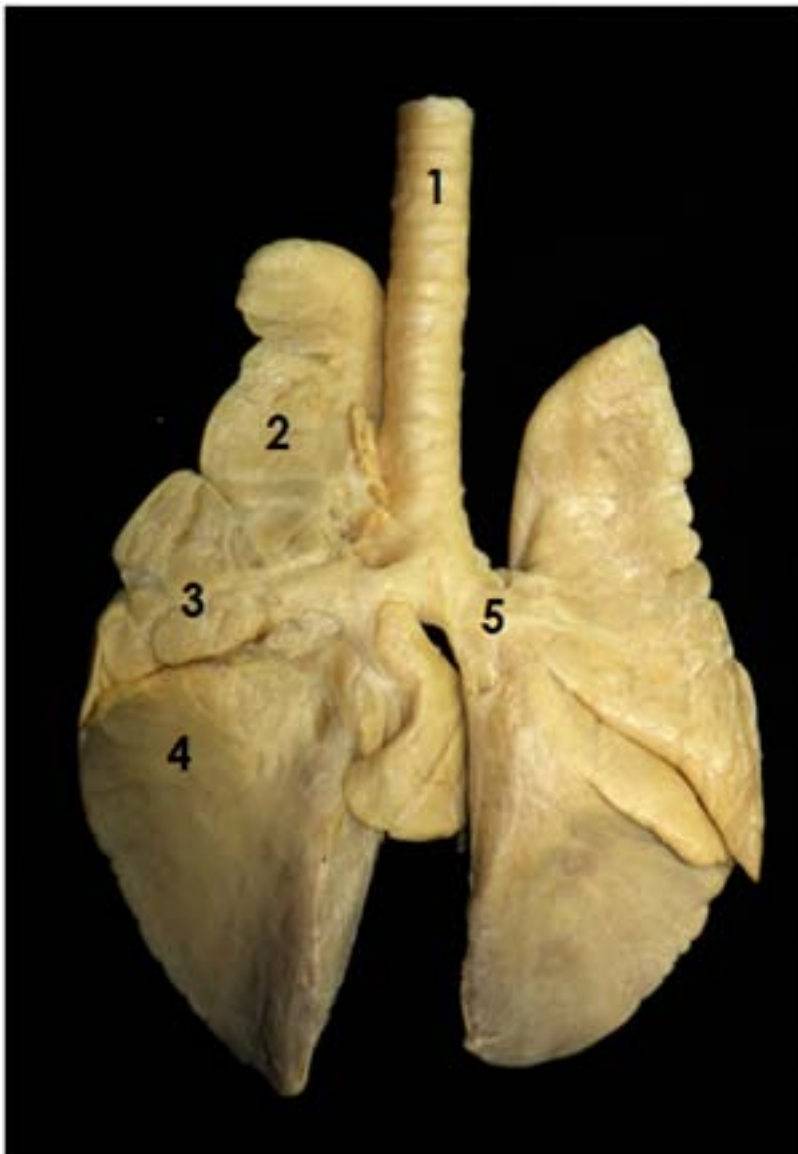


Figure 3: Fig. 2 :



34

Figure 4: Fig. 3 :Fig. 4 :



5

Figure 5: Fig. 5 :

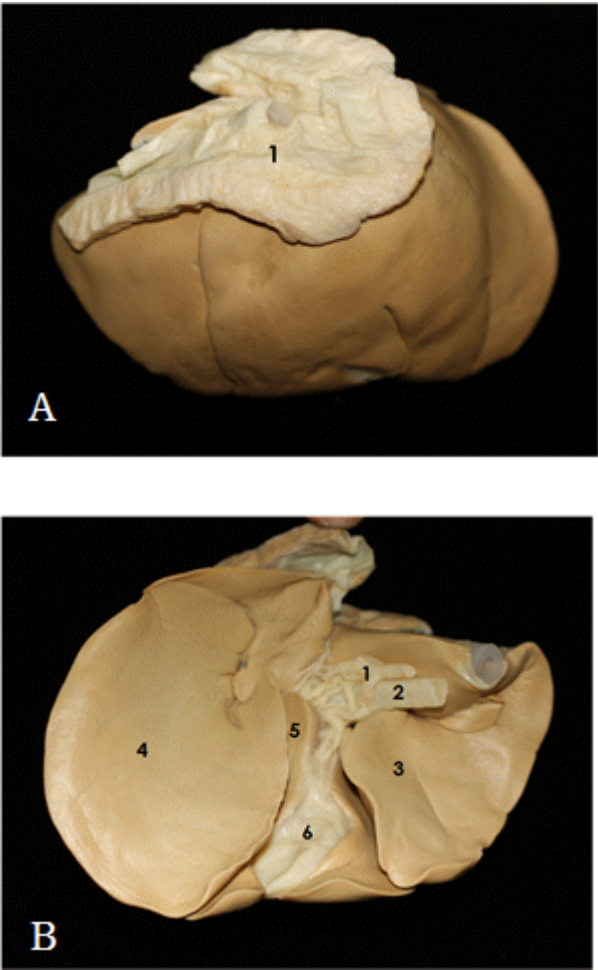


Figure 6: G

1

	Days
Fixation	7
Dehydration	8
Forced impregnation	2
Curing	6

Figure 7: Table 1 :

-
- [Hagens ()] ‘Anatomy and plastination’. Von Hagens , G . *Body Worlds: Catalogue of the Exhibition. Heidelberg: Institute for Plastination*, 2002.
- [Ahn ()] ‘Comparison of cardiac function and coronary angiography between conventional pigs and micropigs as measured by multidetector row computed tomography’. Y K Ahn . *Journal of veterinary science* 2008. 9 p. 121.
- [Latorre et al.] *How useful is plastination in learning anatomy? Veterinary surgery 1*, R M Latorre , M Garcia-Sanz , M Moreno . p. 67.
- [Fishman ()] ‘Miniature swine as organ donors for man: Strategies for prevention of xenotransplant associated infections’. J A Fishman . *Xenotransplantation* 1994. 1 p. .
- [Hector ()] ‘Pre screening of miniature swine may reduce the risk of transmitting human tropic recombinant porcine endogenous retroviruses’. R D Hector . *Xenotransplantation* 2007. 14 p. .
- [Jones ()] ‘Re-inventing anatomy: the impact of plastination on how we see the human body’. D G Jones . *Clin Anat* 2002. 15 p. .
- [Lee et al. ()] ‘The Current Status of Animal Use and Alternatives in Korean Veterinary Medical Schools’. G H Lee , B I Choe , J S Kim . *ATLA. Alternatives to laboratory animals* 2010. 38 p. .
- [Vodi Ka ()] ‘The miniature pig as an animal model in biomedical research’. P Vodi Ka . *Annals of the New York Academy of Sciences* 2005. 1049 p. .
- [Tucker ()] ‘The production of transgenic pigs for potential use in clinical xenotransplantation: baseline clinical pathology and organ size studies’. A Tucker . *Xenotransplantation* 2002. 9 p. .
- [Hosenpud ()] ‘The Registry of the International Society for Heart and Lung Transplantation: fifteenth official report–1998’. J D Hosenpud . *J Heart Lung Transplant* 1998. 17 p. .
- [Hart and Wood ()] ‘Uses of animals and alternatives in college and veterinary education at the University of California, Davis: Institutional commitment for mainstreaming alternatives’. L A Hart , M W Wood . *ATLA-Alternatives to Laboratory Animals* 2004. 32.
- [Henry ()] ‘Using plastinated specimens in teaching veterinary anatomy’. R Henry . *Anatomia, Histologia, Embryologia* 2005. 34 p. 17.