

Overview of Surgical Treatment for Maxillary Constriction

Dr. Faizan Ahmed Khan¹ and Dr. Faizan Ahmed Khan²

¹ Yenepoya Dental College

Received: 14 December 2016 Accepted: 5 January 2017 Published: 15 January 2017

Abstract

The general indications for surgically assisted rapid maxillary expansion (SARME) are skeletal maturity, (extreme) transverse maxillary hypoplasia, either uni- or bilateral, anterior crowding and buccal corridors, the so called black corridors, when smiling. Furthermore the indications for SARME include any case where orthodontic maxillary expansion has failed and resistance of the sutures must be overcome. Transverse maxillary hypoplasia, in adolescents and adults, is frequently seen in non-syndromal and syndromal patients including cleft patients. In skeletally matured patients the uni- or bilateral transverse hypoplasia can be corrected by means of SARME.

Index terms—

1 I. Introduction

The general indications for surgically assisted rapid maxillary expansion (SARME) are skeletal maturity, (extreme) transverse maxillary hypoplasia, either uni-or bilateral, anterior crowding and buccal corridors, the so called black corridors, when smiling. Furthermore the indications for SARME include any case where orthodontic maxillary expansion has failed and resistance of the sutures must be overcome. Transverse maxillary hypoplasia, in adolescents and adults, is frequently seen in non-syndromal and syndromal patients including cleft patients. In skeletally matured patients the uni-or bilateral transverse hypoplasia can be corrected by means of SARME. The treatment is a combination of orthodontics and surgical procedures and provides dental arch space for alignment of teeth. The procedure also causes a substantial enlargement of the maxillary apical base and of the palatal vault, providing space for the tongue for correct swallowing and thus preventing relapse. In addition, a distinct subjective improvement in nasal breathing associated with enlargement of the nasal valve towards normal values is seen with an increase of nasal volume in all compartments. Transverse expansion of the maxilla was first done in 1860 by means of an orthodontic appliance. In the following decennia the orthodontic treatment evolved. The theory of distraction was first published in 1905 by Codivilla ¹. The combined surgical and orthodontic treatment for maxillary expansion was introduced in 1938 for skeletally matured patients. The first successful use of distraction on the femur of a significant group of patients was published in 1990 ². In 1999 the first bone-borne distractor was introduced ³. Maxillary expansion by means of distraction is a nowadays widely used treatment.

However, there is no consensus in the searched literature regarding the surgical technique, the type of distractor used (tooth-borne or bone-borne), the existence, cause and amount of relapse and whether or not overcorrection is necessary.

2 II. History a) History of orthodontic for maxillary constriction

Growth at the suture occurs through deposition of new bone at the sutural margin by the adjacent cellular layer. Toward the end of fetal life the cellular layers decrease in thickness, indicating that the rate of growth is slowing down, and the number of fibers in the intermediate layer uniting the capsular layers decreases. In a study of human sutures from birth to 18 years, Latham and Burston³³ concluded that after about 2 of 3 years the sutures of the skull in general functioned primarily as sites of union of bones, but localized remodeling is a continuing process.

3 B) HISTORY OF SURGICAL TREATMENT FOR MAXILLARY CONSTRICTION

Cranial sutures are unified before complete eruption of the third molar. Soon after this, facial sutures close, and the sutures connecting the cranial and facial complexes are the last to close 4 . Regarding the facial sutures, Sicher 5 states that the closure of sutures in human beings starts, as a rule, in the middle 30s at the posterior end of the median palatine suture but that some facial sutures, including the frontozygomatic, may remain open even in older age groups. This view is supported by Wright 6 , who claimed the intermaxillary and palatine sutures to be unossified and susceptible to comparatively easy separation at as late an age as 35 years.

A conflicting view is expressed by Persson 7 , who found evidence of bony union at 17 years in the midpalatal suture. Latham and Burston 8 , however, found no evidence of synostosis in the same suture by the age of 18 years. An over-all view is expressed by Scott 9 , who believes that, although most facial sutures appear open on the surface of old skulls, some degree of union may be present in the substance of the suture. It is obvious therefore, that the available literature is inconclusive and conflicting. In clinical practice, skeletal correction of the transverse discrepancy via orthodontics (orthopedics) is successful until the age of approximately 14-15 years depending on the gender of the patient. After this age, orthodontic widening becomes virtually impossible and very painful 10,11,12 . In general, it is assumed that closure of the midpalatal suture prevents this type of expansion 10,12 .

In the first part of nineteenth century, Lefoulon 13,14 and Talma 15 reported on maxillary expansion with a palatal or buccal C-shaped spring. A method, reserved for less severe cases, consisted of lateral thumb pressure, 'every morning and even many times daily', by the parent or the child itself. The first documented case of orthodontic correction of maxillary width discrepancies was by Angell 16 . He performed rapid maxillary expansion with the use of a jackscrew appliance in a 14-year-old girl. He observed that by turning the jackscrew daily, he was able to open the maxillary suture sufficiently in a period of 2 weeks. Angell 16 mentions correction of maxillary width discrepancies by opening the midpalatal suture. In 1913, Schröder-Benseler 17 presented the still-popular all-wire frame with a non-spring-loaded jackscrew, the hygienic appliance. Derichsweiler 16 uses bonds to the premolar and molar, which are embedded into a split acrylic base plate with an incorporated conventional orthodontic expansion screw. In 1961 Haas 'Reintroduced' rapid maxillary expansion (RME) and mentions in 1970 that the use of RME is ideally during the growth spurt 18,19 . Reichenbach & Brückl 20 published an excellent survey on orthodontic treatment of maxillary transverse hypoplasia in 1967.

3 b) History of surgical treatment for maxillary constriction

Once skeletal maturity has been reached, orthodontic treatment alone cannot provide a stable widening of the constricted maxilla in cases of deficiencies of more than 5 mm. In general, an orthodontist can camouflage transverse discrepancies less than 5 mm with orthopedic forces alone 21 . The literature mentions several problems accompanied by RME on mature patients, such as failure and or relapse and periodontal problems with the tooth-borne appliances 22 . Timms & Vero 23 mention that 33-50% of the expansion has relapsed before stability is achieved. Others report the lack of movement of the maxillary halves; excessive tipping of the anchor teeth; buccal root resorption of the anchor teeth or even periodontal defects as the teeth are pushed through the buccal cortical plate, which lead to bony defects and gingival recession; unequal expansion and unpredictable relapse and the sensation of pain and necrosis of oral mucosa under the appliance. Bell and Starnbach 24,25,26 report that activation of an appliance against mature sutures can lead to the sensation of pain and necrosis of oral mucosa under the appliance. These forces can also result in periodontal defects as the teeth are pushed through the buccal cortical plate, which lead to bony defects and gingival recession. These complications can be avoided by surgically releasing the osseous structures that resist the expansive forces 24,26 . Therefore the combination of surgical and orthodontic treatment is advocated for widening of the maxilla in skeletally matured patients. Advantages of SARME include improvement of periodontal health; improved nasal air flow; elimination of the negative space, which results in less visible tooth and gingival structures upon smiling 27 . There is also a cosmetic improvement of the buccal hollowing secondary to postexpansion prominence at the site of the lateral wall osteotomy 24,26 . Tooth extractions for alignment of dental arches are often unnecessary 21 . Brown 28 probably first described a technique of SARME with midpalatal splitting in his textbook. Heiss 25 probably first inaugurated the midline splitting in the anterior maxilla for the extension of the compressed maxillary arch for orthodontic reasons. In 1961, Haas 19 described the downward and forward movement of the maxilla that occurs during RME because of the location of the Cranio Maxillofacial sutures. He believed that the maxillary halves separated from each other rather in a tipping than in a parallel fashion due to the strength of the zygomatic buttresses 19 . Isaacson & Ingram 29 and Isaacson et al. 30 mention that historically, the midpalatal suture was thought to be the area of resistance to expansion, but the facial skeleton increases its resistance to expansion as it ages and matures, and that the major site of resistance is not the midpalatal suture but the remaining maxillary articulations. Fertz 31 advocated that resistance of the zygomatic arch prevents parallel opening of the midpalatal suture. In 1975, Lines 32 and in 1976 Bell & Epker 24 demonstrated that the area of increased facial skeletal resistance to expansion was indeed not the midpalatal suture, but the zygomaticotemporal, zygomaticofrontal and zygomaticomaxillary sutures. Identification of these areas of resistance in the craniofacial skeleton stimulated the development of various maxillary osteotomies to expand the maxilla laterally in conjunction with orthodontic RME appliances 4. The areas of resistance to lateral forces in the midface are the piriform aperture (anterior), the zygomatic buttress (lateral), the pterygoid junction (posterior) and the midpalatal synostosed suture (median). In the early reports all four are transected 25,33,34,35 . In 1972 Steinhauser 36 reports a maxillary expansion osteotomy technique

without the use of distraction, a Le Fort I type of osteotomy in combination with the surgical splitting of the palate in the midline, after which a triangular uncortical iliac graft is inserted into the void created by the expansion. More recently, with the emphasis on decreased morbidity and ambulatory surgery, fewer supports are osteotomized; the anterior, lateral and median, the lateral and median, the anterior, posterior and lateral, the anterior and lateral. Most reports note that surgically assisted maxillary expansion is more stable than orthodontic RME alone 24,34,35,37 .

Glassmann et al. 28 , Alpern & Yurosko 39 and Lehmann & Haas 37 reported successful expansion in humans performed with a Hyrax appliance following a lateral osteotomy from the piriform rim to the pterygoid plate without palatal surgery. Their study did not consider the amount of skeletal versus dental expansion and the corresponding relapse following a retention period 40 uniform palatal expansion can be achieved without sectioning of either palate or the pterygomaxillary fissure 28 .

In the year 1999, Mommaerts⁴⁵ presented the Trans Palatal Distractor (TPD), which is a bone-borne device for SARME. After surgical release of the areas of maxillary support the tooth-borne devices used for SARME cause undesired movements of the abutment teeth during expansion and retention phases that could lead to periodontal problems 35, 28,41 . Prolonged retention and overcorrection is advisable to counteract skeletal relapse. The TPD avoids all of these aforementioned problems, since fixation is sought in palatal bone 32 . Recently, the Magdenburg Palatal Distractor (PD) was presented, also a bone-borne device which claims to have no relapse 22 .

4 c) History of Distraction

As mentioned before SARME is a form of distraction that was applied before its biological healing principles were known. Codivilla 1 was the first to describe the technique of distraction osteogenesis for the shortened femur in 1905. Ilizarov described the use of distraction osteogenesis in the field of Orthopedics to lengthen the leg bones in a large group of patients in 1990 2 . The technique is based on a 5-day period of rest after corticotomy before the expansion starts. This gives the tissue time to form the first callus but is too short for consolidation. Four phases of new bone formation can be described. The first is a fibrovascular hematoma; between day 5 and 7 collagen fibers are formed that will arrange parallel to the distraction vector. Second, the bone formation follows the collagen fibers through intramembranous ossification; from the outside to the inside. Third, remodeling phase of the new bone. Fourth, formation of solid compact bone with the same texture as the surrounding (old) bones. When the distraction is performed too fast, the collagen fibers might lose contact and there is no in growth of new bone, providing non- or mal-union. In cases of a too slow distraction premature consolidation can occur and the requested elongation cannot be reached.

5 d) Surgical technique

Since early in the 20th century various techniques have been developed for SARME. The main considerations have opposing interests. One side is a more invasive technique with maximal mobility of the maxillary halves for correction over larger distances with less force but with more possible complications. The other side is less invasive with less possible complications but with more relapse, more periodontal problems, and unexpected fractures. The opinions vary about the site of major resistance in transverse distraction in the midface and also about the method of releasing it. Most methods consider the zygomaticomaxillary junction the major site of resistance and perform a corticotomy through the zygomatic buttress from the piriform rim to the maxillopterygoid junction (fig 1). The midpalatal suture is historically considered the major place of resistance but this was proven to be untrue by Isaacson & Ingram 29 , Isaacson et al. 30 and Kennedy et al. 34 (Fig. 22). Still many, but not all, release the midpalatal suture to improve mobility and to prevent deviation of the nasal septum. The pterygoid plates are also a considerable site of resistance but because of the increased risk of injuring the pterygoid plexus by the osteotomy, some chose not to, without losing much mobility (Fig. 4). By not releasing the pterygoid junction, the pattern of opening of the maxillary halves is more V-shaped with the point of the V dorsally and it might be considered as an individual treatment to achieve more distraction either on the posterior or anterior level. The nasal septum is often released from its palatal base to avoid shifting to either side and thereby causing changes in nasal flow (Fig. 5). A tomographic study by Schwarz showed no significant change in nasal septum position in SARME without sectioning of the nasal septum and an increase nasal airway space⁶⁰. Of the studies on SARME mentioned in international literature, the mean age of the patients undergoing SARME varied from 19 to 29 years 23,35,38,40,41, 43,44, . The groups studied were quite small and mostly contained not more than 20 patients. The period of retention after expansion varies from 2 to 12 months. Generally, a period of three month is used. The amount of distraction at the canine level mentioned varies from 3.4 mm to 5.0 mm, in the first premolar region 4.7 mm to 5.9 mm and in the first molar region 3.4 mm to 8.0 mm. SARME is considered a procedure with little risk of serious complications , however several complications are mentioned in literature varying from life threatening epistaxis to a cerebrovascular accident, skullbase fracture with reversible oculomotor nerve pareses and orbital compartment syndrome 22,35, . Less serious complications reported are postoperative

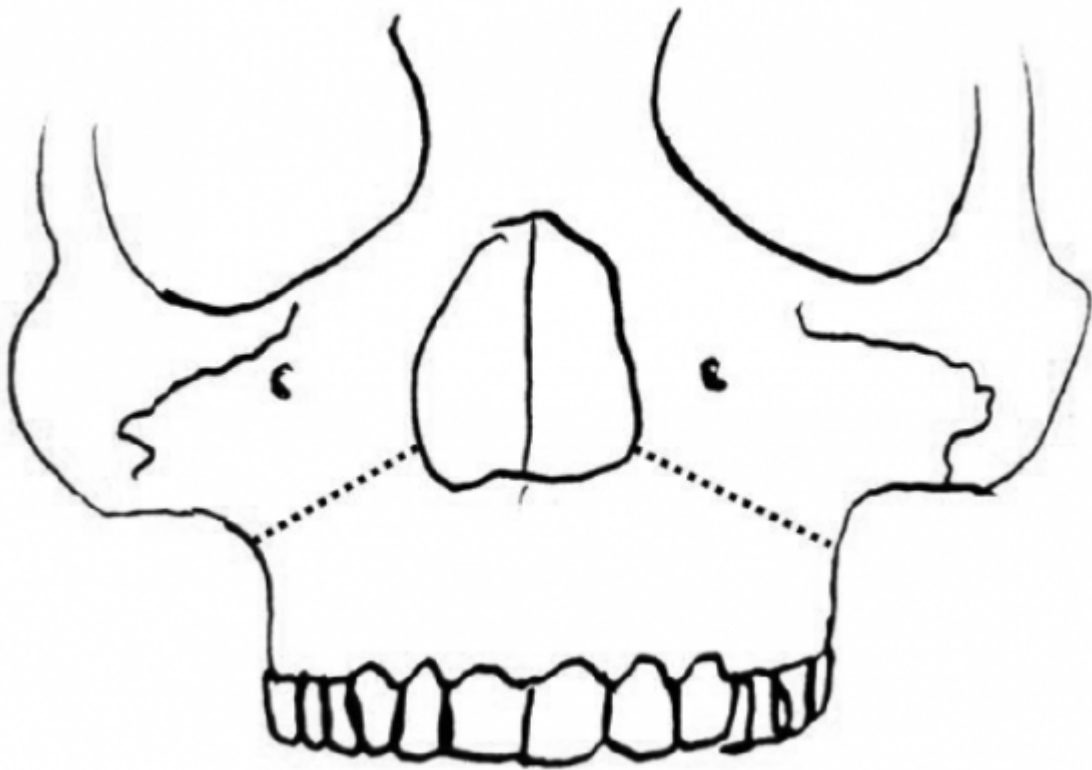


Figure 1: T

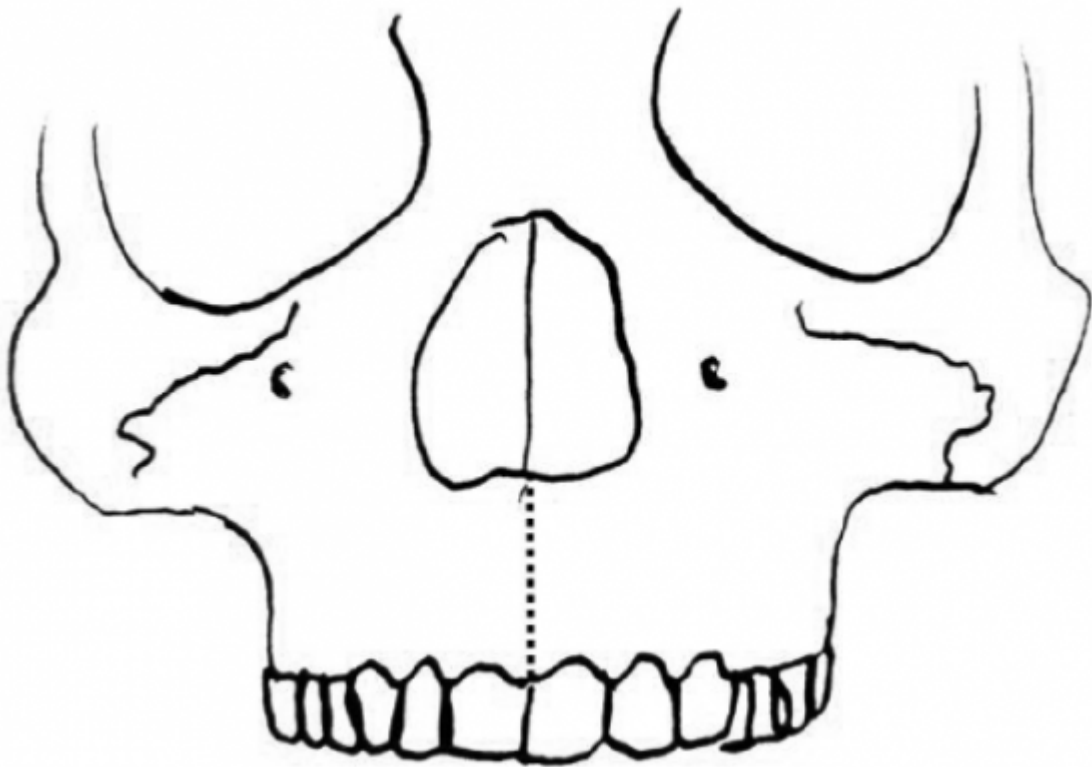


Figure 2:

1

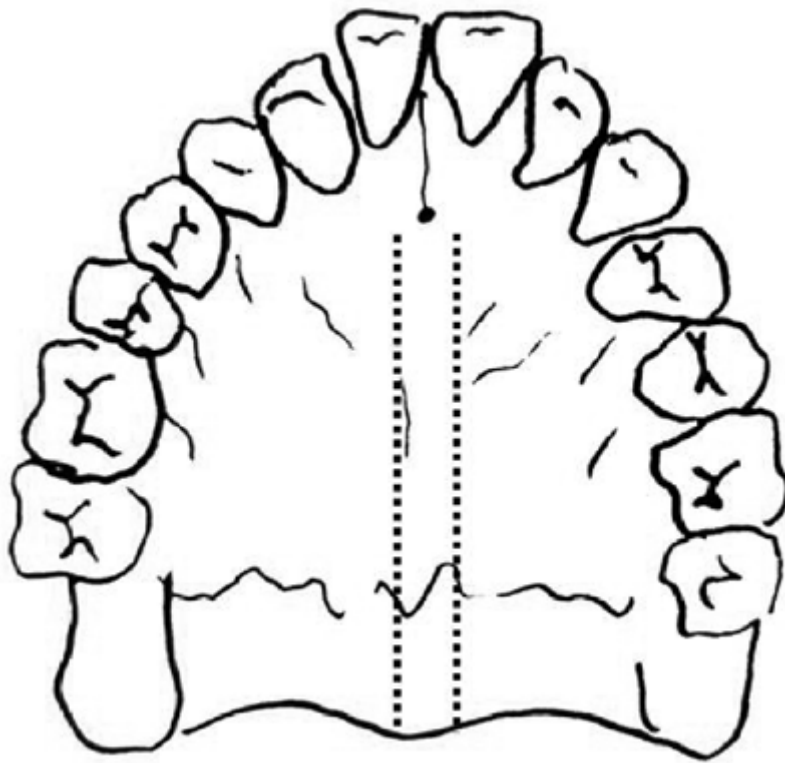
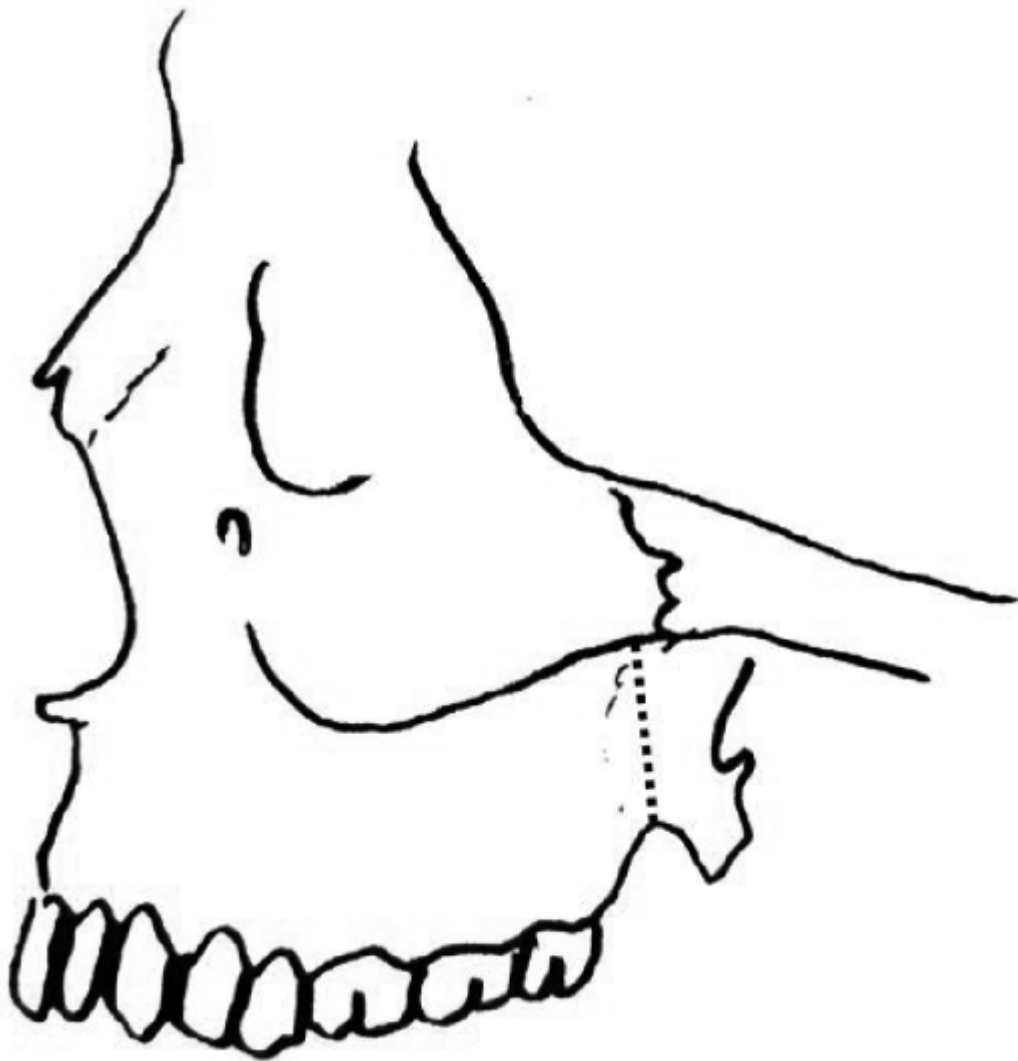


Figure 3: Figure 1 :

164 hemorrhage, pain, sinusitis, palatal tissue irritation/ulceration, asymmetrical expansion, nasal septum deviation,
165 periodontal problems and relapse 46 . ^{1 2}


¹© 2017 Global Journals Inc. (US)Year 2017

²© 2017 Global Journals Inc. (US)



23

Figure 4: Figure 2 :Figure 3 :



4

Figure 5: Figure 4 :

5

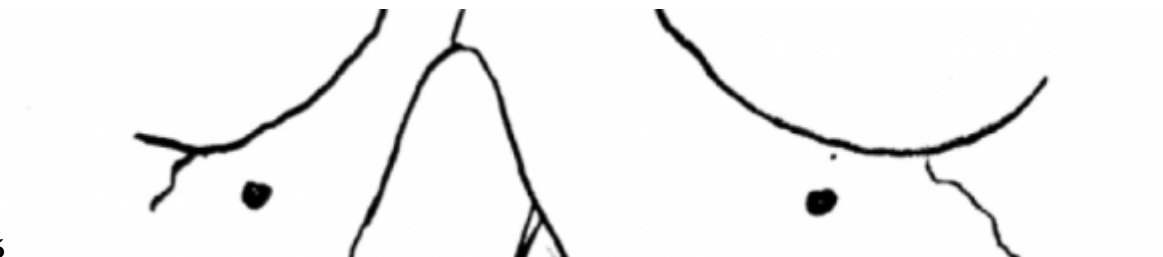

Figure 6: Figure 5 :

-
- [Barth] , Johann Ambrosius Barth . *Verlag, Leipzig*. P 101.
- [Bell ()] 'A review of maxillary expansion in relation to rate of expansion and patients age'. R A Bell . *Am J Orthod* 1982. 81 p. .
- [Lines ()] 'Adult rapid maxillary expansion with corticotomy'. P A Lines . *Am J Orthod* 1975. 67 p. .
- [Ilizarov ()] 'Clinical applications of the tensionstress effect for limb lengthening'. G A Ilizarov . *Clin Orthop* 1990. 250 p. .
- [Lehman et al. ()] 'Conservative surgical orthodontic adult rapid palatal expansion: sixteen cases'. J A Lehman , A J Haas , A S Glassman , S J Nahigian , J M Medway , H I Aronowitz . 16: 749-755. 38. 38. *Clin Plast Surg* 1989. 1984. 86 p. . (Am J Orthod)
- [Swennen et al. ()] 'Craniofacial distraction osteogenesis: a review of the literature. Part I: clinical studies'. G Swennen , H Schliephake , R Dempf , H Schierle , C Malevez . *Int J Oral Maxillofac Surg* 2001. 30 p. .
- [Scott ()] *Dentofacial development and growth. oxford*, J H Scott . 1967. Pergamon Press. p. .
- [Neubert et al. ()] 'Die operative gaumennahterweiterung durch eine modifizierte Le-Fort-I-osteotomie'. J Neubert , S Somsiri , H P Howaldt , K Bitter . *Dtsch Z Mund Kiefer Gesichts Chir* 1989. 13 p. .
- [Starnbach et al. ()] 'Faciosteletal and dental changes resulting from rapid maxillary expansion'. H Starnbach , D Bayne , J Cleall , J D Subtelny . *Angle Orthod* 1966. 36 p. .
- [Isaacson and Ingram ()] 'Forces produced by rapid maxillary expansion I: Forces present during treatment'. R J Isaacson , A H Ingram . *Angle Orthod* 1964. 34 p. .
- [Isaacson et al. ()] 'Forces produced by rapid maxillary expansion II'. R J Isaacson , J L Wood , A H Ingram . *Angle Orthod* 1964. 34 p. 261.
- [Pinto et al. ()] 'Immediate postexpansion changes following the use of the transpalatal distractor'. P X Pinto , M Y Mommaerts , G Wreakes , Wvgja Jacobs . *J Oral Maxillofac Surg* 2001. 59 p. .
- [Haas ()] 'Just the beginning of dentofacial expansion'. A J Haas . *Am J Orthod* 1970. 57 p. .
- [Mehra et al. ()] 'Lifethreatening, delayed epistaxis after surgically assisted rapid palatal expansion: a case report'. P Mehra , D A Cottrell , A Caiazzo , R Lincoln . *J Oral Maxillofac Surg* 1999. 57 p. .
- [Chung et al. ()] 'Maxillary sagittal and vertical displacement induced by surgically assisted rapid palatal expansion'. C H Chung , A Woo , J Zagarinsky , R L Vanarsdall , R J Fonseca . *Am J Orthod Dentofacial Orthop* 2001. 120 p. .
- [Steinhauser ()] 'Midline splitting of the maxilla for correction of malocclusion'. E W Steinhauser . *J Oral Surgery* 1972. 30 p. .
- [Talma] *Mémoires sur quelques points fondamentaux de la médecine dentaire*, A F Talma . Tircher. 1852. Bruxelles.
- [Lefoulon ()] *Nouveau traité Théorique et pratique de l'art dentaire du dentiste. Pairs: fortin*, P J Lefoulon . Masson. 1841: 198.
- [Codivilla ()] 'On the means of lengthening, in the lower limbs, the muscles and tissues which are shortened through deformity'. A Codivilla . *Am J Orthop Surg* 1905. (2) p. 353.
- [Lefoulon] *Orthopédie dentaire. Gazette de l'hôpital*, P J Lefoulon . 1839 p. .
- [Kennedy et al. ()] 'Osteotomy as an adjunct to rapid maxillary expansion'. J W Kennedy , W H Bell , O L Kimbrough , W B James . *Am J Orthod* 1976. 70 p. .
- [Melsen ()] 'Palatal growth studied on human autopsy material'. B Melsen . *Am J Orthod* 1975. 68 p. .
- [Chr and Gerlach ()] 'Palatinaldistraktor Ein innovativer ansatz für die gaumennahterweiterung'. Zahl Chr , K L Gerlach . *Mund Kiefer Gesichts Chir* 2002. 6 p. .
- [Öztürk et al. ()] 'Pulpal bloodflow: effects of corticotomy and midline osteotomy in surgically assisted rapid palatal expansion'. M Öztürk , C Doruk , I Özeç , S Polat , H Babacan , A Biçakci . *J Cranio-Maxillofacial Surg* 2003. 31 p. .
- [Alpern and Yurosko ()] 'Rapid palatal expansion in adults'. M C Alpern , J J Yurosko . *Angle Orthod* 1987. 57 p. .
- [Haas ()] 'Rapid Palatal expansion of the maxillary dental arch and nasal cavity by opening the midpalatal suture'. A J Haas . *Angle Orthod* 1961. 31 p. .
- [Schröder-Benseler ()] Schröder-Benseler . *Die kiefererweiterung. Erg ges Zahnhk*, 1913. p. 629.
- [Wertz ()] 'Skeletal and dental changes accompanying rapid midpalatal suture opening'. R A Wertz . *Am J Orthod* 1970. 58 p. .
- [Persson] 'Structure and growth of facial sutures'. M Persson . *Odontol Revy* 1973 (6) p. 24.

5 D) SURGICAL TECHNIQUE

- 219 [Krogman ()] 'Studies in growth changes in the skull and face of anthropoids: Ectocranial and endocranial suture
220 closure in anthropoids and old world apes'. W M Krogman . *Am J Phys Anthropol* 1930. 46 p. .
- 221 [Bell and Epker ()] *Surgical orthodontic expansion of the maxilla*, W H Bell , B N Epker . 1976. 70 p. .
- 222 [Bell and Jacobs ()] 'Surgical-orthodontic correction of horizontal maxillary deficiency'. W H Bell , J D Jacobs .
223 *J Oral Surg* 1979. 37 p. .
- 224 [Kraut ()] 'Surgically assisted rapid maxillary expansion by opening the midpalatal suture'. R A Kraut . *J Oral*
225 *Maxillofac Surg* 1984. 42 p. .
- 226 [Pogrel et al. ()] 'Surgically assisted rapid maxillary expansion in adults'. M A Pogrel , L B Kaban , K Vargervik
227 , S Baumrind . *Int J Adult Orthodon Orthognath Surg* 1992. 7 p. .
- 228 [Bays and Greco ()] 'Surgically assisted rapid palatal expansion: an outpatient technique with long-term
229 stability'. R A Bays , J M Greco . *J Oral Maxillofac Surg* 1992. 50 p. .
- 230 [Strömberg and Holm ()] 'Surgically assisted, rapid maxillary expansion in adults. A retrospective longterm
231 follow-up study'. C Strömberg , J Holm . *J Cranio Maxillofacial Surg* 1995. 23 p. .
- 232 [Silverstein and Quinn ()] 'Surgically-assisted rapid palatal expansion for management of transverse maxillary
233 deficiency'. K Silverstein , P D Quinn . *J Oral Maxillofac Surg* 1997. 55 p. .
- 234 [Latham and Burston ()] 'The postnatal pattern of growth at sutures of the human skull'. R A Latham , W R
235 Burston . *Dent Pract* 1966. 17 p. .
- 236 [Timms and Vero ()] 'The relationship of rapid maxillary expansion to surgery with special reference to
237 midpalatal synostosis'. D J Timms , D Vero . *Br J Oral Surg* 1981. 19 p. .
- 238 [Brown] *The surgery of oral and facial diseases and malformation. 1938. 4 th Ed*, Gvi Brown . London; Kimpton.
239 p. 507.
- 240 [Mommaerts ()] 'Transpalatal distraction as a method of maxillary expansion'. M Y Mommaerts . *Brit J Oral*
241 *Maxillofac Surg* 1999. 37 p. .
- 242 [Gerlach and Zahl ()] 'Transversal palatal expansion using a palatal distractor'. K L Gerlach , C Zahl . *J Orofac*
243 *Orthop* 2003. 64 p. .
- 244 [Angell] *Treatment of irregularity of the permanent or adult teeth*, E H Angell . 1860: 1: 540-544. p. . (Dental
245 Cosmos)
- 246 [Mossaz et al. ()] 'Unilateral and bilateral corticotomies for correction of maxillary transverse discrepancies'. C
247 F Mossaz , F K Byloff , M Richter . *Eur J Orthod* 1992. 14 p. .
- 248 [Reichenbach and Brückl] *Zahnärztliche fortbildung heft 7*, E Reichenbach , H Brückl . (Kieferorthopädische
249 klinik und therapie)