

# Behçet's Disease Revealed by Two Ruptured False Aneurysms and Literature Review

Abdellah Rezziki<sup>1</sup>, Houssam Alzaarir<sup>2</sup>, Oussama Anane<sup>3</sup>, Adnane Benzirar<sup>4</sup> and Omar Elmahi<sup>5</sup>

<sup>1</sup> Mohammed VI University Hospital

*Received: 7 December 2017 Accepted: 1 January 2018 Published: 15 January 2018*

---

## Abstract

Behçet's disease is an uncommon systemic process generally developing during the third or fourth decade of life. Recurrent inflammatory lesions are characteristic. Cardiovascular involvement, which may be arterial or venous, is rare but with particularly severe prognosis. One case of concomitant aortic and iliac aneurysms is reported. The patient underwent emergency surgery for acute rupture. Surgical revascularization was performed, mainly with prosthetic grafts, and patch aortoplasty. On the basis of this case and cases reported in the literature, it can be concluded that morbidity and mortality are high because of the etiology underlying vascular involvement in Behçet's disease.

---

## *Index terms—*

## 1 I. Introduction

Behçet disease is a clinical syndrome, initially defined by the presence of aphthous stomatitis, recurrent uveitis, and genital ulcers that now is recognized as a multisystemic vasculitis with an undulating course of exacerbations and remissions [1,2]. There is no universally accepted diagnostic test for Behçet disease. In view of this rare and concomitant localization, we present this unusual clinical case of angio-Behçet.

## 2 II. Case Report

A 42-year-old woman was admitted to the emergency department with complaints of severe abdominal and back pain, progressive fatigue, and dizziness. At physical examination her abdomen was tender, and femoral artery pulses were present. The history of the patient found a notion of bipolar aphthous. Blood pressure was 70/40 mm Hg, and cardiac auscultation was normal except for sinus tachycardia. Chest x-ray films were normal. Laboratory investigations revealed a hemoglobin level of 9.2 g/dL and hematocrit of 25%. Bedside abdominal ultrasound revealed a retroperitoneal hematoma. The CT scan revealed a rupture of the sup-renal aorta and the iliac bifurcation.

The patient was taken to the operating theater urgently. After thoraco-lumbotomy, the large hematoma was seen in the retroperitoneal field. The thoracic aorta above the coeliac trunk was clamped, and the false aneurysm sac was opened. Massive fresh hematoma and blood were aspirated from the operative field, and the first perforation site was seen on the left posterior wall of the proximal abdominal aorta (Figure 1), the second perforation site was in the distal abdominal aorta (Figure ??), approximately 4 cm in diameter including the proximal left common iliac artery. In Fig. ??: Second Perforation Site in the Distal Abdominal Aorta The proximal ulcer of the aorta was performed with a Dacron-patch (Figure ??), and an 8-mm PTFE graft was used for reconstruction of the left common iliac artery, the distal side of the graft was anastomosed end-to-side to the left common femoral iliac artery, and the proximal side was anastomosed end-to-side to the distal aorta (Figure ??). The common right iliac artery was re-implanted to the graft (Figure ??). After intensive care therapy for 5 days, rapid healing was observed, and the patient was transferred to the department of vascular surgery. The

patient has had complaints of arthralgia of the knees, oral aphthous lesions, anorexia, and weakness for the last 3 months. At physical examination we find a minor genital ulceration. The pathergy reaction, a hypersensitivity of the skin to a needle prick, which is peculiar to this syndrome, was positive. Rheumatoid factor, anti-DNA, human leukocyte antigen-B5, and antinuclear antibody were normal.

The erythrocyte sedimentation rate and C-reactive protein concentration were mildly elevated. Ocular involvement (uveitis) was not detected at fundoscopic examination.

The diagnosis of Behçet's disease has been retained a posteriori according to the criteria of the International Study group for Behçet disease.

### 3 III. Discussion

Behçet's disease is a systemic vasculitis reported for the first time by Hulusi Behçet in 1937 [1]. The common anatomical substrate is different from vasculitis that can affect all vessels, their nature and size, with predominance for venous involvement [2].

Arterial complications may be a mode of revelation and in most cases constitute a medical-surgical emergency [3]. The diagnosis is based on diagnostic criteria established by the International Study group for Behçet disease [4].

The frequency of vascular involvement in Behçet's disease is highly variable from one population to another ranging from 2 to 46% [2,3,5]. Arterial damage is more rare and its prognosis is darker than that of venous involvement.

Its frequency is between 2 and 7% of cases of MB [6,7], in the retrospective series of Sekkach conducted on 92 patients with Behçet's disease among them 30 cases had vascular damage, venous involvement was observed in 29.3% of cases versus 14.1% of arterial damage [8]. It is probably underestimated, taking into account the frequency of 34% noted in the autopsy series of Lakhanpal [9].

This vasculitis can affect all arteries, and can be manifested by aneurysmal lesions or arterial thrombosis: the latter being less frequently reported [2,8,10].

The localization of aneurysmal involvement is ubiquitous: it can be seen in the different arterial territories and can be life-threatening [6]. The mortality by rupture is estimated at 60% [3,11].

The presence of aneurysmal lesions represents a medical-surgical emergency, and requires a focus on the initial pathology in order to establish a suitable medical treatment including corticosteroids and immune suppressants, their rapid evolution towards rupture being the rule, without the size aneurysm is considered a predictive factor [11].

The pulmonary arteries and the abdominal aorta are the preferred sites of arterial aneurysms [3,12]. The other localizations concern the territories of the superficial femoral artery, the brachiocephalic arterial trunk and the popliteal artery [2,8,13].

In the Bensaid series [3], aortic aneurysmal involvement was of the order of 28% of cases, femoral 38.5% of cases, popliteal 7.5% of cases, leg arteries 7.5% of cases, carotid 8.7% of cases, primary iliac arteries 8.7% of cases.

Concomitant damage to the thoracic aorta and iliac bifurcation is never currently described in the literature. Tuzun [14], in a series of 24 cases of arterial F aneurysms, finds 9 cases of aortic involvement. Association with other arterial aneurysms is common in BD. In a Japanese meta-analysis [15], the multiple attainment rate is 36%. Freyrie [16] published a case of BD with 5 aneurysms including 1 aortic, 2 femoral, 1 anastomotic and one at the puncture site that were operated on over a period of 6 years. Abdominal ultrasound with Doppler complement allows to specify the vascular nature of the lesion and sometimes the topography of the lesions. Abdominal CT angiography is the best positive and topographic diagnostic examination of aneurysmal lesions [1,2,14].

The angio-MRI provides the same data as the CT with a better study of the wall and arterial arborization.

It is necessary to proscribe in this malady angiography providing false aneurysms at the point of puncture [1]. In our patient, the abdominal ultrasound and the angio-CT allowed to make the diagnosis of the false aneurism.

Medical treatment is urgently needed, including immunosuppressive agents based on bolus corticosteroid therapy and cyclophosphamide IV, and is routinely performed postoperatively to avoid the risk of suture release [1,2,3,6].

The surgical treatment consisted of flattening the false aortic aneurysm with closing the breach with a dacron patch and aorto-femoral bypass for the second false aneurysm.

This surgery is particularly delicate, because of the inflammatory terrain with advanced peripatitis, and exposes to a high risk of postoperative complications reported in 30 to 40% of cases. [6,14].

Recently, endovascular treatment has been used as an interesting therapeutic alternative, simultaneous involvement of the thoracic aorta and iliac bifurcation is rare and treatment with a stent-graft has been performed in only one case [19]. Conceive without associated medical treatment (corticosteroids + immune suppressants), [6,18].

## 4 IV. Conclusion

Arterial damage in Behçet's disease is uncommon and is mainly represented by abdominal aortic aneurysm. The aneurysm with double localization thoracic aorta and iliac bifurcation is extremely rare.

---

CT angiography CT has a place of choice in the diagnostic and topographic approach of these lesions, especially in the emergency framework, thus allowing a fast management of the patient.

Medical treatment with corticosteroids and immunosuppressants is still needed to stabilize the lesions and prevent the outbreaks of this disease.

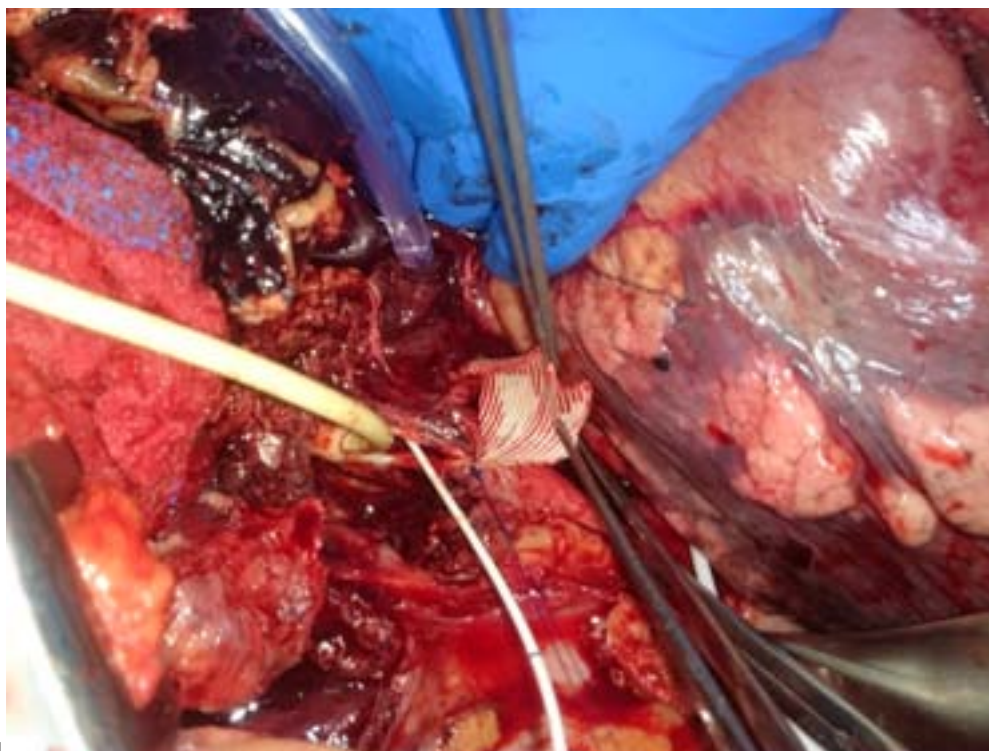


Figure 1: Fig. 1 :

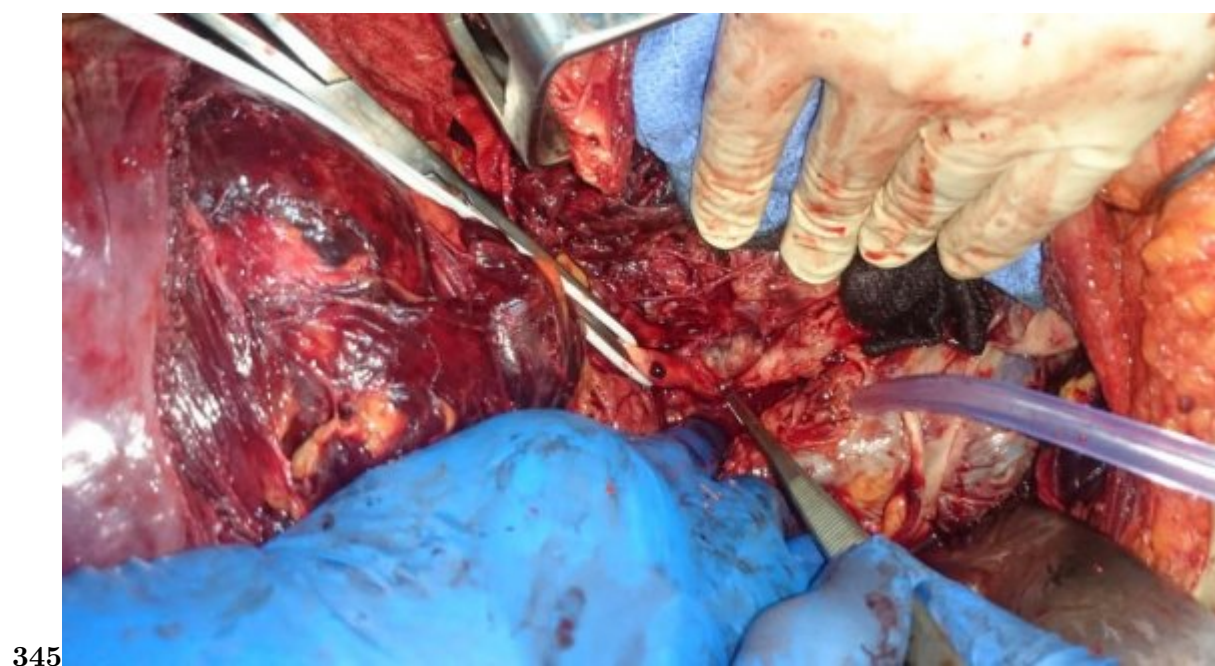

Figure 2: Fig. 3 :Fig. 4 :FFig. 5 :

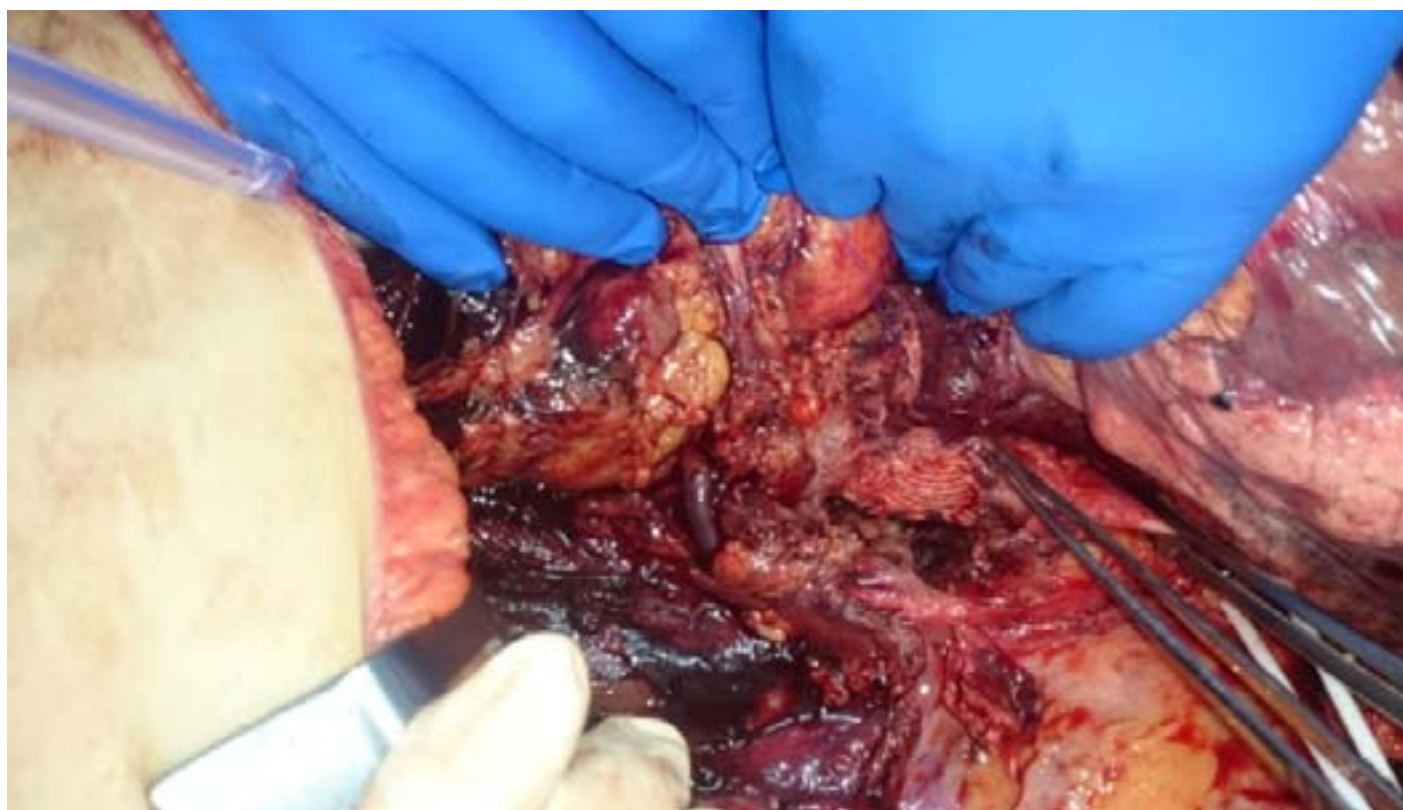

Figure 3:



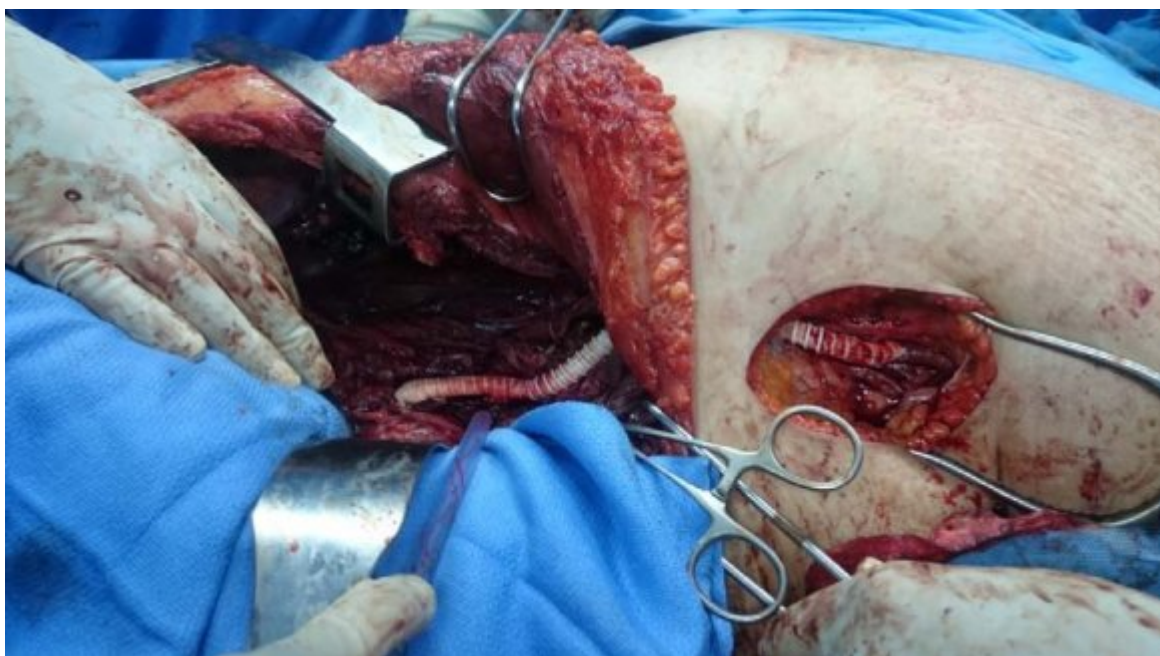


Figure 4:



- 
- [Koike et al. ()] 'A case of aorto-enteric fistula after reconstruction of an abdominal aortic aneurysm associated with Behçet's disease and special reference to 95 reported cases in Japan'. S Koike , K Matsumoto , M Kokubo , Y Mori , S Murakawa , M Hirose . *Nippon Geka Gakkai Zasshi* 1988. 89 p. .
- [Ohshima et al. ()] 'A case of giant common carotid artery aneurysm associated with vascular Behçet disease: successfully treated with a covered stent'. T Ohshima , S Miyachi , K Hattori , H Iizuka , T Izumi , Y Nakane . *Surg Neurol* 2008. 69 p. .
- [Bensaid et al. ()] *Arterial complications of Behçet's disease: about 47 cases. E-memoirs of the National Academy of Surgery*, Y Bensaid , B Lekehal , A El Mesnaoui , Z Bouziane , N Sedki . 2008. 7 p. .
- [Mehmet Erdem Memetoglu and Kalkan ()] *Behçet's disease with aneurysm of internal iliac artery and percutaneous treatment. Interactive Cardio Vascular and Thoracic Surgery*, As?m Mehmet Erdem Memetoglu , Kalkan . 2012. 14 p. .
- [Sekkach et al. ()] 'Behçet's disease: thirty observations with pulmonary vascular damage and peripheral vessels'. Y Sekkach , N Elomri , M Jira , M Elqatni , J Fatihi , F Mekouar . *Presse Méd* 2012. 41 p. .
- [Azghari et al. ()] 'Celiac trunk aneurysm revealing Behçet's disease. About two cases'. A Azghari , H Belmir , M Bouayad , Z Bouziane , R Idrissi , B Lekehal . *J Mal Vasc* 2009. 34 p. .
- [International study group for Behçet's disease. Criteria for diagnosis of Behçet disease Lancet ()] 'International study group for Behçet's disease. Criteria for diagnosis of Behçet disease'. *Lancet* 1990. 335 p. .
- [Hamza ()] 'Large artery involvement in Behçet's disease'. M Hamza . *J Rheumatol* 1987. 14 p. .
- [B'chirhamzaoui S.\* et al. ()] 'Le groupe tunisien d'étude sur la maladie de Behçet. Behçet's disease in Tunisia. Clinical study of 519 cases'. B'chirhamzaoui S.\* , A Harmel , K Bouslama , M Abdallah , M Ennaffaa , S . *Rev Med Interne* 2006. 27 p. .
- [Tuzun et al. ()] 'Management of aneurysms in Behçet's syndrome: an analysis of 24 patients'. H Tuzun , K Besirli , A Sayin , F S Vural , V Hamuryudan , N Hizli . *Surgery* 1997. 121 p. .
- [Lakhanpal et al. ()] 'Pathologic features of Behçet's syndrome: a revue of Japanese autopsy registry data'. S Lakhanpal , K Tani , J T Lie , K Katoh , Y Ishigatsubo , T Ohokubo . *Hum Pathol* 1985. 16 p. .
- [Hafsa et al. ()] 'Superior mesenteric artery aneurysm revealing a Behçet disease: a case report'. C Hafsa , S Kriaa , M Zbidi , A Laifi , F Noomene , M Golli . *Ann Cardiol Angeiol* 2006. 55 p. .
- [Kural-Seyahi et al. ()] 'The long-term mortality and morbidity of Behçet syndrome: a 2-decade outcome survey of 387 patients followed at a dedicated center'. E Kural-Seyahi , I Fresko , N Seyahi , Y Ozyazgan , C Mat , V Hamuryudan . *Medicine* 2003. 82 p. .
- [Merci et al. ()] 'Thrombosis of the superior mesenteric artery and Behçet syndrome'. P Merci , J Constans , B Tissot , A Sebban , G Gorid , E Rullier . *Rev Med Interne* 1996. 17 p. .
- [Comarmond et al. ()] 'Treatment of Behçet's disease'. C Comarmond , B Wechsler , P Cacoub , D Saadoun . *Rev Méd Interne* 2014. 35 p. .
- [Freyrie et al. ()] 'True and false aneurysms in Behçet's disease: case report with ultra structural observations'. A Freyrie , O Paragona , G Cenacchi , G Pasquinelli , G Guiducci , G L Faggioli . *J Vasc Surg* 1993. 17 p. .
- [Tazi-Mezalek et al. ()] 'Vascular damage during Behçet's disease'. Z \* Tazi-Mezalek , W Ammouri , M Maamar . *Rev Med Interne* 2009. 30 p. .
- [Hassikou et al. ()] 'Vascular involvement in Behçet's disease: Two case reports'. H Hassikou , W Bono , R Bahiri , S Abir , M Benomar , N H Hassouni . *Joint Bone Spine* 2002. 69 p. .
- [Tohmé et al. ()] 'Vascular manifestations of Behçet's disease Eighteen cases among 140 patients'. A Tohmé , N Aoun , B El Rassi , E Ghayad . *Joint Bone Spine* 2003. 70 p. .