

Non Functioning Paraganglioma of the Urinary Bladder Treated by Transurethral Resection: Report of a New Case

Chelbi Emna

Received: 15 December 2017 Accepted: 5 January 2018 Published: 15 January 2018

Abstract

Paragangliomas are extraadrenal tumors of the autonomic nervous system and may be found within the skull base, neck, mediastinum and periaortic region. Paragangliomas of the urinary bladder are rare, and nonfunctioning bladder paraganglioma is even rarer and not easily recognized. Histological examination is often key in leading to a definitive diagnosis. The current report presents a case of a 59-year-old female with urinary bladder paraganglioma. The patient presented with only painless gross haematuria. A transitional cell carcinoma was suspected but histological examination and immunohistochemistry of a transurethral resection specimen confirmed the correct diagnosis. In the present report, the clinical features, diagnosis and management of non-functional paraganglioma of the urinary bladder are discussed.

Index terms—

1 Introduction

Paraganglioma of the urinary bladder is a rare tumor, accounting for less than 0.06% of all vesical tumors and less than 1% of all the pheochromocytomas [1,2]. About 98% of the paragangliomas are located in the abdomen, 90% of these are in the adrenal medulla with 10% extra-adrenal sites extending from neck to the pelvis [3]. Paraganglioma arises from the chromaffin tissue of the sympathetic nerves of the bladder wall. As they are rare tumors there are pitfalls in their diagnosis, and no standard treatment protocols are available.

2 II.

3 Case Report

A 59-year-old woman complaining of painless gross hematuria for six months was admitted to our hospital. Her family history was unremarkable, and she had no previous medical problems. Her blood pressure was 110/70-80 mmHg, and her heart rate was in the normal range. Physical examination showed no evidence of hypertensive disease. Abdominal ultrasound showed a large protruding tumor over the left lateral wall of the bladder measuring 4.0 × 3.0 cm (Figure ??). Our submucosal mass was seen on the left lateral wall near the neck of the urinary bladder, with normal mucosal covering. No sign of any metastatic disease was found on computed tomography (CT) scan of other abdominal organ systems.

Transurethral resection of bladder tumor (TURBT) was performed (Figure ??). This TURBT was complete, and tissue was submitted for histopathological examination.

Histologically, bladder mucosa was infiltrated by a proliferation arranged in nests and lobules which are surrounded by a thin vascular network (Figure 3). Tumor cells were polygonal, and provided with an abundant amount of granular, eosinophilic or clear cytoplasm. The nucleus was round with delicate chromatin and inconspicuous nucleoli. There were no mitotic figures. Immunohistochemistry showed strong cytoplasmic positivity of chromogranin and synaptophysin (Figure ??). PS100 stained sustentacular cells and Cytokeratin was negative.

The final diagnosis was nonfunctioning paraganglioma of the urinary bladder. The Patient did not receive any further treatment. The Biopsy of the tumor bed during the first endoscopic control did not show any macroscopic or microscopic recurrence, and the rate of plasma free metanephrines was normal. On a recent

follow-up at 24 months, her cystoscopy examination did not reveal any evidence of recurrence (Figure 3). Her radiological assessment (thoracicabdominopelvic CT) was negative for metastatic disease. III.

4 Discussion

Paragangliomas are tumors of the paraganglion system arising from chromaffin cells in or about sympathetic ganglia and account for 10% of all pheochromocytomas [4]. They account for < 1% of all bladder tumors [4].

Paraganglioma of the urinary bladder is rarely encountered, and nonfunctioning bladder paraganglioma is even rarer [5]. The first case of bladder paraganglioma was reported in 1953 by Zimmerman et al. [6].

The underlying mechanism of bladder paraganglioma remains unclear. Previous studies have shown that bladder paraganglioma occurs more frequently in females than males (female/male ratio is 3:1), primarily during the second and third decades of life [7]. The majority (83%) of paragangliomas of the urinary bladder are hormonally active [8]. However, nonfunctioning paragangliomas are rarer and more difficult to diagnose due to their nonsecreting nature [8]. Therefore, the patients provided no history of hypertension, headache or flushing that would suggest a diagnosis of secreting paraganglioma and endocrine tests, including catecholamines and vanillylmandelic acid in a 24-h urine sample, are rarely considered in the management of nonfunctioning paragangliomas [5].

Nonfunctioning bladder paragangliomas are often found in routine imaging exams that show the possibility of bladder cancer. In most methods of imaging, this neoplasm is indistinguishable from other types of tumors, but some features may lead to the suspicion of bladder paraganglioma such as small intramural lesions which may be accentuated after the administration of contrast in MRI, whereas larger lesions lose the uniformity of attenuation due to necrotic areas [9]. The signal strength on T2 weighted images can be very high in these tumors allowing their characterization [9]. The metaiodobenzylguanidine (MIBG) is highly specific for pheochromocytoma, and it can be useful to distinguish between functional and nonfunctional tumors, but it is less sensitive compared to MRI to detect paragangliomas [9,10].

Determination of the site of primary or metastatic disease is probably best achieved with I-MIBG scintigraphy when available. Its disadvantages include limited availability and high cost, reasons why our patient did not do it [11].

The cystoscopic appearance of a submucosal tumor, yellow at the cut, should raise the suspicion of bladder paraganglioma [12,13]. Histopathologically, the tumor cells show characteristic zellballen or nesting pattern with delicate fibrovascular stroma [14]. Immunohistochemistry shows strong cytoplasmic expression of chromogranin, synaptophysin and neuron-specific-enolase in the tumor cells and supporting cells stain by S-100 protein [15]. The differential diagnoses of the urinary bladder paraganglioma include urothelial carcinoma, metastatic renal cell carcinoma, prostatic carcinoma, malignant melanoma, and granular cell tumor [14]. Histological appearance and immunoprofile as described above helped us to distinguish bladder paraganglioma from other differential diagnoses.

Between 5 and 15% of the paragangliomas of the urinary bladder are said to be malignant. However, no histological criteria have been established to distinguish between benign and malignant tumors. Only the appearance of local invasion or distant metastases confirms that the tumor is cancerous [16].

Treatment modalities include transurethral resection and partial or total cystectomy combined with pelvic lymph node dissection, especially in the presence of proven metastasis [17,18].

With the advances in laparoscopy techniques, laparoscopic partial cystectomy has become the treatment of choice [5,18]. However, the optimal management mode is still uncertain [5]. Transurethral resection is considered to be feasible in tumors of less than 3 cm in size without deep parietal infiltration [19]. In the present case, a transurethral resection was successfully performed, and we did not notice any transient hypertensive crisis during tumor manipulation. Our Patient did not receive any further treatment, and her cystoscopy examination and radiological assessment did not reveal any evidence of recurrence after a follow-up of 2 years.

However, regular follow-up is necessary to detect late recurrences [20]. It must be lifelong and include cystoscopy and imaging study. No consensus has been established for the frequency of these measures: nevertheless, we suggested at least an annual follow-up for those patients who are asymptomatic or whenever clinically indicated.

5 IV. Conclusion

Non-functioning bladder paragangliomas may present clinical, radiology and pathological features similar to bladder cancer.

A definitive diagnosis may be reached only by histology, and no histological criteria have been established to distinguish between benign and malignant tumors.

Transurethral resection for bladder paraganglioma may be a treatment of choice, offering several advantages, including reduced invasion, rapid recovery and early discharge from the hospital, but the optimal management mode remains uncertain. ¹

¹© 2018 Global Journals

12

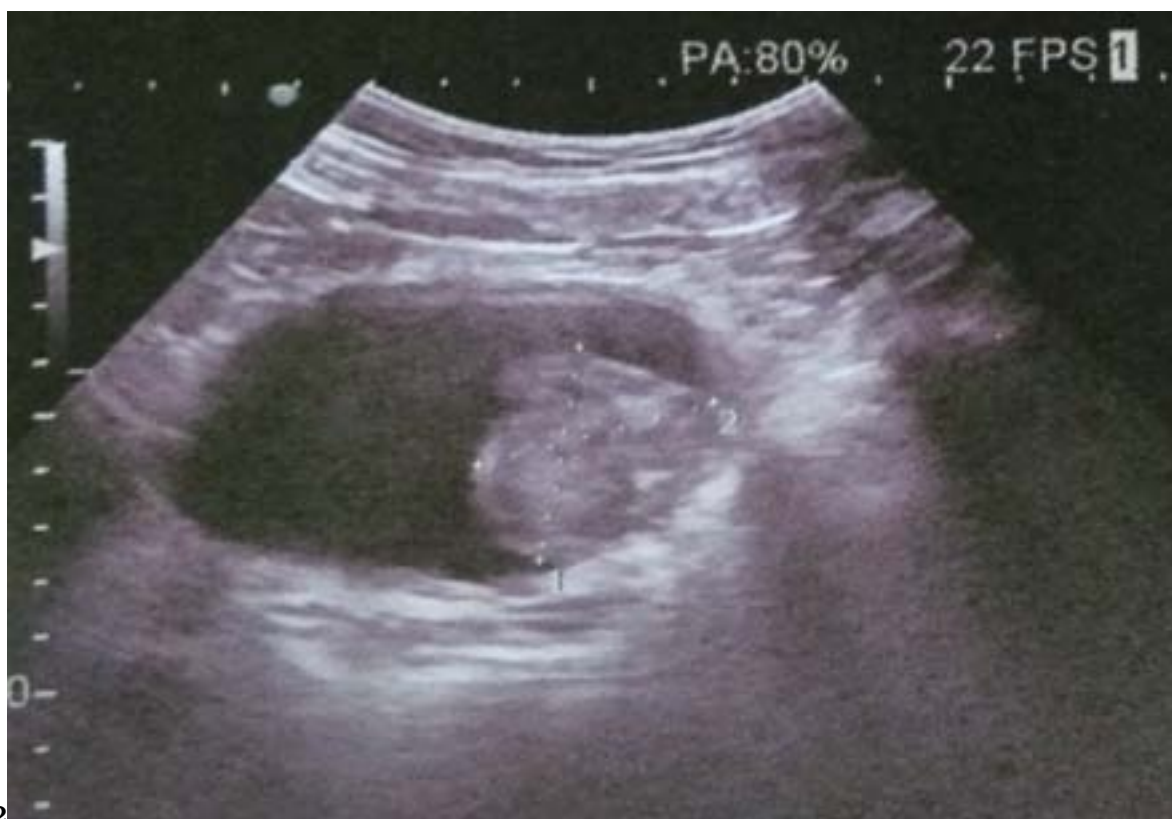

Figure 1: Fig. 1 :Fig. 2 :

3

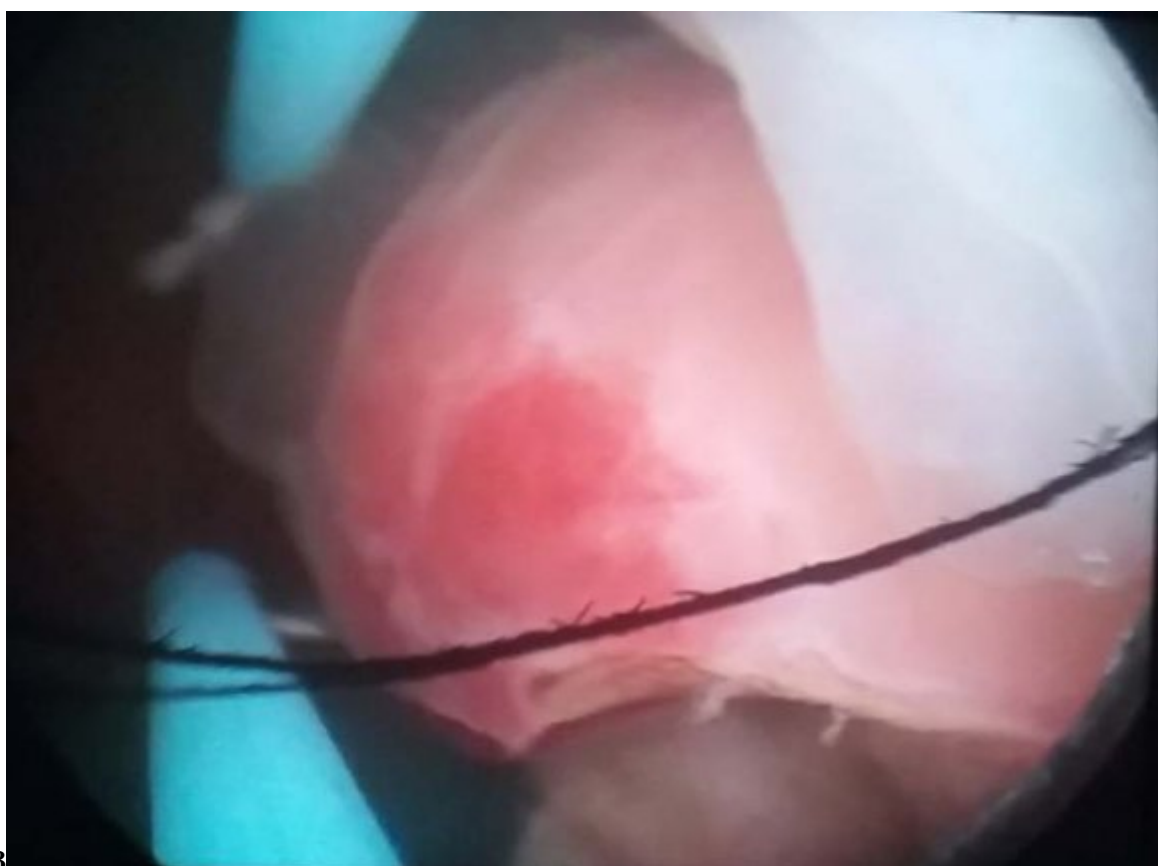
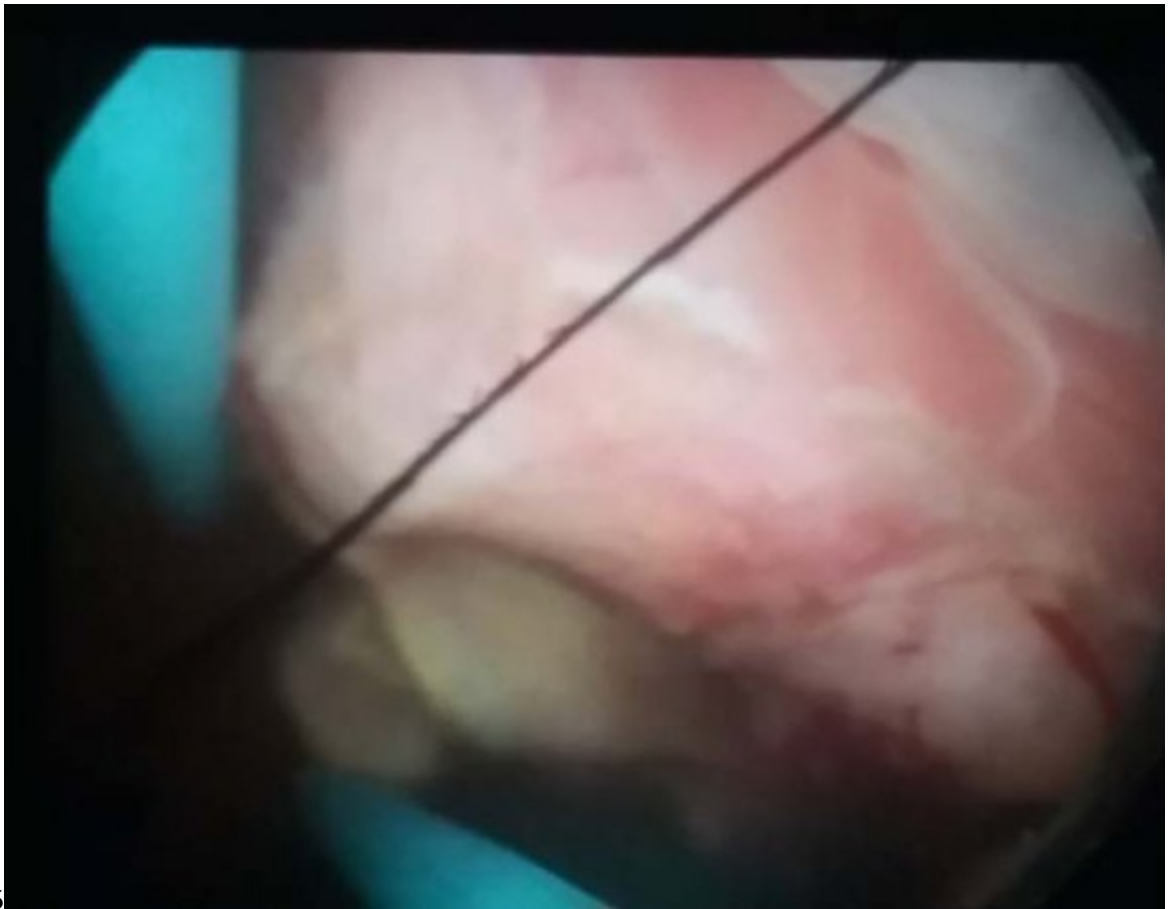

Figure 2: Fig. 3 :



45

Figure 3: Fig. 4 :FFig. 5 :

.1 Conflicts of Interest

The authors declare that they have no conflicts of interest.

- [Baimac et al. ()] ‘Bladder Pheochromocytoma: A 3-Year Follow-Up after Transurethral Resection (TURB)’. Casetta G Baimac , R Vella , A Tizzani . *Urol Int* 2000. 65 p. .
- [Singh et al. ()] ‘Calcified nonfunctional paraganglioma of the urinary bladder mistaken as bladder calculus: a diagnostic pitfall’. D V Singh , A Seth , N P Gupta , M Kumar . *BJU International* 2000. 85 p. .
- [Dahia ()] ‘Evolving concepts in pheochromocytomas and para-ganglioma’. P L Dahia . *Curr Opin Oncol* 2006. 18 p. .
- [Spessoto et al. ()] ‘Incidental Diagnosis of Nonfunctional Bladder Parag anglioma’. L C Spessoto , F A Vasilceac , T L Padilha , P F De Arruda , M Gatti , J G De Arruda . *Urol Case Rep* 2015. 4 p. .
- [Yadav et al. ()] ‘Malignant non-functional paraganglioma of the bladder presenting with azotemia’. R Yadav , A K Das , R Kumar . *Int Urol Nephrol* 2007. 39 p. .
- [Kovacs et al. ()] ‘Malignant paraganglioma of the urinary bladder: Immunohistochemical study of prognostic indicators’. K Kovacs , D Bell , G W Gardiner , R J Honey , J Goguen , F Rotondo . *Endocr Pathol* 2005. 16 p. .
- [Katiyar et al.] ‘Non-Functional Paraganglioma of the Urinary Bladder Treated by Transurethral Resection: Report of Two Cases’. R Katiyar , S Dwivedi , S Trivedi , S C Patne , U S Dwivedi . 2016: 10. *J Clin Diagn Res* (2) p. .
- [Lai et al.] ‘Non-functioning paraganglioma of the urinary bladder: A case report and review of the literature’. Y Lai , D Chen , Z Yu , L Ni , S Yang . *Oncol Lett* 2014 (3) p. .
- [Xu et al.] ‘Nonfunctional paraganglioma of the urinary bladder: a case report’. D F Xu , M Chen , Y S Liu , Y Gao , X G Cui . *J Med Case Rep* 2010 p. 216.
- [Gupta et al. ()] ‘Nonfunctioning paraganglioma of the urinary bladder: A rare entity’. V Gupta , J Sharma , A Sangwaiya , V Kaira , S Samal , R Sen . *Clin Cancer Investig J* 2015. 4 p. .
- [Melicow ()] ‘One hundred cases of pheochromocytoma (107 tumors) at the Columbia Presbyterian Medical Centre, 1926-1976: A clinicopathologic analysis’. M M Melicow . *Cancer* 1977. 40 p. .
- [Maddocks and Fagan ()] ‘Paraganglioma of bladder with recurrence ten years later’. R A Maddocks , W T Fagan Jr . *Urology* 1976. 7 p. .
- [Adraktas et al. ()] ‘Paraganglioma of the urinary bladder’. D Adraktas , M Caserta , H Tchelepi . *Ultrasound Q* 2014. 30 (3) p. .
- [Zhou et al. ()] ‘Paraganglioma of the urinary bladder: a lesion that may be misdiagnosed as urothelial carcinoma in transurethral resection specimens’. M Zhou , J I Epstein , R H Young . *Am J Surg Pathol* 2004. 28 p. .
- [Ghafoor et al.] ‘Paraganglioma of urinary bladder: an unusual presentation. pitfalls in diagnosis and treatment’. A U Ghafoor , I Yousaf , R Pervez , R U Khan , K Mir . *J Pak Med Assoc* 2012 (1) p. .
- [Pastor -Guzmán et al. ()] J M Pastor -Guzmán , S López -García , J M Giménez -Bachs , R Ruíz -Mondejar , L Cañamares -Pabolaza , M Atiénzar -Tobarra . *Paraganglioma of the bladder: controversy regarding treatment*, 2004. 73 p. .
- [Zimmerman et al. ()] ‘Pheochromocytoma of the urinary bladder’. I J Zimmerman , R E Biron , H E Macmahan . *N Engl J Med* 1953. 249 p. .
- [Thrasher et al. ()] ‘Pheochromocytoma of urinary bladder: contemporary methods of diagnosis and treatment options’. J B Thrasher , R R Rajan , L M Perez , P A Humphrey , E E Anderson . *Urology* 1993. (5) p. .
- [Manger et al.] ‘Pheochromocytoma: a clinical and experimental overview’. W M Manger , R W Gifford , Jr , B Hoffman . *Curr Probl Cancer* 1985 (5) p. .
- [Kontani et al. ()] ‘Recurrent granular cell tumour of the bladder in a patient with von Recklinghausen’s disease’. K Kontani , T Okaneya , T Takezaki . *BJU Int* 1999. 84 p. .