

Adenocarcinoma of Left Maxilla: Case Report (Clinico Radiologic, Pathologic Features and Management)

Dr. Anshuman Dwivedi

Received: 6 December 2017 Accepted: 4 January 2018 Published: 15 January 2018

Abstract

Very rarely malignant tumors of the nasal cavities and paranasal sinuses have been seen. The incidence is less than one percent of all tumors and less than three percent of head and neck tumors in which most common is the carcinoma of the maxillary sinus. In this, a case of adenocarcinoma with histopathology and treatment planning is discussed.

Index terms—

One of the most common malignant tumor in the salivary glands is Adenocarcinoma which accounts for less than 1% of all malignancies and for from 5% to 20% of all carcinomas in the sinonasal area. Few reports in the literature describes the diagnostic imaging findings of adenocarcinoma arising in the maxillary sinus. They are painful, fast-growing masses, but occasionally present as painless and slow-growing.

1 II. Case Report

A 48-year-old woman was referred to our hospital with the chief complain of swelling in the left upper facial region since 2-3 months. Patient did not give any positive history of any deleterious habit. On extra oral examination a soft, elastic mass of 29mm in diameter extending anteroposteriorly from the lower left eyelid till the inferior border of mandible and superoinferiorly extending from the left corner of mouth till the tragus of ear was seen. The overlying skin was normal as surrounding skin with a slight raise in temperature (Fig 1). On palpation the swelling was soft in consistency was compressible and tender. Patient also complained of the nasal congestion and left sub ocular tension. While palpating neck region a single lymph node of approx. 12mm in diameter was palpated at left level II region. On intra oral examination an ulcerative lesion was seen in the left maxillary arch region in relation to 27 28 with bluish discoloration around the ulcerative lesion. On checking the mobility status of 26 it was grade 3 mobile (The mass compressed the orbit base, but the orbit's contents were not affected. The maxillary tuberosity and the hard palate were destroyed. The CECT images also suggested that it was not a Squamous cell carcinoma but a malignant tumor.

After the radiological the biopsy was performed which revealed parakeratinized stratified squamous epithelium overlying fibrocellular connective tissue stroma. The epithelium showed dysplastic features such as increased N: C ratio, prominent intercellular junctions, prominent and increased number of nucleoli, mitotic figures. Focal areas of invasion in the form of discrete tumor islands are seen. The C.T. stroma shows solid tumor mass areas with variable organisations formed by large polygonal cells having pale to eosinophilic cytoplasm and nucleus ranging from hyperchromatic to vesicular. Tumor cells were also arranged in forms of sheets, clusters, pseudoductal patterns with secretory material. Few cells also showed individual cell keratinization, with numerous atypical mitotic figures. Tumor necrosis and perineural invasion was also observed and a diagnosis of Adenocarcinoma NOS (High grade) was given.

After the conformational biopsy report, surgical resection was done.

In the treatment tumors which have broad invasion into the maxillary sinus the Dieffenbach-Weber-Fergusson incision modified by Zange is used to perform a hemimaxillectomy (Fig ??). Before beginning the process of incision the area was marked and infiltrated with 1% xylocaine with 1 in 100,000 units adrenaline. After the incision cheek flap was elevated from the antero lateral surface of maxilla in the subperiosteal plane. Then dissection was slightly altered so that the involved skin overlying the anterolateral wall of maxilla was also removed en bloc along with the tumor. The lymph nodes upto level V were removed. Infra orbital floor defect was reconstructed by rotating temporalis muscle flap and facia lata graft was harvested (Fig 7).

1 II. CASE REPORT

47 The PNS view of the skull showed radiopacity in the left maxillary sinus, nasal cavity. The radiopacity was
48 also appreciated in the left orbit with absence of a left maxillary tuberosity line and the lower border of left orbit.
49 At this point, a malignant tumor was strongly suspected (Fig. ??).

50 After the basic radiographic examinations the patient was advised for the Contrast Enhanced Computed
51 Tomography (CECT). The coronal sections of CECT shows a well-defined hypodense lesion in the left maxillary
52 region extending into the left maxillary sinus, left nasal cavity and left orbit. The hypodense mass is also
53 infiltrating into the buccinators and the masseter muscle involving the massetric space. Massive destruction of
54 the alveolar bone, walls of maxillary sinus and inferior orbital wall can also be appreciated. (Fig ??). Tensor
55 fascia lata flap is a myofasciocutaneous flap that has been first described by Wangenstein in 1934 for abdominal
56 wall reconstruction. This flap started to gain popularity after further description by Nahai, et al., 1978 and 1979.
57 It has a significant role in the management of pressure sores, facial reanimation. Also, it has been used as a free
58 flap in head and Neck reconstruction. In our case fascia lata flap was used for the reconstruction of the infra
orbital floor.



1

Figure 1: Fig. 1 :

23

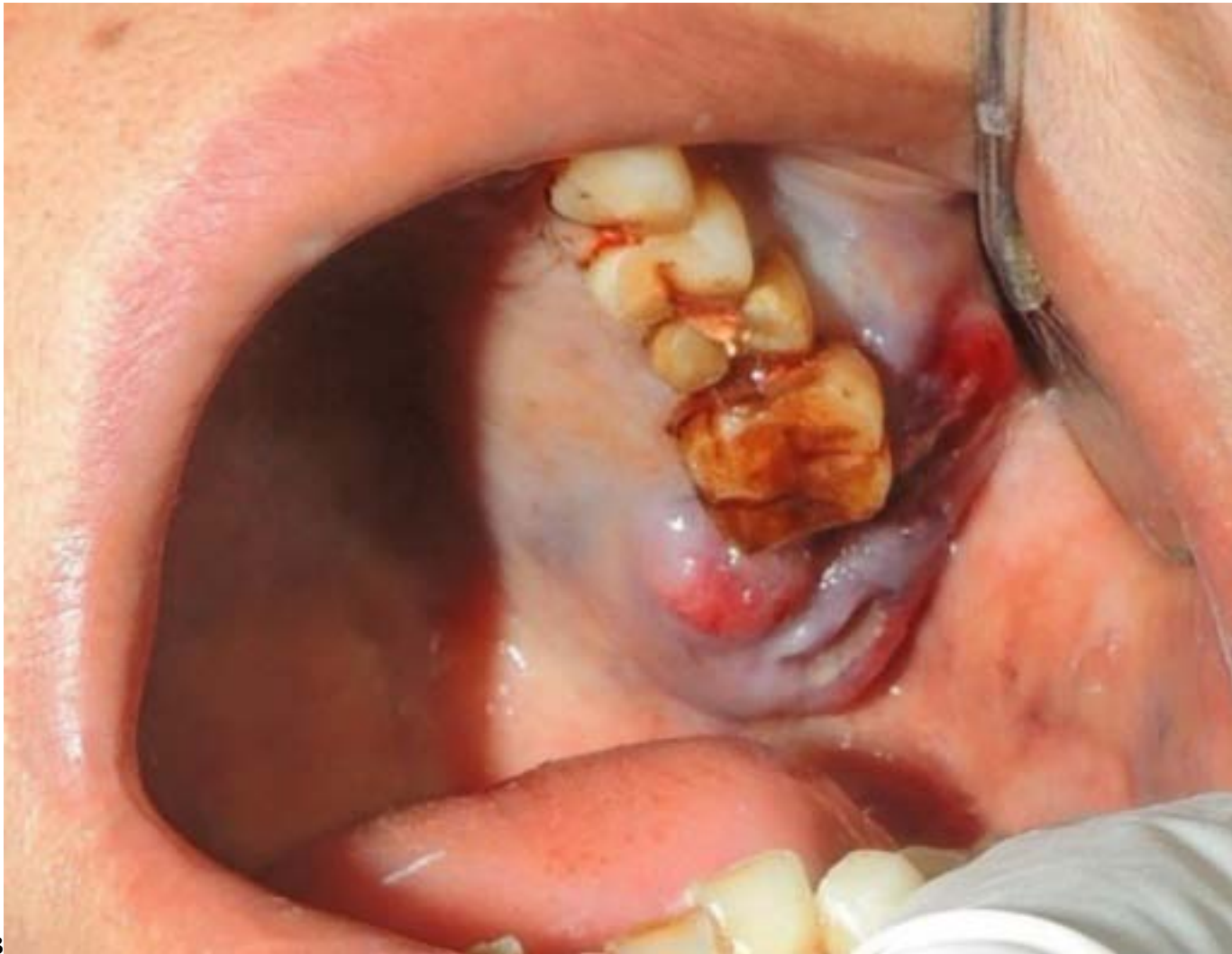

Figure 2: Fig. 2 :Fig. 3 :

456

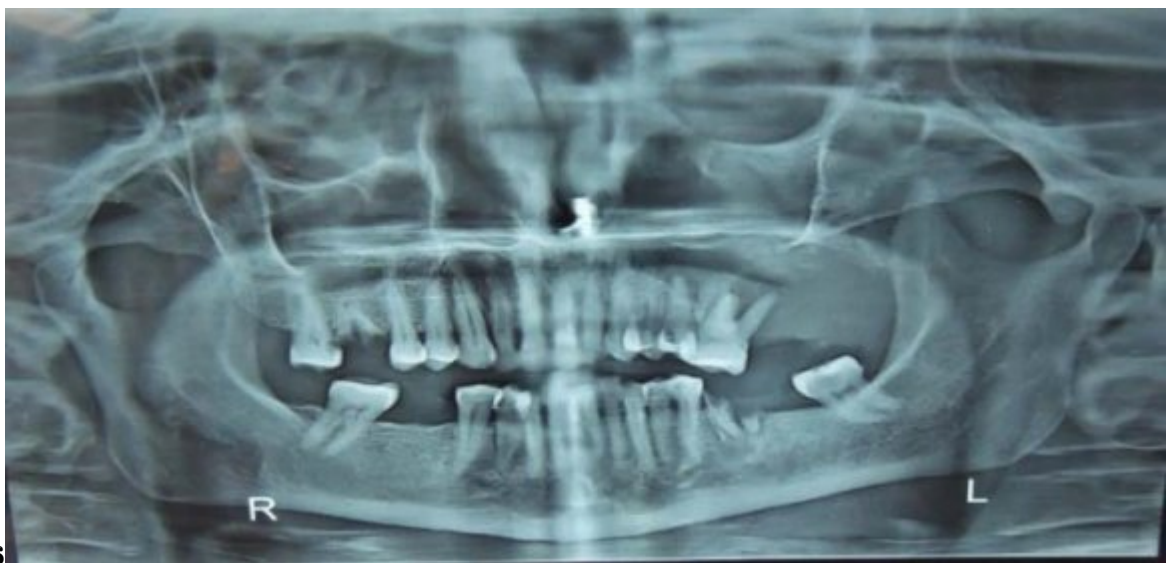

Figure 3: FigFig. 4 :Fig. 5 : 6 :

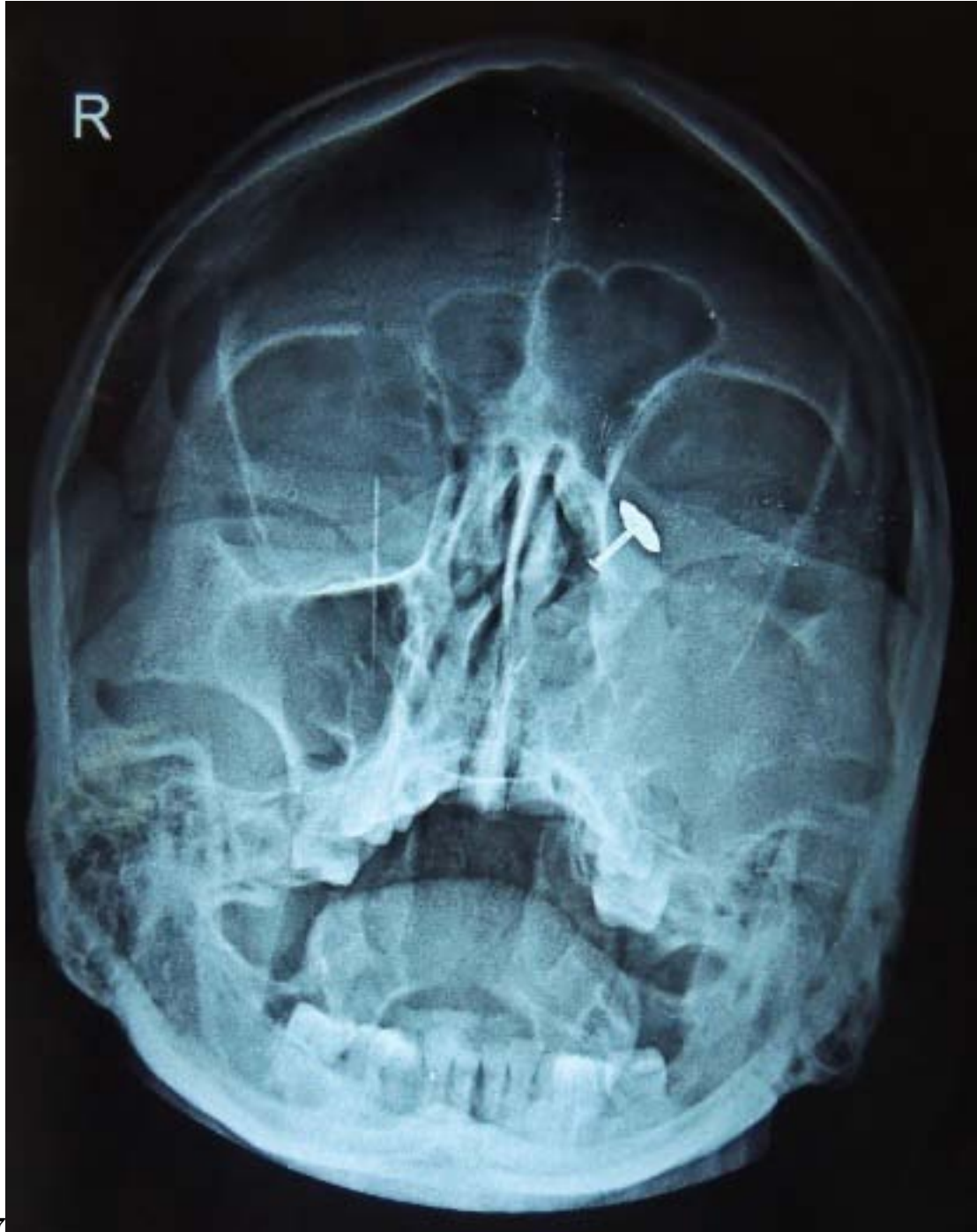


Figure 4: Fig. 7 :D

After reconstruction the closure was done and the sample was send to pathology department for further special stains. The submitted resected tissue specimen impression was compatible with the incisional diagnosis of Adenocarcinoma NOS (High Grade). Level I lymph nodes shows tumor cells infiltration. No tumor invasion was seen in the Anterior, Posterior, Medial, Lateral and Superior margins and Periorbital fatty tissue. And the final impression of Adenocarcinoma NOS (High Grade) was given.

1 III. Discussion

Third most common malignant tumor in the salivary glands is Adenocarcinoma which accounts for less than 1% of all malignancies and for from 5% to 20% of all carcinomas in the sinonasal area..They are painful, fast-growing masses, but occasionally present as painless and slow-growing. Classification of adenocarcinoma can be cytologic and architectural grades; grade I tumors are circumscribed and minimally invasive with mild pleomorphic features; grade III tumors are more solid, more pleomorphic, and have a greater mitotic rate; and grade II tumors lie between these two extremes. The present case falls in grade III. The stage and site of the tumor are important as they predict the patient survival rate. Treatment of choice always being Radical neck dissection, and the imaging characteristics were more in favor of a high-grade, cellular, infiltrating tumor.

In our case, the bone destruction was massive, considering that the tumor occupied the maxillary sinus, floor of orbit, left nasal cavity. These features are consistent with those of adenocarcinoma. This tumor was determined to be adenocarcinoma NOS, which means it does not belong to any pathological category, regardless of whether it is a malignant polymorphic adenoma or an adenoid cystic carcinoma.

Cancer of the maxilla can be a lethal disease, and its treatment often leaves the patient with marked functional and cosmetic deficits. Many different methods have been proposed for reconstructing these defects, which include a prosthetic obturator, temporalis l

[Gamoh et al. ()] ‘Adenocarcinoma in the maxillary sinus: a case report’. S Gamoh , N Kakimoto , J T K Ozono , C M Kishino , Y Uchiyama , S M Furukawa . *Oral Radiol* 2004. 20 p. .

[Strong ()] ‘Adenocarcinoma of salivary origin: clinicopathologic study of 204 patients’. SpiroR H , Huvos A G Strong , EW . *Am J Surg* 1982. 144 p. .

[Nahai et al. ()] ‘Experiences with the tensor fascia lata flap’. F Nahai , H L Hill , T R Hester . *Plast Reconstr Surg* 1979. 63 p. .

[Roth et al. ()] ‘Primary adenocarcinoma of the maxillary sinus simulating an osteosarcoma’. J Roth , P L Friedlander , E Palacios . 81:14. *Ear Nose Throat J* 2002.

[Sun et al. ()] ‘Reconstruction of high maxillectomy defects with the fibula osteomyocutaneous flap in combination with titanium mesh or a zygomatic implant’. J Sun , Y Shen , J Li , Z Zhang . *Plast Reconstr Surg* 2011. 127 p. .

[Auclair and Ellis (ed.) ()] *Surgical pathology of the salivary glands*, P L Auclair , G L Ellis . Ellis G, Auclair P, Gnepp D (ed.) 1991. Philadelphia, PA: WB Saunders. p. . (Adenocarcinoma not otherwise specified)

[Abubaker ()] ‘The temporalis muscle flap in reconstruction of intraoral defects: an appraisal of the technique’. A O Abubaker , Abouzgiam . *Oral Surg* 2002. 94 p. .

[Hill et al. ()] ‘The tensor fascia lata myocutaneous free flap’. H L Hill , F Nahai , L Vasconez . *Plast Reconstr Surg* 1978. 61 p. .