



GLOBAL JOURNAL OF MEDICAL RESEARCH: J  
DENTISTRY & OTOLARYNGOLOGY  
Volume 19 Issue 1 Version 1.0 Year 2019  
Type: Double Blind Peer Reviewed International Research Journal  
Publisher: Global Journals  
Online ISSN: 2249-4618 & Print ISSN: 0975-5888

## The Current Role of Woodman's Arytenoidectomy in Treating Bilateral Abductor Vocal Cord Palsy

By Satish Chandra T., Sudhakar Rao M., Sameera G., Satyanarayana MVN & Lavanya V.

*Dr. Pinnamaneni Institute of Medical Sciences and Research Foundation*

**Abstract-** Bilateral abductor vocal cord palsy is one of the most complex laryngeal condition which an otolaryngologist do encounter in their routine practice. Complexity because of the various etiological factors which can affect neurological component anywhere from cerebral cortex to superior mediastinum or local factors like cricoarytenoid fixation. The treatment option is to establish the airway without compromising the voice and lower airway protection from aspiration. Various surgical options have evolved in due course of time ranging from open procedures to laser endoscopic procedures.

**Objectives:** Evaluating the role external arytenoidectomy (woodman's) in the treatment of bilateral abductor vocal cord paralysis.

**Materials and methods:** It's a retrospective study including 15 cases of bilateral abductor vocal cord palsy of various etiologies varying from congenital to iatrogenic ones.

**Keywords:** bilateral abductor vocal cord palsy (bavcp), woodman's arytenoidectomy, laterofixation, vocal fold immobility.

**GJMR-J Classification:** NLMC Code: WV 530



*Strictly as per the compliance and regulations of:*



# The Current Role of Woodman's Arytenoidectomy in Treating Bilateral Abductor Vocal Cord Palsy

Satish Chandra T. <sup>α</sup>, Sudhakar Rao M. <sup>σ</sup>, Sameera G. <sup>ρ</sup>, Satyanarayana MVN <sup>ω</sup> & Lavanya V. <sup>¥</sup>

**Abstract-** Bilateral abductor vocal cord palsy is one of the most complex laryngeal condition which an otolaryngologist do encounter in their routine practice. Complexity because of the various etiological factors which can affect neurological component anywhere from cerebral cortex to superior mediastinum or local factors like cricoarytenoid fixation. The treatment option is to establish the airway without compromising the voice and lower airway protection from aspiration. Various surgical options have evolved in due course of time ranging from open procedures to laser endoscopic procedures.

**Objectives:** Evaluating the role external arytenoidectomy (woodman's) in the treatment of bilateral abductor vocal cord paralysis.

**Materials and methods:** It's a retrospective study including 15 cases of bilateral abductor vocal cord palsy of various etiologies varying from congenital to iatrogenic ones.

**Results:** Study included 8 cases of iatrogenic, 4 cases of pediatric (congenital), and 3 cases of idiopathic bilateral vocal cord paralysis. All the patients were treated by external woodman's arytenoidectomy with successful decannulation. All the patients are followed for a period of 2 years with excellent outcome.

**Conclusion:** Woodman's arytenoidectomy with laterofixation of vocal cord is equally effective procedure for treating bilateral abductor vocal cord palsy when compared with endoscopic procedures.

**Keywords:** bilateral abductor vocal cord palsy (bavcp), woodman's arytenoidectomy, laterofixation, vocal fold immobility.

## 1. INTRODUCTION

Vocal fold immobility is the term that describes restricted movement of vocal folds secondary to mechanical fixation or neurological involvement. Mobility of the vocal folds may be decreased or absent, and it may be unilateral or bilateral. From the standpoint of the etiology, choice of treatment, and prognosis, it is important to differentiate between hypomobility and immobility, as well as unilateral or bilateral involvement<sup>1</sup>.

**Author α:** MS ENT Professor, Department of ENT and Head & Neck surgery, Dr. pinnamanenisidhartha institute of medical sciences & research foundation, Chinnaoutpalli, gannavaram, Krishna dist, Andhra Pradesh. e-mail: sctripuraneni@yahoo.com

**Author σ:** MS, ENT Associate professor, Department of ENT and Head & Neck surgery.

**Author ρ ω ¥:** Senior resident. e-mails: sameera.gera@gmail.com, nv.chanti@gmail.com, lavanya.viswanadham@gmail.com

Bilateral abductor palsy of vocal cords results from either damage to the recurrent laryngeal nerves of both sides or fixation of bilateral cricoarytenoid joints. Dysfunction of recurrent laryngeal nerves may result from either trauma to the nerve or any mass affecting the nerve in the neck or mediastinum or even lesions in the floor of the 4<sup>th</sup> ventricle or brainstem (congenital or acquired) which can affect the both vagal nuclei. However, in many cases no definite cause can be found and these are described as idiopathic.

The patients with bilateral abductor cord palsy usually present with breathing difficulties either with stridor or partial difficulty in breathing as both the cords tend to lie in median or paramedian position. These patients do not have any problem with their voice or aspiration. Some of these patients need immediate surgical intervention due to acute respiratory insufficiency. Other patients can bear light to moderate dyspnea for a long period with no need of therapy.

Tracheostomy can solve dyspnea problems, by sustaining good tone and air passages protection, although it is not well accepted by many patients as long-term solution. Therapeutic procedures in these cases are challenging for the otolaryngologist as it requires to establish the laryngeal airway, without disturbing the sphincteric function of the larynx and preserving quality of voice.

A number of surgical procedures have been described for improvement of the compromised airway in bilateral abductor palsy. Jackson<sup>2</sup>, in 1922, suggested ventriculocordectomy technique through external approach. In 1946, Woodman<sup>3</sup> suggested arytenoidectomy through extralaryngeal approach along with suturing of the vocal process to inferior horn of thyroid cartilage. Endolaryngeal accesses were introduced in 1948 by Thornell<sup>4</sup>, who proposed arytenoidectomy with electric cautery. Arytenoidectomy and posterior cordotomy performed using CO<sub>2</sub> laser was introduced by Ossoff et al <sup>5, 6</sup> and by Dennis and Kashima<sup>7</sup>.

Current study is a retrospective study of 15 patients of bavcp with various etiologies who were treated with tracheostomy followed by woodman's procedure. All the patients were evaluated for the time taken for successful decannulation of tracheostomy and

range of change in pitch of their voice and recurrence over a period of 2 years.

## II. MATERIALS AND METHODS

This is the retrospective study, which included 15 patients from 2013 to 2015. These are the patients who presented to our department directly or referred by other departments with history of stridor or breathing difficulty. The patients with bilateral abductor vocal cord palsy secondary to malignancy were excluded (like esophageal, mediastinal mass, thyroid) from the study. Only the patients who were proven to be idiopathic & secondary to iatrogenic etiology and without any underlying progressive disease were included in our study. All the 7 patients who presented without any iatrogenic history are thoroughly investigated from skull base to mediastinum to rule out all the probable etiologies. The investigatory protocol included CT scan from skull base to mediastinum, upper GI scopey, chest x-ray. In pediatric patients to rule out intracranial pathologies MRI was done.

The treatment protocol we adopted is primary tracheostomy followed by external arytenoidectomy (Woodman's) and decannulation starting from 4<sup>th</sup> post-operative day. Woodman<sup>3</sup> in 1946, introduced this technique which is still popular till date. He concluded that a satisfactory airway and a fair voice can be preserved when the posterior commissure is between 4-6 mm.

### a) Procedure

Under general anesthesia, tracheostomy done if prior tracheostomy is not there,

- A Vertical incision is given parallel to anterior border of sternocleidomastoid muscle from the level of the upper border of thyroid cartilage to lower border of cricoid cartilage.
- Platysma muscle is incised.
- Strap muscles separated, if required omohyoid is divided.
- Larynx is tilted anteriorly by retracting the thyroid cartilage.
- Inferior constrictor muscle has been separated from thyroid cartilage along with perichondrium.
- If required removed a small portion of posterior part of thyroid cartilage.
- Cricoid cartilage is identified and followed posteriorly.
- After dislocating cricothyroid joint, the posterior and lateral cricoarytenoid muscles are then detached from muscular process of arytenoid cartilage. Arytenoid is resected leaving a small piece if vocal process behind.
- The vocal process of arytenoid was exposed and sutured to thyroid ala.

- The final degree of tightening of this suture is determined by direct laryngoscopy.
- Wound closure done in layers.

Postoperatively the patients were followed with video laryngoscopy. Waited till the surgical edema subsided before planning for decannulation from 4<sup>th</sup> day onwards.

### b) Results

Current series included 15 patients, age ranging from 3-60 yrs.

Table 1

Age	
2-10	3
10-25	2
25-50	6
>50	4

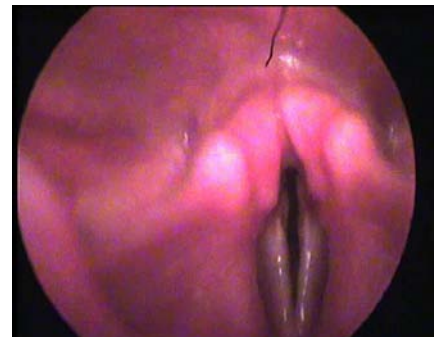
The youngest patient in our study was 3 years girl baby presented with h/o noisy breathing since birth worsening during upper respiratory tract infections, one of such episode led to sever stridor and referred to us by our pediatric department. Two of the pediatric patients also underwent one or more instances of intubation for the same complaint.

Etiological factors include iatrogenic in 8 and idiopathic in 7 shown in table 2.

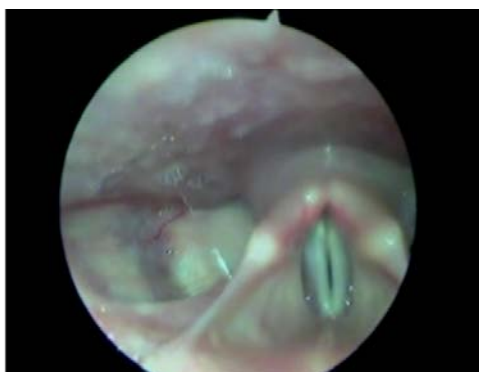Table 2

Etiology	
Congenital/idiopathic	4
Iatrogenic	8
Cns /idiopathic	3

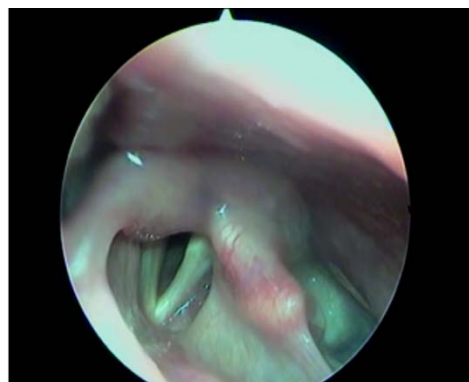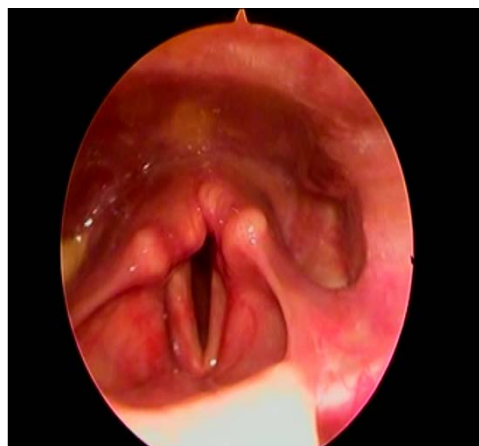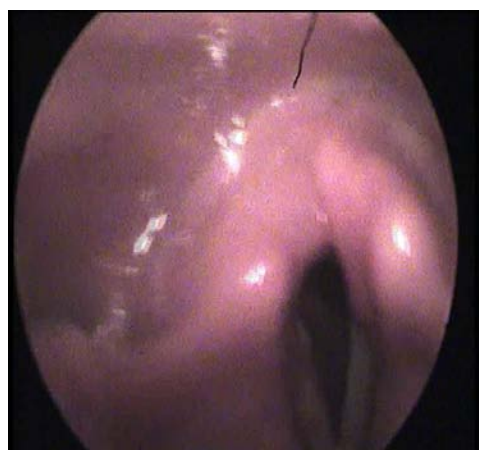
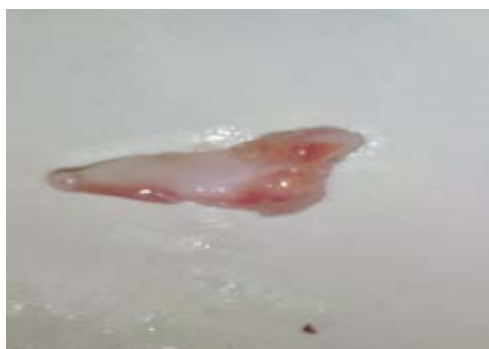Most of the patients in pediatric age group are with idiopathic etiology, even after thorough investigation we couldn't find out any pathology. Among all 15 patients, 7 of them are presented with severe stridor who immediately underwent emergency tracheostomy. Rest all the 8 patients presented with nocturnal snoring and dyspnea on exertion.



Picture 1: Pre-openscopic images



Picture 2: Arytenoid specimen



Picture 3: Post op images

### III. RESULTS

We were able to decannulate all the patients from tracheostomy as early as 4<sup>th</sup> to 7<sup>th</sup> day with acceptable voice. Out of all the 15 patients, 2 patients complained mild aspiration starting from 4<sup>th</sup> day in immediate post op period which eventually subsided on its own over next few days with swallowing therapy. Those 2 patients developed bavcp secondary to the total thyroidectomy.

All the patients are followed for more than 2 years. None of them have any recurrent symptoms and relatively with better voice quality. None of them showed any cicatricial contraction with obvious success rate of 100%.

### IV. DISCUSSION

Bilateral abductor vocal cord paralysis increases the airway resistance leading to persistent dyspnea because the median or paramedian position of the vocal cords. Final positioning of the vocal cords is dependent on the activity of the cricothyroid muscle, condition of the denervated vocalis muscle, condition of the cricoarytenoid joint, change in the epithelium of the vocal folds in an attempt to adapt to the compromised air way.<sup>10</sup>

Aim of the treatment of bilateral abductor vocal cord palsy is to relieve the obstruction either by bypassing or widening the narrow area. At the same time preserving the voice and preventing the aspiration are also important. Tracheostomy being the life saving procedure may not be the final option as most of them don't want lifelong tracheostomy. Wide range of surgical options available to achieve this.

No operation should be attempted until at least 2 months after onset of paralysis, where etiology of the paralysis is known thus allowing for possibility of any spontaneous recovery.<sup>8</sup> The technique for increasing the airway caliber involves lateralization of one vocal fold/removal of tissue from posterior glottis. Work by Hirano and colleagues has shown that the posterior glottis accounts for 50-65% area of the total glottis and



thus enlarging the posterior glottis, has a greater effect on the airway while preserving the voice quality.<sup>8</sup>

Woodman in 1946 introduced the technique of extra laryngeal approach for the excision of arytenoid along with laterofixation of vocal cord to the inferior cornu of thyroid cartilage. He stated in his article that a satisfactory airway along with good voice can be achieved with a gap of 4 to 6mm in posterior commissure.<sup>3</sup>

In the current study we performed woodman's procedure in 15 patients with successful decannulation in all the patients with a span of 4 to 9 days. Excision of the arytenoid with lateralization of the same cord by pulling it laterally, by placing a stitch from vocal process to thyroid cartilage, under direct visualization of the glottis with direct laryngoscopy, to secure the desired lateral position of the cord is the key to the successes. We made sure mucosa was not traumatized while doing the procedure. Prabir Kumar Mondal in their study of surgical management of Bilateral abductor paralysis by extra laryngeal approach had similar results.<sup>8</sup>

Brigger and Hartnick in their stated that "open" procedures seem to be the most effective primary treatment for bilateral VCP in children. Both external arytenoidopexy and external arytenoidectomy demonstrated similar operation specific decannulation rates. Minimally invasive or endoscopic CO2 laser arytenoidectomies performed as a primary intervention do not appear to be as efficacious as "open" procedures as a primary intervention.<sup>9</sup> It has been postulated that one reason for decreased efficacy of CO2 laser ablation within the pediatric larynx is the smaller scale of the anatomic landmarks and obstruction of the posterior glottis by a flaccid aryepiglottic fold.<sup>11</sup>

In the current study we did Woodman's procedure in 4 pediatric patients, youngest being 3 yrs. We were able to decannulate all of them with acceptable voice. Mucosal sparing external procedures have an advantage over the intraluminal mucosal handling procedures in pediatric patients as the later always has a chance of fibrosis, contractures and probability of posterior glottic stenosis. Removal of the arytenoid and fixing the cord laterally without traumatizing the laryngeal mucosa especially interarytenoid area always holds good for pediatric patients.

Complications like perichondritis of the arytenoids, granuloma formation, explosion burns by laser are less with Woodman's procedure.

## V. CONCLUSION

Bilateral abductor palsy of vocal cords is a life-threatening condition. Wide ranges of surgical procedures are evolved over a period of time. Endoscopic laser posterior cordotomy or Kashima's surgery is considered to be the choice of treatment for bilateral vocal cord palsy. Woodman's procedure is one

of the oldest procedure initially reported way back 1946. Even though this is an external approach in experienced hands can be very successful one as it allows the surgeon to control the degree of lateralization of the cord intraoperatively under vision, and the problems of adverse glottic scarring can be avoided.<sup>10</sup>

## REFERENCES RÉFÉRENCES REFERENCIAS

1. Rosenthal L H, Benninger M S, Deeb R H. Vocal fold immobility: a longitudinal analysis of etiology over 20 years. *Laryngoscope*. 2007; 117(10): 1864-70.
2. Jackson C. Ventriculocordectomy, a new operation for the cure of goitrous glottic stenosis. *Arch Surg*. 1922, 4: 257-74.
3. Woodman D. A modification of the extralaryngeal approach to arytenoidectomy for bilateral abductor paralysis. *Arch Otolaryngol*. 1946, 43:63-5.
4. Thornell W C. Intralaryngeal approach for arytenoidectomy in bilateral abductor vocal cord paralysis. *Arch Otolaryngol*. 1948. 47: 505-508.
5. Ossoff R H et al. Endoscopy laser arytenoidectomy for the treatment of bilateral vocal cord paralysis. *aryngoscope*.1984, 94: 1293-1297.
6. Ossoff R H et al. Endoscopy laser arytenoidectomy revisited. *Ann Otol Rhinol Laryngol*. 1990, 99: 764-771.
7. Dennis D P, Kashima H. Carbon dioxide laser posterior cordotomy for treatment of bilateral vocal cord paralysis. *Ann Otol Rhinol Laryngol*. 1989, 98: 930-934.
8. Prabir Kumar Mondal et al. Surgical management of bilateral abductor paralysis by extralaryngeal approach. *Indian Journal of Otolaryngology and Head and Neck Surgery* 2005; 57: 75-77.
9. Brigger and Hartnick et al. Surgery for pediatric vocal cord paralysis: A meta-analysis. *Otolaryngology– Head and Neck Surgery* 2002, 126: 349-355
10. Shetty S C, Prasad D. Woodmans operation for bilateral vocal cord para1ysis- our experience. *Ind J Otol Head Neck Surg*1998; 50: 241.
11. De Gaudemar I, Roudaire M, Francois M, et al. Outcome of laryngeal paralysis in neonates: a long term retrospective study of 113 cases. *Int J Pediatr Otorhinolaryngol*1996; 34: 101-10.