



GLOBAL JOURNAL OF MEDICAL RESEARCH: H  
ORTHOPEDIC AND MUSCULOSKELETAL SYSTEM  
Volume 19 Issue 2 Version 1.0 Year 2019  
Type: Double Blind Peer Reviewed International Research Journal  
Publisher: Global Journals  
Online ISSN: 2249-4618 & Print ISSN: 0975-5888

# Bilateral Atypical Femoral Fractures after Prolonged Bisphosphonate Therapy: A Case Report and New Approach to the Management of Iatrogenic Fractures

By Joseph Maalouly M.D., Dany Aouad M.D., Murielle Feghaly, Cynthia Habib  
& Georges El-Rassi M.D.

*Balamand University*

**Abstract-** Atypical femoral fractures (AFFs) are defined as atraumatic fractures of the femoral diaphysis and are known to be a complication of prolonged bisphosphonate (BP) therapy. Surgical treatment of AFFs consists of intramedullary (IM) nailing. We report the case of a 58-year-old female patient who presented with bilateral femoral fractures after 12 years of BP therapy. Surgical management using IM nails resulted in iatrogenic fractures of the femoral shaft in both limbs. We therefore, opted for conservative treatment, where a non-weight bearing protocol was implemented. Healing was then observed after six months of follow-up.

**Keywords:** atypical femoral fractures, bisphosphonate, alendronate, ibandronate, osteoporosis.

**GJMR-H Classification:** NLMC Code: WI 965, WE 185



*Strictly as per the compliance and regulations of:*



# Bilateral Atypical Femoral Fractures after Prolonged Bisphosphonate Therapy: A Case Report and New Approach to the Management of Iatrogenic Fractures

Joseph Maalouly<sup>α</sup> M.D., Dany Aouad<sup>σ</sup> M.D., Murielle Feghaly<sup>ρ</sup>, Cynthia Habib<sup>ω</sup> & Georges El-Rassi<sup>ξ</sup> M.D

**Abstract-** Atypical femoral fractures (AFFs) are defined as atraumatic fractures of the femoral diaphysis and are known to be a complication of prolonged bisphosphonate (BP) therapy. Surgical treatment of AFFs consists of intramedullary (IM) nailing. We report the case of a 58-year-old female patient who presented with bilateral femoral fractures after 12 years of BP therapy. Surgical management using IM nails resulted in iatrogenic fractures of the femoral shaft in both limbs. We therefore, opted for conservative treatment, where a non-weight bearing protocol was implemented. Healing was then observed after six months of follow-up.

**Keywords:** atypical femoral fractures, bisphosphonate, alendronate, ibandronate, osteoporosis.

## I. BACKGROUND

Atypical femoral fractures (AFFs) are a newly defined concept. After the emergence of several cases that linked the prolonged bisphosphonates (BP) use to atypical femoral fractures<sup>(1,2,3)</sup>, the American Society of Bone and Mineral Research (ASBMR) appointed a multidisciplinary team of experts to define AFFs<sup>(4)</sup>. AFFs were defined as low-intensity or atraumatic fractures of the femoral diaphysis, meeting at least four of the five major features described by the 2013 ASBMR task force<sup>(5)</sup>. These features were dependent on the mechanism of occurrence of the fracture (should be atraumatic or with minimal trauma), the location (fracture should be transverse, originating from the lateral cortex), the classification (non or minimally comminuted), and the radiological description (fracture site showing evidence of endosteal or periosteal thickening). The major features also discerned complete fractures that extended through the two bone cortices and were found to be associated with a medial spike from incomplete fractures that only involved the lateral cortex.

**Author α ξ:** Department of Orthopedic Surgery and Traumatology, Saint Georges University Medical Center, Balamand University, P.O.Box 166378, Achrafieh, Beirut, 1100 2807, Lebanon.  
e-mail: dany\_aouad@hotmail.com

**Author ρ ω:** Faculty of Medicine, Saint Georges University Medical Center, Balamand University, P.O.Box 166378, Achrafieh, Beirut, 1100 2807, Lebanon.

There are very few studies, most with small samples<sup>(6,7,8,9,10)</sup> that have examined different surgical options for the management of AFFs. Most authors agree that IM nailing is the best treatment option. For instance, Das De et al.<sup>(7)</sup> recommended fixation with a full-length intramedullary (IM) nail and partial to full weight-bearing post-op for the management of diaphyseal fractures of the femur. Other studies opted for extramedullary devices and post-op wheelchair mobilization or partial weight-bearing<sup>(10)</sup> for the management of AFFs. These studies<sup>(8,10)</sup> report complication rates up to 63%<sup>(10)</sup> with the main complications being the need for revision surgery, implant failure or need for bone grafting.

In the absence of set recommendations and guidelines for the management of AFFs, we report a case of bilateral AFFs treated by IM nailing. This case was, however, complicated by iatrogenic bilateral femoral shaft fractures which were managed by a more conservative approach: non-weight bearing protocol with regular follow-ups and assessment.

## II. CASE REPORT

A 58-year-old postmenopausal female patient presented to our clinic complaining of a one-year history of bilateral thigh pain that was persistent and more pronounced on the right. The patient denied any history of trauma or fall. She reported having severe osteoporosis for which she had taken alendronate for ten years followed by ibandronate for the last two years. Her history is also significant for hypertension and dyslipidemia.

X-rays done following her visit showed evidence of bilateral, non-displaced, mid-diaphyseal femoral fractures with cortical thickening (Fig.1). After stopping ibandronate, a plan for separate IM nailing of the fractures was set, starting with the right side then followed by the left.

During the right femoral shaft fracture repair, the patient was placed on an orthopedic traction table. Preparation of insertion site over greater trochanter after which a guidewire was inserted, followed by reaming. Then an IM nail of 12mm in diameter, without

complications, was inserted in the medullary canal with the help of a hammer. During the insertion of the nail, a trochanteric fracture was noticed. Distal locking was obtained by using two 4 mm screws, which were prepared by 3.5mm drilling. Upon their insertion we noticed the occurrence of an iatrogenic fracture in the femur. X-ray imaging by C-arm of the right femur done post-op revealed that iatrogenic fracture had occurred, involving the proximal third of the shaft and the lower half of the anterior cortex of the greater trochanter (Fig. 2). We opted for a nonoperative treatment because we believe that any surgical treatment may result in more devascularization. The patient was discharged home after a short and uncomplicated post-op stay on a supportive, non-weight bearing protocol and a follow-up every three weeks with serial X-rays. Partial weight bearing at four months post-op was initiated after the patient became pain-free.

After six months of follow-up (Fig. 3), the patient showed significant clinical improvement, and imaging showed complete healing of the fractures.

After allowing an adequate recovery period, the patient was re-admitted for the management of her left femoral fracture. IM gamma nail was inserted with proximal fixation with a cephalomedullary screw. Distal fixation using two 4 mm screws was attempted, but the left femur showed evidence of iatrogenic fractures upon insertion of the screws (Fig.4). We used a 3.2mm drill to insert the 4 mm screws. The same protocol was followed again, with the patient discharged on a supportive, non-weight bearing protocol and a scheduled follow-up every three weeks. After five months of follow-up, the patient exhibited significant clinical improvement with return to normal activity and was pain-free. At six months follow up imaging showed complete healing of the fractures (Fig.5).

### III. DISCUSSION

In this study, we report a case of bilateral AFFs after prolonged BP use complicated by iatrogenic bilateral femoral shaft fractures upon IM nail insertion. These fractures were managed conservatively by putting the patient on non-weight bearing protocol with follow up imaging and assessment every three weeks. The physiopathology of AFF after BP use is well described in the literature.

After BP use, femoral diaphyseal AFF is the most common. BP reduces the dissolution of hydroxyapatite, resulting in inhibition of osteoclasts and inhibiting bone resorption<sup>(11)</sup>. As a result, accumulation of micro-damage occurs<sup>(12)</sup> and the maturation of collagen is prevented<sup>(13)</sup>. They have also been reported to increase mineralization<sup>(14,15)</sup> and increase advanced glycated end-products<sup>(16)</sup>.

The recommended surgical approach is IM nailing<sup>(7,17,18)</sup> while other approaches include

extramedullary devices<sup>(10)</sup> have been reported. Kharwadkar et. al. reported that fractures managed with IM nailing achieved better healing since they heal by endochondral ossification while extramedullary approaches such as the use of plate and screws would result in delayed healing especially due to their placement on the lateral side of the femoral shaft which would result in the absence of load sharing<sup>(18)</sup>. Similarly, Lee K.J et al. reported that IM nailing of AFFs resulted in a complete bony union in 95.7% of their cases with only two patients requiring revision surgery<sup>(18)</sup>.

We report the case of a 58y.o female patient that presented with bilateral femoral fractures, consecutive management of the fractures by IM nailing starting with the right side followed by the left was performed. On the right, we had a fracture which is unusual to happen in the normal population since the standard technique has been used. Possibly, in a similar patient we should over-ream and medialize the insertion of the nail. Then, the nail should be inserted without the aid of a hammer.

On the left side, the distal locking 4 mm screw was placed in the static hole which was drilled with a 3.2 mm mesh. Perhaps the diameter of the drill was not big enough; maybe tapering should have been used. A 100% concentric drilling that may create more stress than usual during insertion.

In both cases, we have to introduce carefully the nail and screws with proper positions, drilling, tapering, and sizing.

In the absence of recommendations around the management of iatrogenic fractures in BP exposed bones, a non-weight bearing protocol was opted for, with patient assessment and follow up with imaging every two weeks was attempted. The decision to not re-operate was based on the fact that the healing process would have already started. Present literature shows evidence of delayed healing in BP users, as BP has been shown to delay the remodeling of the calcified cartilage callus formed during the initial phases of healing to mature bone<sup>(19)</sup>. Therefore, we relied on the natural healing process and patient cooperation with minimal activity and non-weight bearing. After six months from the first fracture and six months from the second, radiological and clinical evaluation showed, indeed, evidence of complete healing. For instance, Thompson et al. reported that 22 patients with 24 fractures required on average six months to achieve union of the fractures with two patients needing one year to achieve full union after surgical repair<sup>(20)</sup>. Likewise, in a study conducted by Lee et al. <sup>(18)</sup>, of the 46 femoral fractures included in the study, only 63% healed within six months with the rest necessitating up to 12 months for complete recovery.

#### IV. CONCLUSION

We report a case of bilateral iatrogenic femoral shaft fractures upon IM nailing for the management of bilateral AFFs after prolonged exposure to BP. After opting for a conservative approach, these fractures showed evidence of complete radiologic and clinical healing within six months on the right side and six months on the left side similar to previous studies which reported an average of six to 12 months to achieve fracture healing. Based on this case and previous literature, surgical management of AFFs with IM gamma

nailing with cephalomedullary nailing for proximal fixation and two transverse screws for distal fixation is preferred. Since BP render bones very fragile, reaming to measures beyond those used for normal bones should be done to avoid iatrogenic fractures. Also, patients, as well as physicians, should be made aware of the possibility of occurrence of AFFs as a complication of prolonged use of BP and the presence of alternative choices such as calcium and vitamin D or teriparatides for the long-term management of osteoporosis.

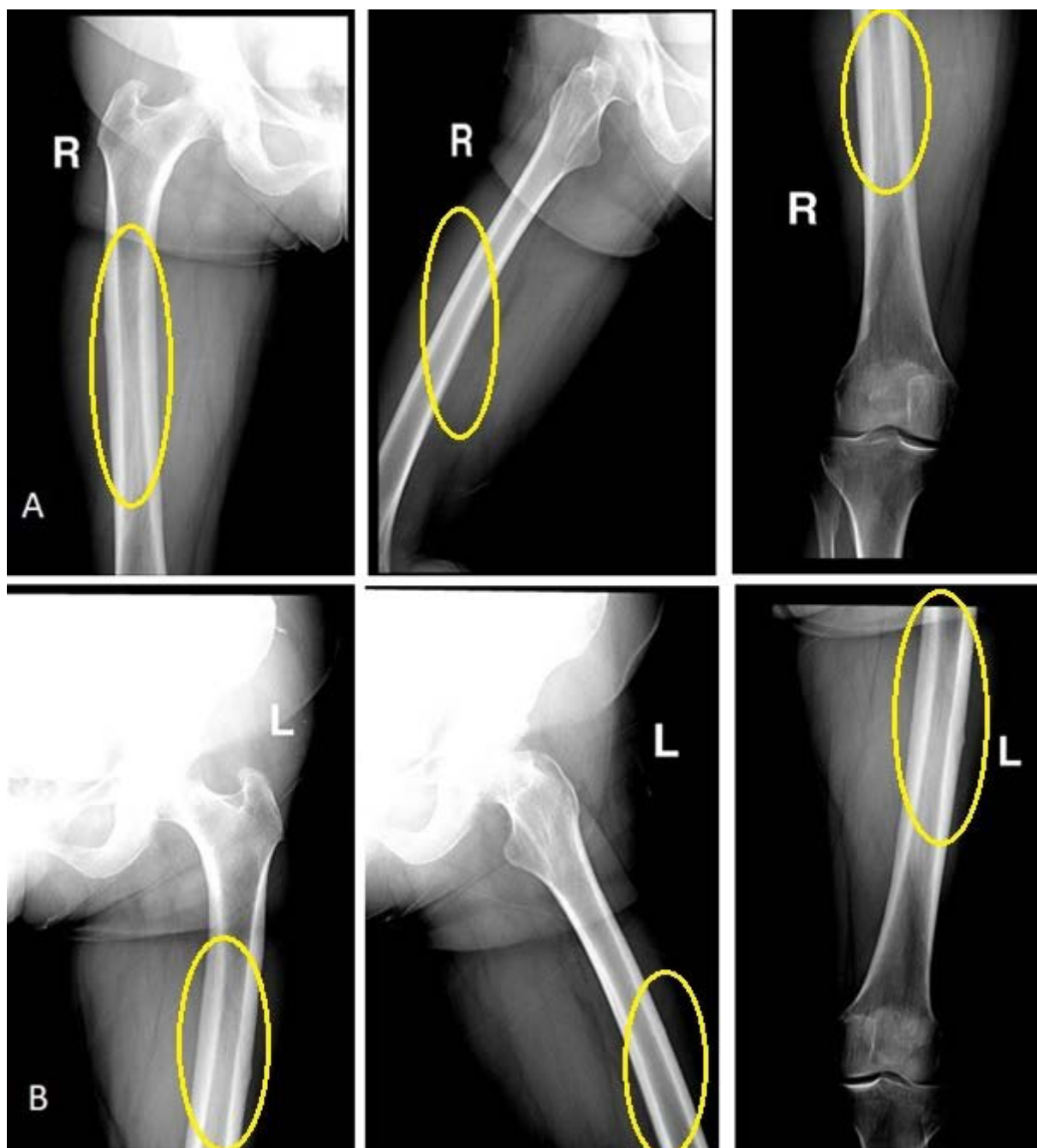


Figure 1: A 58-year-old female patient presenting with bilateral femoral fractures; A: Right femur, B: Left femur

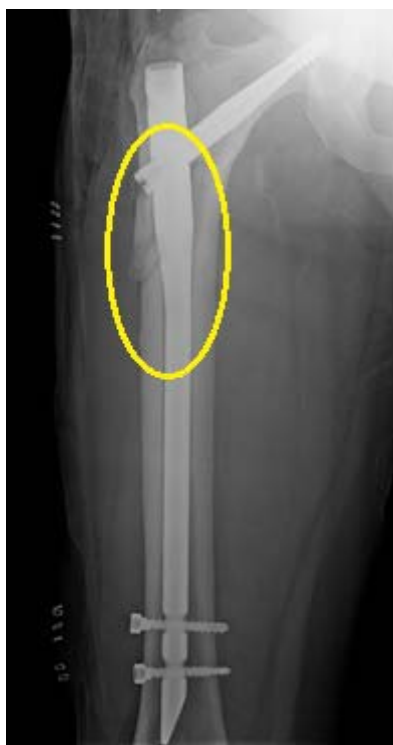

Figure 2: X-ray of the right femur on day 0 post-op showing an iatrogenic fracture of the proximal third of the femoral shaft

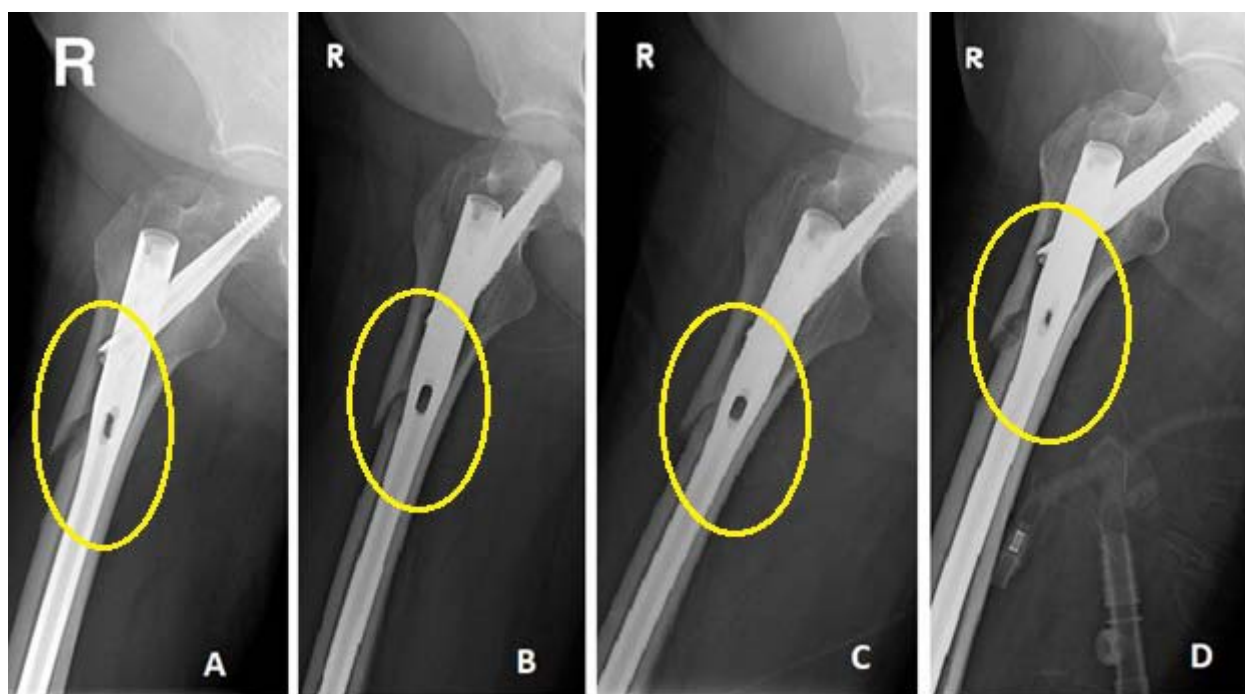


Figure 3: X rays of the right femur; A: week 3, B: week 6, C: week 12, D: week 15.



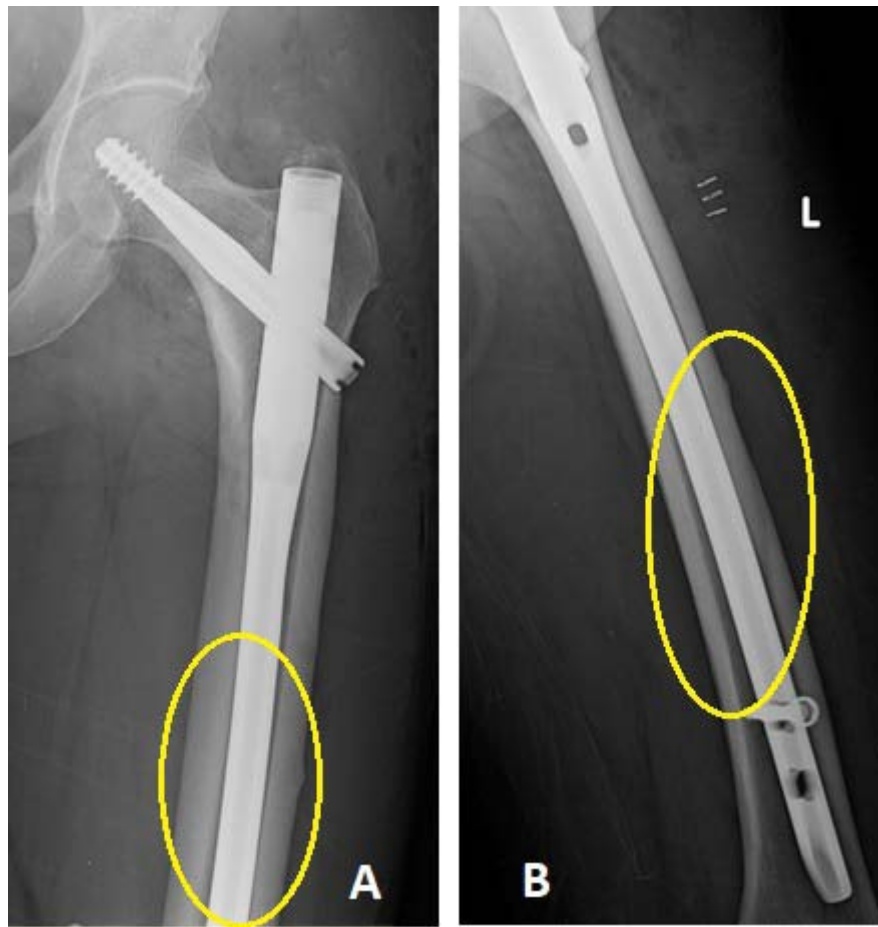

Figure 4: A, B: X rays of the left femur on day 0 post-op showing an iatrogenic fracture of the distal third of the femoral shaft

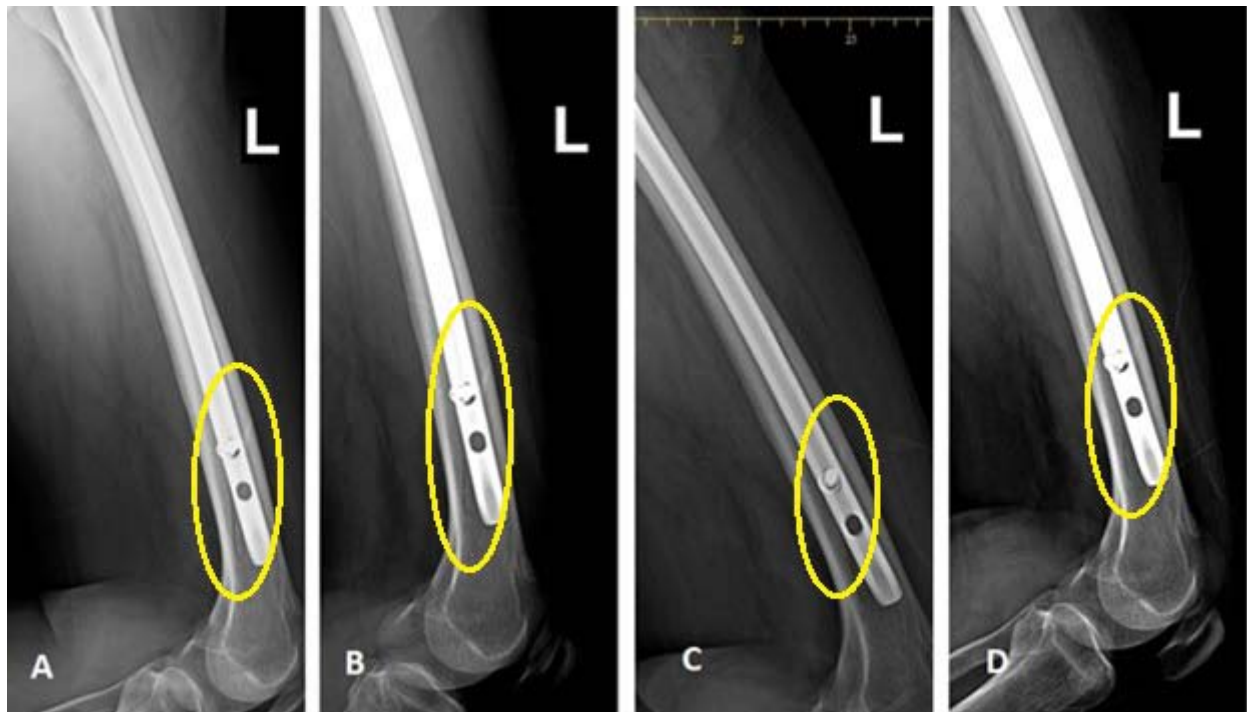

Figure 5: X rays of the left femur; A: week 6, B: week 10, C: week 16, D: week 23.

## REFERENCES RÉFÉRENCES REFERENCIAS

1. Ing-Lorenzini K, Desmeules J, Plachta O, Suva D, Dayer P, Peter R. Low-energy femoral fractures associated with the long-term use of bisphosphonates: a case series from a Swiss university hospital. *Drug Safety*. 2009;32:775–785.
2. Sayed-Noor AS, Sjöden GO. Case reports: two femoral insufficiency fractures after long-term alendronate therapy. *Clin Orthop Relat Res*. 2009;467(7):1921–6.
3. Capeci CM, Tejawani NC. Bilateral low-energy simultaneous or sequential femoral fractures in patients on long-term alendronate therapy. *J Bone Joint Surg [Am]* 2009;91-A:2556–2561.
4. Shane E, Burr D, Ebeling PR, et al; American Society for Bone and Mineral Research. Atypical subtrochanteric and diaphyseal femoral fractures: report of a task force of the American Society for Bone. *J Bone Miner Res* 2010;25:2267–2294. DOI: 10.1002/jbmr.253
5. Shane E, Burr D, Abrahamsen B, et al: Atypical subtrochanteric and diaphyseal femoral fractures: Second report of a task force of the American Society for Bone and Mineral Research. *J Bone Miner Res* 2014;29(1):1–23
6. Rocos B, Fleming T, Harding K, Acharya M, Riddick A, Kelly M. A Case Series and Discussion on Surgical Treatment Strategy for Atypical Proximal Femoral Fractures Associated with Bisphosphonate Use. *Cureus*. 2018 ;10(12), e3670. doi:10.7759/cureus.3670.
7. Das De S, Setiobudi T, Shen L, Das De S. A rational approach to management of alendronate-related subtrochanteric fractures. *J Bone Joint Surg*. 2010;92:679–686.
8. Weil YA, Rivkin G, Safran O, Liebergall M, Foldes AJ. The outcome of surgically treated femur fractures associated with long-term bisphosphonate use. *J Trauma*. 2011;71(1):186–90.
9. Egol KA, Park JH, Rosenberg ZS, Peck V, Tejawani NC. Healing delayed but generally reliable after bisphosphonate-associated complete femur fractures treated with IM nails. *Clinical Orthopaedics and Related Research*. 2013;472(9):2728–34.
10. Teo B. J. X., Koh J. S. B., Goh S. K., Png M. A., Chua D. T. C., and Howe T. S. Post-operative outcomes of atypical femoral subtrochanteric fracture in patients on bisphosphonate therapy. *The Bone & Joint Journal* 2014 96-B:5, 658–664.
11. Fleish, H., Russell, R.G., Francis, M.D. Diphosphonates inhibit hydroxyapatite dissolution in vitro and bone resorption in tissue culture and in vivo. *Science*. 1969; 165: 1262–1264.
12. Sato M, Grasser W, Endo N, et al. Bisphosphonate action: alendronate localization in rat bone and effects on osteoclast ultrastructure. *J Clin Invest* 1991;88:2095–2105.
13. Schaffler MB, Choi K, Milgrom C. Aging and matrix microdamage accumulation in human compact bone. *Bone*. 1995;17:521–525.
14. Durchschlag E, Paschalis EP, Zoehrer R, et al. Bone material properties in trabecular bone from human iliac crest biopsies after 3- and 5-year treatment with risedronate. *J Bone Miner Res*. 2006;21:1581– 1590.
15. Boivin GY, Chavassieux PM, Santora AC, Yates J, Meunier PJ. Alendronate increases bone strength by increasing the mean degree of mineralization of bone tissue in osteoporotic women. *Bone*. 2000; 27:687–694.
16. Roschger P, Paschalis EP, Fratzl P, Klaushofer K. Bone mineralization density distribution in health and disease. *Bone*. 2008; 42:456–466.
17. Kharwadkar N, Mayne B, Lawrence JE, Khanduja V. Bisphosphonates and atypical subtrochanteric fractures of the femur. *Bone Joint Res*. 2017;6(3):144–153.
18. Lee K-J, Yoo JJ, Oh K-J, et al. Surgical outcome of intramedullary nailing in patients with complete atypical femoral fracture: a multicenter retrospective study. *Injury* 2017;48:941–945.
19. Cao, Y., Mori, S., Mashiba, et al. Raloxifene, estrogen, and alendronate affect the processes of fracture repair differently in ovariectomized rats. *The Journal of Bone and minerals research*. 2002;17:2237–2246.
20. Thompson RN, Phillips JR, McCauley SH, Elliott JR, Moran CG. Atypical femoral fractures and bisphosphonate treatment: experience in two large United Kingdom teaching hospitals. *J Bone Joint Surg* 2012; 94(3): 385–90.

