

# Neurofibroma of Tongue -A Rare Case Report

Ballage A, ennouni. A, khatri. A, Rouadi S, Abada RL, Roubal , ahtar M<sup>1</sup>

<sup>1</sup> Ibn Rochd University Hospital

*Received: 16 December 2018 Accepted: 2 January 2019 Published: 15 January 2019*

---

## Abstract

Neurogenic tumors are rare in the oral cavity. Neurofibroma is a rare benign nonodontogenic tumor which may present either as a solitary lesion or as part of the generalized syndrome of neurofibromatosis or von Recklinghausen's disease (VRD) of the skin. The rarity of benign lingual tumors and their distinctive histopathological features have prompted us to report this case.

---

*Index terms*— neurofibroma, histopathology, tongue.

## 1 Introduction

Neurofibromas are rare in head & neck region but are the most common among neural lesion [1]. Plexiform neurofibroma is least common and is pathognomic of von Recklinghausen disease, seen in 17-30% of patient, caused by mutation of NF1 gene in chromosome 17. Up to 10% of these lesions are associated with neurofibromatosis, an autosomal dominant disorder [1]. Neurofibroma can be of three subtypes, localized, diffuse and plexiform [2,3].

Approximately 5-10% of plexiform neurofibroma under go malignant transformation, and their rate of growth is inversely proportional to age. The growth of Plexiform Neurofibroma is usually ill-defined, and there is a risk of recurrence [3][4][5][6][7][8]. Here, we present a case of a plexiform neurofibroma of the base of the tongue.

## 2 II.

## 3 Case Report

An eighteen-years-old man presented to our department with a history of a slowly growing painless mass involving the tongue which was present for two years. Oral cavity examination revealed a pinkish red swelling with an irregular surface involving the right side of the mobile tongue. The swelling, which was evident on inspection, was approximately 4x5 cm in size and was soft, nonreducible and nonpulsatile on palpation.

Complete blood count was normal. Magnetic resonance imaging (MRI) showed a hypervascularized mass in the tongue which was consistent (figure 1). Histopathological examination of the biopsy revealed lesional tissue composed of delicate spindle cells with thin wavy nuclei along with fine collagen fibrils (figure 2). Myxoid and cellular areas were seen. The patient underwent surgical removal of the mass under general anesthesia which was non-encapsulated and infiltrating deep into the intrinsic tongue muscles with a poor cleavage plane between the lesion and these muscles (figure 3).

Neither a cranial nerve trunk nor a main vascular structure was seen in the surgical field. The postoperative period was uneventful. The motor functions and sensation of the tongue were normal as well.

The patient was evaluated clinically for features of the syndrome. Multiple café au lait macules were subsequently discovered on his trunk, the patient was referred to a cancer center for further management and follow-up.

## 4 III.

## 5 Discussion

Neurofibromas of the large nerves, which appear clinically as soft, drooping and doughy masses, are benign tumors composed of neurites, Schwann's cells, and fibroblasts within a collagenous or myxoid matrix [9,10]. In

## 5 DISCUSSION

---

43 contrast to schwannomas, they are nonencapsulated and engulf the nerve of origin. Plexiform neurofibromas,  
44 forming tortuous cords along the segments and branches of a nerve with a tendency to grow centripetally, are  
45 poorly circumscribed tumors [10]. This tumor is said to be indicative of VRD even though it may be the only  
46 manifestation of the disease (11,12).

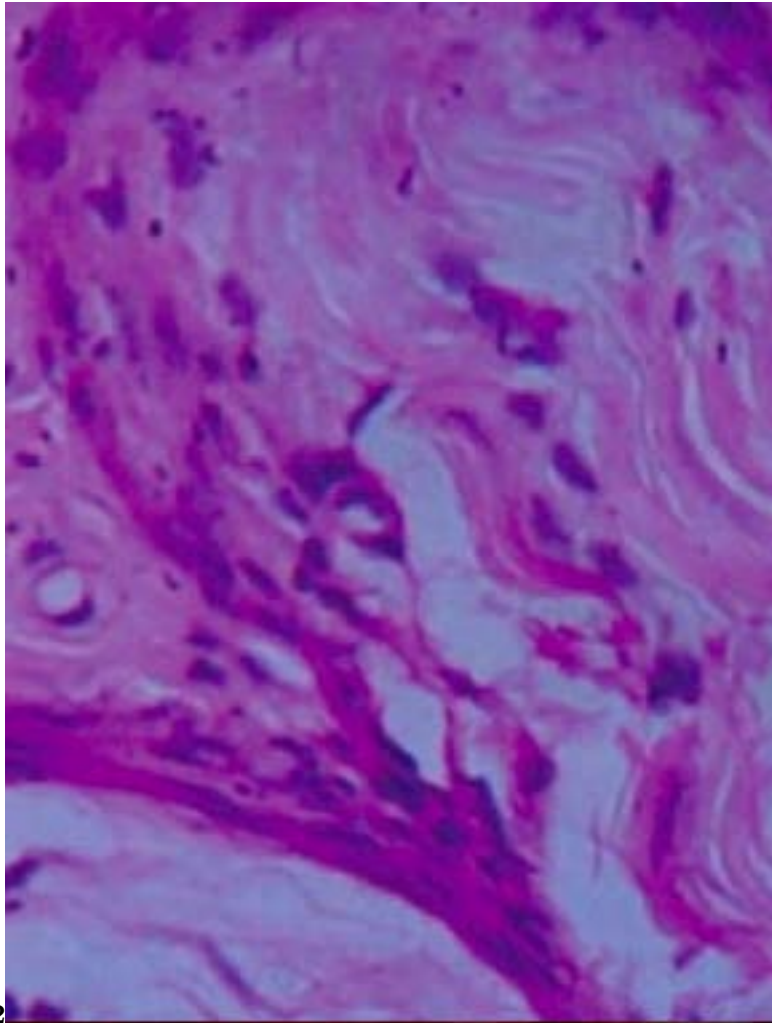
47 Neurofibromas, usually associated with VRD, are generally encountered as multiple lesions, and rarely occur  
48 as a solitary tumor [2].

49 Differential diagnosis of such a tongue mass must include neurofibroma, schwannoma (neurilemoma),  
50 lymphangioma, hemangioma, hamartoma, teratoma, pyogenic granuloma, nerve sheath myxoma, and cystic  
51 lesions such as mucoid cysts and dermoid cysts.

52 The standard treatment for neurofibromas has been surgical excision and the diagnosis can only be confirmed by  
53 histological examination. Neurofibromas have extensive vascularity and tend to bleed during surgery. Therefore,  
54 excessive bleeding should be kept in mind while attempting surgical removal [3]. Early diagnosis in such a  
55 patient is very important and these patients need regular follow-up during their lifetime to detect recurrences.  
56 Fortunately, there were no signs of recurrence or other manifestations during the follow-up period of our patient  
until that date.

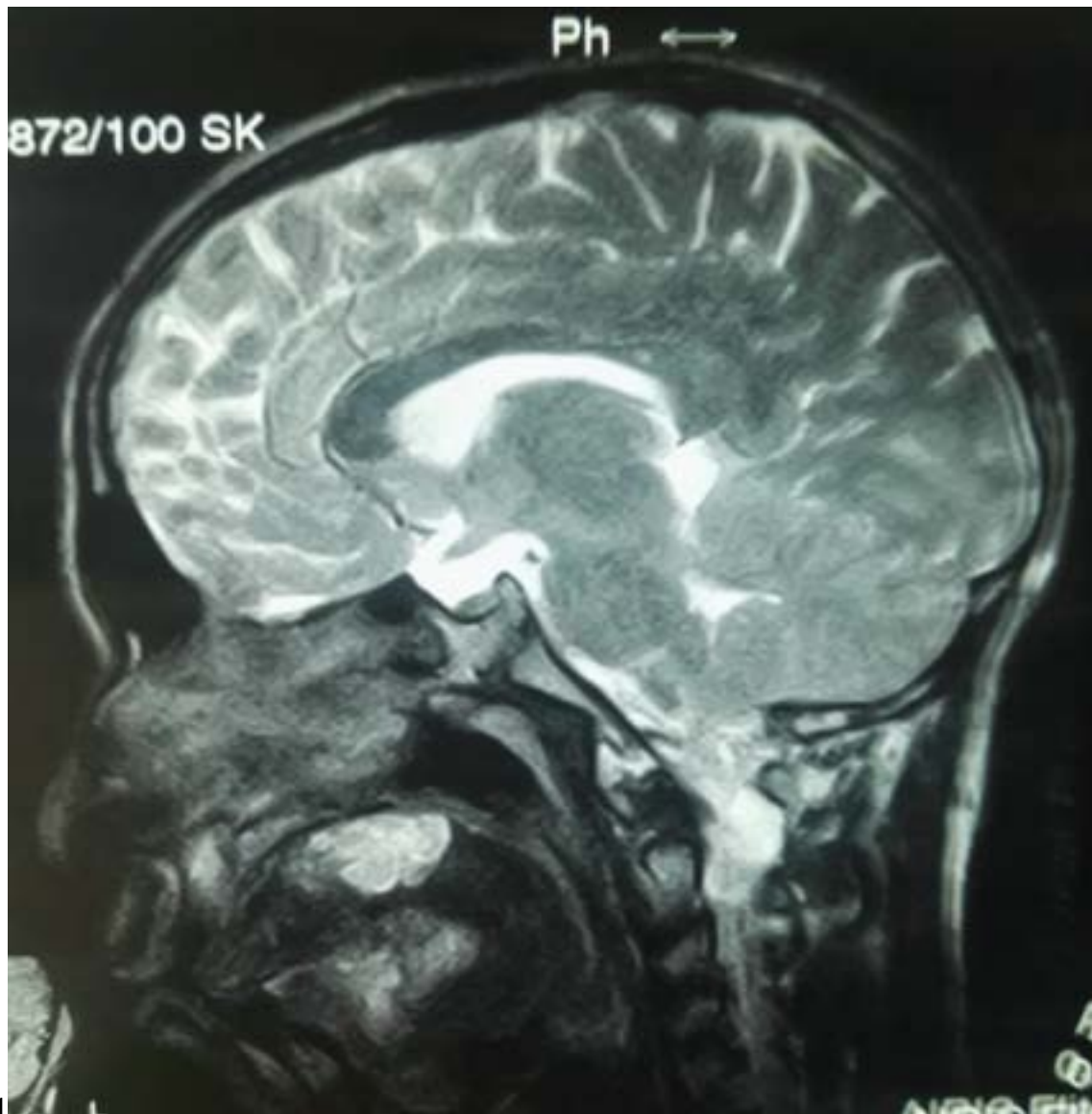

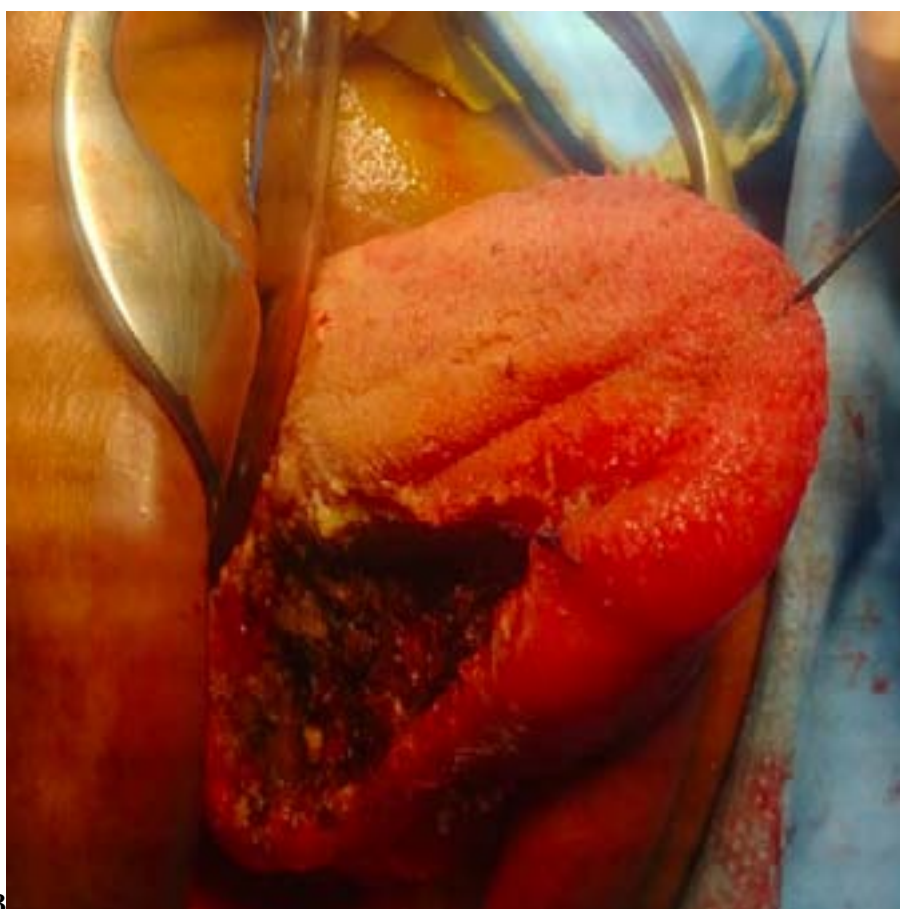Figure 1: Figure 1 :



2

Figure 2: Figure 2 :



3

Figure 3: Figure 3 :

- 
- 58 [Sharma et al.] , Abhishek Sharma , Parama Sengupta , Anjan K R Das .  
59 [Nguyen et al. ()] ‘Growth dynamics of plexiform. neurofibromas: a retrospective cohort study of 201 patients  
60 with neurofibromatosis 1’. R Nguyen , E Dombi , B C Widemann , J Solomon , C Fuensterer . *Orphanet J*  
61 *Rare* 2012.
- 62 [Gupta] Rajesh Gupta . *Neurofibroma of tongue: case report*,
- 63 [Megahed ()] ‘Histopathological variants of neurofibromatosis: a study of 114 lesions’. M Megahed . *Am J*  
64 *Dermatopathol* 1994. 16 p. .
- 65 [Suresh et al. ()] ‘Isolated plexiformneurofibroma of tongue and oropharynx: a rare manifestation of von  
66 Recklinghausen’s disease’. C Suresh , M S Sharma , S Seemiaran . *J Otolaryngol* 1998. 27 p. .
- 67 [Sharma et al. ()] ‘Isolated plexiform neurofibroma of the tongue’. A Sharma , P Sengupta , A Das . *J Lab*  
68 *Physicians* 2013. 5 (2) p. .
- 69 [Zamarro and Royo ()] ‘Neurofibroma of the tongue’. Lahoz Zamarro , M T , Galve Royo , A . *An Otorrinolaringol*  
70 *Ibero Am* 1990. 17 p. .
- 71 [Hirsch et al. ()] ‘Neurofibromatosis: clinical presentation and anaesthetic implications’. N P Hirsch , A Murphy  
72 , J Radcliffe . *Br J Anaesth* 2001. 86 (4) p. .
- 73 [Shapiro et al. ()] ‘Neurofibromatosis: oral and radiographic manifestations’. S D Shapiro , K Abromovitch , M  
74 L Van Dis . *Oral Surg Oral Med Oral Pathol* 1984. 58 p. .
- 75 [Akinbami et al. ()] ‘Pattern of presentation and management of orofacial and necksoft tissue tumors in a  
76 Nigerian tertiary health centre -apreliminary study’. B O Akinbami , O G Omitola , O Akadiri . *Intern*  
77 *Med Inside* 2013. 1 p. 9.
- 78 [Weitzner ()] ‘Plexiform neurofibroma of major salivaryglands in children’. S Weitzner . *Oral Surg* 1986. 50 p. .
- 79 [Güneri et al. (2006)] ‘Plexiform neurofibroma of the tongue: a case report of a child’. E A Güneri , E Ako?lu ,  
80 S Sütay , K Ceryan , O Sa?ol , U Pabuçcuo?lu . *Turk J Pediatr* 2006 Jun. 48 (2) p. .
- 81 [Suramya et al. ()] ‘Solitary Plexiform Neurofibroma of the Gingiva: Unique Presentation in the Oral Cavity’. S  
82 Suramya , P Shashikumar , H S S Kumar , G . *J Clin Diagn Res* 2013. 7 (9) p. .