



GLOBAL JOURNAL OF MEDICAL RESEARCH: J
DENTISTRY & OTOLARYNGOLOGY
Volume 19 Issue 2 Version 1.0 Year 2019
Type: Double Blind Peer Reviewed International Research Journal
Publisher: Global Journals
Online ISSN: 2249-4618 & Print ISSN: 0975-5888

Surgical Management of Infected Radicular Cyst using PRF and Graft Augmentation

By Dr. G. Srutha keerthi, Dr. P. Manasa, Dr. V. Priyanka & Dr. V. Prashanth

Abstract- The radicular cyst is one of the most commonly occurring cysts in the oral cavity. It is usually preceded by trauma or an infection which is followed by enlargement. In recent times there are several treatment procedures that are being applied to improve the postoperative condition and to accelerate the process of healing and regeneration in the affected site. A 30-year-old patient reported to our OPD with the chief complaint of swelling on the left side of the face since 2-3 months, on investigation a diagnosis of radicular cyst was given, which was initially treated by endodontic treatment of the involved tooth followed by enucleation of the cyst and apicoectomy. PRF and G bone graft- hydroxyapatite crystals were placed for aesthetic rehabilitation with 21.

Keywords: bone graft, PRF, radicular cyst.

GJMR-J Classification: NLMC Code: WU 158



Strictly as per the compliance and regulations of:



Surgical Management of Infected Radicular Cyst using PRF and Graft Augmentation

Dr. G. Srutha keerthi ^α, Dr. P. Manasa ^ο, Dr. V. Priyanka ^ρ & Dr. V. Prashanth ^ω

Abstract- The radicular cyst is one of the most commonly occurring cysts in the oral cavity. It is usually preceded by trauma or an infection which is followed by enlargement. In recent times there are several treatment procedures that are being applied to improve the postoperative condition and to accelerate the process of healing and regeneration in the affected site. A 30-year-old patient reported to our OPD with the chief complaint of swelling on the left side of the face since 2-3 months, on investigation a diagnosis of radicular cyst was given, which was initially treated by endodontic treatment of the involved tooth followed by enucleation of the cyst and apicoectomy. PRF and G bone graft- hydroxyapatite crystals were placed for aesthetic rehabilitation with 21.

Keywords: bone graft, PRF, radicular cyst.

I. INTRODUCTION

Cyst is a pathological cavity that may be filled with fluid, semi-fluid or gaseous contents, but never pus and it may or may not lined by epithelium. They are broadly classified into odontogenic and nonodontogenic origin with may be inflammatory or non-inflammatory. Odontogenic cysts are those which arise from the epithelium associated with the development of teeth. The source of epithelium is from the reduced enamel epithelium, enamel organ and the remnants of the dental lamina [1].

Radicular cysts or periapical cysts or lateral periodontal cysts are the most common inflammatory origin odontogenic cystic lesions of the oral cavity. They are most commonly found at the root apices of the pathologically affected teeth and there is no gender predilection [2].

II. CASE REPORT

A 30-year-old male patient reported to the outpatient department of Dental Surgery with the chief complaint of pain and gradually increasing intraoral swelling since one month. There was a history of trauma to the upper anterior teeth before five years. He consulted a dentist and was advised to undergo treatment, but he refused to get it done. Before a month,

Author α: MDS, Dept of Oral and Maxillofacial Surgery, Kamineni Institute of Dental Sciences, Narketpally, Nalgonda, Telanagana, India.

Author ο: MDS, Dept of Oral Medicine and Radiology, Meghna Institute of Dental Sciences, Nizamabad, Telangana, India.

e-mail: poosamanasa@gmail.com

Author ρ: MDS, Dept of Periodontology, Lenora Institute of Dental Sciences, Rajahmundry, Andhrapradesh.

Author ω: MDS, Dept of Conservative Dentistry and Endodontics, CKS Teja Dental College, Tirupati.

he noticed a palatal swelling near upper right anterior tooth region. Initially, the swelling was smaller in size later it gradually increased since four days with continuous mild pain in the upper right anterior region.

Intraoral clinical examination revealed an oval swelling located over right palate crossing the midline from 11 to 14 regions. On palpation, the lesion was around 2.5cm × 3.5cm, soft in consistency, and tender, pus discharge was evident. There was no change in color of the mucosa overlying the swelling. Based on history and clinical findings a provisional diagnosis of the infected periapical cyst was given.

The intraoral periapical radiograph and orthopantomogram presented an oval shape large periapical radiolucency about 4.5cm × 5.5cm associated with 11 and 12 extending till 14. The computed tomographic images revealed a large lesion involving 11-14 tooth regions with a labial plate and palatal plate perforation. On aspiration with a sterile syringe needle, straw colored fluid with blood was obtained.

A final diagnosis of the infected periapical cyst was given based on history, clinical and radiographic findings. The treatment plan included cyst enucleation followed by autologous PRF placement with GF graft under local anesthesia with root canal treatment in 11, 12. There was no significant medical history that influenced the procedure and prognosis. Root canal opening was done in all affected teeth before the surgical procedure.

Surgical enucleation, followed by placement of autologous PRF as a surgical adjuvant, was planned under local anesthesia. For the preparation of PRF, 5 ml of whole venous blood was collected in two sterile Vacutainer tubes without adding anticoagulant. The Vacutainer tubes were then centrifuged for 10 min at the speed of 3000 rpm. The cystic site was exposed through the intraoral approach and, the cystic lining was enucleated. For enucleation, nerve blocks were administered with 2% Local anesthesia with adrenaline (1:200000) Crevicular incision was given and the labial full thickness mucoperiosteal flap was elevated to expose the area of the lesion. The expansion of the existing cortical bone window was done and, underlying pathology was exposed and, space was made for curettage. PRF, G bone graft hydroxyapatite crystals were placed in the defect. Hemostasis was achieved and, primary closure was done using sutures.

Postoperative instructions were given and medication was prescribed to the patient. The excised cystic mass was sent for the histopathological examination.

Histopathological features were suggestive of a clinical diagnosis of an infected radicular cyst. Suture removal was done after a week and a palatal plate was given. The patient was kept under regular clinical and radiographic follow-up. After one month of follow-up, oral and radiological examination revealed healing wound and reduction in the size of radiolucency.



Fig. 1: Front profile of patient

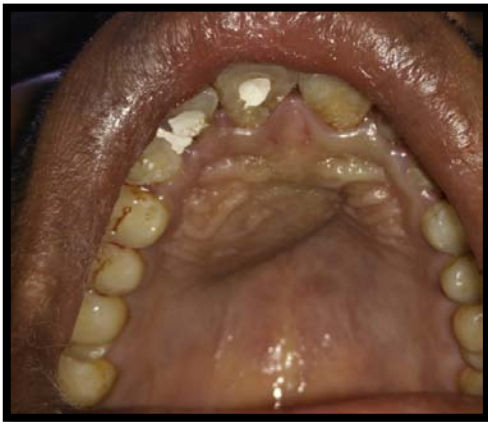

Fig. 2: Palatal swelling

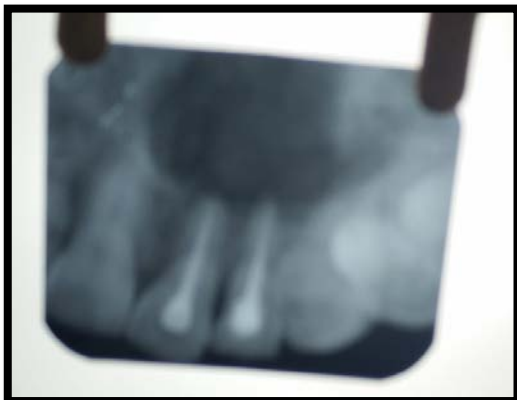

Fig. 3: IOPA showing ill defined radiolucency

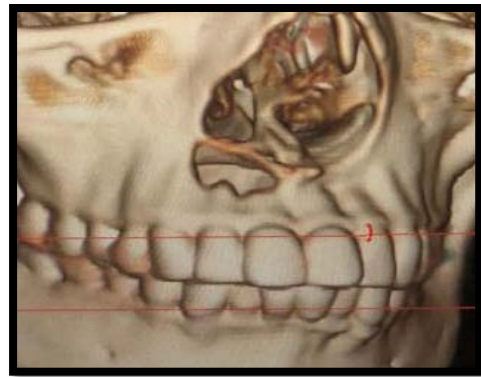

Fig. 4: CT image showing labial perforation

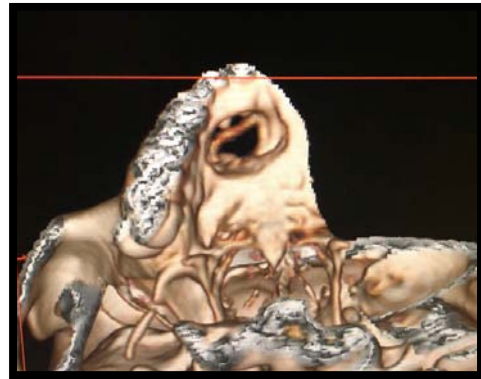


Fig 5.: CT image showing palatal perforation

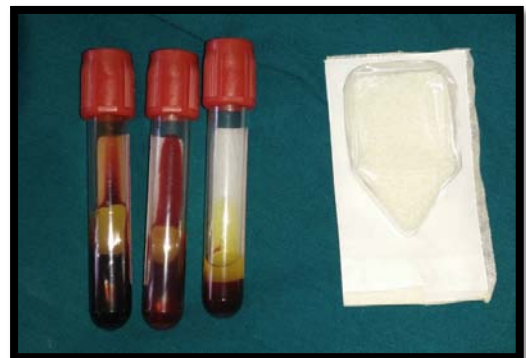

Fig. 6: Showing PRF and graft

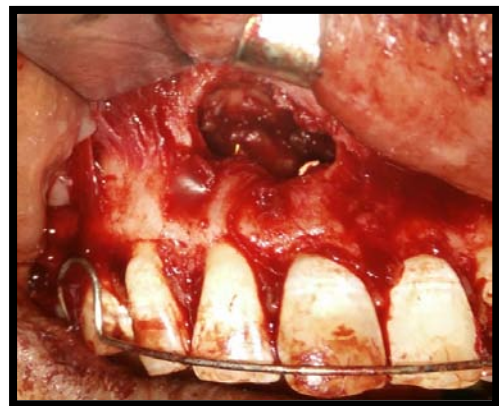

Fig. 7: Showing labial perforation

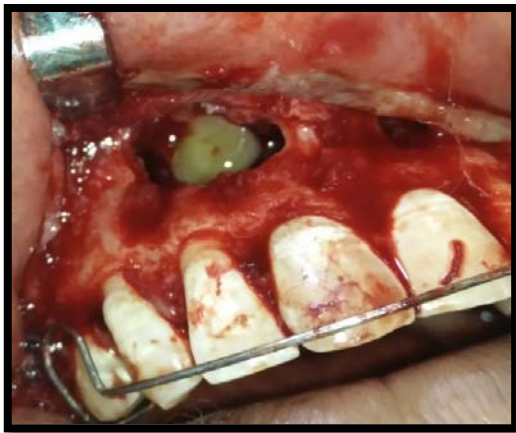

Fig. 8: PRF filled in the labial defect

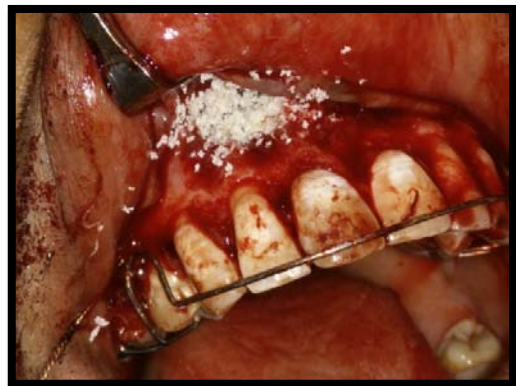

Fig. 9: Showing graft filled into defect

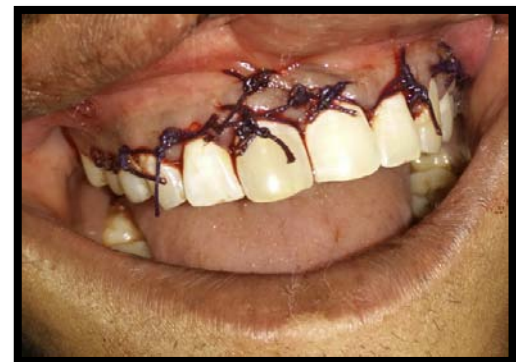

Fig. 10: Primary closure

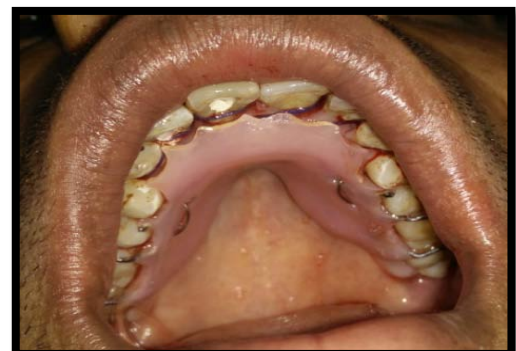

Fig. 11: Retainer placed palatally

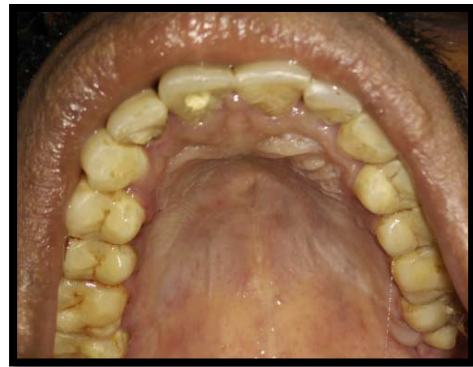

Fig. 12: Post operative image of palate

III. DISCUSSION

Radicular cysts are the most common odontogenic cyst affecting maxilla arises as a consequence of inflammation from epithelial residues in the periodontal ligament. The pathogenesis of cyst starts with initiation which gradually progresses to cyst formation, then enlarges to involve the adjacent bone and other surrounding vital structures in its surrounding. [3]. There are several treatment options to treat the cyst such as endodontic treatment followed by enucleation and marsupialization [4].

Regeneration and Repair (In a study by Ross, Platelets have regenerative potential) are the two main factors for post-surgical process [5]. Regeneration has been defined as the reproduction or reconstitution of a lost or injured part to restore the architecture and function of the periodontium [6].

Platelet-rich fibrin (PRF), a fibrin matrix in which platelet cytokines, growth factors, and cells are trapped, released after some time and serve as a resorbable membrane has been a new paradigm shift in the platelet gel therapeutic concept. Autologous PRF is considered to be a biomaterial which aids in healing. Present studies have shown its application in various treatment modalities of dentistry. PRF has several advantages such as it does not require any biochemical handling of blood and also economical. PRF also has a supportive effect on the immune system [7, 8].

Several types of bone grafts are used such as autogenous graft, allogeneic graft, alloplastic graft, and xenogeneic graft. Bone grafts alone without a blood clot or angiogenic factors are unlikely to promote sufficient periapical wound healing. PRF can be used in conjunction with bone grafts in the form of a platelet gel [3]. Besides promoting wound healing, bone growth & maturation, PRF with bone graft has advantages of graft stabilization, wound healing, hemostasis and improved handling properties [6]. The application of autologous platelet-rich fibrin along with bone graft present new possibilities for enhanced healing and functional recovery. It could be effective and economical than any other available regenerative materials.

IV. CONCLUSION

Various treatment options have been suggested depending on the size and location of the cyst. While in large lesions endodontic treatment is followed by surgical enucleation; however some authors prefer nonsurgical management of smaller lesions. This case report presents a new surgical approach using PRF and bone graft for management of large cyst along with endodontic treatment.

REFERENCES RÉFÉRENCES REFERENCIAS

1. Shafer's textbook of oral pathology, 6th ed, 487-490.
2. Nair PNR. Non-microbial etiology: periapical cysts sustain post-treatment apical Periodontitis. Endodontic Topics 2003; 6: 96-113.
3. Schwartz Z, Somers A, Mellonig T J, Carnes D L Jr, Dean D D, Cochran D L, et al. Ability of commercial demineralized freeze-dried bone allograft to induce new bone formation is dependent on donor age but not gender. *J Periodontol*. 1998; 69: 470-8.
4. Gassling V L, Açil Y, Springer I N, Hubert N, Wiltfang J. Platelet-rich plasma and platelet-rich fibrin in human cell culture. *Oral Surg Oral Med Oral Pathol Oral Radiol Endod*. 2009; 108: 48-55.
5. Ross R, Glomset J, Kariya B, Harker L. A platelet-dependent serum factor that stimulates the proliferation of arterial smooth muscle cells in vitro. *Proc Natl Acad Sci USA*. 1974; 71: 1207-10.
6. Gassling V, Douglas T, Warnke P H, Açil Y, Wiltfang J, Becker S T. Platelet-rich fibrin membranes as scaffolds for periosteal tissue engineering. *Clin Oral Implants Res*. 2010; 21: 543-49.
7. Saluja H, Dehane V, Mahindra U. platelet rich fibrin: A second generation platelet concentrate and new friend of oral and maxillofacial surgeons. *Ann Maxillofac Surg*, 2011; 1(1): 53-7.
8. Carlson E R. Bone grafting the jaws in the 21st century: The use of platelet-rich plasma and bone morphogenetic protein. *Alpha Omegan*. 2000; 93: 26-30.