

A Rare Case of Giant Endometrial Polyp with Hematometra with Old Healed Endometriotic Lesions: A Case Report

Dr. Anjali Kumari

Received: 12 December 2018 Accepted: 2 January 2019 Published: 15 January 2019

Abstract

Giant endometrial polyp with hematometra with old healed endometriotic lesion is a rare case. We present a case of old patient presented with complaint of pain in lower abdomen, but after clinical evaluation, USG and MRI report, the case diagnosed early as endometrial polyp, incidentally find hematometra and old healed endometriotic lesion at the time of hysterectomy.

Index terms— endometrial polyp, hematometra, endometriosis. with degenerative changes. Transabdominal hysterectomy with bilateral salpingo-oophorectomy done in which per op findings suggested endometrial polyp approx size 6 * 6cm inside uterus present on cut section, hematometra was present inside uterus and healed endometriotic lesion present around fallopian tubes. Histopathology report revealed atrophic endometrial glands with endometrial polyp in endometrium with no evidence of granuloma or malignancy.

1 Introduction

Endometrial polyps are benign masses that protrude into uterine lumen. They can be single or multiple, sessile or pedunculated [1]. Their size vary from millimeters to centimeters, size more than 4cm are considered to be giant [2]. Here, we report a case of 70-year old patient with endometrial polyp with hematometra with old healed endometriotic lesion. Endometriosis occurs in 6-10 % during reproductive period and 2-5% of postmenopausal women [3][4]. Hematometra in a postmenopausal woman is generally associated with cervical stenosis from senile atrophy, radiotherapy or a neoplastic lesion involving the lower uterine cavity or cervix [5].

2 II.

3 Case Report

A 70-year-old woman P 7 L 4 A 1, presented to our department with complaints of pain in lower abdomen. She had menopause since last 10 years. She had intermittent pain in lower abdomen since one month. General clinical examination was essentially within normal limits. Pelvic examination revealed cervix unhealthy with multiple nabothian cyst on per speculum examination and bulky uterus approx size 6 weeks, non tender on per vaginum examination. There were no history of prior surgery. Abdominal ultrasound showed submucosal fibroid. Pap smear taken from cervix which revealed atypical squamous cells. All routine blood investigations were within normal limits. III.

4 Discussion

Endometrial polyps are composed of endometrial glands, fibrous tissue and can contain smooth muscle [6]. These polyps can occur at any age but frequently occurs around menopause [7]. In this case, patient have hematometra may be due to endometrial polyp.

5 IV.

6 Conclusion

Giant endometrial polyp, as seen in this case, are exceedingly rare variants of classical polyp. Associated with hematometra. To the best of my knowledge, this is a rare case of postmenopausal women with giant endometrial polyp with hematometra with old healed endometriotic lesion.

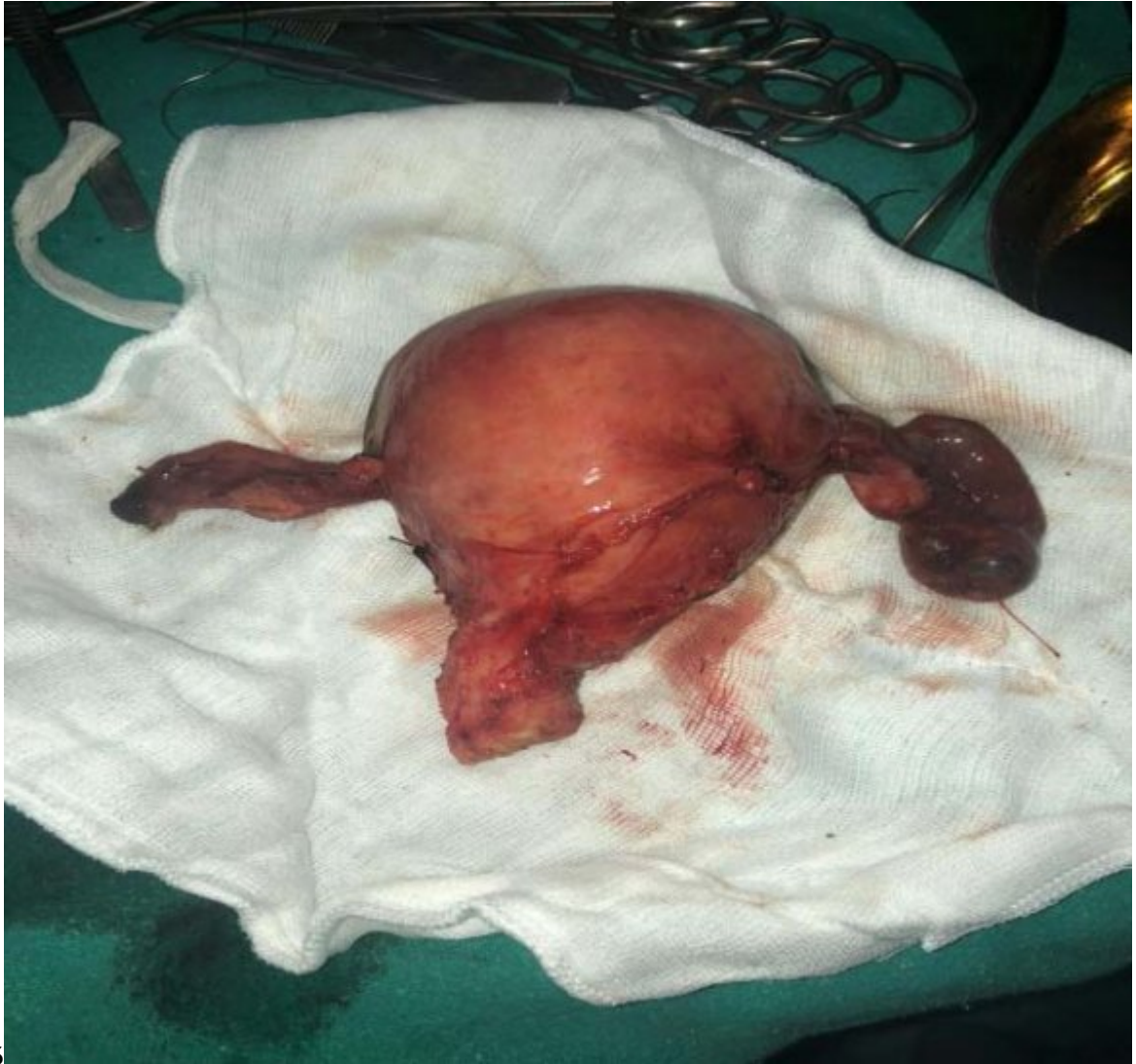

Figure 1: A Fig. 1 - 5 :

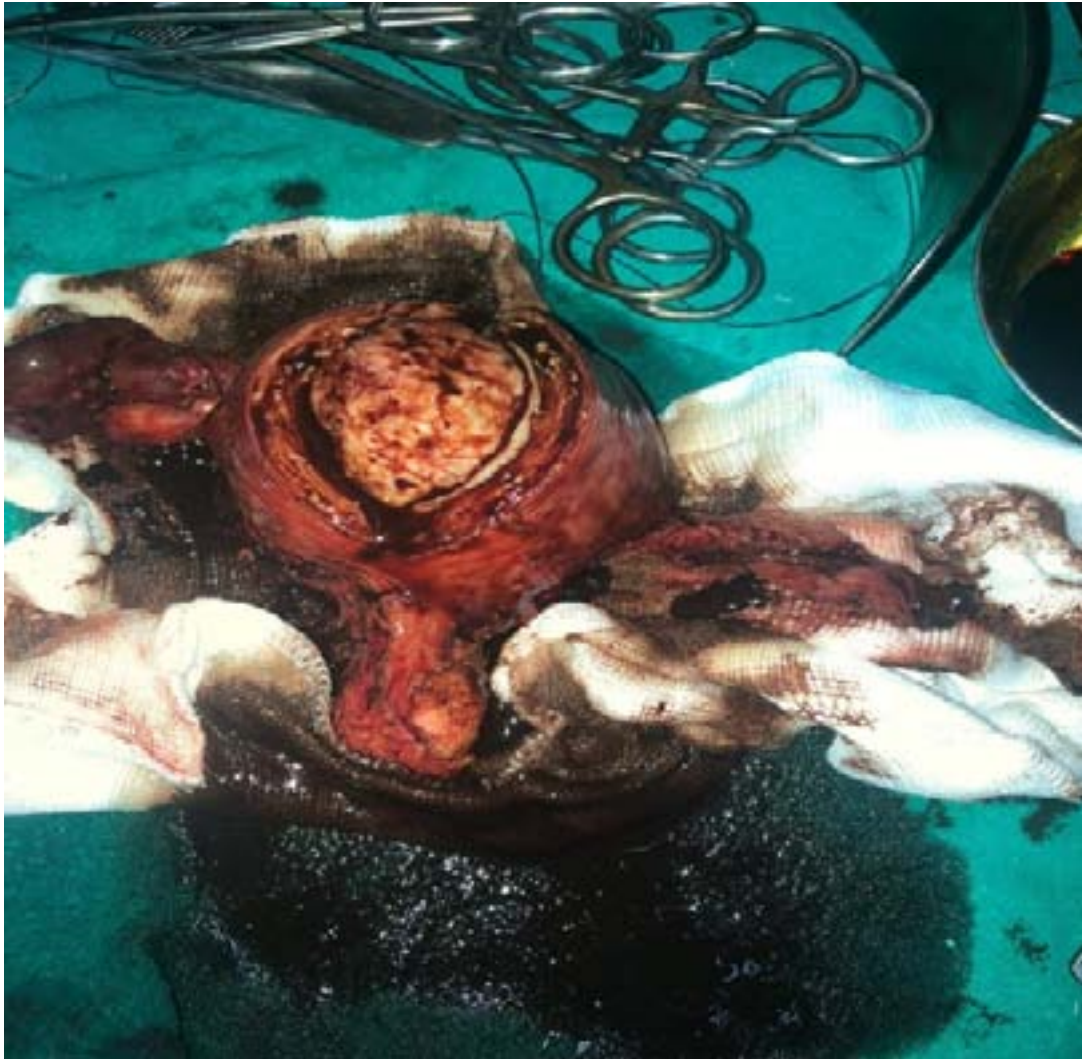


Figure 2:

-
- 43 [Peterson et al. ()] , W F Peterson , E R Novak , Polyp . *Obstet Gynecol* 1956. 8 p. .
- 44 [J Med Primatol ()] , *J Med Primatol* 2009. 38 p. .
- 45 [J Med Primatol ()] , *J Med Primatol* 2009. 38 p. .
- 46 [Bennett et al.] M W Bennett , E DickJr , N E Schlabritz-Loutsevitch , J C Lopez-Alvarenga , P C Williams
47 , R Sharp . *Endometrial and cervical polys in 22 baboons (Papio sp.), 5 cynomolgus macaques (Macaca*
48 *fascicularis) and one marmoset, (Callithrix jacchus)*
- 49 [Bennett et al.] M W Bennett , E DickJr , N E Schlabritz-Loutsevitch , J C Lopez-Alvarenga , P C Williams
50 , R Sharp . *Endometrial and cervical polys in 22 baboons (Papio sp.), 5 cynomolgus macaques (Macaca*
51 *fascicularis) and one marmoset, (Callithrix jacchus)*
- 52 [Wu et al. ()] ‘Endometrial carcinoma presenting as hematometra mimicking a large pelvic cyst’. M-P Wu , C-C
53 Chang , F-M Yen , Yet Hsieh , M-F Chao , M-H . *J Clin Ultrasound* 1999. 27 p. .
- 54 [Reslova et al. ()] ‘Endometrial polyp. A clinical study of 245 cases’. T Reslova , J Tosner , M Resi , R Kugler ,
55 I Vavrova . *Arch Gynecol Obstet* 1999. 262 p. .
- 56 [Punnonen et al. ()] ‘Postmenopausal endometriosis’. R Punnonen , P J Klemi , V Nikkanen . 10.1016/ 0028-
57 2243. *Eur J Obstet Gynecol Repord Biol* 1980. 11 p. .
- 58 [Dabrosin et al. ()] ‘Therapeutic effect of angiostatin gene transfer in a murine model of endometriosis’. C
59 Dabrosin , S Gyorffy , P Margetts , C Ross , J Gauldie . *Am J Pathol* 2002. 161 p. .