

# A Case Report of Comminuted Mandibular Fracture with Condylar Neck Fracture

Dr. Sandip Rathod

Received: 13 December 2018 Accepted: 2 January 2019 Published: 15 January 2019

## Abstract

The fracture of the comminuted type has a prevalence of 30 to 50

## Index terms—

## 1 Introduction

andibular fractures are a frequent injury occurred when there is trauma to the face and jaw this could lead to functional and aesthetic problems. The high incidence of mandibular fracture was related to its anatomy and characteristics. 1 Communitated fracture refers to multiple fracture fragments. It is a break or splinter of the bone into multiple lines. Etiology behind this kind of fracture is high impact injuries suchas, traffic accidents and falls. 2 Mandibular fractures usually have a predictable pattern, determined by the direction and force of the impact sustained. A blow to the symphysis or Para symphysis of the mandible prompts us to look for fractures in the sub condylar regions, the countercoup phenomenon. 3 One of the major goals of its treatment is focused on the union of fractured segments restoring the pre-injury strength and function. It requires a proper anatomical reduction and immobilization that will consolidate the fractured segments. 4 Earlier, conservative treatment modality was preferred over surgical because surgical procedures would lead to devitalization of soft tissues adherent to splintered bone, leading to increased risk of infection and necrosis. But nowadays, open reduction with internal fixations preferred because of the opinion that lacks stability of bony fragments leads to infection. It is a better treatment modality with a lower incidence of complications in case of moderately or severely displaced fracture bone fragments. 2 Any treatment to be carried out depends on the severity of injury and general condition of the patient, Author ? : e-mail: dr.kavitawadde@gmail.com once the general condition of the patient is stable then the concomitant injuries to be addressed. 5 The material of choice for rigid internal fixation of mandibular communicated fracture are plates and screws, reconstruction plates and 3D titanium mesh, compared to plates and screws, reconstruction plates provide more satisfying morphology and stability. 2 Absolute stability of the fracture construct must be achieved; this is the prerequisite for sound bone healing and a low rate of infection. These principles can be adhered to using reconstruction plates . 6 II.

## 2 Case Report

A 24-year-old male patient reported to the Department of Oral & Maxillofacial Surgery, with the road traffic accident. He was under the influence of alcohol during accident. The Patient -reported 10 days after trauma. No history of bleeding from ear, nose and oral cavity &unconsciousness. He also had past history of road traffic accident and fractured with right leg femur bone, under the influence of alcohol which was treated earlier. Intra-orally revealed extra oral deep laceration wound approximately 1 cm in length was present below chin region (Fig. 1). Intra oral examination revealed deranged occlusion, and there was a root piece of first left molar & difficulty in mouth opening. All routine investigations for general anesthesia have been carried out. Routine investigations were carried out. Erich arch bar was fixed intra-orally in the maxillary and mandibular region from upper right 1 st molar to left first molar & from lower right 1 st molar to left 2 nd molar. The Patient was planned under General anesthesia infiltration was done with 1:100000 diluted local anaesthesia with adrenaline solution. The Sub mandibular incision was given on left side and extended into the existing wound, posteriorly layer wise dissection was done, Facial artery & facial vein were identified and preserved communicated mandibular body fracture was exposed (Fig. ??). Intra orally the lower left molar was extracted then the fractured fragment was reduced and fixed with the reconstruction plate. The occlusion was achieved. Intermaxillary fixation was

done. Reconstruction plate of 13 holes with 2.5 mm in width was adapted and placed at the lower border of the mandible and was fixed with 8mm X 2.5mm interlocking titanium screws (Fig. ??). Layer-wise suturing done with 3-0 ethanol and skin with 4-0 mersilk. Throat pack was removed, and pressure dressing had been given. Recovery was uneventful. A Post-operative panoramic radiograph was been taken, showed reconstruction plate at the inferior border of the left side body mandible (Fig. 6).

### 3 Discussion

To treat communicated fractures is a challenge because of difficulty in reducing fractured fragments. Various treatment modalities include closed reduction, external pin fixation, internal wire fixation, and open reduction. Closed reduction was used for management of comminuted fracture before to preserve the periosteal blood supply of fractured fragments. Authors concluded open reduction with internal fixation as a better treatment modality for fixation of comminuted fractures, whenever possible. Its advantages are a stable internal fixation of bone fragments, and return of function and shorter maxillomandibular fixation period. Materials usually used for internal fixation include titanium plates and screw, reconstruction plate, titanium mesh, and bio absorbable mesh. Most of the studies show either 2.7mm or 2.4 mm reconstruction plate for fixation of comminuted fractures. Firstly, the arch bars are placed to form single arch and help in guiding the occlusion while doing open reduction and then fixed with the locking reconstruction plate and three or four screws on either side of the fracture. Usually noncompression plates are used for communicated fracture. Second option in preserving the vascularity to the communicated fragments and preventing secondary infections, thus closed reduction has been considered as the treatment of choice. However, recent reports insisted that open reduction and internal fixation (ORIF) is a better treatment option with fewer complication rates. Due to advancement in surgical method and armamentarium, the internal fixation is more favored for ORIF in the management of a comminuted mandibular fracture. It was also suggested that closed reduction or conservative treatment is a better choice only when there is minimally displaced comminuted fractures. Plates and screws are used for rigid fixation to prevent displacement of fracture segments by absorbing a part of the functional load that is present at a fracture site. Subsequently, several things to be taken into consideration or the choice must be made regarding the proper plate length and thickness required, and what type and size of screws to use. First plate length is generally determined to allow for the placement of more than one screw on either side of fracture to nullify the dynamic forces that act on the mandible in ideal conditions. Three screws are placed on either side of the fracture segments for adequate stabilization. The screws are placed at least a millimetre from the fracture site. A plate thickness is determined by the forces required to stabilize fractured bone segments. Options are first load sharing fixation with mini plates, or loadbearing with reconstruction plate. These options differ in their internal screw diameter, thickness, surface area of in-contact bone (footprint), titanium grade, malleability, which has ability to stabilize the bone segments against the intrinsic forces on the mandible. These characteristics, in general, increase as one progress from mini plates, locking plates, to recon plates. [6][7][8][9][10] The simplification of the comminuted fragments with mini plates and screws are used as an aid in reducing fracture, for subsequent fixation with reconstruction plates. A mandibular reconstruction bone plate can be used to bridge the comminution gap and stabilize the most proximal and distal segments. If major fracture parts are fixed, other minor fragments at the site can heal well even if unfixed. Comminuted fractures should have load bearing fixation applied across the area of comminution. A reconstruction plate with at least three and preferably four screws on each side of the comminuted area is the optimal way load bearing fixation is being provided. For condylar fractures, the conservative management is the treatment of choice for the majority of fractures. In general, early mouth opening exercises is essential for the treatment of condylar fractures. Open reduction of condylar fracture is recommended when it is impossible to achieve pretraumatic or adequate occlusion by close reduction.

That's why in our case we have used 13-hole reconstruction plate with 8mm x 2.5mm screw were fixed on either side on the left body of mandible, but the condyle fracture was treated by closed reduction since the vertical height of ramus was maintained we have given intermaxillary fixation for 3 weeks.

IV.

### 4 Conclusion

In this case report, we observe that there is no consensus concerning the manner of treating comminuted fractures of the mandible. The neck of the condyle fracture didn't compromise the vertical height of ramus hence we have managed it conservatively. We recommend the use of reconstruction plate for comminuted fracture of mandible. Open reduction with internal fixation with large reconstruction plates would provide rigid fixation and with minimum number of complications, combined with the use of post-operative maxillomandibular fixation, should be the treatment of choice.

---

<sup>1</sup>© 2019 Global Journals

<sup>2</sup>© 2019 Global Journals 1



1

Figure 1: Figure 1 :

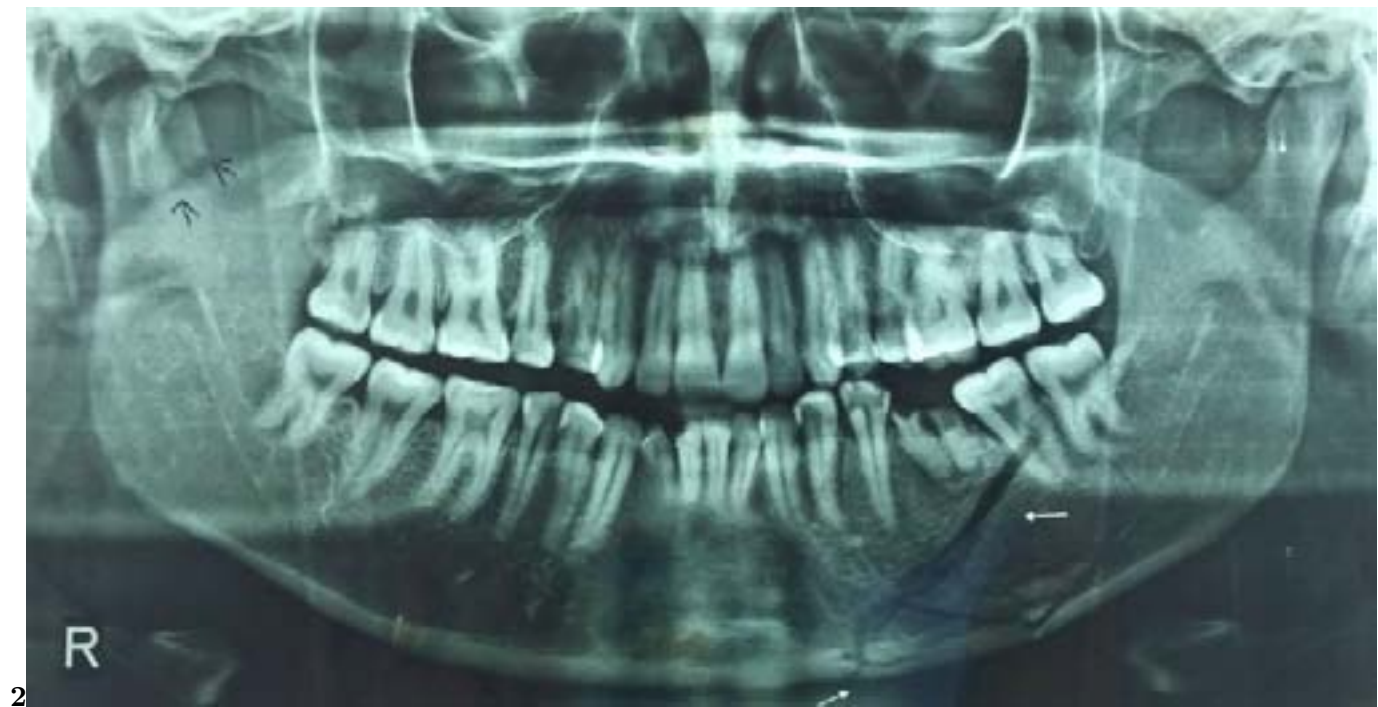
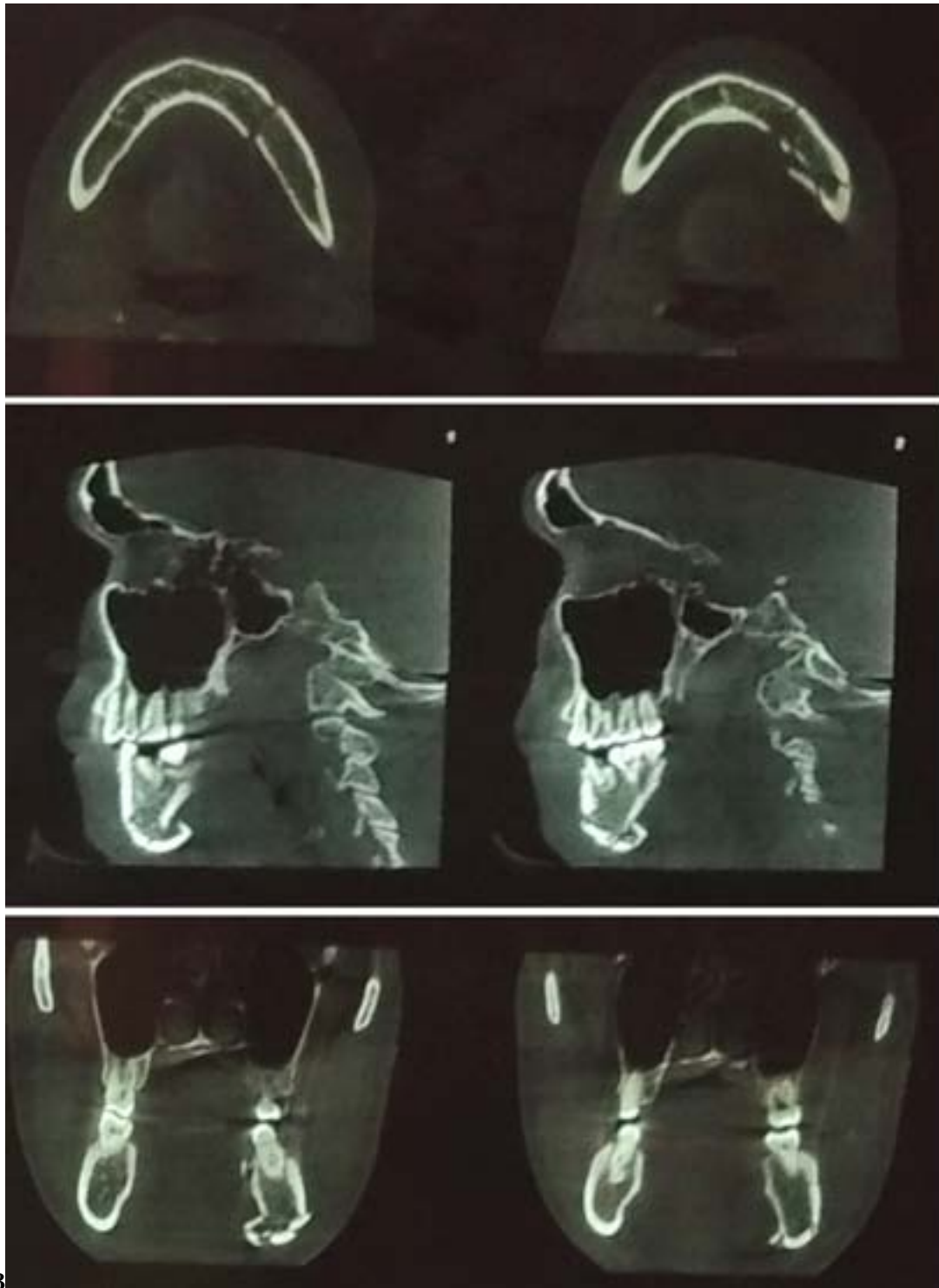


Figure 2: Figure 2 :



3

Figure 3: Figure 3 :



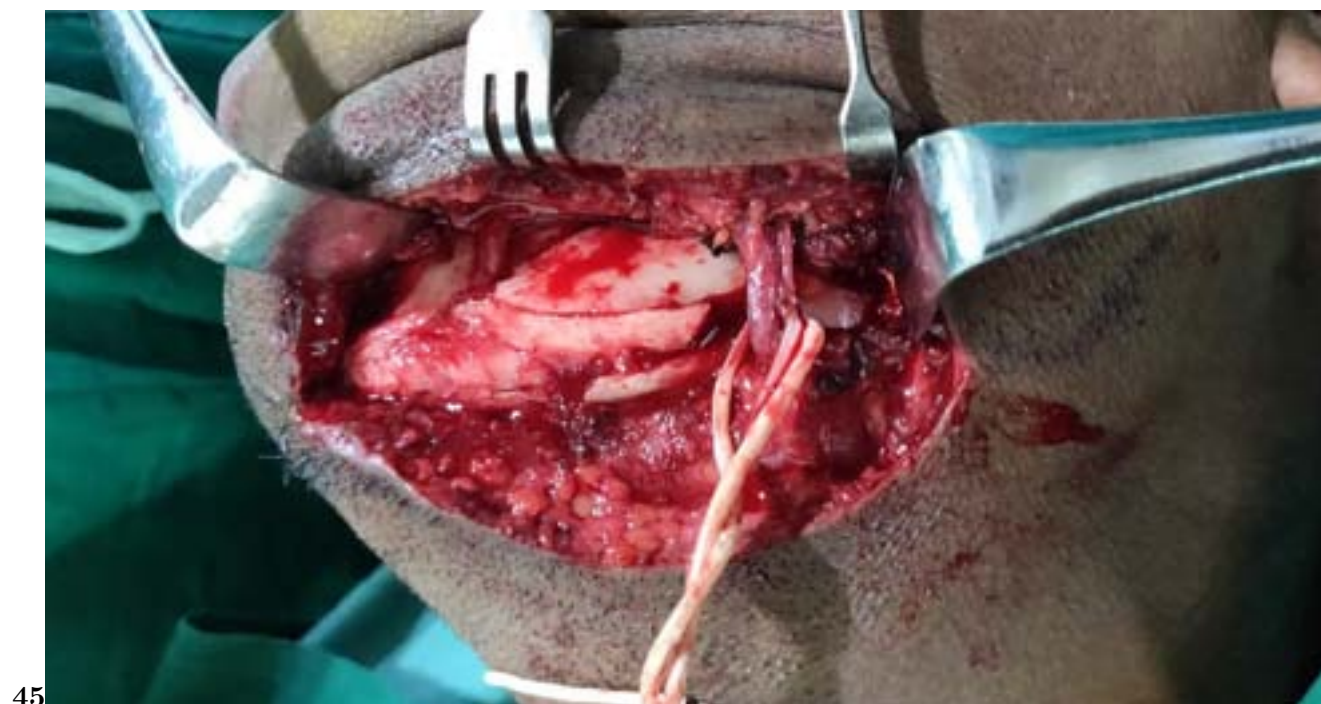

Figure 4: Figure 4 :Figure 5 :

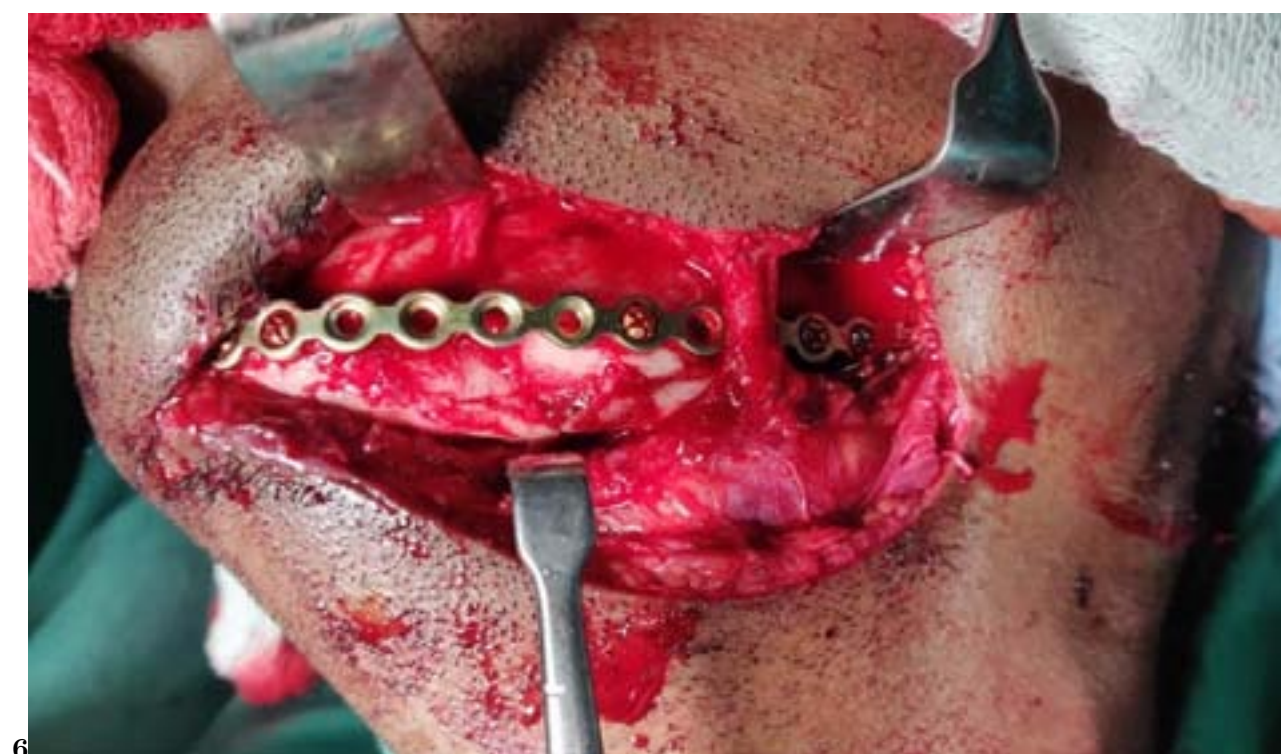

Figure 5: Figure 6 :

- 
- [Kuriakose et al. (1996)] *A comparative review of 266 mandibular fractures with internal fixation using rigid (AO/ASIF) plates or mini-plates. British journal of oral and maxillofacial surgery*, M A Kuriakose , M Fardy , M Sirikumara , D W Patton , A W Sugar . 1996 Aug 1. 34 p. .
- [Li and Li (2011)] 'Clinical characteristics and treatment of multiple site comminuted mandible fractures'. Z Li , Z Li . *Journal of Cranio-Maxillofacial Surgery* 2011 Jun 1. 39 (4) p. .
- [Abdelfadil et al. (2013)] *Infected mandibular fractures: risk factors and management*, E Abdelfadil , A S Salem , S I Mourad , Al-Belasy F A . 2013 May. 18 p. . (Journal of Oral Hygiene & Health)
- [Stacey et al. (2006)] *Management of mandible fractures. Plastic and reconstructive surgery*, D H Stacey , J F Doyle , D L Mount , M C Snyder , K A Gutowski . 2006 Mar 1. 117 p. .
- [Maki (2007)] 'Multiple and comminuted mandibular fractures: treatment outlines in adverse medical conditions in Iraq'. Al-Assaf D A Maki , M . *Journal of Craniofacial Surgery* 2007 May 1. 18 (3) p. .
- [Chrcanovic (2013)] *Open versus closed reduction: comminuted mandibular fractures. Oral and maxillofacial surgery*, B Chrcanovic . 2013 Jun 1. 17 p. .
- [Koshy et al.] 'Pearls of mandibular trauma management'. J C Koshy , E M Feldman , C J Chike-Obi , J M Bullocks . *Seminars in plastic surgery 2010 Nov*, Thieme Medical Publishers. 24 p. 357.
- [Neto et al. (2015)] 'simplification on the reduction of comminuted mandibular fractures for stable internal fixation'. I C Neto , J M Franco , M D Santana , H M Batista , E C Soares , D G De Alencar Gondim , F A Sandrini , De Abreu , L C Rodrigues , L . *International Archives of Medicine* 2015 Jun 12. 8.
- [Ellis et al. (2003)] *Treatment considerations for comminuted mandibular fractures*, Iii E Ellis , O Muniz , K Anand . 2003 Aug 1. 61 p. . (Journal of oral and maxillofacial surgery)
- [Smith and Teenier (1996)] *Treatment of comminuted mandibular fractures by open reduction and rigid internal fixation*, B R Smith , T J Teenier . 1996 Mar 1. 54 p. . (Journal of oral and maxillofacial surgery)
- [Lee et al. ()] 'Treatment of extensive comminuted mandibular fracture between both mandibular angles with bilateral condylar fractures using a reconstruction plate: a case report'. K Lee , K Yoon , K S Park , J Cheong , J Shin , J Bae , I Ko , H Park . *Journal of the Korean Association of Oral and Maxillofacial Surgeons* 2014. 40 (3) p. .
- [Lee et al. (2014)] 'Treatment of extensive comminuted mandibular fracture between both mandibular angles with bilateral condylar fractures using a reconstruction plate: a case report'. K Lee , K Yoon , K S Park , J Cheong , J Shin , J Bae , I Ko , H Park . *Journal of the Korean Association of Oral and Maxillofacial Surgeons* 2014 Jun 1. 40 (3) p. .
- [Nazimi et al. ()] *Treatment of extensively comminuted mandibular fracture with the aid of a condylar positioning device. Case reports in dentistry*, A J Nazimi , T Ezulia , J R Rajaran , M Yunus , S Salmiah , S Nabil . 2017 July 17. 2017. p. 4.
- [Scolozzi and Richter (2003)] *Treatment of severe mandibular fractures using AO reconstruction plates*, P Scolozzi , M Richter . 2003 Apr 1. 61 p. . (Journal of oral and maxillofacial surgery)