



GLOBAL JOURNAL OF MEDICAL RESEARCH: J
DENTISTRY & OTOLARYNGOLOGY
Volume 20 Issue 1 Version 1.0 Year 2020
Type: Double Blind Peer Reviewed International Research Journal
Publisher: Global Journals
Online ISSN: 2249-4618 & Print ISSN: 0975-5888

Evaluation of the Pharyngeal Airway Space Before and After Bi-Lateral Sagittal Split Osteotomy Surgery using Three-Dimensional Cone Beam Computed Tomography

By Sameer Khan, Devaki Vijayalakshmi, K.S. Nagachandran, S. Karthik, Janani Jayapal
& Abinaya Somaskandhan

Meenakshi Ammal Dental College

Abstract- Objectives: To evaluate the changes in the pharyngeal airway space (PAS) before and after bi-lateral sagittal split osteotomy (BSSO) surgery using a three-dimensional cone-beam computed tomography (3D-CBCT).

Material and Methods: The sample consisted of patients (n=7), aged between 21-30 years, having a skeletal Class II with retrognathic mandible and orthognathic maxilla who underwent orthodontic treatment and were advised for BSSO advancement surgery. Pre-surgical CBCT scans were taken a week before the surgery (T0) and the post-treatment records, three months after the surgery (T1). The 3D PAS was reconstructed from the CBCT scans, and the volumetric changes were evaluated.

Keywords: airway volume, BSSO advancement, CBCT, 3-dimensional, pharyngeal airway space.

GJMR-J Classification: NLMC Code: WU 300



Strictly as per the compliance and regulations of:



© 2020. Sameer Khan, Devaki Vijayalakshmi, K.S. Nagachandran, S. Karthik, Janani Jayapal & Abinaya Somaskandhan. This is a research/ review paper, distributed under the terms of the Creative Commons Attribution-Noncommercial 3.0 Unported License (<http://creativecommons.org/licenses/by-nc/3.0/>), permitting all non-commercial use, distribution, and reproduction in any medium, provided the original work is properly cited.

Evaluation of the Pharyngeal Airway Space Before and After Bi-Lateral Sagittal Split Osteotomy Surgery using Three-Dimensional Cone Beam Computed Tomography

Sameer Khan ^α, Devaki Vijayalakshmi ^σ, K.S. Nagachandran ^ρ, S. Karthik ^ω, Janani Jayapal [¥]
& Abinaya Somaskandhan [§]

Abstract- Objectives: To evaluate the changes in the pharyngeal airway space (PAS) before and after bi-lateral sagittal split osteotomy (BSSO) surgery using a three-dimensional cone-beam computed tomography (3D-CBCT).

Material and Methods: The sample consisted of patients (n=7), aged between 21-30 years, having a skeletal Class II with retrognathic mandible and orthognathic maxilla who underwent orthodontic treatment and were advised for BSSO advancement surgery. Pre-surgical CBCT scans were taken a week before the surgery (T0) and the post-treatment records, three months after the surgery (T1). The 3D PAS was reconstructed from the CBCT scans, and the volumetric changes were evaluated.

Result: The PAS volume was derived, and the pre-surgical values (T0 mean=14083.19mm³) were compared with the post-surgical values (T1 mean=18067.26mm³), and a significant increase by 28.29% in the volume was evident (t=4.51, p=0.04 < 0.05) for a mean mandibular advancement of 4.7mm.

Conclusion: Our findings suggest that bilateral mandibular advancement surgery in patients with retrognathic mandible increases the PAS volume anatomically and enhances the breathing functionally.

Keywords: airway volume, BSSO advancement, CBCT, 3-dimensional, pharyngeal airway space.

1. INTRODUCTION

The upper airway has long been an area of interest in orthodontics, with topics such as the relationships between facial type and airway,¹ airway shape and volume with growth and development² and the clinician's potential to modify the airway through

treatments like growth modification³ and surgery for correction of jaw deformities.⁴ However, most studies evaluating the airway have been conducted with two-dimensional (2D) cephalograms, providing limited data such as linear and angular measurements, for a complex three-dimensional (3D) structure.^{5,6}

Contemporarily, the lateral cephalograms still seem to be the dominating evaluation tool in the field of upper airway research inspite of its disadvantages. The main drawback, without any doubt, is considered as the degradation of a three-dimensional (3D) entity into two dimensions. With the introduction of CBCT, shortcomings of lateral cephalograms have been overcome.^{7,8}

Despite the widespread use of CT examinations in clinical practice, this new technology brought along concerns about the exposure to ionizing radiation and its potential hazards. Therefore, radiation dose and strategies for dose reduction, especially for younger patients, have become an important focus of interest.

With the advent of Cone Beam Computed Tomography, lower radiation doses and faster image acquisition times have become possible when compared with conventional computed tomography scans.^{9,10} Also the three-dimensional diagnosis of the airway is more reliable with the Cone Beam Computed Tomography with the reduced radiation dose.¹¹

The isolation of the hard and soft tissue structures based on the variations in their densities is apparent in a CBCT image, which allows the segmentation and visualization of hollow structures such as the airway, and the analysis of the airway volume are easy with the use of appropriate software.

Previous studies have reported that patients with skeletal class II malocclusion with mandibular retrognathism had a reduced pharyngeal airway space.¹² Mandibular advancement surgery has been advocated as a treatment option for skeletal retrognathism, which has a strong influence on the airway post-surgically. Several studies have reported regarding the Pharyngeal Airway Space (PAS) changes two-dimensionally using lateral cephalograms after

Author α: BDS, MDS, Post graduate, Dept of orthodontics and dentofacial orthopaedics, Meenakshi Ammal Dental College.
e-mail: jjanani93@gmail.com

Author σ: BDS, MDS, Professor & HOD, Dept of orthodontics and dentofacial orthopaedics, Meenakshi Ammal Dental College.
e-mail: devasara17@gmail.com

Author ρ: BDS, MDS, Professor, Dept of orthodontics and dentofacial orthopaedics, Meenakshi Ammal Dental College.

Author ω: Senior lecturer, Dept of orthodontics and dentofacial orthopaedics, Meenakshi Ammal Dental College.

Author ¥ §: Post graduate, Dept of orthodontics and dentofacial orthopaedics, Meenakshi Ammal Dental College.

surgical procedures.^{5,6} The purpose of this study is to evaluate the airway volumetric after mandibular advancement surgery using 3D CBCT techniques.

II. MATERIALS AND METHODS

The study protocol was reviewed and approved by 'The Institutional Ethics Committee of Meenakshi Academy of Higher Education and Research, Meenakshi University' with the Ref MAHER/COE – 250/2014. Before the CBCT scan, the patients were fully informed about the purpose of this study and the radiation risks associated with the scan. All the patients included in this study were from the department of orthodontics, meenakshi ammal dental college and hospital who have reported for orthodontic treatment.

Inclusion Criteria

- The patients included in the study were adults within the age group of 21 years to 30 years.
- The patients should have a skeletal Class II jaw base with retrognathic mandible and an orthognathic maxilla.
- Cephalometric criteria (mean pre-surgical values). SNB 76.40. ANB 4.70. Wit's Appraisal 2.4mm.
- The patients should not have undergone any previous surgeries of the oral and maxillofacial region before the study.

Seven patients, who were advised for mandibular advancement surgery using Bilateral Sagittal

Split Osteotomy, were selected for this study. The 3D-CBCT was acquired using Planmeca ProFacecone beam 3D imaging system (Planmeca, Helsinki, Finland). The pre-surgical 3D-CBCT was taken within a week before the surgery. The post-surgical 3D-CBCT was taken three months following the Bi-Lateral Sagittal Split Osteotomy. The surgery performed on the patients involved advancement of the mandible, with a mean of 4mm, in the anterior-posterior direction. Rigid fixation was done using mini-plates and screws.

All subjects were examined and oriented to have their heads positioned with the Frankfort horizontal plane parallel to the floor with maximum intercuspation. The whole maxillo-facial complex, (extending from the vault of the skull superiorly, till the level of the thyroid cartilage) was scanned with the Planmeca ProFace Cone-Beam 3D imaging system. With the exposure time of about 14 seconds, the 3D images acquired were reconstructed with 400 microns isometric voxel size, with the tube voltage of about 90 kV and 9mA tube current. Images were examined with the scanner's proprietary software ROMEXIS (Version 3.0.2.R).

In the explorer view of the software, the image in the coronal section was oriented so that the sagittal slicing plane (Red line) passes through the anterior nasal spine (ANS). This will help to obtain the particular sagittal section which passes exactly through the mid-sagittal plane. In the sagittal section of the image, the following landmarks were marked (Figure: 1)

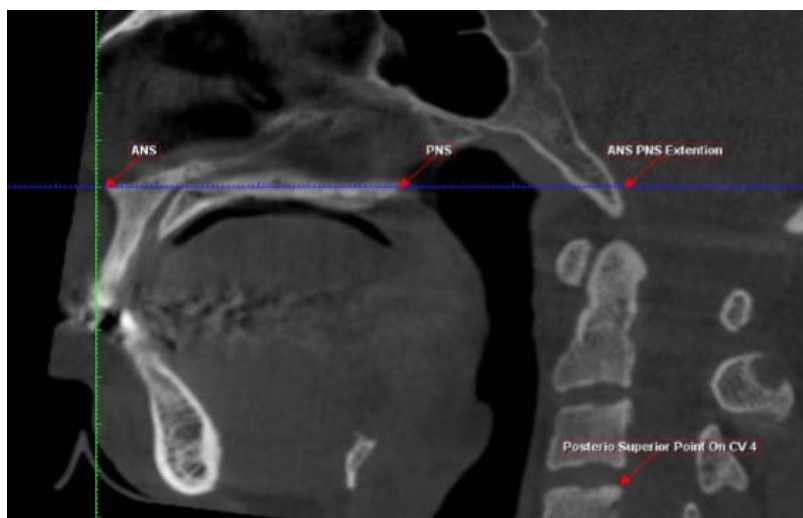


Figure 1: Sagittal section showing orientation to palatal plane with its landmarks (Pre-surgical)

- ANS-Anterior nasal Spine
- PNS-Posterior nasal Spine
- C4up-The most superior point on the posterior border of the body of the C4

Then the sagittal image is rotated so that the palatal plane (ANS-PNS) is parallel to that of the axial slicing plane (Blue Line). Since the airway is not bounded fully with hard tissue structures, the anterior and superior boundary is located at the PNS point and

the posterior and inferior boundary is located at the C4up point as it corresponds to the deepest point of the vallecula. Taking these landmarks as reference, the external volume of the airway is drawn using a tool provided by the software.

The airway could be isolated after demarking the total volume of interest required for the study. The ROMEXIS software automatically created the third dimension based on the height and the width of the

region marked in the two-dimensional view (Figure: 2). Using the 3D region growing tool, the 'air cavity' was selected from the pre-sets. A local threshold level of 70

was used and the particular area of interest in the airway region was selected.

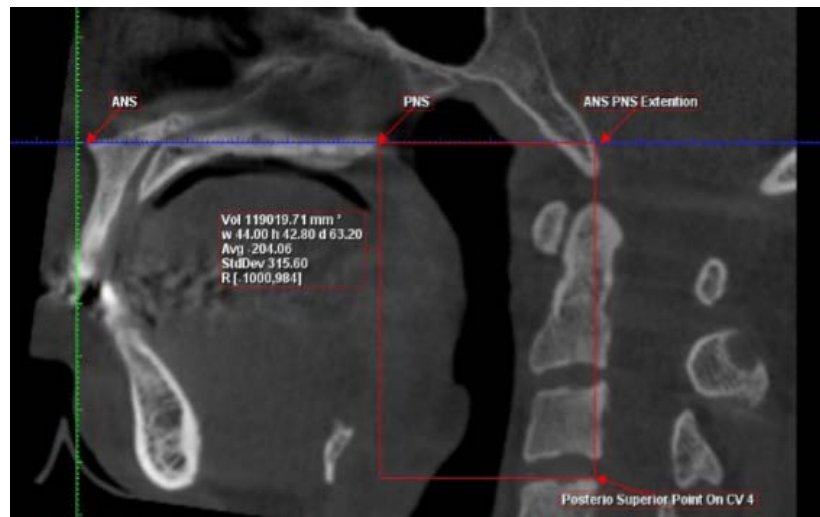


Figure 2: Demarcation of the total volume of interest required for the study (Pre-surgical)

Depending on the density variations, the volume of the selected region is derived and displayed by the software in all the three orientation planes (Figure: 3). Thus, the air cavity was isolated and a 3D rendered

image of the airway along with its volume (measured in mm^3) was displayed in the explorer window (Figure: 4a, 4b).

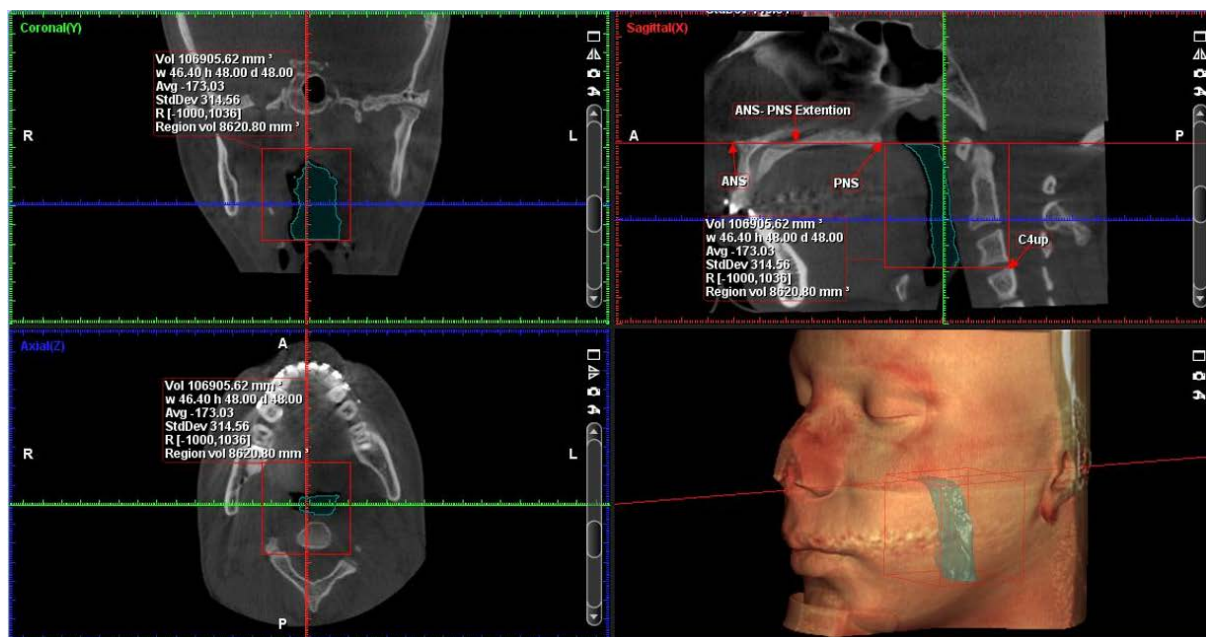


Figure 3: Airway isolated in coronal sagittal, axial and 3D rendered view

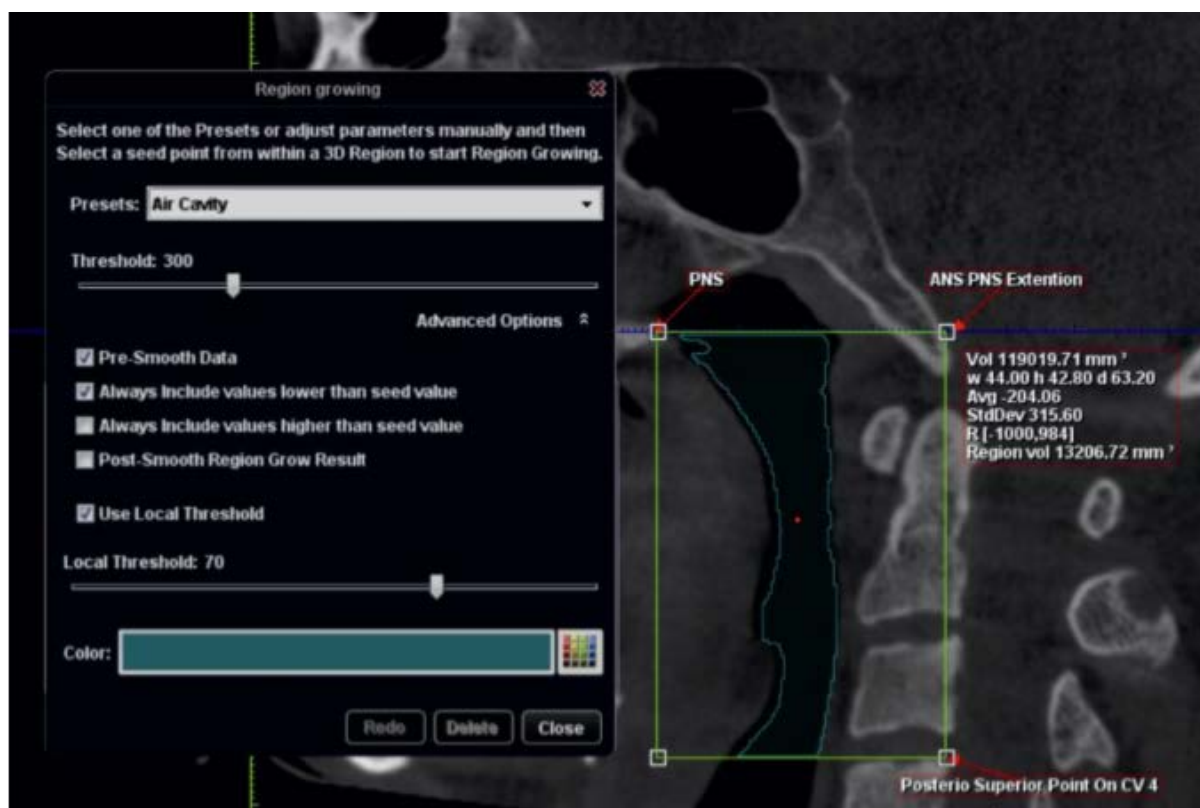


Figure 4(a): Measured Pharyngeal Airway Space volume (mm³)

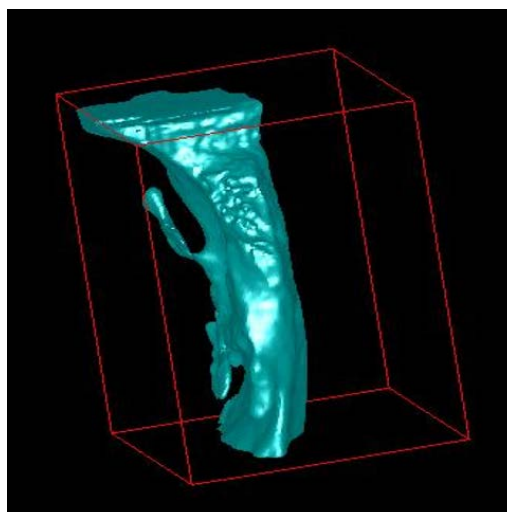


Figure 4(b): 3D rendered view of the isolated Pharyngeal Airway Space (Pre- surgical)

This procedure was carried out by a single operator (S.K) to create and measure the rendered volumes. For reliability purpose, it was repeated by the same operator after a period of two weeks and finally, the average is taken for the calculation.

Descriptive statistics including the mean, and standard deviation for each group were calculated by using SPSS (version 20.0). The Normality test, Kolmogorov-Smirnov and Shapiro Wilk tests results showed that all the variables followed the normal distribution and therefore the parametric test was applied to analyze the data. To compare the mean

values between the pre-surgical and post-surgical Pharyngeal Airway Space (PAS) volume paired t-test was applied. A p-Value < 0.05 level of significance was used for the test.

III. RESULTS

The descriptive statistics are summarised in Table-I, II shows the changes in the cephalometric measurements of the craniofacial morphology taken before and after the mandibular advancement surgery. The volumetric increase in the Pharyngeal Airway Space (PAS) for the patients (n=7) showed a significant

increase from baseline (T₀) to 3 months post-surgical (T₁) ($t=4.51$, $p=0.04 < 0.05$), which is represented in Table-III. From baseline (T₀) to the post-surgical measurements (T₁), the total PAS volume for a mean

mandibular advancement of 4.7mm showed an increase of 28.29%. Changes in the PAS volume before and after mandibular advancement surgery (volume in mm³) are given in Figure: 5-7.

Table I: Volumetric measurements of the Pharyngeal Airway Space before and after mandibular advancement surgery and their mean values of the patients (n=7)

Patients	Pre-Surgical Airway Volume (mm ³) (T ₀)	Post-Surgical Airway Volume (mm ³) (T ₁)	Increase in volume (mm ³) (T ₁) - (T ₀)	Percentage of variation (%)
Patient 1	14832.45	16645.08	1812.63	12.22
Patient 2	8246.72	10917.12	2670.4	32.38
Patient 3	13206.72	20093.57	6886.85	52.15
Patient 4	17946.11	23677.06	5730.95	31.93
Patient 5	13351.42	20075.36	6723.94	50.36
Patient 6	14124.56	16031.62	1907.06	13.50
Patient 7	16874.34	19031.01	2156.67	12.78
Mean	14083.19	18067.26	3984.07	28.29%

Table II: Variables describing the craniofacial morphology of the samples both pre-surgical and postsurgical.

Mean Variables	Pre Surgical (T ₀)	Post-Surgical (T ₁)	Difference (T ₁) - (T ₀)
SNB °	76.4	81.3	4.9
ANB °	4.7	2.4	2.3
Wit's (mm)	2.4	-0.9	-3.3

Table III: Paired differences & the test results of the study

Post – Pre surgical airway volume	Mean Paired Differences		t – Value	p-Value
	Volume (mm ³)	Percentage of variation (%)		
	3984.07	28.29%	4.51	0.04

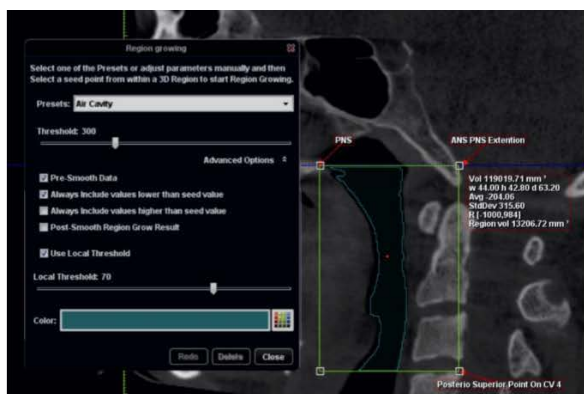


Figure 5(a)

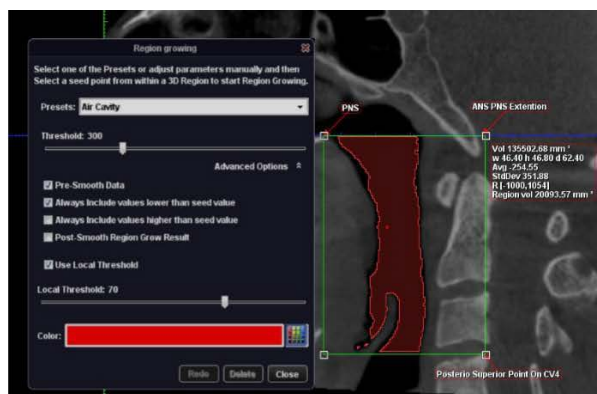

Figure 5(b)

Figure: 5(a): Pre-surgical & 5(b): Post-surgical Pharyngeal Airway Space

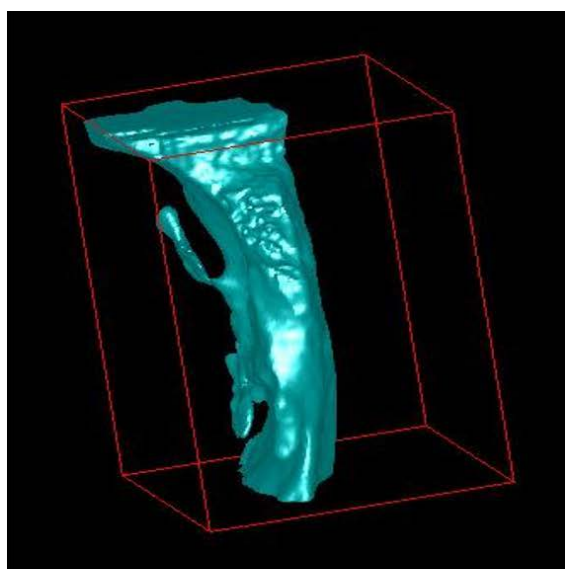


Figure 6(a)




Figure 6(b)

Figure: 6(a): Pre-surgical & 6(b): Post-surgical 3D rendered view of the Pharyngeal Airway Space

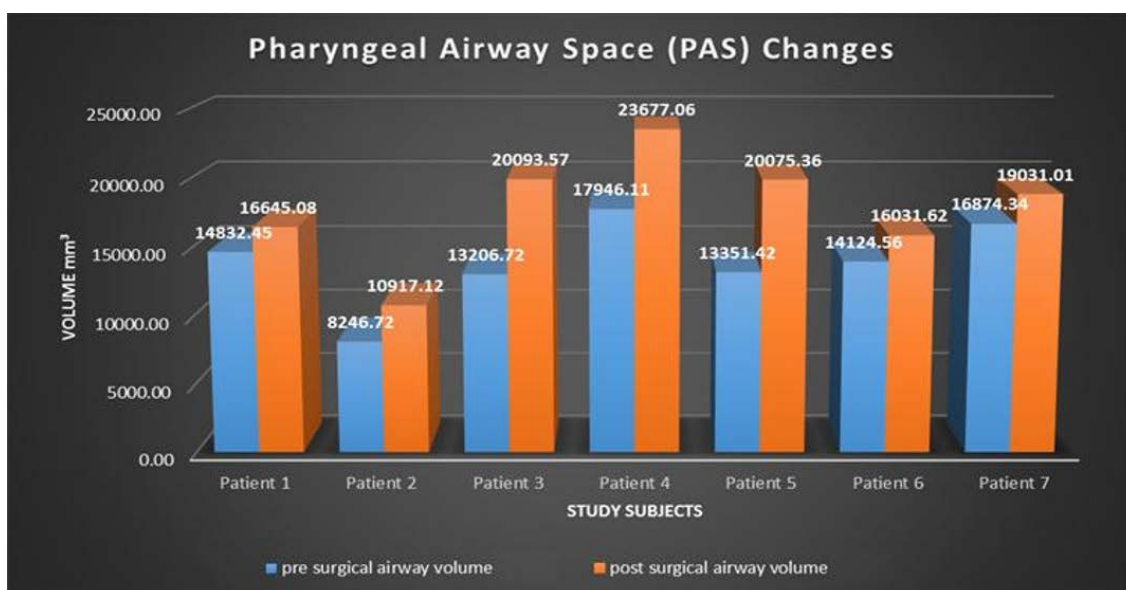


Figure 7: Pharyngeal Airway Space volume changes before and after mandibular advancement surgery (volume in mm³)

IV. DISCUSSION

Several two-dimensional studies have evaluated the relationship between the airway, head posture, craniofacial morphology, and the positioning of the jaw bases.^{1,2,13,14} However many drawbacks have been reported regarding the assessment of the airway using the lateral cephalograms. Some of them include, assessment of a three-dimensional structure using two-dimensional imaging technique, measurements in "area" rather than "volume" and superimposition of structures.

To overcome these drawbacks, many studies have utilized the Computed Tomography (CT) Scan for the assessment of the Pharyngeal airway.¹⁵⁻¹⁷ However the ionizing radiation and potential hazards of increased radiation dose with conventional CT Scan have limited its use in assessing the Pharyngeal airway. On the contrary CBCT imaging provides an adequate imaging quality with low radiation doses and shorter exposure time. Recently many studies have also been reported regarding the accuracy of CBCT in assessing the Pharyngeal Airway volume over the conventional lateral cephalograms, and CT Scans.^{8,11}

Aboudara et al⁸ evaluated the PAS volumes determined from cephalograms and compared them with 3D-CBCT records. The 3D PAS analysis yields reproducible and clinically relevant data while being superior to cephalometric analysis. In the present study, Pharyngeal Airway Space (PAS) volume was analyzed by using the software PLANMECA ROMEXIS. The threshold value in the analysis software is an important tool in determining the boundaries of the airway to be measured. By varying the threshold value, the filling degree of the airway can get altered, and hence the measurements might be overestimated or underestimated when compared with the actual volume. Alves et al¹⁸ evaluated the influence of threshold value in measuring the actual airway volume and reported that the accurate prototype airway volume could be obtained with thresholds between 70 and 75 when using the Dolphin 3D software. In the present study, Romexis Software was used; for the assessment of the airway volume, the software is provided with a pre-set local threshold value of 70, which was similar to that as suggested by Alves et al. and the software automatically calculated the airway volume in cubic millimeters.

Studies have reported that the variation in the anteroposterior jaw relationships show different pharyngeal airway volumes and patients with a retrognathic mandible have a relatively lesser airway volume when compared to the airway volume to that of a Class I skeletal base.^{2,18}

Treatment modalities for the correction of mandibular retrognathism in Class II patients in growing individuals include functional appliance therapy to advance the mandible where as in adults, surgical

mandibular advancement is the only option available, both of which will have a strong influence in the airway volume.^{19,20} Li et al. compared growing class II div1 patients and patients treated with twin block appliance and found an improvement in the oropharyngeal and the hypopharyngeal airway along with the anterior positioning of the hyoid bone after functional appliance treatment.²¹

Several studies have reported the improvement of the PAS in Class II patients with mandibular retrognathia after mandibular advancement surgery.^{22,23} Hernández et al. have stated that the mandibular advancement surgery results in greater improvement in the Pharyngeal airway volume due to the advancement of the skeletal attachment of the suprahyoid muscles and tendons that play a major role in the widening of the PAS.²⁴

Turnbull et al. described a similar effect in their cephalometric study demonstrating significant enlargement in the PAS after mandibular advancement surgery. It was noted that the volume increase is most pronounced in the lower and middle thirds of the PAS, which is related to post-operative advancement of the tongue, hyoid, and associated structures.²⁵ Kochel et al. in their 3D CBCT study assessed the Pharyngeal airway changes after mandibular advancement surgery in adult Class II patients and reported an increase in the PAS by 45.6%.²⁶

The improvement in the PAS in our study showed an increase of 28.29% for a mean mandibular advancement of 4.7mm. This was less when compared to that of the studies reported by Hernández et al.²⁴ and Kochel et al.²⁶ Probably, the reason for the reduced degree of improvement in our study is due to lesser sample size. Also, the degree of mandibular advancement might influence on the magnitude of the airway volume improvement, and Hernández et al.²⁴ have already reported that in their future study, they might try to evaluate a correlation between the magnitude of the skeletal forward movement and the increase in the PAS volume.

The present study evaluated the airway volume, three dimensionally using cone beam computed tomography in patients with skeletal Class II malocclusion with mandibular retrognathism. However, the limitations of the current study include limited sample size, and short-term follow-up. Moreover, the reliability of the software was not carried out.

V. CONCLUSION

The following conclusions can be drawn from the present study:

- 1) Mandibular advancement surgery increased the Pharyngeal Airway Space (PAS) in patients with the retrognathic mandible.

- 2) With a mean mandibular advancement of 4.7mm, the PAS showed about 28.29% of improvement, which was statistically significant.

Our findings suggest that bilateral mandibular advancement surgery in patients with retrognathic mandible is a viable treatment option that not only improves the facial profile and esthetics but also enhances the functional characteristics of the airway by increasing its volume.

BIBLIOGRAPHY

1. Hakan El and Juan Martin Palomo. Measuring the Airway in 3 Dimensions: A Reliability and Accuracy Study. *Am J Orthod Dentofacial Orthop* 2010; 137: S50.E1-S50.E9.
2. Kim YJ, Hong JS, Hwang YI, and Park YH. Three-Dimensional Analysis of Pharyngeal Airway in Preadolescent Children with Different Anteroposterior Skeletal Patterns. *Am J Orthod Dentofacial Orthop* 2010; 137: 306.E1-11.
3. Ozbek MM, Memikoglu TU, Gögen H, Lowe AA, Baspinar E. Oropharyngeal Airway Dimensions And Functional-Orthopedic Treatment In Skeletal Class II Cases. *Angle Orthod* 1998; 68: 327-36.
4. Yu LF, Pogrel MA, and Ajayi M. Pharyngeal Airway Changes Associated with Mandibular Advancement. *J Oral Maxillofac Surg* 1994; 52:40.
5. Ibrahim M. Zeitoun. Cephalometric Changes of the Upper Airway after Advancement of Micrognathic Mandible of Long-Standing Bilateral TMJ Ankylosis. *The Saudi Dental Journal* 1993; 121:126.
6. Soteris Achilleos, Olaf Krogstad AND Torstien Lyberg. Surgical Mandibular Advancement and Changes in Uvuloglossopharyngeal Morphology and Head Posture a Short- and Long-Term Cephalometric Study in Males. *Eur J Orthod* 2000; 367:381.
7. Foltán R., Rybínová K. the Impact of Mandibular Advancement on the Upper Airways Patterns – Cephalometric Study. *Prague Medical Report* 2007; 147–154.
8. Aboudara C, Nielsen I, and Huang Jc. Comparison of Airway Space with Conventional Lateral Headfilms and 3-Dimensional Reconstruction from Cone-Beam Computed Tomography. *Am J Orthod Dentofacial Orthop* 2009; 135: 468–479.
9. Ludlow JB, Davies-Ludlow LE, Brooks SI and Howerton WB. Dosimetry of 3 CBCT Devices for Oral And Maxillofacial Radiology: CB Mercuray, Newtom 3G And i-CAT. *Dentomaxillofac Radiol* 2006; 35: 219-26.
10. MahJk, Danforth Ra, Bumann A and Hatcher D. Radiation Absorbed In Maxillofacial Imaging With A New Dental Computed Tomography Device. *Oral Surg Oral Med Oral Pathol Oral Radiol Endod* 2003; 96: 508-13.
11. PalomoJm, Rao Ps and Hans Mg. Influence of CBCT Exposure Conditions on Radiation Dose. *Oral Surg Oral Med Oral Pathol Oral Radiol Endod* 2008; 105:773-82.
12. Alves PV, Zhao L, O'gara M, Patel PK, Bolognese AM. Three Dimensional Cephalometric Study of Upper Airway Space in Skeletal Class II and III Healthy Patients. *J Craniomaxillofac Surg* 2008; 19: 1497 – 1507.
13. Alves PV, Zhao L, O'gara M, Patel PK, Bolognese AM. Three Dimensional Cephalometric Study of Upper Airway Space in Skeletal Class II and III Healthy Patients. *J Craniomaxillofac Surg* 2008; 19: 1497 – 1507.
14. Beni Solow, Susanne Siersbæk-Nielsen and Ellen Greve. Airway Adequacy, Head Posture, and Craniofacial Morphology *Am J Orthod* 1984; 214: 223.
15. Yamashina, Tanimoto and Sutthiprapaporn. The Reliability of Computed Tomography (CT) Values and Dimensional Measurements of The Oropharyngeal Region using Cone Beam CT: Comparison with Multidetector CT. *Dentomaxillofac Radiol* 2008; 37: 245–251.
16. Takahashi M, Okada H, Oguni N, Maeda K, Segawa K, Nitta N, Murata K. How Accurate Is CT Morphometry of Airway? Phantom and Clinical Validation Study. *Eur J Radiol*. 2011 Dec; 80(3): E524-30.
17. Tsuyoshi Oguma, Toyohiro Hirai Mail, Akio Niimi, Hisako Matsumoto, Shigeo Muro, Michio Shigematsu, Takashi Nishimura, Yoshiro Kubo, Michiaki Mishima. Limitations of Airway Dimension Measurement on Images Obtained using Multi-Detector Row Computed Tomography. *Doi: 10.1371/Journal.Pone.0076381*.
18. Matheus Alves, Jr, Carolina Baratieri, Cl_Audia Trindade Mattos, Daniel Brunetto, Ricardo Da Cunha Fontes, Jorge Roberto Lopes Santos, and Antonio Carlos De Oliveira Ruellas. Is The Airway Volume Being Correctly Analysed. *Am J Orthod Dentofacial Orthop* 2012; 141: 657-61.
19. Turnbull Nr and Battagel Jm. The Effects of Orthognathic Surgery on Pharyngeal Airway Dimensions and Quality of Sleep. *J Orthod* 2000; 27: 235–247.
20. Fengshan Chen, Kazuto Terada, Yongmei Hua and Isao Saito. Effects of Bimaxillary Surgery And Mandibular Setback Surgery on Pharyngeal Airway Measurements in Patients with Class III Skeletal Deformities. *Am J Orthod Dentofacial Orthop* 2007; 131: 372-7.
21. Liang Li, Hong Liu, Huijuan Cheng, Yanzhao Han, Chunling Wang, Yu Chen, Jinlin Song and Dongxu Liu. CBCT Evaluation of the Upper Airway Morphological Changes in Growing Patients of Class II Division 1 Malocclusion with Mandibular

- Retrusion using Twin Block Appliance: A Comparative Research 2014; E94378.
22. Conradt R, Hochban W and Brandenburg U. Long-Term Follow-Up after Surgical Treatment of Obstructive Sleep Apnoea by Maxillomandibular Advancement. *Eur Respir J* 1997; 10:123–128.
 23. Lye Kw Effect Of Orthognathic Surgery on the Posterior Airway Space (PAS). *Ann Acad Med Singapore* 2008; 37:677–682.
 24. Hernández-Alfaro F, Guijarro-Martinez R and Mareque-Bueno J. Effect of Mono- and Bimaxillary Advancement on Pharyngeal Airway Volume: Cone-Beam Computed Tomography Evaluation. *J Oral Maxillofac Surg* 2011; 69: E395– 400.
 25. Turnbull Nr and Battagel Jm. The Effects of Orthognathic Surgery on Pharyngeal Airway Dimensions and Quality of Sleep. *J Orthod* 2000; 27:235–247.
 26. Janka Kochel, Philipp Meyer-Marcotty, Franka Sickel, Helmut Lindorf and Angelika Stellzig Eisenhauer. Short-Term Pharyngeal Airway Changes after Mandibular Advancement Surgery in Adult Class-II Patients—A Three-Dimensional Retrospective Study. *J Orofac Orthop* 2013; 74: 137152.

