

The Management of Breast Cancer during Pregnancy in the Maternity Ward of Rabat in Morocco-A Case Report

M. Yousfi

Received: 8 December 2019 Accepted: 1 January 2020 Published: 15 January 2020

Abstract

Breast cancer during pregnancy (PABC) is a rare affection; but since more women postpone childbearing until middle age, the incidence of breast cancer in pregnancy started increasing. Delays in diagnosis and treatment are also due to physiological changes in the breast during pregnancy. Breast cancer associated with pregnancy represents a unique clinical scenario that requires balancing between risks and benefits for both the maternal and fetal wellbeing. The goal of this report is to evaluate and promote effective management for patients with breast cancer during pregnancy.

Index terms—

1 Introduction

Breast cancer is the most common form of cancer diagnosed during pregnancy; it occurs in 1 to 4 cases per 10,000 pregnancies [1]. This incidence is rising because of the the delay of childbearing combined with increased occurrence of young-onset breast cancer [2].

However, pregnancy follow-ups and treatment methods are relative to gestational age. which creates a dilemma regarding the preservation or termination of pregnancy.

The role of the obstetrician is to take a multidisciplinary approach to improve maternal and child health outcomes. showing an irregular breast tumor, classified as score five according to the Breast Imaging Reporting and Data System (BI-RADS). Based on the results, a right breast biopsy and histological analysis were performed and concluded an invasive ductal carcinoma grade 3, with estrogen and progesterone receptors positive, and human epidermal growth factor receptor 2 (HER2) negative. An ultrasonography and heart monitoring of the fetus was done. A pulmonary X-ray with abdominal protection and liver ultrasonography was realized with no signs of distant metastatic disease. The patient was sent to oncologists and received four cures of chemotherapy consisting of épirubicine 100 mg and cyclophosphamide. With partial breast tumor remission at 38 weeks of gestation, the parturient started labor, and fetal monitoring showed suspicion of fetal distress (Fig. ??). 40-year-old lady, Gravida 3 Para 3, two vaginal births, who came at 32 gestational weeks. With no personal or family history of cancer. The volume of the right breast started growing abnormally from 30 weeks of gestation without the patient noticing, since there was no pregnancy follow up either. The parturient consulted after the breast consistency and volume changed with skin erythema and homolateral axillary adenopathy that were also palpable during physical examination. An ultrasound examination was realized (Fig. 1), Fig. ??: Fetal monitoring showing recurrent deceleration. Afterward, a cesarean section was realized, with a newborn baby Apgar 4/6 out of 10, with respiratory distress of 4 out of 10 and malformation of the righthand fingers. The baby was addressed to pediatrics for a complementary malformation examination. Examination of the placenta was negative, and after three weeks, the patient was sent again to oncology to complete the rest of chemotherapy.

She later underwent a modified radical mastectomy, a complement of radiation, and hormonal therapy (tamoxifen) was given.

2 Case 2:

Thirty-nine years old patient, with no history of cancer, Gravida 3 Para 3, two vaginal births, with 27 gestational weeks of pregnancy. Seven months before, the patient had noticed (in the left breast) a retro areolar and superior

lump associated with skin inflammation. An ultra-sonography was realized describing left infectious mastitis (Fig. ??).

3 Fig. 3: Irregular retroareolar mass, with cutaneous thickness

The patient was given antibiotics for 14 days, with no improvement, according to her. Due to personal reasons, no follow up was done until she came back after seven months later, with an extensive mass involving all four quadrants of the breast, with nipple invasion (Fig. 4). the left mammary gland, with thickened skin associated with pectoral muscle infiltration and multiple axillary nodes with a costal lesion (Fig. ??).

4 Fig. 5: Infiltration of the left mammary gland, with thickened skin, associated with pectoral muscle infiltration, and multiples axillary nodes with coastal lesion

The biopsy concluded an invasive ductal carcinoma of grade 3 with estrogen and progesterone receptors negative and a positive human epidermal growth factor Receptor of 2 (HER2). The patient underwent neoadjuvant chemotherapy consisting of paclitaxel, Adriamycin, and cyclophosphamide. Ultrasonography of the fetus was made showing a 27week fetus with no anomalies (Fig. ??) Fig. ??: Mono Fetal evolutive pregnancy corresponding to 27 weeks of gestation At 38 weeks of pregnancy, labor was induced, resulting in the birth of a healthy girl Apgar 10/10, 2900 g. After a week, the patient was sent to oncology again to complete her treatment.

5 II.

6 Discussion

The diagnosis of breast cancer associated with pregnancy concerns every breast cancer appearing during pregnancy and lactation, and about a year in post-partum [2][3]. Some delay concerning the diagnosis of breast cancer in pregnant patients is frequently caused by changes in breast tissue that occurs during pregnancy [4]. According to gestational age and breast's physiological modifications, clinical examination and diagnosis might be difficult.

Breast disorders related to pregnancy are usually benign, but because of the seriousness of pregnancy-associated with breast cancer and the risk of a delayed diagnosis, during this period, all masses must be carefully evaluated [5]. Also, the physician must proceed to a careful local and systemic examination as would be done in a non-pregnant woman, followed by an imaging study if a lump is clinically suspected.

An initial diagnosis can be made by using breast ultrasound, as this method is considered safe and has high sensitivity and specificity [6]. If there are any suspicious features or ultrasound is not enough, then it is prudent to proceed with bilateral mammography (with abdominal shielding) to exclude bilateral and multicentric disease. Also, mammography is considered safe for the fetus, since the breast radiation around three mGy, so fetal exposure is about 0.004 Gy [7]. In our cases, we especially relayed on ultra-sonography results that were positive.

After Imaging, the examination should be complemented by biopsy. In our case, we used Tru-Cut biopsy, and the results were in favor of invasive ductal carcinoma, as reported in studies showing that 70-90% are Invasive ductal carcinoma, followed by invasive lobular carcinoma [8]. The frequency of inflammatory breast cancer is increasing, and the histologic score system (Scarff, Bloom Richardson grading system) is also high.

Radiographic examinations for staging purposes should be avoided during pregnancy and used only when the estimated risk of metastatic disease is high, and if the results can change the therapeutic decision. In this situation, a liver ultrasound is recommended if there is any suspicion of liver metastases. And if the patient is symptomatic and metastases are highly suspected, chest X-ray and a skeletal survey via non contrast MRI can be done. MRI scan of the breast is not indicated for breast cancer during pregnancy because it requires to lie in a prone position, and the use of gadolinium contrast is associated with adverse effect on the fetus.

One of our patients with stage 4 disease required an MRI, but CT scan was done because of the masse volume and difficulty to have a prone position. Through the examination costal invasion was discovered.

According to clinical and imaging examination, the patient can best aged like a non-pregnant woman. The modality of treatment involved surgery associated with adjuvant or neoadjuvant chemotherapy.

Mastectomy can be done under general anesthesia and can be performed at any gestational age with minimal risk to the fetus. After 20 weeks, the patient should be positioned with left lateral uterine displacement to avoid aortocaval compression [8].

Breast-conserving surgery may be safely performed in most cases. But preferably in the second and third trimesters, to not delay radiation therapy that can be used until after delivery [8].

Sentinel lymphnode biopsy in PABC patients is approved during pregnancy according to National Comprehensive Cancer Network (NCCN) guidelines since several studies showed it might be safely performed [9].

Chemotherapy is administered considering gestational age and can be safely initiated during the second and third trimesters. In our oncology institute, anthracyclines, especially cyclophosphamides, Adriamycin with or without 5-fluorouracil are the most commonly used medications. [10] For metabolizing chemotherapeutic substances, the placenta takes three weeks what helps its excretion from the fetus [10]. After 35 weeks

chemotherapy may result in fetal toxicity increases the chances of spontaneous labor and at the time of delivery some bleeding problems, sepsis, or death may occur. Consequently, the time interval of three weeks is recommended between the last chemotherapy session and the delivery.

Therefore, Radiation therapy (RT) is generally not recommended during pregnancy and should be delayed until the post-partum period [11]. RT is not an absolute contraindication for PABC and may be considered in highly selected cases following riskbenefit assessment with the mother while considering gestational age.

Currently, the use of Taxanes, tamoxifen, and anti-HER2 are usually started in the post-partum period [12,13].

Our two patients underwent neoadjuvant chemotherapy before modified radical mastectomy. Post-natal, radiotherapy, and hormonal therapy were given depending on the stage and hormone receptor status.

PABC patients should be considered as highrisk obstetric patients, with routine fetal and maternal health checkup at least once every three weeks. Regarding pregnancy follow up, fetal development should be assessed before there is an increased risk of IUGR (intrauterine growth restriction), prematurity, low birth weight (sometimes due to chemotherapy). Some authors suggest random ultrasonography checkup in each semester of pregnancy with weight evaluation and also fetal doppler [14].

Preterm delivery should be avoided. Vaginal delivery is preferred since post-partum anti-neoplastic treatment can be resumed immediately, while at least a one-week interval is recommended after cesarean section. Cesarean section is not indicated regarding PABC, and concerning neonatal outcomes, immaturity may underlie neonatal sequel and thus recommend avoiding premature delivery [14].

Also, the placenta should be inspected as previous reports found placental metastases [15].

Breastfeeding is generally not recommended during chemotherapy as drugs are excreted in human milk. Also, cyclophosphamide treatment might cause transient neutropenia in the new born. But It becomes possible three weeks after the end of chemotherapy; breastfeeding should not be contraindicated to women who have completed chemotherapy with momentous time before delivery. From the neonatal perspective [16], breastfeeding with contralateral breast after the end of treatment is possible.

Regarding fertility, chemotherapy has ovarian toxicity that may cause transitory amenorrhea or even precocious menopause. There are different factors influencing this toxicity, like the age, the type of cytotoxic, the duration of treatment, and accumulated doses [17]. Women must be informed before starting the treatment, of the risk of menopause and the impact on fertility.

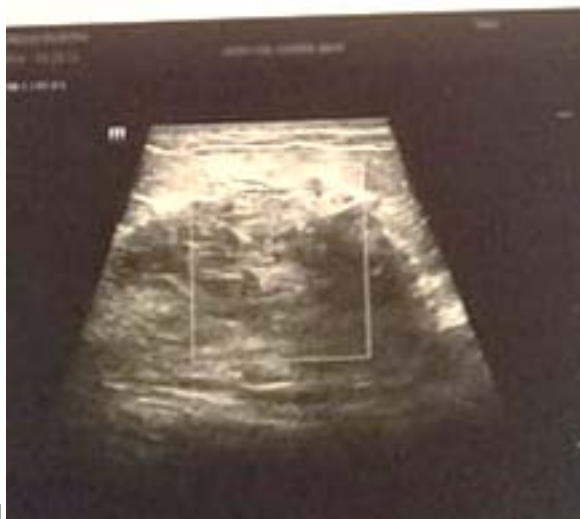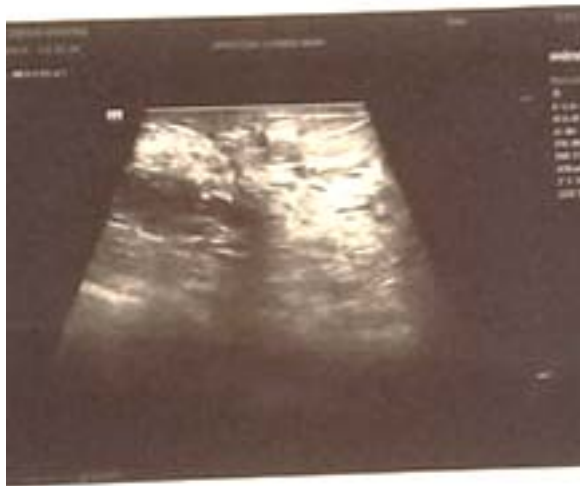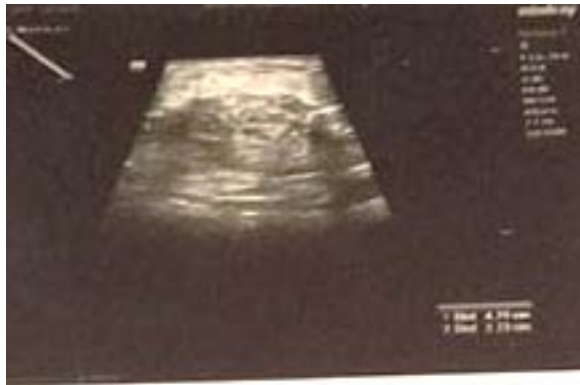The oncologic follow-up concerning breast cancer requires a clinical examination, mammography with ultrasonography every 6th to 12 months, for three years, then every year. Before starting a new pregnancy after breast cancer: Liver sonography, chest X-ray, or thoracic, abdominal scan must be realized [18]. In the case of using anthracyclines or trastuzumab in high doses, heart ultrasonography is required because of the high risk of cardiac insufficiency related to pregnancy [19]. During pregnancy, a breast examination must be done frequently, and imaging mustn't be requested if there are no clinical signs.

The Conception can be accepted 2 or 3 years after treatment or five years when tamoxifen is prescribed (but three months after the end of treatment) [20].

7 III.

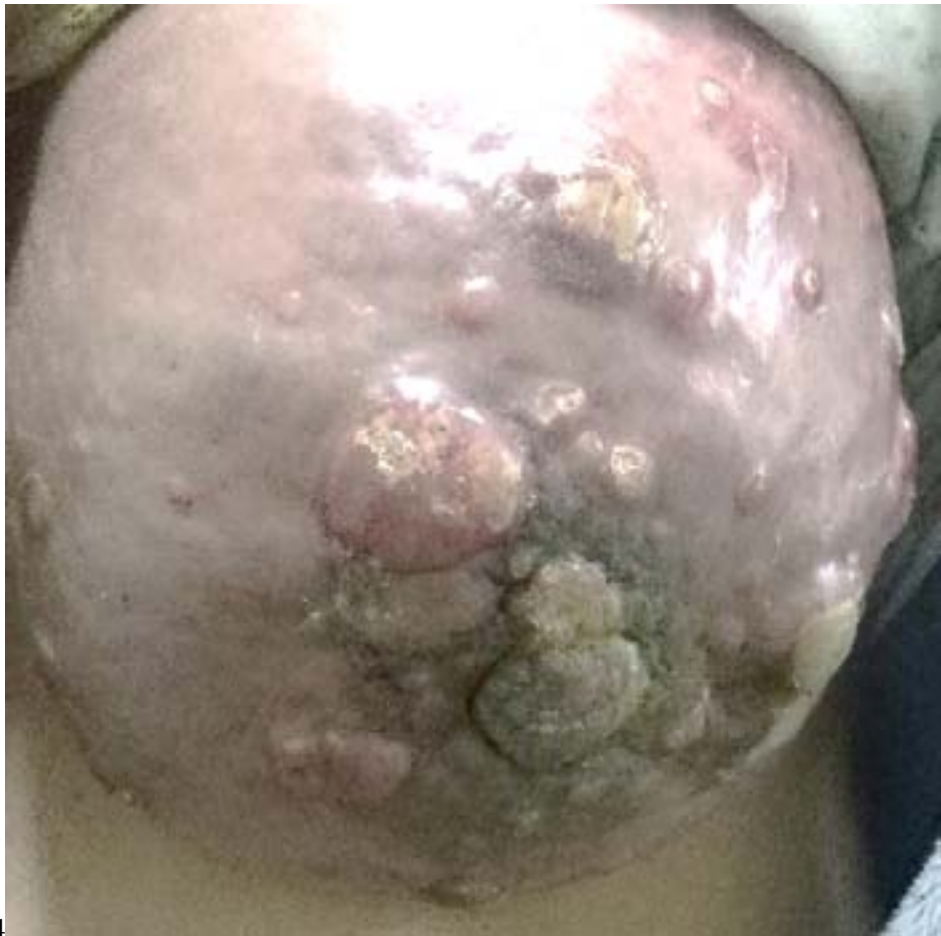
8 Conclusion

All efforts must be taken to detect PABC at an early stage and avoid such delays in the treatment of this challenging set of patients. Cancer-associated with pregnancy represents a unique clinical scenario that requires a delicate balance of risks and benefits for both maternal and fetal well-being, as well as a multidisciplinary discussion and close monitoring by an expert team.



1

Figure 1: Fig. 1 :



4

Figure 2: Fig. 4 :

[Navrozoglou et al.] , I Navrozoglou , T Vrekoussis , E Kontostolis .

[Tewari et al. ()] ‘Ambiguous genitalia in infant exposed to tamoxifen in utero’. K Tewari , R G Bonebrake , T Asrat , A M Shanberg . *Lancet* 1997. 350 p. 183.

[Lenhard et al. ()] ‘Breast cancer and pregnancy: Challenges of chemotherapy’. M S Lenhard , I Bauerfeind , M Untch . *Crit. Rev. Oncol* 2008. 67 p. .

[Dousias et al. ()] ‘Breast cancer during pregnancy: a mini review’. V Dousias , S Zervoudis , E N Stathopoulos , O Zoras , E Paraskevidis . *Eur J Surg Oncol* 2008. 34 (8) p. .

[Stearns et al. ()] ‘Breast cancer treatment and ovarian failure: risk factors and emerging genetic determinants’. V Stearns , B Schneider , N L Henry . *Nat Rev Cancer* 2006. 6 p. .

[Loibl and Von Minckwitz ()] ‘Breast carcinoma during pregnancy International recommendations from an expert meeting’. S Loibl , G Von Minckwitz , GwynK . *Cancer* 2006. 106 (2) p. .

[Cancer du sein infiltrant non metatstatiquequestion d’actualité ()] *Cancer du sein infiltrant non metatstatique-question d’actualité*, 2012.

[Van Calsteren K 1 et al. (2010)] ‘Cancer during pregnancy: an analysis of 215 patients emphasizing the obstetrical and the neonatal outcomes’. Van Calsteren K 1 , L Heyns , De Smet , F . *J Clin Oncol* 2010 Feb 1. 28 (4) p. .

[Myers et al. ()] ‘Imaging appearance and clinical impact of preoperative breast MRI in pregnancy-associated breast cancer’. K S Myers , L A Green , L Lebron , E A Morris . *AJR* 2017. 209 p. .

[Andersson et al. ()] ‘Increasing incidence of pregnancy-associated breast cancer in Sweden’. T M Andersson , A L Johansson , C C Hsieh , S Cnattingius , M Lambe . 10.1097/AOG.0b013e3181b19154. <https://doi.org/10.1097/AOG.0b013e3181b19154> *Obstet. Gynecol* 2009. 114 p. .

[Azim and Jr ()] *Managing Cancer during Pregnancy*, H A Azim , Jr . 2016. Cham, Switzerland: Springer.

[Chabbert-Buffet N 1 , Uzan et al. (2010)] ‘Pregnancy after breast cancer: a need for global patient care, starting before adjuvant therapy’. C Chabbert-Buffet N 1 , Uzan , J Gligorov , S Delalogue , R Rouzier , S Uzan . *Surg Oncol* 2010 Mar. 19 (1) p. .

[Lawrenz ()] ‘Pregnancy after breast cancer: case report and review of the literature’. B Lawrenz , M . *Arch Gynecol obstet* 2011. 283 p. .

[Averette et al. ()] ‘Pregnancy after breast carcinoma: The ultimate medical challenge’. H E Averette , R Mirhashemi , F L Moffat . *Cancer* 1999. 85 p. .

[Cardonick ()] ‘Pregnancy associated breast cancer: optimal treatment options’. E Cardonick . *Int J Women’s Health* 2014. 6 p. .

[Jafari et al. ()] ‘Pregnancy-associated Breast Cancer: A Review of Imaging Modalities’. M Jafari , M Gity , A Olfatbakhsh , K Rezaei-Alantari , E A Hashemi . *Int. J. Cancer Manag* 2018. p. e65444.

[Sechopoulos et al. ()] ‘Radiation dose to organs and tissues from mammography: Monte Carlo and phantom study’. I Sechopoulos , S Suryanarayanan , S Vedantham , C J D’orsi , A Karellas . *Radiology* 2008. 246 p. .

[Pavlidis and Pentheroudakis ()] ‘The pregnant mother with breast cancer: diagnostic and therapeutic management’. N Pavlidis , G Pentheroudakis . *Cancer Treat Rev* 2005. 31 (6) p. .

[Keleher et al. ()] ‘The safety of lymphatic mapping in pregnant breast cancer patients using Tc-99m sulfur colloid’. A Keleher , R Wendt , E Iii;Delpassand , A M Stachowiak , H M Kuerer . *Breast J* 2004. 10 p. .

[Zagouri et al. ()] ‘Trastuzumab administration during pregnancy: A systematic review and meta-analysis’. F Zagouri , T N Sergentanis , D Chrysikos , C A Papadimitriou , M A Dimopoulos , R Bartsch . *Breast Cancer Res. Treat* 2013. 137 p. .

[Amant et al. ()] ‘Van Calsteren, K. Breast cancer in pregnancy’. F Amant , S Loibl , P Neven . *Lancet* 2012. 379 p. .