



GLOBAL JOURNAL OF MEDICAL RESEARCH: J  
DENTISTRY & OTOLARYNGOLOGY  
Volume 20 Issue 3 Version 1.0 Year 2020  
Type: Double Blind Peer Reviewed International Research Journal  
Publisher: Global Journals Inc. (USA)  
Online ISSN: 2249-4618 & Print ISSN: 0975-5888

## Incidence and Outcome of Second Brachial Cleft Anomalies: A Three Years Experience and Appreciation

By Delwar AHM

**Abstract- Background:** Second branchial cleft anomalies are remarkable of all other inborn errors of branchial apparatus. As a congenital, it may be presented at birth but usually manifests in early teenagers and young adults. Like all other inborn errors, it is better to correct earlier before suffering from any complications.

**Methods:** It is a cohort retrospective study of 15 cases in the Department of Otolaryngology and Head-Neck Surgery, Cumilla Medical College, and Cumilla Medical Centre, Bangladesh, from 01 July 2016 to 31 June 2019.

**Results:** Incidence of anomalies among routine ENT operations was 0.21%. Of 15, the cyst was 04(26.27%), sinus was 10(66.66%), the fistula was 1(6.67%), children were 09(60%), the adult was 6(40%), and young adult and an early teenager were 07(46.66%), male was 11(75.33%), and females were 04(26.27%), bilateral were 2(13.33%), unilateral was 13(86.67%) in which right was 10(76.33%), and left was 03(23.08%), painful cyst with abscess was 01(6.67%), the painless cyst was 03(20%), sinus with the mucoid fluid discharge was 07(46.68%), painful sinus with mucopurulent discharge and skin-excoriation was 03(20%), painful fistula with mucopurulent discharge and skin-excoriation was 01(6.67%), post-operative wound infection was 2(13.33%). Recurrence and the branchio-oto-renal syndrome were absent in our study.

**Keywords:** second brachial cleft anomalies (SBCA), cyst, sinus, fistula.

**GJMR-J Classification:** NLMC Code: QS 675



*Strictly as per the compliance and regulations of:*



# Incidence and Outcome of Second Brachial Cleft Anomalies: A Three Years Experience and Appreciation

Delwar AHM

**Abstract- Background:** Second branchial cleft anomalies are remarkable of all other inborn errors of branchial apparatus. As a congenital, it may be presented at birth but usually manifests in early teenagers and young adults. Like all other inborn errors, it is better to correct earlier before suffering from any complications.

**Methods:** It is a cohort retrospective study of 15 cases in the Department of Otolaryngology and Head-Neck Surgery, Cumilla Medical College, and Cumilla Medical Centre, Bangladesh, from 01 July 2016 to 31 June 2019.

**Results:** Incidence of anomalies among routine ENT operations was 0.21%. Of 15, the cyst was 04(26.27%), sinus was 10(66.66%), the fistula was 1(6.67%), children were 09(60%), the adult was 6(40%), and young adult and an early teenager were 07(46.66%), male was 11(75.33%), and females were 04(26.27%), bilateral were 2(13.33%), unilateral was 13(86.67%) in which right was 10(76.33%), and left was 03(23.08%), painful cyst with abscess was 01(6.67%), the painless cyst was 03(20%), sinus with the mucoid fluid discharge was 07(46.68%), painful sinus with mucopurulent discharge and skin-excoriation was 03(20%), painful fistula with mucopurulent discharge and skin-excoriation was 01(6.67%), post-operative wound infection was 2(13.33%). Recurrence and the branchio-oto-renal syndrome were absent in our study.

**Conclusion:** Surgery is the treatment modalities of second branchial cleft anomalies. Infected cases should treated first medically to control the infection then make a plan for operation.

**Keywords:** second brachial cleft anomalies (SBCA), cyst, sinus, fistula.

## 1. INTRODUCTION

A child, teenagers or young adult with a congenital cyst, or sinus, or fistula in the head or neck region is the occasional patient for the ENT Surgeon. Second branchial cleft anomalies(SBCA) is a sporadic disease entity but 95% of all branchial abnormalities.<sup>1</sup> In the fourth week of an embryo, surrounding the primitive pharynx or cephalic part of the foregut, six pairs of condensation appear in the form of branchial or visceral arches. There is depression both inside and outside of the arches in which inside line by ectoderm is known as a branchial or pharyngeal pouch and outside by

ectoderm is known as branchial or pharyngeal cleft. Between the two is the cleft membrane or mesoderm of the branchial arch with internally lined by columnar and outside with squamous epithelium. Each branchial arch has a central plate of cartilage, which gives rise to bone, a muscle mass, a nerve, supply to the same derivatives of it, and an artery. The Fifth arch disappears, and the sixth arch is rudimentary. The brachial cyst is a persistent cervical sinus due to the fusion of overgrowing second branchial arch with the sixth arch. Usually this sinus disappears. If it persists, accumulation of the secretion from the appendage of the ectodermal lining of sweat and sebaceous glands occurs inside the sinus and gives rise to a cystic swelling called a branchial cyst. Sometimes the second arch fails to fuse with the sixth arch and gives rise to brachial sinus and fistula.<sup>2</sup> There are some other theories to form the cyst and sinus, which are branchial apparatus, hypopharyngeal and inclusion theory. The well accepted one is the brachial anomalies result from incomplete involution of the brachial apparatus. The Second branchial arch forms the epidermis of the dorsal pinna and upper part of the neck. The branchial cyst usually lies superficial to the structures developed from the second and third arches, which are the lesser cornu of the hyoid bone, posterior belly of digastrics muscles, facial nerve, and external carotid artery. Another theory describes that the mesoderm forms the facial muscles and the body of the hyoid bone, and the endodermal elements from the root of the tongue, the foramen caecum, the thyroid stalk, and the tonsil. The second branchial cleft sits immediately caudal to these structures, and it is the persistence of this cleft that leads to the formation of the second branchial cyst, and sinus.<sup>3</sup> SBCA may form the part of the branchio-oto-renal syndrome.<sup>4,5</sup> The second branchial cyst may be infected to an abscess, consequently automatically bursting or giving inadvertent incision to draining the pus leading to the formation of a sinus or fistula.<sup>1</sup> There is some differential diagnoses related to SBCA like a tubercular cold abscess, cervical dermoid, plunging ranula, cystic hygroma, carotid body tumor, cervical lymphadenopathy, and submandibular salivary gland swelling. In 1929 Baily H. classify the SBCA into four types, which provide the information for clinical diagnosis and surgical planning of unusually placed

**Author:** MBBS, DLO, MCPS (ENT), MRCPS (Glasgow), UK. Associate Professor of Otolaryngology, Cumilla Medical College, Bangladesh.  
e-mail: mamun.delwar196@gmail.com

cyst, sinus, or fistula: 1. Deep to the platysma, anterior to sternocleidomastoid-. 2. Abutting the internal carotid artery adherent to internal jugular vein (most common). 3. Extending between internal and external carotid arteries. 4. Abutting pharyngeal wall and potentially extending superiorly to the skull base.<sup>6</sup> The external opening of the sinus and fistula may present as a congenital opening in the junction of lower one third and upper two-third anterior to sternocleidomastoid muscle directed proximally and medially to pass the carotid fork extending to communicate with the pharynx through the palatine tonsil to form a fistula.<sup>7</sup> Usually, the sinus or fistula tract leaks clear mucous secretion, sometimes they are infected, and consequently, the formation of an abscess occurs in early infancy, requires intravenous antibiotic and surgical drainage.<sup>8</sup> The SBCA presented unilaterally, sometimes may be presented bilaterally.<sup>9</sup> As a rule with SBCA, the diagnosis is evident, and no further investigations are required. But some cases of studies showed that the reliability of clinical examination was 50-60%.<sup>10</sup> The surgical excision of the complete tract is the option of the treatment of SBCA. Surgical anatomy of the branchial apparatus should understand clearly as the internal jugular vein, hypoglossal nerve, facial nerve, and parotid gland closely related to the tract.

The study finds out relative incidence, frequency, and presentation of SBCA, and the best management of it.

## II. METHODS AND MATERIALS

It is a cohort retrospective study of 15 cases in the Department of Otolaryngology and Head-Neck Surgery, Cumilla Medical College, and Cumilla Medical Centre (PVT) LTD, which is a concern clinic of Central Medical College, Cumilla, Bangladesh from 01 July 2016 to 31 June 2019. During three years period, 7099 routine ENT operations were performed. Among 15, the cyst was 04; sinus was ten, and fistula was 01. All 15 patients were clinically diagnosed as SBCA and confirmed by history, examination, and investigation such as USG of the neck, and renal system, sinogram, FNAC, and MRI whichever were need. The following data collected about the patients: Age, sex, side, presenting features, post-operative follow-up, and complications. Statistical software SAS used to calculate all data. All cases of neck swelling diagnosed as SBCA included in the study. All other cases present with neck swelling like a tubercular cold abscess, cervical dermoid, plunging ranula, cystic hygroma, carotid body tumor, cervical lymphadenopathy, and submandibular salivary gland swelling excluded from the study. Branchio-oto-renal syndrome was absent in our study.

## III. RESULTS

Incidence of SBCA, out of routine ENT operations, was 0.21% (Chart-1). Of 15, cyst was 4(26.67%), sinus 10(66.66%), fistula 01(6.67%), male were 11(73.33%), and females were 4(26.67%) (Figure-1). Considering from 15, unilateral was 13(86.67%) in which right was 10(76.92%), and left 03(23.08%), and bilateral was 02(13.33%) (Figure-2). We studied the age of two categories. Firstly, children (00-18 years) were 09(60%), and adults (19 years and above) were 06(40%). Secondly, children below early teenage 00-10 years were 04(26.67%), early teenage, and young adult 11-30 years were 07(46.66%), and 31years, and above were 04(26.67%) whereas the lowest age was 05 years and highest was 55 years, mean age was 21.13 years and the standard deviation was 19.13 (Figure-3). Presenting features exhibited, painful cyst with abscess formation was 01(6.67%), painless cyst 03(20%), sinus with the mucoid discharge was 07(46.66%), sinus with mucopurulent discharge and skin excoriation 03(20%), and fistula with mucopurulent discharge and skin excoriation was 01(6.67) (Figure-4). Regarding investigations, ultrasonography of neck and the renal system performed all 15(100%) cases, sinogram 11(73.33%) cases, FNAC 04(26.67%) cases, and MRI 02(13.33%) bilateral cases (Figure-5). CT scans in children wasn't doing due to more exposure to ionizing radiation. All cases treated surgically through stepladder incision externally and one cases complete fistula both externally excision of fistulas tract, and internally tonsillectomy did per orally (Figure-6). 02(13.33%) cases suffered wound infection after surgery (Figure-5). Post-operative recurrence was absent in our study.

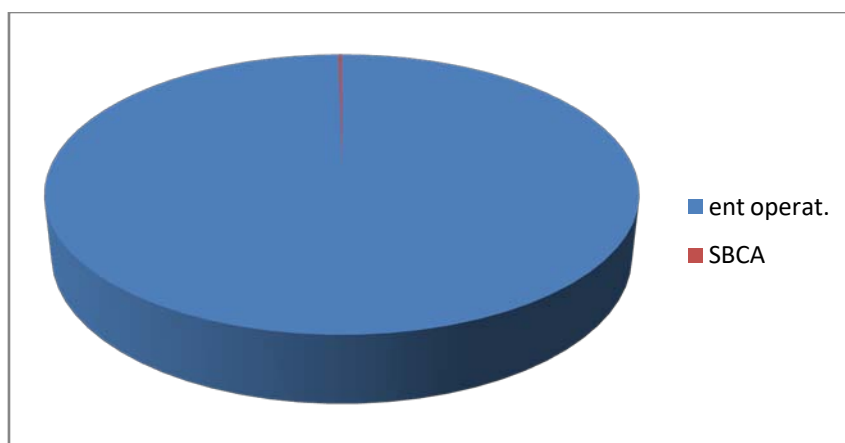


Chart-1: ENT operations and SBCA (n-7099;SBCA-15:0.21%)

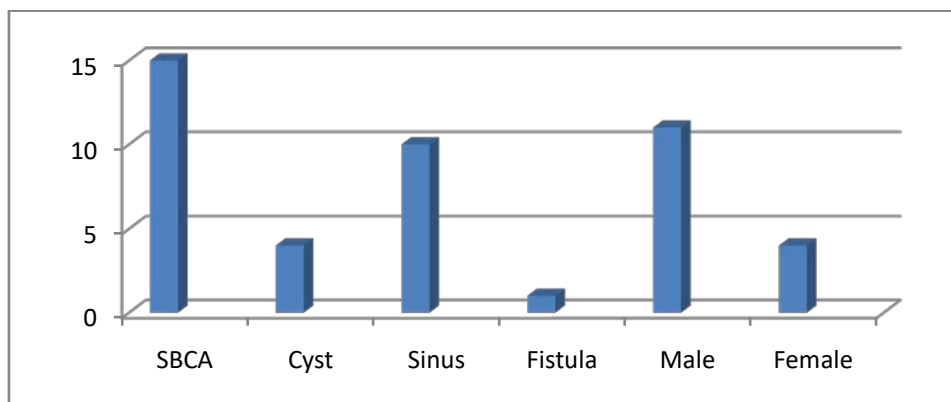


Figure-1: Types & Gender epidemiology: [n-15;cyst-4(26.67%):sinus-10(66.66%):fistula-1(6.67%):male-11(73.33%):female-4(26.67%)]

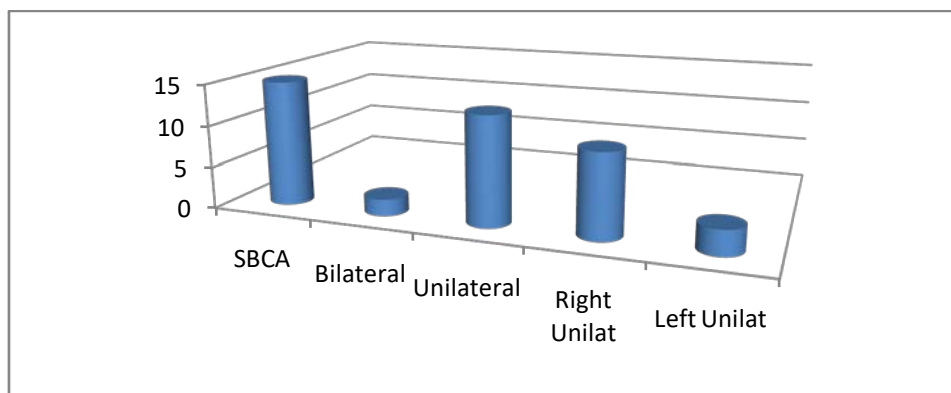
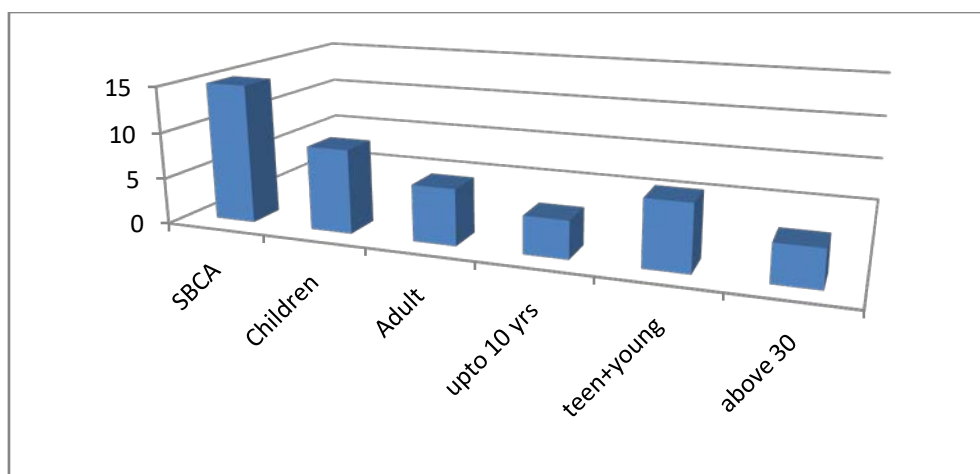
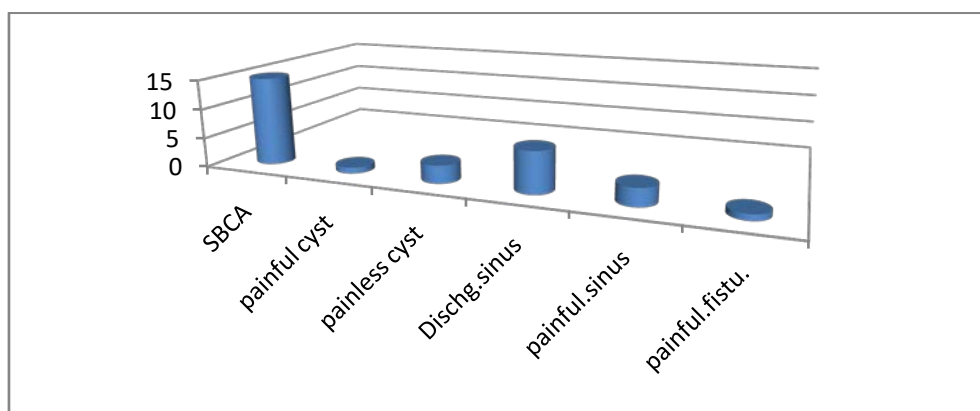


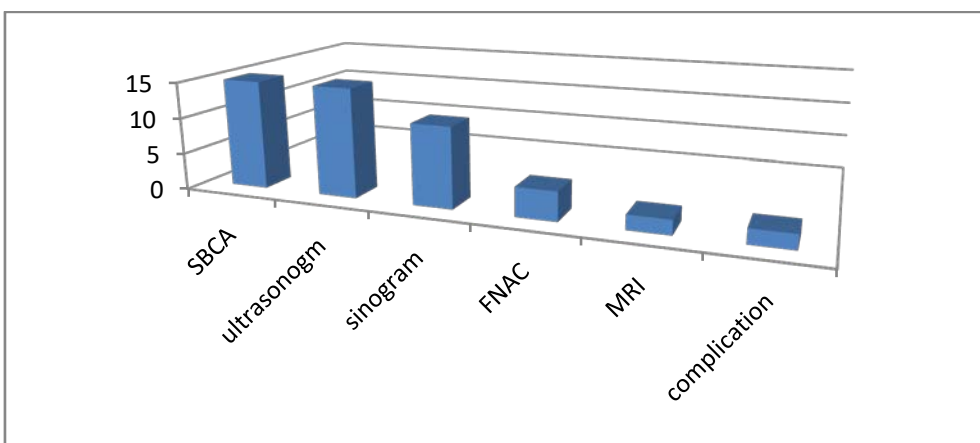
Figure-2: Side and Laterality: [n-15;bilateral-2(13.33%):Unilateral-13(86.67%):Right unilateral-10(76.92%): Left unilateral-3(23.08%)]



*Figure-3:* Age allocation:[n-15;Children-9(60%):Adult-6(40%):Children( 0-10)yrs-4(26.67%):Early teen & young adult(11-30)yrs-7(46.66%):Adult above 30yrs-4(26.67%)]



*Figure-4:* Presenting features:[n-15;painful cyst with abscess-1(6.67%):painless cyst-3(20%):painless sinus with mucoid discharge-7(46.66%):painful sinus -3(20%):painful fistula-1(6.67%)]



*Figure-5:* Investigation & complication:[n-15;ultrasonogram-15(100%):sinogram-11(73.33%):FNAC-4(26.67%):MRI-2(13.33%):complication-2(13.33%)]



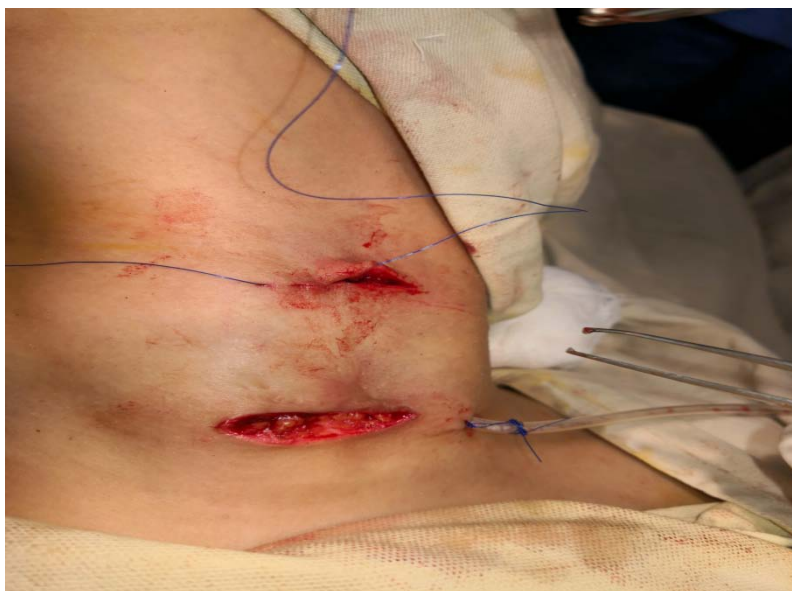

Figure-6: Picture of stepladder incision

#### IV. DISCUSSION

Branchial apparatus abnormalities were well-known from the eighteenth century. Ascherson first described the branchial cyst in 1832 and established the most common theory that the formation of the branchial cleft is the defective obliteration of branchial apparatus.<sup>11</sup> All were near to one another. Other's are cervical sinus theory, hypopharyngeal theory and inclusion theory.<sup>12</sup>

The incidence of SBCA was 0.21% in routine operation. In the two institutions, we found only 15 patients in three years, which supported by Mitroi M. et al. series, they found 23 patients in six years, Kalra VK. et al. also held up our study, showed 94 cases for ten years.<sup>13,14</sup>

Regarding the type of SBCA sinus was the highest 66.66% and the cyst was the second most common type, 26.67% in our literature, which supported by Choi SS. et al., established maximum incidence of sinus followed by fistula.<sup>12</sup> Whereas Telander RL. et al. were against our series; they reported 75% was cyst followed by fistula and sinus.<sup>15</sup>

Concerning the age, mean age was 21.13 years in our report, which was opposite to Karabulut R. et al., they displayed the mean age was 5.30.<sup>16</sup> Choi SS. et al. series kept up our report, they exhibited the mean age was 18.35 years.<sup>12</sup> Early teenager and young adult were 46.66% in our study, supported by Keith GT. et al.<sup>3</sup> Mitroi M. et al. showed most cases were in 2<sup>nd</sup> and 3<sup>rd</sup> decade, replicated our study.<sup>13</sup>

Gender epidemiology showed in our series of males (73.33%) were near three times more than females (26.67%), supported Simpson RA. et al. reported male, females ratio was 3:1.<sup>17</sup> Faerber EN. et

al. study revealed that there was no gender predilection.<sup>18</sup>

In our series, right unilateral was 76.92%, supported Ford GR. et al., they reported 60% on the right side, Kalra VK. also showed right preponderance was 65.95%.<sup>19,14</sup> Agaton-Bonilla FC. et al. showed bilateral SBCA were 1-30% that complemented our study that was 13.33%.<sup>20</sup>

Regarding presenting features, in our study, painful cyst with abscess was 6.67%, painful sinus with the muco-purulent discharge 20%, painful fistula with secretion 6.67%, the painless sinus with mucous production 46.66%, the painless cyst was 20%, total infected was 33.34%, and uninfected was 76.66%, supported Ford GR. et al. series displayed repeated discharge from the opening, and infection of cervical mass.<sup>19</sup> Som P. also held up our study, reported that small mass or opening usually one side of neck rarely bilateral, painless and painful if inflammation.<sup>21</sup>

About investigations, ultrasonography did in 100% of our cases, which carried out Bruneton JN. et al. study who described that with modern high-resolution transducers, one could evaluate the internal architecture of lesion.<sup>22</sup> Sinogram did 73.33%(11) of cases, which kept up Celis I. et al. series which reported pre-operative sonogram helps define the anatomy of a sinus or fistula.<sup>23</sup> FNAC did our 26.67%(4) cases that Benson MT. et al. reported the confirmation of cyst by pathological characteristics, usually cyst filled with turbid, yellowish fluid that may contain cholesterol crystal, thin-walled, lined by stratified squamous epithelium, sometimes columnar respiratory epithelium.<sup>24</sup> MRI did in 13.33%(2) cases, Miller MB. Reported that MRI imaging better depicts the extent of SBCA into tissue, which allows accurate pre-operative surgery planning.<sup>25</sup>

Treatment of SBCA is surgical excision on the uninfected neck; if infection, after control of it, surgery should be planned, supported Daoud FS. Series.<sup>26</sup> Several surgical approaches described by Mandell DL. and Agaton-Bonilla FC. stepladder incision or wide cervicotomy incision known as hockey stick incision to excision of SBCA.<sup>27,20</sup> We practiced stepladder incision, and in one case, complete fistula, externally fistulous tract, and tonsillectomy did per-orally. To proper delineating the course of the sinus or fistula we used in Methylene blue, which practiced kalra VK. et al.<sup>14</sup> We followed-up the patient up to six months every monthly, recurrence didn't find out during the period, but Ford GR. And Prasad SC. et al. reported a 3% and 1.2% recurrence rate accordingly.<sup>19,28</sup>

Post-operative wound infection was 13.33% in our study, whereas Prasad SC. et al. represented 14.71% close to our series.<sup>28</sup> It was due to that one of the patient was diabetic and another one needful and un-lettered, and unaware about post-operative cleanliness and safety. We were admitted to the patients in the hospital for regular dressing, and start intravenous antibiotics, controlled diabetes, healed the wound without any eventful consequence.

## V. CONCLUSION

Though sporadic, SBCA is one of the remarkable congenital anomalies of the head and neck region. Surgical excision of the tract is the aim of treatment due to the risk of repeated infection. Surgery can perform at any age. Care should take to identify and avoiding injury the vital structures like the lingual nerve, facial nerve, parotid gland, internal jugular vein, and hypoglossal nerve.

*Funding:* No funding sources.

*Conflict of interest:* None declared.

*Ethical approval:* The study was approved by the Institutional Ethics Committee.

## REFERENCES RÉFÉRENCES REFERENCIAS

- Acinero SP, Waldhausen JHT. Congenital cervical cysts, sinuses and fistula. *Otolaryngol Clin North Am.* 2007; 40:161-176.
- Silverberg SG. Silverberg's Principle and Practice of Surgical Pathology and Cytopathology. 4<sup>th</sup> ed, New York; Churchill living stone-Elsevier: 2006.
- Keith G. Trimble and Luke McCadden. Cysts and Sinuses of the Head and Neck. Scott-Brown's Otorhinolaryngology Head & Neck Surgery, 8<sup>th</sup> edition, Volume-2, Section-1, Chapter; 41:page-467.
- Chen A, Francis M, Ni L, Cremers CW, Kimberling WJ, Sato Y. Phenotypic manifestation of branchio-oto-renal syndrome. *American Journal of Medical Genetics.* 1995; 58:365-70.
- Kemperman MH, Stickens C, Kumar S, Joosten FB, Huygen PL, Cremers CW. The branchio-oto-renal syndrome. *Advances in Oto-Rhino-Laryngology.* 2002; 61:192-200.
- Baily H. Branchial cysts and others essays on surgical subjects in the facio-cervical region. London; 1929.
- Sedguick CE, Walsh J. Branchial cysts and fistulas. *Am J Surgery.* 1952; 83:3-8.
- Waldhausen JH. Branchial cleft and arch anomalies in children. *Semin Pediatr. Surg.* 2006; 15(2):64-69.
- Singh AP, Kumar V, Narula V, Meher R, Raj A. Bilateral first and second arch anomalies: A rare presentation. *Singapore Med. J.* 2012; 53:74-6.
- Neel HB, Pemberton J. Lateral cervical cysts and fistulas surgery. 1945; 18:653-659.
- Golledge J, Ellis H. The etiology of lateral cervical (Branchial) cysts: Past and present theories. *J Laryngol Otol.* 1994; 108(8):653-659.
- Choi SS, Zalal GH. 'Branchial anomalies: a review of 52 cases'. *Laryngoscope.* 1995; 105(9-1):909-913.
- Mitroi M, Dumitrescu D, Simionescu C, Popescu C, Mogoanta C, Cioroianu L, Surlin C, Capitanescu A, Georgescu M. Management of second branchial cleft anomalies. *Romanian Journal of Morphology and Embryology.* 2008; 49(1):69-74.
- Kalra VK, Rattan NK, Yadav SPS, Bhukar S, Dheeraj S. Second Branchial Anomalies: A study of 94 Cases. *Indian J Otolaryngol Head Neck Surg.* December, 2017; 69(4):540-543.
- Telander RL, Filston HC. Review of head and neck lesions in infancy and childhood. *Surgery Clin North Am.* 1992; 72(6):1429-1447.
- Karabulut R, Sonmez K, Turkyilmaz Z, Ozen IO, Demirogullari B, Guclu MM, Basaklar AC, Kale N. Second branchial anomalies in children. *J Otorhinolaryngol Relat Spec.* 2005; 67:160-162.
- Simpson RA. Lateral cervical cysts and fistulae. *Laryngoscope.* 1969; 79:30-59.
- Faerben EN, Swartz JD. Imaging of neck masses in infants and children. *Crit Rev Diagn Imaging.* 1991; 31(3-4):283-314.
- Ford GR, Balakrishnan A, Evans ING, Bailay CM. Branchial cleft and pouch anomaly. *Journal of Laryngology and Otology.* 1992; 106(2):137-143.
- Agaton-Bonilla FC, Gay-Escoda C. Diagnosis and treatment of brachial cleft and pouch anomalies: A retrospective study of 183 patients. *Int J Oral Maxillofac Surg.* 1996; 25:449-452.
- Som P. Cystic Lesions of the neck. *Postgrad Radiol.* 1987; 7:211-236.
- Bruneton JN, Fenart D. Other cervical sites: Ultrasonography of the neck. *Int Bruneton Jn. Ed.* Berlin. Springer-Verlag; 1987:93-106.
- Celis I, Bijmens E, Cleeren P. The use of pre-operative fistulography in patients with a second

- branchial cleft anomaly. *Eur Radiol.* 1998; 8:1179-1180.
24. Benson MT, Dalen K, Mancuso AA, Kerr HH, Cacciarelli AA, Mafee MF. Congenital anomalies of the branchial apparatus: Embryology and pathologic anatomy. *Radiographics.* 1992; 12(5): 943-960.
  25. Miller MB, Rao VM, Tom BM. Cystic masses of the head and neck: Pitfalls in CT and MRI interpretation. *AJR Am J Roentgenol.* 1992; 159(3):601-607.
  26. Daoud FS. Branchial cyst: An often forgotten diagnosis. *Asian J Surg.* 2005; 24(3):174-178.
  27. Mandell DL. Head and Neck anomalies related to the branchial apparatus. *Otolaryngologic Clinics of North America.* 2000; 33(6):1309-1332.
  28. Prasad SC, Azeez A, Thada ND, Rao A, Bacciu A, Prasad KC. Clinical, Branchial Anomalies: Diagnosis and management. *International Journal of Otolaryngology.* 2014; ID-237015:01-09. <http://dx.doi.org/10.1155/2014/237015>.

