



GLOBAL JOURNAL OF MEDICAL RESEARCH: J  
DENTISTRY & OTOLARYNGOLOGY  
Volume 20 Issue 5 Version 1.0 Year 2020  
Type: Double Blind Peer Reviewed International Research Journal  
Publisher: Global Journals Inc. (USA)  
Online ISSN: 2249-4618 & Print ISSN: 0975-5888

# Perichondritis of the Pinna: A Real Compulsion of Hospital Linger

By Delwar AHM

**Abstract- Background:** Perichondritis of pinna is relentless, deadly cellulitis of the auricular cartilage, which may lead to necrosis. As a result, shrinkage and deformity of the pinna may occur. Different etiological factors, including self-trauma by high ear piercing for beauty and fashion, accident, assault, infections, progressive otitis externa, and allergy, are mentionable. **Methods:** It is a cohort retrospective study of 63 cases in the Department of Otolaryngology and Head-Neck Surgery, Cumilla Medical College, and Cumilla Medical Centre, Bangladesh, from 01 July 2016 to 31 June 2019.

**Results:** The incidence of perichondritis among ENT casualty was 0.86%. Off 63, the male was 33 (52.38%), and the female 30 (47.62%), children were 27 (42.86%), and adult 36 (57.14%), in which lowest age 02 years, highest 76, mean age 21.952, and the standard deviation 16.676, diabetic 08 (12.70%), smoker 09(14.29%), and all were unilateral.

**Keywords:** perichondritis, piercing, exploration, debridement, scooping, and curettage.

**GJMR-J Classification:** NLMC Code: WV 200



*Strictly as per the compliance and regulations of:*



# Perichondritis of the Pinna: A Real Compulsion of Hospital Linger

Delwar AHM

**Abstract- Background:** Perichondritis of pinna is relentless, deadly cellulitis of the auricular cartilage, which may lead to necrosis. As a result, shrinkage and deformity of the pinna may occur. Different etiological factors, including self-trauma by high ear piercing for beauty and fashion, accident, assault, infections, progressive otitis externa, and allergy, are mentionable. **Methods:** It is a cohort retrospective study of 63 cases in the Department of Otolaryngology and Head-Neck Surgery, Cumilla Medical College, and Cumilla Medical Centre, Bangladesh, from 01 July 2016 to 31 June 2019.

**Results:** The incidence of perichondritis among ENT casualty was 0.86%. Off 63, the male was 33 (52.38%), and the female 30 (47.62%), children were 27 (42.86%), and adult 36 (57.14%), in which lowest age 02 years, highest 76, mean age 21.952, and the standard deviation 16.676, diabetic 08 (12.70%), smoker 09(14.29%), and all were unilateral. Etiological factors revealed post-traumatic was 18 (28.57%) in which high ear piercing 11 (17.46%), and accident and assault 07 (11.11%), furunculosis 12 (19.05%), post-infective 09 (14.29%), allergy due to hair color 06 (9.53%), and others were herpes zoster oticus, malignant otitis externa, post-operative, and insect bite. Presenting features exhibited earache was 61 (98.83%), red, hotness and stiffness of pinna 59 (93.65%), and auricular abscess 36 (57.14%). Culture and sensitivity test showed *Pseudomonas aeruginosa* was 58.33%, *Staphylococcus aureus* 41.67%, and others were *Streptococcus*, *Proteus*, *Enterococcus*, and *E coli*. Treatment included conservative was 27 (42.86%), whose treatment continued through out-patient department service, and surgical 36 (57.14%). Complications produced minor deformity was 23.81%, and major 11.11%. the hospital stayed, one to two weeks was 42.22%, three to four weeks 16.67%, and more than five weeks 36.11%.

**Conclusion:** Prevention and early treatment lowering the immensity of the disease.

**Keywords:** perichondritis, piercing, exploration, debridement, scooping, and curettage.

## I. INTRODUCTION

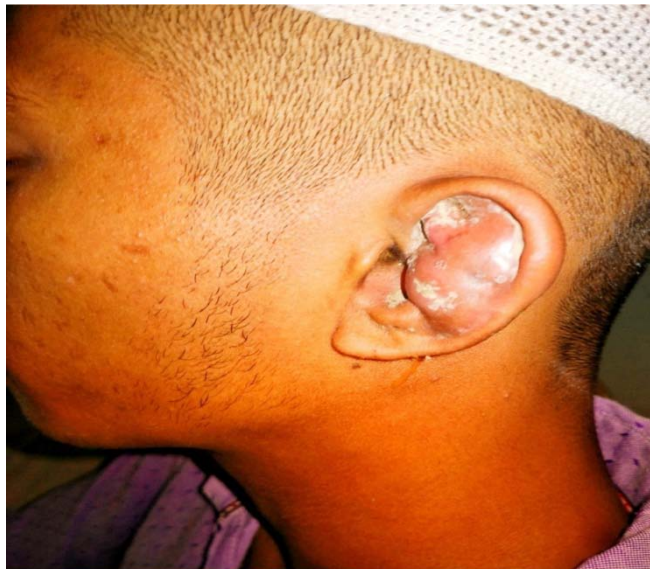The pinna projects at a variable angle as a fan-like formation from the side of the head and perform the collecting of sound. The unique pattern of it is comparable with fingerprint and can allow the identification of persons on the physiognomy of their auricles [1]. The body of the pinna is formed of a single piece of yellow elastic fibro-cartilage and is a continuous plate except for a narrow gap between the tragus and the helix. The cartilage of the auricle covers with perichondrium from which it derives its supply of nutrients, as cartilage itself is avascular. High ear piercing, accident or assault makes injury of the pinna, and stripping of perichondrium, which causes hematoma may lead to necrosis of cartilage with crumpled up 'boxer's ear, pugilistic or cauliflower ear [2]. The sequelae of inflammation of the pinna described by James W. Loock into four stages: 1. Erysipelas, 2. Cellulitis, 3. Perichondritis, 4. Chondritis [3]. Perichondritis is mainly traumatic, which includes lacerations of the pinna, surgery of external auditory canal, frost bite, insect bite, burns, infected hematoma Auris, incision, or aspiration for hematoma of the pinna, and in recent years high ear piercing for wearing fashionable ornaments [4]. In the process of perichondritis, various types of bacterial invasion occur. The most common organisms were *Pseudomonas aeruginosa* (69%) [5], Polymicrobial (22%), *Streptococcus* spp. (22%), *Staphylococcus aureus* (20%), and other Gram-negative organisms include *Proteus*, *Enterococcus*, and *Escherichia coli* [6], [7]. Body piercing is popular after 1990, which was done by well known singer Michael Jackson, Madonna, and so many Hollywood stars. The teenager and young adult following them piercing the Tongue, Lips, Eyebrows, Nose, Nipple, Umbilicus, and Genitalia [8], [9],[10]. Body piercing is one of the religious or rituals of mysticism to God in some countries of Asia and Latin America from teenager to adulthood. The procedure usually did by an untrained person; as a consequence, healing of the wound various from one month to one year [11]. The pathological process of perichondrium of pinna following hyperplasia of skin, thickened subcutaneous tissue, thickening of perichondrium by infiltration, and destruction of cartilage by phagocytes [12]. The classical presentation of the perichondrium of the pinna is severe earache, erysipelas, cellulitis, and auricular

**Corresponding Author:** MBBS, DLO, MCPS (ENT), MRCPS (Glasgow), UK, Associate Professor of Otolaryngology, Cumilla Medical College, Bangladesh. e-mail: mamun.delwar196@gmail.com

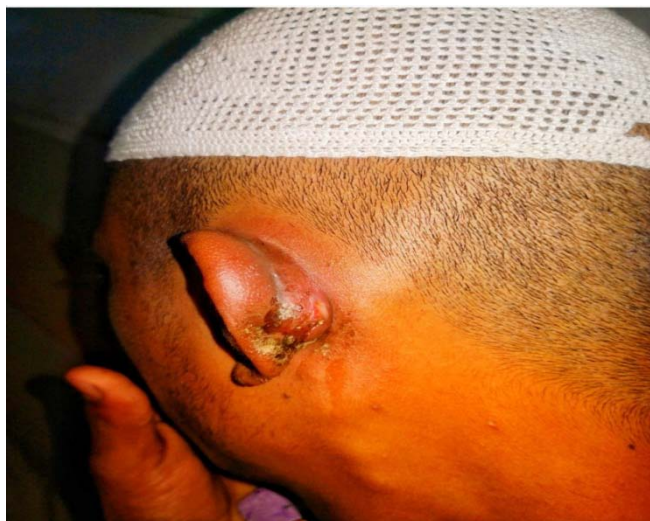
abscess, so diagnosis is clinical and special investigation aren't required routinely [3]. Some systemic disease related to perichondritis which includes Relapsing Perichondritis [13], non-Hodgkin lymphoma of pinna with or without immunodeficiency state [14], [15]. Different types of management options described by the surgeons depending on the staging of perichondritis. Stage of erysipelas and early cellulitis adequately managed by the use of a topical, and high doses of oral and parental antibiotics may halt the progression of disease due to *Pseudomonas aeruginosa* [16]. Some surgeons practiced minimum invasive procedures like aspiration of infected edematous fluid, syringing the cavity two to three times daily with streptomycin solution [17]. It is difficult to decide how much cartilage to excise, and frequent consecutive debridement to prevent the deformity of the pinna. Many surgeons suggested aggressive excision of

necrotic cartilage, including overlying skin and subcutaneous tissue [18] [19]. In severe cases, James W. Look, and Dowling et al. practiced total corpectomy via an incision in the helical margin, the ear splits in bivalve fashion, the necrotic cartilage removed, and a layer of fine mesh gauze placed between the flap and changed daily [3],[20]. Another group of surgeons applied fenestrated polyethylene tubes placed in subperiosteal tunnels on either side of the cartilage and aminoglycoside/cortisone solution used to irrigate these twice daily [21], [22]. Aggressive surgery, while it may, at times be necessary, may aggravate the ultimate deformity [3].

This study finds out the relative incidence, frequency, presentation, and complications of perichondritis of the pinna and the best management option for it.

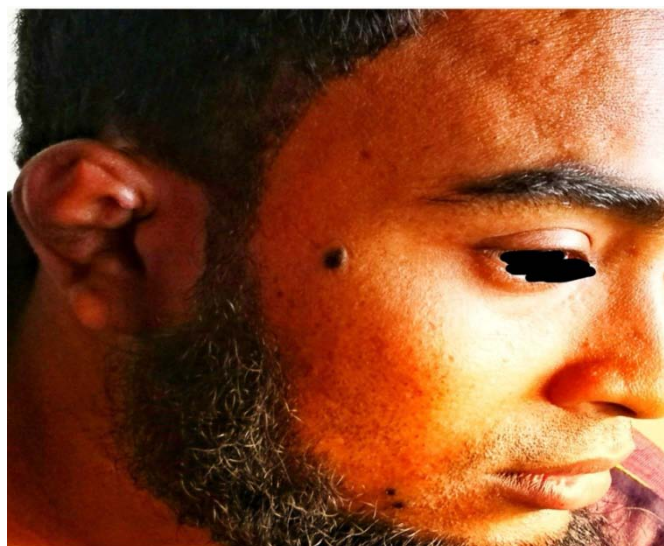


*Figure-1:* Auricular abscess of the left ear.

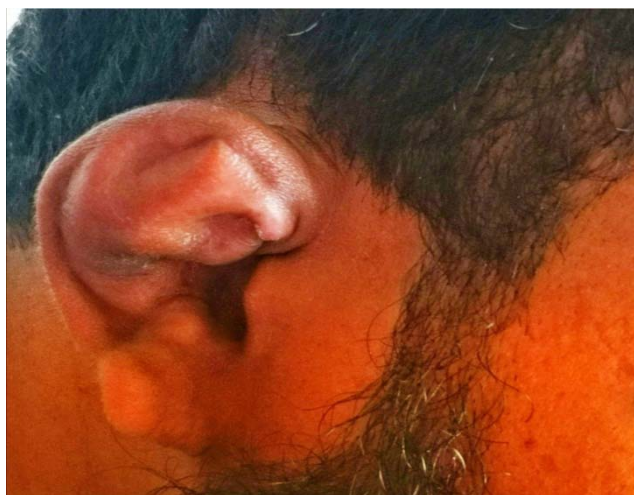

*Figure-2:* Perichondritis due to assault.

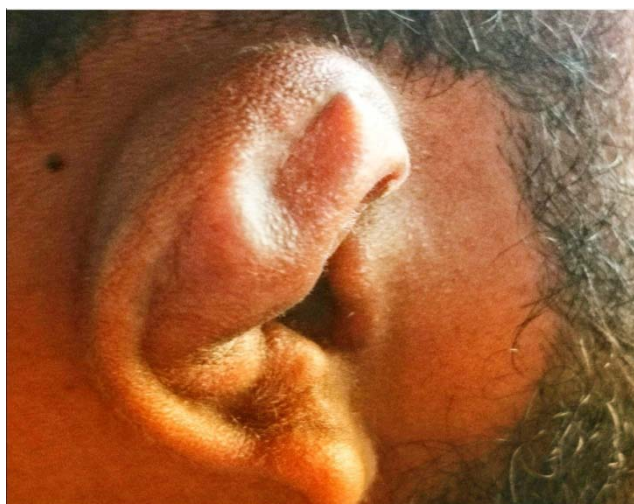




*Figure-3:* Auricular abscess due to blunt trauma.

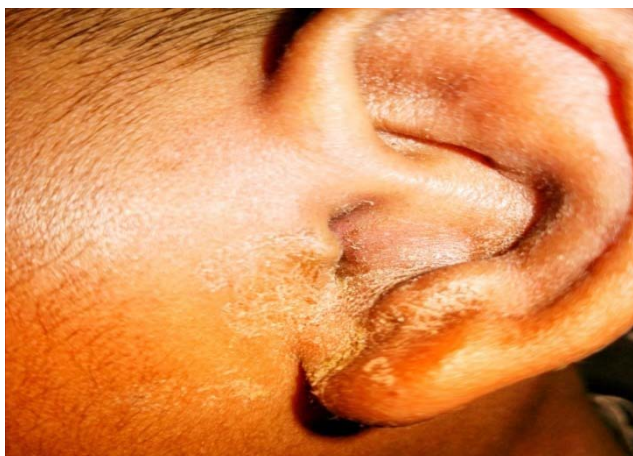


*Figure-4:* Close view of the figure-3 case.

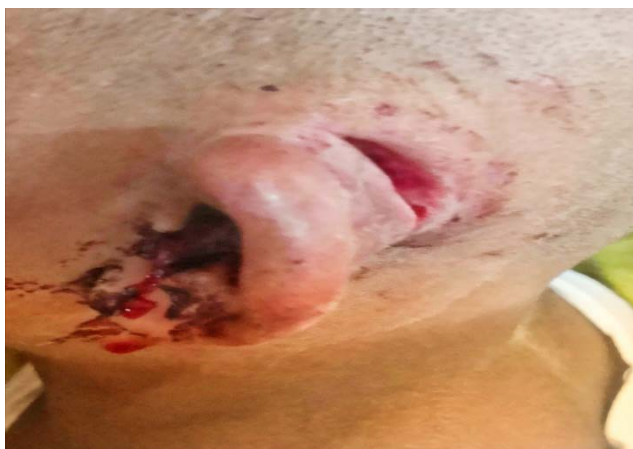

*Figure-5:* Auricular cellulitis with Hematoma.

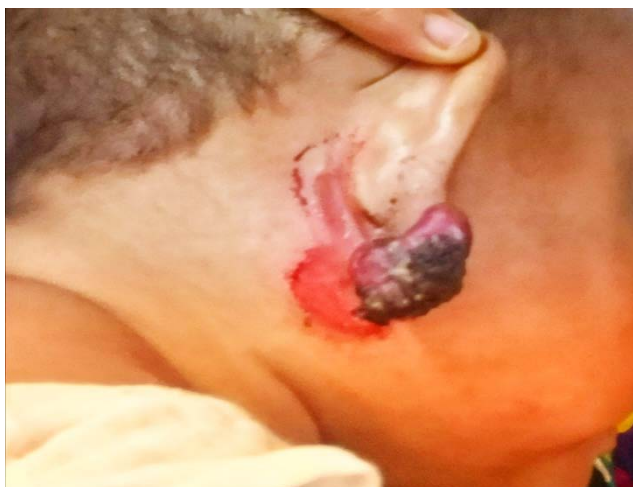



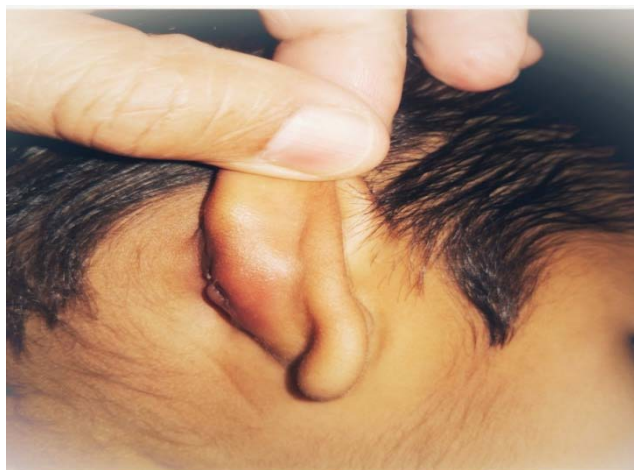*Figure-6:* Cellulitis of pinna due to Furunculosis.



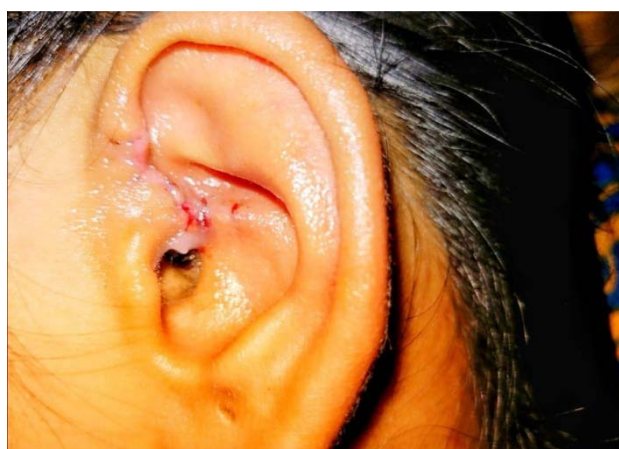*Figure-7:* Post infective perichondritis including pos-auricular abscess of 03 years child.



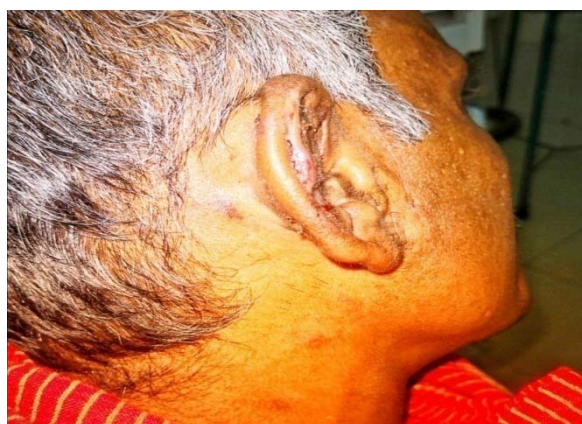*Figure-8:* Foreign body granuloma of the auricle with perichondritis of 02 years child.



*Figure-9:* Auricular sinus with perichondritis.

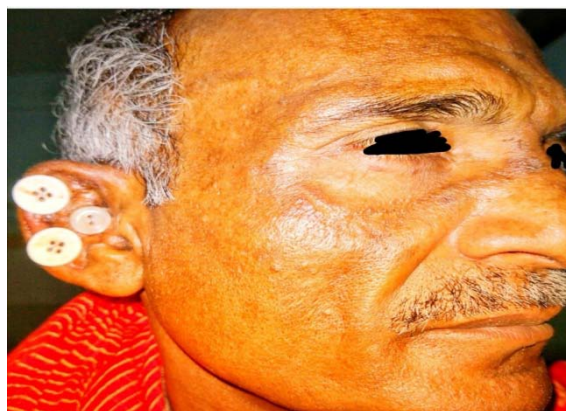

*Figure-10:* Perichondritis due to accident.



*Figure-11:* Helical incision along the margin of the helix of pinna.





*Figure-12:* Button placed medial and lateral side of bivalve pinna and fixed by thred 3/0 proline.



*Figure-13:* Fix the bivalve pinna of a teenage girl by button method.

## II. METHODS AND MATERIALS

It is a cohort retrospective study of 63 cases in the two tertiary care Hospitals from 01 July to 31 June 2019. During three years period, ENT casualty patient was 7295. We divided the 63 patients into two categories depending on the James W. Cook's classification [3].

The category one patients produced mild to moderate symptoms like erysipelas, induration, and early cellulitis. They were twenty-seven and treated conservatively through out-patient department service. We discussed with the patient about the fatal out of the disease to maintain the proper treatment. We started parental intravenous combined systemic broad-spectrum like Injection Meropenem, Clindamycin, and Metronidazole to combat both aerobic and anaerobic bacteria especially *Pseudomonas aeruginosa*. We advised them to admit in the Upazilla Health Complex, which is the secondary care hospital, and near their homes to maintain the intravenous course properly for seven to ten days according to the condition of the

added pain killer, anti-ulcer, local drop, and ointment whichever were needed. Accordingly, they came to consult with us and exhibited 90% improvement. We converted the parental antibiotic into oral form like Tab Moxifloxacin (400mg), Cap Clindamycin (300mg), and Tab Metronidazole (400mg) for another ten days. They were disease-free since the last follow-up.

The rest 36 patients were category two, who produced symptoms auricular abscess, perichondritis, and chondritis. They need immediate surgical exploration and got admitted to the hospital. We started parental intravenous combined broad-spectrum systemic antibiotics without any delay like category one. We did incision and drainage 22 patients and regular surgical dressing with EUSOL pack (Edinburg solution of lime). We gave incision along the helical margin up to maximum fluctuate point and split the ear bivalve fashion. Through the splitting line, we placed the EUSOL pack and gave pressure bandage by maintaining the auricular shape. The 13 patients of category two need exploration, debridement, and extensive scooping and curettage. We gave helical incision from the upper

attachment of auricle up to the lobule (Figure-11) and split the ear bivalve fashion, debridement, scooping and curettage of all dead tissue and cartilage, and placing the EUSOL pack and regular dressing as before. We did the surgery of the children and uncooperative patients under general anesthesia and cooperative patients under local anesthesia when the infection was overcome and growing of granulation tissue, the bivalve ear attached by button method for ten to fourteen days (Figure-12, 13).

One patient did mastoidectomy operation. He cleared his ear by street ear cleaner like a hawker. Afterward he developed perichondritis with mastoiditis. Perichondritis treatment continued, but he complained the severe earache need narcotic analgesic. CT scan showed osteomyelitis change in the mastoid bone. After mastoidectomy, the patient cured of symptoms.

We followed-up the patient fifteen days interval for one month and the last follow-up after three months. We referred the major deformed patients to the Plastic and Reconstruction department for further consultation. The following data collected about the patient: Sex, age, laterality, personal history, presenting features, investigation, treatment, post-operative follow-up, complication, and hospital stay. Statistical software SAS used to calculate all data.

### III. RESULTS

The incidence of perichondritis of pinna, out of ENT casualty, was 0.86%. The etiological factors explored, post-traumatic was 18 (28.57%) in which high ear piercing 11 (17.46%), accident and assault 07(11.11%), furunculosis 12 (19.05%), post-infective 09 (14.29%), allergy due to hair color 06 (9.53%), Herpes

Zostus Oticus 04 (6.35%), Malignant otitis externa 03 (4.76%), post-operative 02 (3.17%), insect bite( honey bees) 02 (3.17%), burn 02 (3.17%), and unknown 05(7.94%). Of them, the female was 30 (47.62%), and the male 33(52.58%), children (according to UNICEF and WHO children age up to 18 years) were 27 (42.86%), and adult 36 (57.14%) in which lowest age 02 years, highest age 76, mean age 21.952, and the standard deviation 16.676, and all patients had a unilateral ear. Personal history revealed diabetic was 08 (12.70%), and non-diabetic 55 (87.30%), smoker 09 (14.29%), and non-smoker 54 (85.71%). Presenting features exhibited moderate to severe earache was 61 (96.83%), red, hotness, and stiffness of pinna 59 (93.65%), auricular abscess 36 (57.14%). Bacteriology showed *Pseudomonas aeruginosa* was 21 (58.33%), *Staphylococcus aureus* 15 (41.67%), *Streptococcus pyogenes* 13 (36.11%), and gram-negative *Bacillus Proteus*, *Enterococcus faecalis*, *Escherichia coli* 11(30.56%). Regarding the treatment of the patient, 27 (42.86%) treated by conservative medical through out-patient department service, and 36 (57.14%) surgical through indoor service in which incision and drainage did 22 (61.11%), exploration, debridement, scooping, and curettage of auricular cartilage 13 (36.11%), and mastoidectomy 01(2.78%). After four months of follow-up, complications revealed minor deformity was 15 (23.81%), major deformity 07 (11.11%), and rest 41 (65.08%) normal. The treatment response was variable depending on the condition of the patient and prolonged the hospital stay. 17 (42.22%) patients stayed in a hospital for up to two weeks, 06 (16.67%) patients three to four weeks, and rest 13 (36.11%) patients five weeks and above.

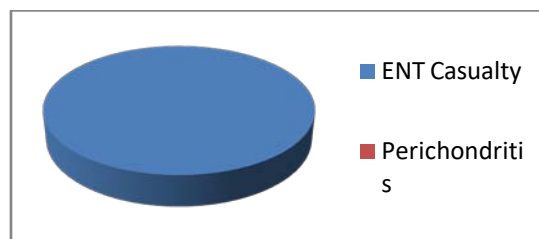
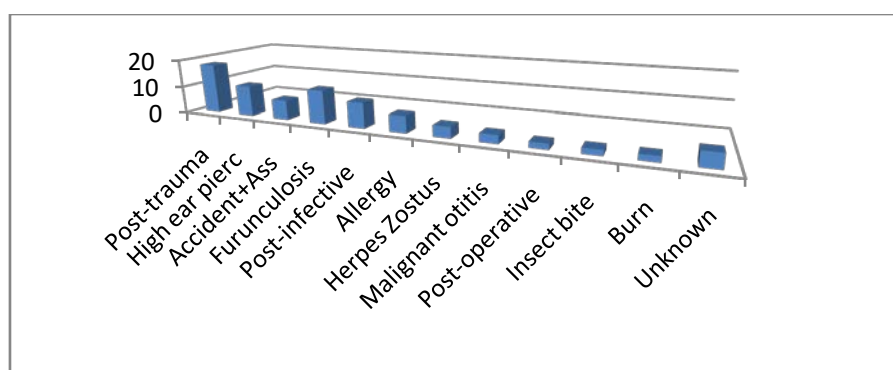
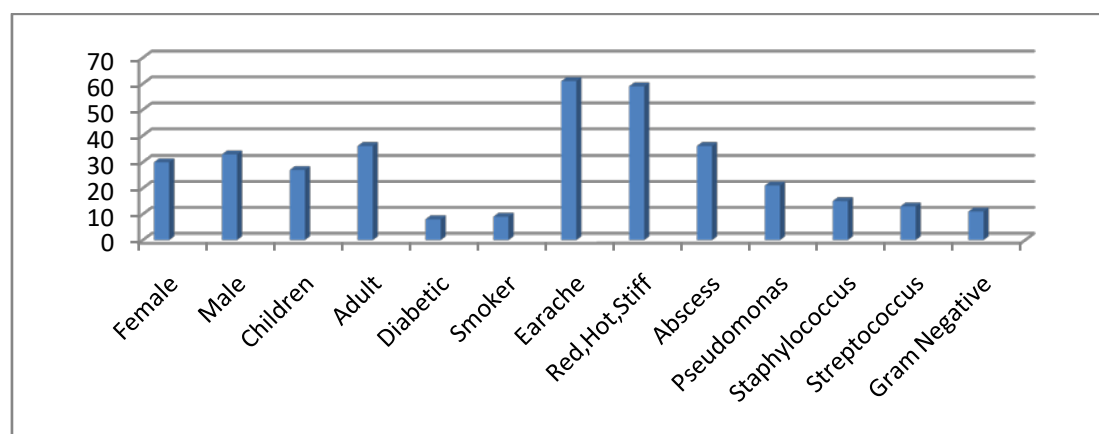


Chart-1: Incidence of perichondritis- n-7295; ENT casualty-7295: Perichondritis-63.

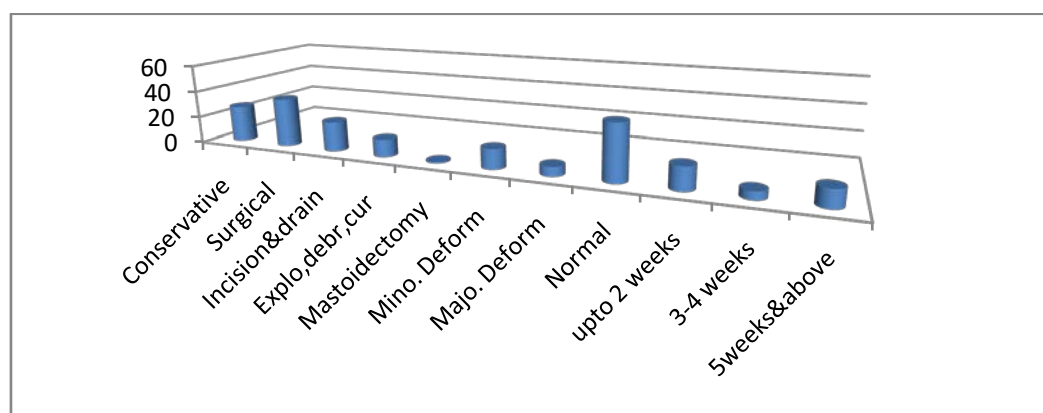




**Figure-14:** Etiological factor-n-63; 1.Post-trauma-18(A. High ear pierce-11, B-Accident & Assault-7).2.Furunculosis-12.3.Post-infective-9. 4. Allergy-6. 5. Herpes Zostus Oticus-4. 6. Malignant otitis externa-3. 7. Post-operative-2. 8. Insect bite-2. 9. Burn-2. 10. Unknown-5.



**Figure-15:** n-63; 1. Gender: Female-30: Male-33, 2. Age: Children-27: Adult-36, 3. Personal history: Diabetic-8: Smoker-9, 4. Presenting features: Earache-61: Red, Hot & Stiff pinna-59: Abscess-36, 5. Bacteriology: Pseudomonas-21: Staphylococcus-15: Streptococcus-13: Gram Negative-11.



**Figure-16:** n-63; 1. Treatment: Conservative-27: Surgical-36: Incision & drainage-22: Exploration, Debridement, Scooping & Curettage-13: Mastoidectomy-1. 2. Complications: Minor Deformity-15: Major Deformity-7: Normal-41. 3. Hospital Stay: Upto2 weeks: 3-4 Weeks-6: 5 Weeks & above-13.

#### IV. DISCUSSION

Perichondritis of the pinna is a fatal infection and deformed the second identity of the body after fingerprint [1]. The incidence of perichondritis in the

present study, out of ENT casualty (7295) was 0.86%. There was no available data to compare it.

Regarding the etiology, post-traumatic was the common cause (28.57%) which included high ear piercing 11 (17.46%) usually found during Eid festival,

and accident and assaulted 07 (11.11%) supported by Cicchetti S et al. and Prasad HK study [23], [16]. Other factors were furunculosis 19.05%, post-infective 14.29%, allergy due to hair color 9.53%, Herpes zostus oticus 6.35%, malignant otitis externa 4.76%, post-operative, insect bite and burn all three were 3.17%, and unknown 7.94%, persistence with Hanif J, Prasad HK and Gautam D et al. series [4], [16], [24].

In gender epidemiology, males were 52.58%, and females 47.62%, almost equal in my work in opposition to Gautam D et al. series, revealed male 38 (76%), female 12 (24%), Prasad KC also exhibited male preponderance [24], [25]. It may be due to high ear piercing and furunculosis of external auditory canal patients; all or maximum were females in my paper.

Concerning the age, children were 42.86%, and adults 57.14% in the present study, against Gautam D et al. reported 76% was 30-50 years. Still, Fernandez ADP et al. series showed maximums were a teenager in favor of my observation [24], [26].

Personal history revealed diabetic was 12.70% and smoker 14.29% in my research causes delayed wound healing persistence with Fernandes LF work, recorded insulin depended on diabetic patient treated by hyperbaric oxygen after proper controlling of DM [27]. To control this type of fatal infection, the patient should stop smoking and diabetes should be normal through consultation with the Endocrinologist.

Presenting features exhibited earache was 96.83%, erythematous and indurated pinna 93.65%, and auricular abscess 57.14% in this paper, kept up by all others study like Prasad HK, Cicchetti C, Gautam D and Davis O et al. series [16], [23], [24], [28].

Culture and sensitivity report in my study, *Pseudomonas aeruginosa* was 58.33%, *Staphylococcus aureus* 41.67%, *Streptococcus pyogenes* 36.11%, and Gram-negative 30.56%, near to James W. Looock, Prasad HK and Gautam D papers [3], [16], [24]. James W. Looock showed *Pseudomonas aeruginosa* was 69%, Polymicrobial 22%, *Streptococcus* spp. 22%, and *Staphylococcus aureus* 20%. Prasad HK revealed *Pseudomonas* and *E Coli* were 50%, *Pseudomonas aeruginosa* 38%, *Pseudomonas* and *Staphylococcus* 07% and *Staphylococcus aureus* 05%. Gautam D exhibited *Pseudomonas aeruginosa* was 48%, *Staphylococcus* 20%, *Enterococcus faecalis* 10%, *Streptococcus* group A 06%, and Polymicrobial 08%. About bacteriology, Cossette JE, and Bergstrom L. observation also near to my report [29], [30].

Regarding treatment, we treated 42.86% patient conservative medical treatment supported by Prasad HK and Gautam D, though the number of patients fewer than me. They treated 19% and 24% patient accordingly conservative alone [16], [24]. Surgical treatment included incision and drainage was 61.11%, exploration, debridement, scooping and curettage 36.11%, and mastoidectomy 2.78% in this paper, near Prasad HK

percentage of the patient but the difference the method of surgery [16]. He presented incision and drainage was 31%, cartilage and wound debridement 31%, and mastoidectomy 07%. But my method of surgery kept up by James W. Looock, Dowling JA, Kent SE, and Widick MH et al. series [3], [20], [31], [32].

Post-operative follow-up presented minor deformity was 23.81%, extensive deformity 11.11%, and retain architecture 65.08% near to Gautam D et al. displayed partial deformity was 50%, total deformity 18%, and no deformity 32% [24]. Salem W and Scoog T et al. report also support our findings [33], [34].

Regarding hospital stay, conservatively treated 42.86% of patient received their treatment through outpatient department service. Surgically treated, 57.14% patients had got admitted to the hospital. Among them, 42.22% stayed in the hospital up to two weeks, 16.67% three to four weeks, and 36.11% five weeks and above-, consistent with Prasad HK, Gautam D, and Fernandez ADP works [16], [24], [26].

## V. CONCLUSION

Perichondritis of the pinna is one of the dreadful diseases which can commonly strike teenagers, young, and diabetic persons. Teenagers and females are doing high ear piercing for wearing ornaments, which increases their fashion and smartness. It is necessary to develop their awareness to do high ear piercing a trained medical personnel. Development of realization about the ear infection and care to the people is essential through local health authority. Truculent surgical treatment without undue delay and the latest parental broad-spectrum antibiotic may restrain the disease and mitigate the hospital stay outstanding.

*Fund:* Nothing any source.

*Competing Interests:* No competing interests exist.

*Ethical Approval:* The study was approved by the Institutional Ethics Committee.

## REFERENCES RÉFÉRENCES REFERENCIAS

1. Feenstra L, van der Lugt C. Ear Witness. *J Laryngol Otol* 2000; 114: 497-500.
2. Davidi E, Paz A, Duchman H. Perichondritis of the auricle: analysis of 114 cases. *Israel Med Assoc J* 2011; 13: 21-4.
3. James W. Looock. Perichondritis of the External Ear. *Scott-Brown's Otorhinolaryngology Head & Neck Surgery, Volume-2, The Ear*. 2018; 8<sup>th</sup> edition (Chapter-79): p-959.
4. Hanif J, Frosh A, Marnane C. High ear piercing and the rising incidence of perichondritis of the pinna. *BMJ (Clinical research ed.)* 2001; 322: 906-7.
5. Cumberworth VL, Hogarth TB. Hazards of ear piercing procedures which traverse cartilage: a repeat of *Pseudomonas* perichondritis and review of other complications. *Br J Clin Prac* 1990;44:512-13.

6. Stroud MH. A simple treatment for suppurative perichondritis. *Laryngoscope*. 1963; 73: 556-63.
7. Stevenson EW. Bacillus Pyocyaneus perichondritis of the ear. *Laryngoscope*. 1964; 74: 255-9.
8. Chen M, Scully C. Tongue piercing: a new fad in body art. *Br Dent J* 1992; 172: 87.
9. Watson MG, Campbell JB, Pahor AL. Complication of nose piercing. *BMJ* 1987; 294: 1262.
10. Hansen RB, Olsen LH, Langkilde NC. Piercing of the glans penis. *Scand J Urol Nephrol* 1998; 32: 219-20.
11. Stim A. Body piercing: medical consequences and psychological motivations. *Lancet* 2003; 361(9364): 1205-15.
12. Martin R, Yonkers AJ, Yarrington CT. Perichondritis of the ear. *Laryngoscope* 1976; 86: 664-73.
13. McAdam LP, o'Hanlan MA, Bluestone R. Relapsing polychondritis: prospective study of 23 patients and review of the literature. *Medicine* 1976;55: 193-215.
14. Levin RJ, Herick DH, Cohen AF. Human immunodeficiency virus-associated non-Hodgkin's Lymphoma piercing as an auricular perichondritis. *Otolaryngol Head Neck Surg* 1995; 112: 493-5.
15. Indudharan R, Arai T, Myint KK, Jackson N. Lymphoblastic Lymphoma/Leukemia presenting as perichondritis of the pinna. *J Laryngol Otol* 1998; 112: 592-4.
16. Prasad HK, Sreedharan S, Prasad HS. Perichondritis of the auricle and its management. *J laryngol Otol* 2007; 121: 530-4.
17. Pattanaik S. Effective, simple treatment for perichondritis and pinna hematoma. *J Laryngol Otol* 2009; 123: 1246-9.
18. Bassiouny A. Perichondritis of the auricle. *Laryngoscope* 1981; 91: 422-31.
19. Apfelberg DB, Waisbren BA, Masters FW, Robinson DW. Treatment of chondritis in the burned ear by the instillation of antibiotics. *Plast Reconstr Surg* 1974; 53: 179-83.
20. Dowling JA, Foley FD, Moncrief JA. Chondritis of the burned ear. *Plast Reconstr Surg* 1968; 42: 115-22.
21. Wanamaker HH. Suppurative perichondritis of the auricle. *Trans AM Acad Ophthalmol Otolaryngol* 1972; 76: 1289-91.
22. Lombardo L. Post-operative perichondritis of the auricular lobe: Aetiopathogenic and therapeutic study. *Arch Ital Otol Rhinol Laryngol* 1955; 66: 763-70.
23. Cicchetti S, Skillman J, Gault TD. Piercing the upper ear: a simple infection, a difficult construction. *British Journal of Plastic Surgery* 2002;55 :194-197.
24. Gautam D, Bijan B, Ganesh CG, Ritam R. Auricular perichondritis in a Tertiary Rural Hospital. *Philipp J Otolaryngol Head Neck Surg*. 2013; 28(1): 06-09.
25. Prasad KC, Karthik S, Prasad SC. A comprehensive study on lesion of the pinna. *Am J Otolaryngol* 2005; 26(1): 1-6.
26. Fernandez ADP, Neto IDC, Anias CR, Pinto PCL, eCastro JDC, Carpes AF. Post- Piercing perichondritis. *Rev Bras Otorrinolaringol* 2008; 76(6): 933-7.
27. Fenandes LF, Levor M, de Carvalho GM, Guinmraes AC. Hyperbaric oxygen in the treatment of perichondritis of the pinna. *Diving and Hyperbaric Medicine*. 2013; 43(3): 166-167.
28. Davis O, Powell W. Auricular perichondritis secondary to acupuncture. *Arch Otolaryngol* 1985; 322: 906-7.
29. Cossette JE. High ear piercing. *Otolaryngol Head Neck Surg* 1993; 109:967-8.
30. Bergstrom L. Disease of the external ear. In Bluestone CD, Stooles SE, eds. *Pediatric Otolaryngology*, Philadelphia: W. B. Saunders Co. 1990; Bluestone & Stooles edition: 315-16.
31. Kent SE, Rokade AV, Premraj K, Bucher C. High ear piercing and perichondritis of pinna. *BMJ* 2001; 323: 401.
32. Widick MH, Coleman J. Perichondrial abscess resulting from a high ear piercing- Case Report. *Otolaryngol Head Neck Surg*. 1992; 107: 803-4.
33. Salem W. Mastoiditis with extensive osteitis and pyogenic perichondritis of the pavilion. *Rev Bras Cir* 1960; 39: 334-6.
34. Skoog T, Ohlsen L, Sohn SA. Perichondrial potential for cartilaginous regeneration. *Scand J Plast Reconstr Surg* 1972; 6: 123-5.