



GLOBAL JOURNAL OF MEDICAL RESEARCH: J  
DENTISTRY & OTOLARYNGOLOGY  
Volume 20 Issue 6 Version 1.0 Year 2020  
Type: Double Blind Peer Reviewed International Research Journal  
Publisher: Global Journals  
Online ISSN: 2249-4618 & Print ISSN: 0975-5888

## Submandibular Cervical Mass as the First Presenting Sign of FVPTC. A Case Report and Review of Literature

By Dr. Soumya M, Dr. Radhika M. Bavle, Dr. Sudhakara M. & Dr. Srinath N.

**Abstract-** Submandibular cervical swellings can manifest with a wide range of differentials which could be congenital, infective, reactive, neoplastic, or metastatic in origin. Here we discuss a case of a 42 year old male patient, who initially presented with a painless mass in the right submandibular region with no other associated symptoms, which on further examination turned out to be metastatic lymphadenopathy. A thorough investigation of the neck was subsequently performed, which lead us to the diagnosis of follicular variant of papillary thyroid carcinoma with submandibular lymphnode metastasis. Thus, the consideration of a metastatic lymph node in the differential diagnosis is always mandatory in the case of a long standing, largely asymptomatic solitary mass in the lateral neck of an adult patient.

**Keywords:** cervical mass, submandibular swelling, papillary thyroid carcinoma, follicular variant, lymph node metastasis.

**GJMR-J Classification:** NLMC Code: WU 170



*Strictly as per the compliance and regulations of:*



# Submandibular Cervical Mass as the First Presenting Sign of FVPTC. A Case Report and Review of Literature

Dr. Soumya M<sup>α</sup>, Dr. Radhika M. Bavle<sup>σ</sup>, Dr. Sudhakara M. P<sup>ρ</sup> & Dr. Srinath N. Ω

**Abstract-** Submandibular cervical swellings can manifest with a wide range of differentials which could be congenital, infective, reactive, neoplastic, or metastatic in origin. Here we discuss a case of a 42 year old male patient, who initially presented with a painless mass in the right submandibular region with no other associated symptoms, which on further examination turned out to be metastatic lymphadenopathy. A thorough investigation of the neck was subsequently performed, which lead us to the diagnosis of follicular variant of papillary thyroid carcinoma with submandibular lymphnode metastasis. Thus, the consideration of a metastatic lymph node in the differential diagnosis is always mandatory in the case of a long standing, largely asymptomatic solitary mass in the lateral neck of an adult patient.

**Keywords:** cervical mass, submandibular swelling, papillary thyroid carcinoma, follicular variant, lymph node metastasis.

## I. INTRODUCTION

Neck masses are frequently encountered in clinical practice. A careful evaluation of these masses along with a lucid history is paramount as they give an insight into the differential diagnosis of the lesion in question. Evaluation of neck masses should generally involve a definite algorithm which includes - a thorough clinical examination, review of the systemic state, physical evaluation of the site in question, imaging, a good differential diagnosis and a sound pathologic assessment.

Eliciting a good history from the patient in terms of the location, growth rate, associated symptoms like referred pain, hoarseness of voice, dysphagia will provide clues in determining the origin and the nature of the pathology.

A detailed knowledge of the anatomy of the triangles of neck and lymphatic drainage of the head

and neck is essential to arrive at a comprehensive differential diagnosis. [1]

Anatomically, the neck can be divided into [1]

- Central Neck
- Lateral Neck - further subdivided into
  - Anterior triangle
  - Posterior triangle

Lateral masses in the neck can be categorized broadly into -

- Developmental/congenital anomalies
- Neoplastic lesions - benign and malignant
- Traumatic lesions
- Metabolic and Autoimmune disorders
- Infectious or inflammatory lesions
- Vascular and endocrine lesions

The present case in discussion was a lateral neck mass, which on biopsy, revealed metastatic deposits of a lesion carrying features of papillary thyroid carcinoma.

## II. CASE PRESENTATION

A 42-year-old male patient reported to our hospital with a complaint of a swelling in the right upper neck region since 2 years. He gave a history of a small painless mass, which grew to the present size of 3x2 cm. Previous medical, family or habit history were non-contributory.

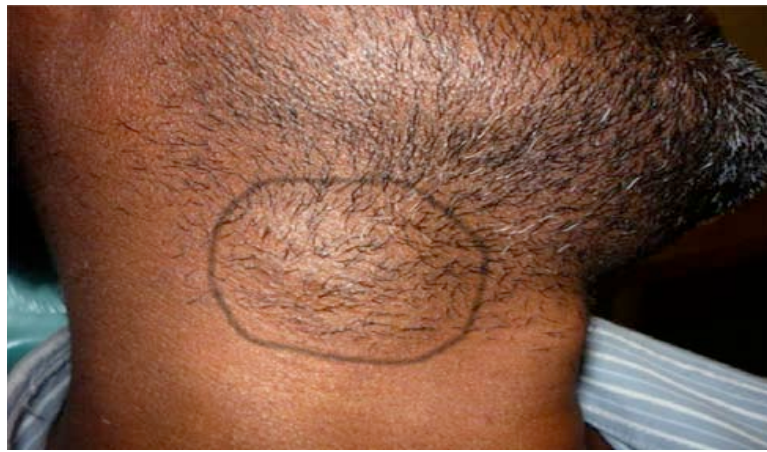On examination, an extra-oral nodular compressible swelling was evident in the submandibular region about 4 cm below the inferior border of the mandible, anterior to the sternocleidomastoid muscle. It was firm, well-defined and moved on deglutition.

**Author α:** Department of Oral and Maxillofacial Pathology, Krishnadevaraya College of Dental Sciences & Hospital Bangalore-562157. e-mail: soumyamakarla@gmail.com

**Author σ:** Professor and Head, Department of Oral and Maxillofacial Pathology, Krishnadevaraya College of Dental Sciences & Hospital, Bangalore. e-mail: radix69@gmail.com

**Author ρ:** Reader, Department of Oral and Maxillofacial Pathology, Krishnadevaraya College of Dental Sciences & Hospital, Bangalore. e-mail: sudhakarmop@gmail.com

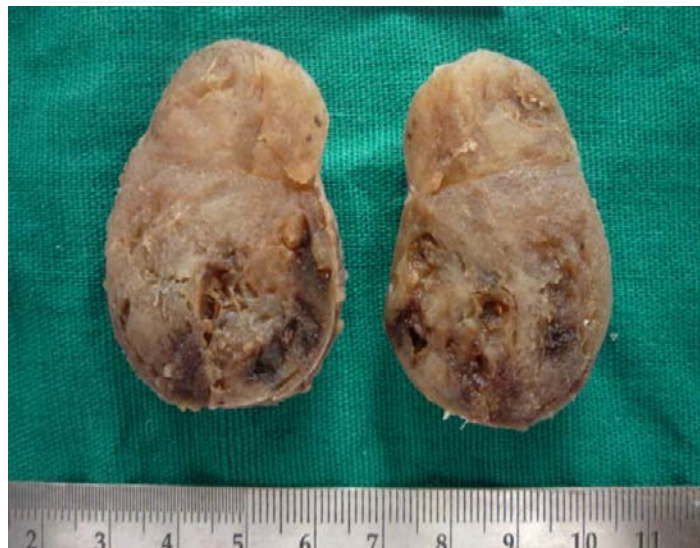**Author Ω:** Professor and Head, Dept of Oral & Maxillofacial Surgery Krishnadevaraya College of Dental Sciences & Hospital, Bangalore e-mail: srinathdr@gmail.com



*Figure 1:* Clinical image: Extra-oral cervical swelling of about 3x2 cm, evident in the submandibular region about 4 cm below the inferior border of the mandible

Intraorally, there were no contributory findings. Complete blood investigation revealed all values to be within the normal range. Thyroid hormone (TSH) levels were well within limits. A provisional diagnosis of cervical lymphadenopathy suspected to be associated with tuberculosis was made and the lesion was surgically excised.

Excisional biopsy revealed a solid soft tissue specimen measuring about 4.8 x3.5 cm; well circumscribed, creamish-brown, rubbery in consistency. Cut surface showed areas of greenish jelly, hemorrhage and cystic degeneration.

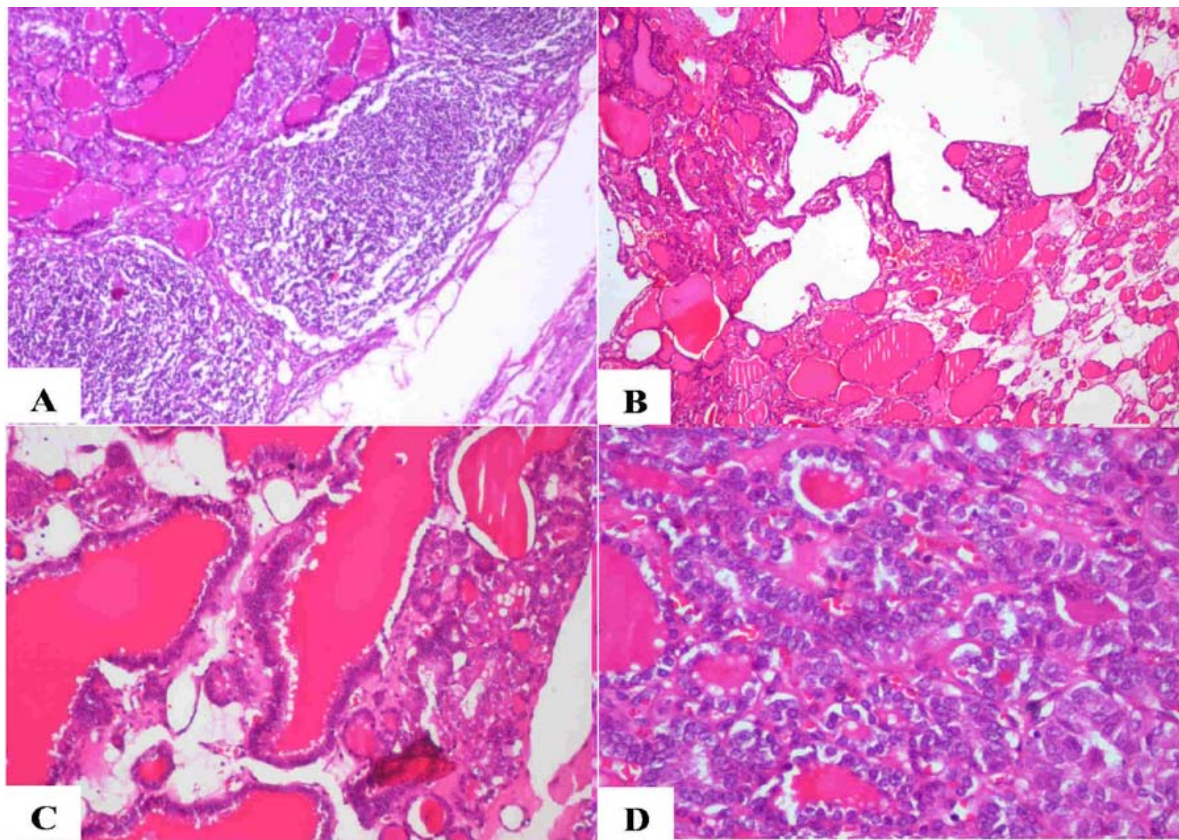


*Figure 2:* Gross specimen: A solid well circumscribed soft tissue specimen, creamish-brown in colour, rubbery in consistency measuring about 4.8 x3.5 cm. Cut surface shows areas of cystic degeneration and haemorrhage

Histopathological sections showed encapsulated lymphoid tissue with peripherally situated lymphoid follicles and centrally numerous large and small thyroid-like follicles, lined by a single layer of secretory epithelial cells with dense basophilic nucleus. The epithelial areas proliferated into papillary growths in few areas. The follicles contained homogenous eosinophilic colloidal secretions with scalloped appearance at the periphery. The epithelial cells showed features of dysplasia, nuclear crowding, overlapping, large open faced nuclei with optical

clearing (orphan Annie nuclei), few mitoses and minimal connective tissue stroma in between the cells.

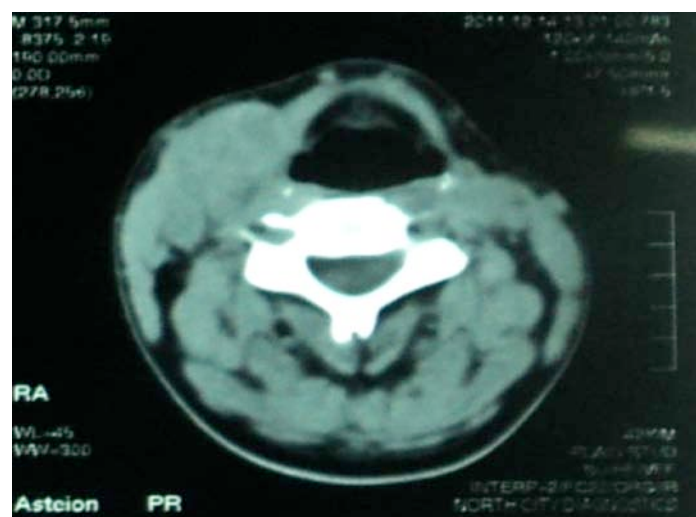




**Figure 3:** Figure 3: Photomicrographs of H&E stained tissues exhibit: 3A-Encapsulated lymph node tissue with peripherally situated lymphoid follicles and centrally numerous follicles filled with eosinophilic colloidal material (x40). 3B: Epithelium lining the follicles is thrown into papillary growths (x40). 3C: Follicles are lined by single layer of secretory epithelial cells exhibiting focal nuclear crowding. Edges of the follicle exhibit scalloping of eosinophilic coagulum (x100). 3D: Dysplastic secretory epithelial cells with large open face nuclei, nuclear clearing and minimal stroma (x200).

With these findings, the lesion was diagnosed as a metastatic papillary thyroid carcinoma (PTC) - follicular variant. Further evaluation of the head and

on computed tomography (CT) scan revealed enlarged right lobe of the thyroid gland with presence of cystic nodules.



**Figure 4:** CT scan revealed enlarged right lobe of thyroid gland with presence of cystic nodules

Multiple enhancing solid masses were also observed in the carotid space, supra clavicular and lower cervical stations with cystic degenerative changes suggestive of lymphadenopathy. A total thyroidectomy along with right radical neck dissection (RND) was performed under general anesthesia.

The thyroidectomy specimen showed a large nodular lesion with cystic and hemorrhagic areas on gross pathology. Microscopically, features of papillary thyroid carcinoma with sheets of thyroid follicles lined by cells with optically clear nuclei with grooving was observed which confirmed the initial diagnosis. Additionally, 19 lymph nodes were isolated from the RND specimen, of which, 2 showed metastatic deposits.

To further rule out any other metastatic deposits, ultrasonography of the abdomen and pelvis was performed and was found free of any pathology. No metastasis other than that of the cervical lymph nodes was detected.

The patient was referred for auxiliary radiotherapy and was subjected to I<sup>131</sup> therapy for ablation of any residual thyroid tissue. Thyroglobulin levels and an I<sup>131</sup> scan performed after 6 months of the surgery showed normal levels and complete ablation of the residual gland respectively. The patient is on follow up every 6 months and so far is free of any recurrence for the last eight years.

### III. DISCUSSION

One of the most important considerations in an adult patient presenting with a mass in the neck should be a neoplasm, either benign or malignant, or a metastatic deposit from a primary cancer.

Skandalakis et al., [2] proposed a "rule of 7" based on duration of the lesions, which stated that time span of symptoms that were caused due to infections was 7 days; for tumours 7 months and an interval of 7 years for developmental anomalies. Our patient, with a history of a neck mass since 2 years, could be categorised under the tumour bracket.

Based on the anatomic location in the present case, neck masses could arise due to:

- i. Ectopic thyroid tissue
- ii. Congenital/ Developmental anomalies
- iii. Thyroid gland pathology
  - a. Benign thyroid lesions - Multi-nodular goitre, Hashimoto's thyroiditis,

- b. Thyroid nodules - benign/malignant
- iv. Salivary gland pathology
- v. Lymphomas
- vi. Cervical group of lymph nodes –
  - o Ectopic nodes
  - o Infectious nodes
  - o Inflammatory origin – Lymphadenitis
  - o Hodgkins lymphoma
  - o Metastatic nodes

75% of lateral neck masses in patients over 40 years of age have been found to be caused by malignant tumours. The incidence of neoplastic cervical adenopathy increases with age. [3] This conformed with the age group of our patient who was 42 years.

Garrel et al., stated that a lateral cervical mass must indicate the probability of lymph node metastasis firstly and based on the habits of alcohol and tobacco use, of epidermoid carcinoma of upper gastro-intestinal and respiratory tracts [4]. The second most common is thyroid cancer, [5,6] especially in patients under 40 years with no other risk factor, particularly in cases of a cystic cervical mass, [4] similar to our case presentation.

Though congenital anomalies are rare in adults, they cannot be excluded from the differential diagnosis of a neck mass. Branchial anomalies like cleft cysts, sinuses and fistulae are most frequent in the lateral neck. They are generally insidious, asymptomatic lesions. Cystic hygromas and dermoid cysts can also typically present in this area. [3]

Reactive lesions characteristically exhibit signs of inflammation and tenderness and also arise due to infection or granulomatous inflammation. But in our case, the patient was asymptomatic and was initially suspected of tuberculous lymphadenopathy.

Benign tumours like schwannoma, lipoma, hemangioma, parathyroid and salivary adenomas can present as neck masses. Malignant tumours of the neck include soft tissue sarcomas, lymphomas, salivary gland tumours.

The most frequently encountered solitary mass in the lateral neck in an adult is a metastatic lymph node. The location of the affected lymph nodes in the neck is a good indicator of the origin of the lesion Table 1 [7].

Table 1: Patterns of lymph node metastasis in head and neck

Lymph node groups	Sites of origin
Level IA (submental)	Anterior oral cavity, lower lip
Level IB (submandibular)	Oral cavity, anterior nasal cavity, submandibular gland, midfacial face skin
Level II (upper jugular)	Oropharynx, oral cavity, nasopharynx, nasal cavity, larynx, hypopharynx
Level III (mid jugular)	Oropharynx, oral cavity, nasopharynx, larynx, hypopharynx
Level IV (lower jugular)	Oropharynx, larynx, hypopharynx, upper esophagus, thyroid

Level V (posterior triangle)	Nasopharynx, posterior scalp skin, thyroid
Level VI (anterior compartment)	Thyroid, larynx, hypopharynx, upper esophagus
Supraclavicular	Non-head and neck, thyroid
Retropharyngeal	Nasopharynx, posterior pharynx
Parotid	Lateral/upper facial and scalp skin, parotid gland

Benign and malignant thyroid neoplasms are the leading cause of anterior compartment neck masses. Patients with malignant thyroid nodules present with 40% clinically positive nodes and 90% histologically positive nodes. [5,6]

Several reports state that thyroid carcinomas initially manifest as neck masses not conforming to the typical pattern of the glandular involvement. [8,9] Lymphadenopathy due to metastasis is the initial symptom evident on clinical examination in about 23-56% of the cases of Papillary thyroid carcinomas (PTC). [10]

Such lymph node metastases commonly occur as solid masses in the anterior or lateral aspect of the neck. [11,12] These lymph nodes, usually are chiefly located in levels IIa and III i.e. superior and median cervical areas of the neck. [9]

Such a finding was evident in our case, wherein the clinically detectable lateral neck mass was a solid lesion, which on further investigation was found to be an enlarged lymph node in the anterior triangle of neck.

Imaging is an important adjuvant used for determining the location and features of the lesion in patients presenting with a neck mass. Ultrasonography is a common modality used to evaluate pathologies of the thyroid gland and also to detect metastatic lymphadenopathies.

Rosario et al., have described the characteristic ultrasonic appearance of metastatic lymph nodes in PTC which include:

- i. A minimum axial diameter of 0.7 mm for Level II neck nodes and 0.6 mm for all the other levels of the neck
- ii. Round shape of the lymph node
- iii. Hyperechogenicity in relation to the adjacent muscles,
- iv. Intranodal cystic necrosis,
- v. Peripheral calcifications, and
- vi. The absence of an echogenic hilum.

When the presence of cystic necrosis and calcifications within the lymph node are observed; then the specificity is almost 100% in those patients with PTC. Such a picture is absent in normal or reactive lymph nodes. [10,13]

CT and MRI (magnetic resonance imaging) are indispensable tools in evaluating neck masses. Definitive features of central necrosis, thickened walls, intracystic elements, calcifications, greater peripheral uptake observed in CT scans with contrast, [14] are suggestive of a metastatic thyroid lesion with 100% sensitivity and

90% specificity as compared to sonography with 80% specificity [11,15] as observed in our case.

MRI is the preferred imaging tool for inaccessible or difficult to visualize primary tumour sites - base of tongue, skull. In thyroid carcinomas, MRIs exhibit a T2 hyperintense signal, which indicates thyroglobulin rich material. [4]

In the present case, the neck mass was surgically excised to reveal a solid nodule, rubbery in consistency, with areas of greenish jelly, hemorrhage and cystic degeneration. On pathologic assessment, the nodule was diagnosed as follicular variant of papillary thyroid carcinoma, re-confirmed post total thyroidectomy.

Papillary carcinoma is the most frequently encountered type of thyroid malignancy comprising of 80-85% of cases. It generally presents as a nodular lesion of the thyroid gland. [11, 16]

Loco-regional lymph node metastasis as an initial manifestation is seen in over 50% cases of papillary thyroid cancer. Studies have shown that it does not alter the long-term prognosis particularly in those below 45 years of age. [16]

The follicular variant of papillary thyroid carcinoma (FVPTC) is the most common variant of papillary thyroid carcinoma (PTC), accounting for about 22.5% -30% of all PTCs. [17]

It affects females more than males with a ratio of 3.6:1 and commonly occurs in 3rd to 5th decade of life with a mean age of 44 years. Our patient was diagnosed at 42 years of age, though he was a male patient. This variant of PTC has an excellent prognosis with 98% 20 year survival rate and < 0.2% mortality rate. [17,18]

This histologic type comprises predominantly of follicles of varying sizes, lined by tumour cells which typically exhibit the nuclear features of PTC. The nuclei are large and oval with powdery to optically clear chromatin, cytoplasmic invaginations into the nucleus, increased number of grooves, crowding and overlapping; termed as ground glass or Orphan Annie nuclei which are the hallmark of PTC. Other features include dark hyper eosinophilic colloid, irregular contour of follicles, scalloping of colloid, multinucleated macrophages in lumen of follicles [17] - all of which were evident in this case along with few papillary structures and mitotic figures.

Other variants of PTC include macrofollicular, oncocytic, clear cell, tall cell, columnar, diffuse sclerosing, insular/solid, cribriform-morula.



Histologically, follicular variant of PTC can be mistaken for follicular adenoma or adenocarcinoma, but the distinctive nuclear features of the tumour cells and hypereosinophilic scalloped colloid are characteristic of papillary thyroid carcinoma. [17,18]

The treatment protocol advocated for patients diagnosed with carcinoma of thyroid, with initial presentation of cervical lymph node metastasis is total thyroidectomy along with modified RND as risk of recurrence is reduced with compartment-oriented dissection, than with simple excision of enlarged lymph nodes. [9, 19] Adjuvant radio-ablation with iodine and lifelong thyroxin therapy is recommended to ensure better outcome and quality of life. [9,20]

The above treatment procedure was strictly adhered to for this patient inclusive of the ablation and thyroxin medication. Regular I<sup>131</sup> scans and serum tests at 6-month intervals have shown no evidence of any recurrent disease till date.

#### IV. CONCLUSIONS

The presence of a unilateral, largely asymptomatic, long standing mass in the lateral neck of an adult patient should be considered as metastatic until proven otherwise. A definitive protocol should be adhered to in such cases, which will provide a step-by-step approach to rule out various differentials to arrive at the right diagnosis. Cervical lymphadenopathy is an initial presentation in over 50% cases of PTC, as in the present case. Therefore, including lymph node metastasis from primary thyroid carcinomas especially papillary thyroid carcinoma (follicular variant) into the repertoire of neck lesions is a must for all head and neck pathologists and clinicians.

#### REFERENCES RÉFÉRENCES REFERENCIAS

1. Lee J, Fernandes R: Neck masses: Evaluation and Diagnostic approach. *Oral Maxillofacial Surg Clin N Am.* 2008, 20:321-37. <https://doi.org/10.1016/j.coms.2008.04.001>
2. Skandalakis JE, Gray SW, Takakis NC, Godwin JT, Poer DH: Tumours of the neck. *Surgery.* 1960, 48:375-384.
3. Schwetschenau E, Kelly DJ: The Adult Neck mass. *Am Fam Physician.* 2002, 66:831-8.
4. Garrel R, Tripodib C, Cartiera C, Makeieffa M, Crampettea L, Guerrier B: Cervical lymphadenopathies signaling thyroid microcarcinoma. Case study and review of the literature. *European Annals of Otorhinolaryngology, Head and Neck diseases.* 2011, 128:115-119. <https://doi.org/10.1016/j.anorl.2010.11.007>
5. Irani S: Metastasis to head and neck area: a 16-year retrospective study. *Am J Otolaryngol.* 2011, 32:24-7. <https://doi.org/10.1016/j.amjoto.2009.09.006>
6. Pietarinen-Runtti P, Apajalahti S, Robinson S, et al.: Cystic neck lesions: clinical, radiological and differential diagnostic considerations. *Acta otolaryngologica.* 2010, 130:300-4. <https://doi.org/10.3109/00016480903127450>
7. Chernock RD, Lewis JS: Approach to Metastatic Carcinoma of Unknown Primary in the Head and Neck: Squamous Cell Carcinoma and Beyond. *Head and Neck Pathol.* 2015, 9:6-15. <https://doi.org/10.1007/s12105-015-0616-2>
8. Park CS, Min JS: Lateral neck mass as the initial manifestation of thyroid carcinoma. *Head Neck.* 1989, 11:410-3. <https://doi.org/10.1002/hed.2880110506>
9. De Jong SA, Demeter JG, Jarosz H, Lawrence AM, Paloyan E: Primary papillary thyroid carcinoma presenting as cervical lymphadenopathy: the operative approach to the "lateral aberrant thyroid". *am Surg.* 1993, 59:172-7.
10. Choi EC, Moon W-J, Lim YC: Tuberculous cervical lymphadenitis mimicking metastatic lymph nodes from papillary thyroid carcinoma. *Br J Radiol.* 2009, 82:208-211. <https://doi.org/10.1259/bjr/91644902>
11. Chiang KY, Zhuang YL, Li WY, Lin CZ. Occult Papillary: Thyroid Carcinoma Presenting as Huge Cervical Metastasis with Cystic Pattern. *Tzu Chi Med J.* 2008, 20:140-143. [https://doi.org/10.1016/S1016-3190\(08\)60025-7](https://doi.org/10.1016/S1016-3190(08)60025-7)
12. Ozdamar OI, Acar OG, Kafkasli C, Kalcioğlu MT, Zenginkinet T, Tamer HT: Papillary Thyroid Microcarcinoma with a Large Cystic Dilated Lymph Node Metastasis to the Neck Mimicking a Branchial Cleft Cyst: A Potential Pitfall. *Case Reports in Otolaryngology Volume.* 2015, Article ID 796358, 4: <http://dx.doi.org/10.1155/2015/796358>
13. Rosario PW, Fagundes TA, Maia FF, Franco AC, Figueiredo MB, Purisch S: Sonography in the diagnosis of cervical recurrence in patients with differentiated thyroid carcinoma. *J Ultrasound Med.* 2004, 23: 915-20. <https://doi.org/10.7863/jum.2004.23.7.915>
14. Som PM, Curtin HD, Mancuso AA: Imaging-based nodal classification for evaluation of neck metastatic adenopathy. *AJR.* 2000, 174:837-44. <https://doi.org/10.2214/ajr.174.3.1740837>
15. Ahn JE, Lee JH, Yi JS, et al.: Diagnostic accuracy of CT and ultra- sonography for evaluating metastatic cervical lymph nodes in patients with thyroid cancer. *World J Surg.* 2008, 32:1552-8. <https://doi.org/10.1007/s00268-008-9588-7>
16. LiVolsi AV: Papillary thyroid carcinoma: an update. *Modern Pathology.* 2011, 24:1. 10.1038/modpatho.1.2010.129
17. Thompson LDR: Update on follicular variant of papillary thyroid carcinoma with an emphasis on new terminology: noninvasive follicular thyroid

- neoplasm with papillary-like nuclear features. *Diagnostic Histopathology*. 2016, 22:171-8.
18. LDR Thompson: Malignant neoplasms of the thyroid gland. *Head and Neck Pathology*, 2nd Ed, Elseiver. 2013, <https://doi.org/10.1016/B978-1-4377-2607-7.00033-6>
  19. Dralle H, Machens A: Surgical approaches in thyroid cancer and lymph node metastases. *Best Pract Res Clin Endocrinol Metab*. 2008, 22:971-87. <https://doi.org/10.1016/j.beem.2008.09.018>
  20. Cooper DS, Doherty GM, Haugen BR, et al.: Revised American Thyroid Association management guidelines for patients with thyroid nodules and differentiated thyroid cancer. *Thyroid*. 2009, 19:1167-214. <https://doi.org/10.1089/thy.2009.0110>

