

Breast to Bowel: Mesenteric Bowel Ischaemia as a Rare Presentation for Breast Cancer in a Male

Michael Law

Received: 14 December 2019 Accepted: 1 January 2020 Published: 15 January 2020

Abstract

Intestinal ischaemia is a surgical emergency requiring rapid diagnosis, with reported mortality rates of up to 50%

Index terms—

1 Introduction

Intestinal ischaemia is a surgical emergency requiring rapid diagnosis, with reported mortality rates of up to 50%. 1,2 In patients presenting with intestinal ischaemia secondary to mesenteric venous thrombosis (MVT), over 50% were found to have a specific cause, including 13-16% secondary to underlying malignancy. 1,3 We report an interesting case of breast cancer presenting acutely with mesenteric venous thrombosis and intestinal ischaemia.

2 II.

3 Case Report

An 81-year-old male presented with sudden, severe abdominal pain, haematemesis and fresh perrectal bleeding. He was haemodynamically unstable, in rapid atrial fibrillation (AF), and required intubation due to delirium. His only past medical history was a cerebrovascular accident 30 years prior to admission, with no regular medications. Examination revealed a generally tender soft abdomen. Investigations showed lactate of 3.8 mmol/L (0.5-2.2 mmol/L), INR 1.2 (0.9-1.2), PT 16.5 secs (12-16 secs) and a PTT 32secs (25-35 secs). Computed tomography (CT) scan demonstrated superior mesenteric venous thrombosis with a long (190cm) segment of ileal ischaemia, (Fig. 1) a focal thrombus in the atrial appendage and chronic pulmonary emboli. Intravenous (IV) heparin was commenced and he underwent an urgent exploratory laparotomy, in which 1.90 metres of necrotic small bowel was found and resected. (Fig. 2) A re-look laparotomy at 48 hours showed no further ischaemic bowel and side-to-side stapled anastomosis was performed. The patient remained stable in ICU.

Subsequent hypercoagulability investigations were equivocal including no mural thrombus seen on transthoracic echocardiogram. A systems review and detailed clinical examination however identified an inverted left nipple and palpable breast mass which was confirmed on left breast ultrasound as a 2.3 cm spiculated mass (breast imaging reporting and data system (BI-RADS) score 5, (Fig. 3). Core biopsy confirmed a grade 2 invasive breast carcinoma (oestrogen/progesterone receptor +++ >90%, HER2 negative) and endocrine therapy was commenced after consultation with medical oncology. The patient was discharged to rehabilitation day 20 post-operatively on long term apixaban.

4 III.

5 Discussion

Mesenteric ischaemia accounts for 1:1000 acute hospital admissions 1 with embolism being the most common aetiology. Mesenteric venous thrombosis (MVT) is responsible for 10% of cases and is associated with the highest mortality. 1,4 Risk factors for mesenteric ischaemia include ischaemic heart disease, AF, hypertension, diabetes and kidney disease. 1,5 Patients commonly present with pain out of proportion to clinical findings, associated with a new cardiac arrhythmia. First-line management for MVT is anticoagulation with heparin infusion. 1,6 In addition to patients having risk factors for mesenteric ischaemia, other risk factors or aninheri

table thrombophilia is often identified. 1,3,7 As demonstrated in this case, patients presenting with MVT should be thoroughly evaluated for other sites of thrombus as 50% of patients have pre-existing or current deep vein thrombosis or pulmonary embolism. 8 Current guidelines also suggest that patients with MVT should be screened for hypercoagul ability, including measuring Protein C, S, anti thrombin III and Factor V levels. 7 Factor V Leiden is the most frequent hypercoagulable state and is found in 20-40% of MVT patients. 1 Other pre-disposing risk factors to consider include malignancy, portal hypertension, abdominal trauma, abdominal infection, acute pancreatitis, nephrotic syndrome, liver cirrhosis and splenomegaly. 1 Malignancy is reported in 13-16% of patients with MVT due to activation of the coagulation system, 3,9 and should be considered as an underlying cause. Myeloproliferative malignancies are present in 8-18% of patients with MVT, 7 but the authors are not aware of any studies to date that have examined differences in incidence of MVT in different malignancies. 7 As such, no formal guidelines exist to guide investigations to exclude underlying malignancy and rely on a systems review in both history and clinical examination. This may result in unexpected changes in ongoing management as illustrated by this patient's unexpected breast cancer diagnosis which is rare in males, accounting for only 0.5-1% of cases. 10 Whilst breast cancer has a lower reported risk when compared to other malignancies such as pancreatic, lung and stomach malignancies of causing venous thromboembolism (1-2%), this was the underlying cause for this patient's intestinal ischemia and acute surgical presentation. 9 In summary, patients with intestinal ischemia, especially those caused by MVT, should be investigated for underlying thrombophilia, but if this is negative, be considered for underlying malignancy. Our case highlights the importance of thorough clinical examination, which may yield rare but critical diagnoses, such as breast cancer in a male patient.

IV.

6 Disclosure Statement

The authors have no financial or conflicts of interest to declare.

7 Author Affiliations

Eastern Health Breast and Endocrine Unit, Melbourne.

Figure Legends

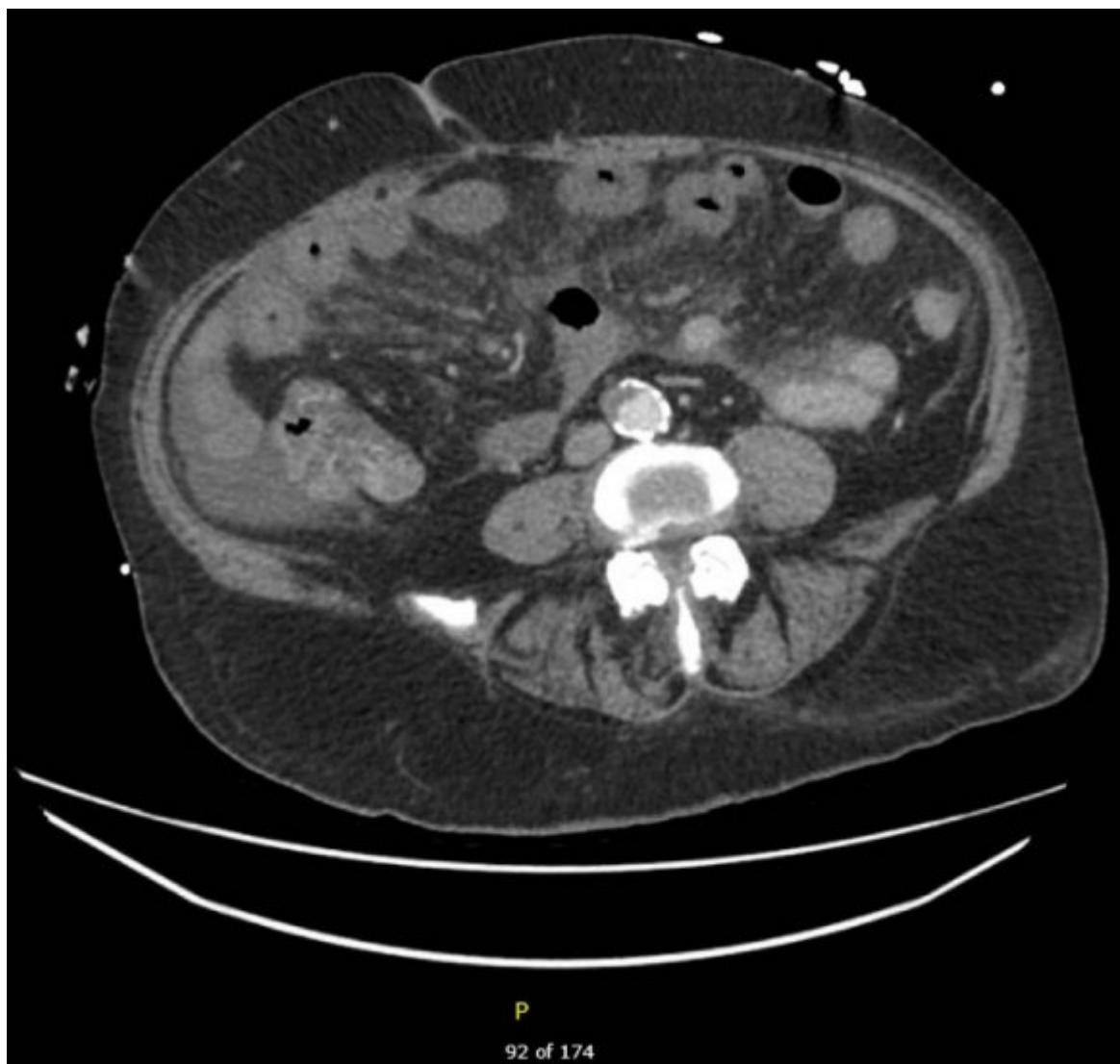
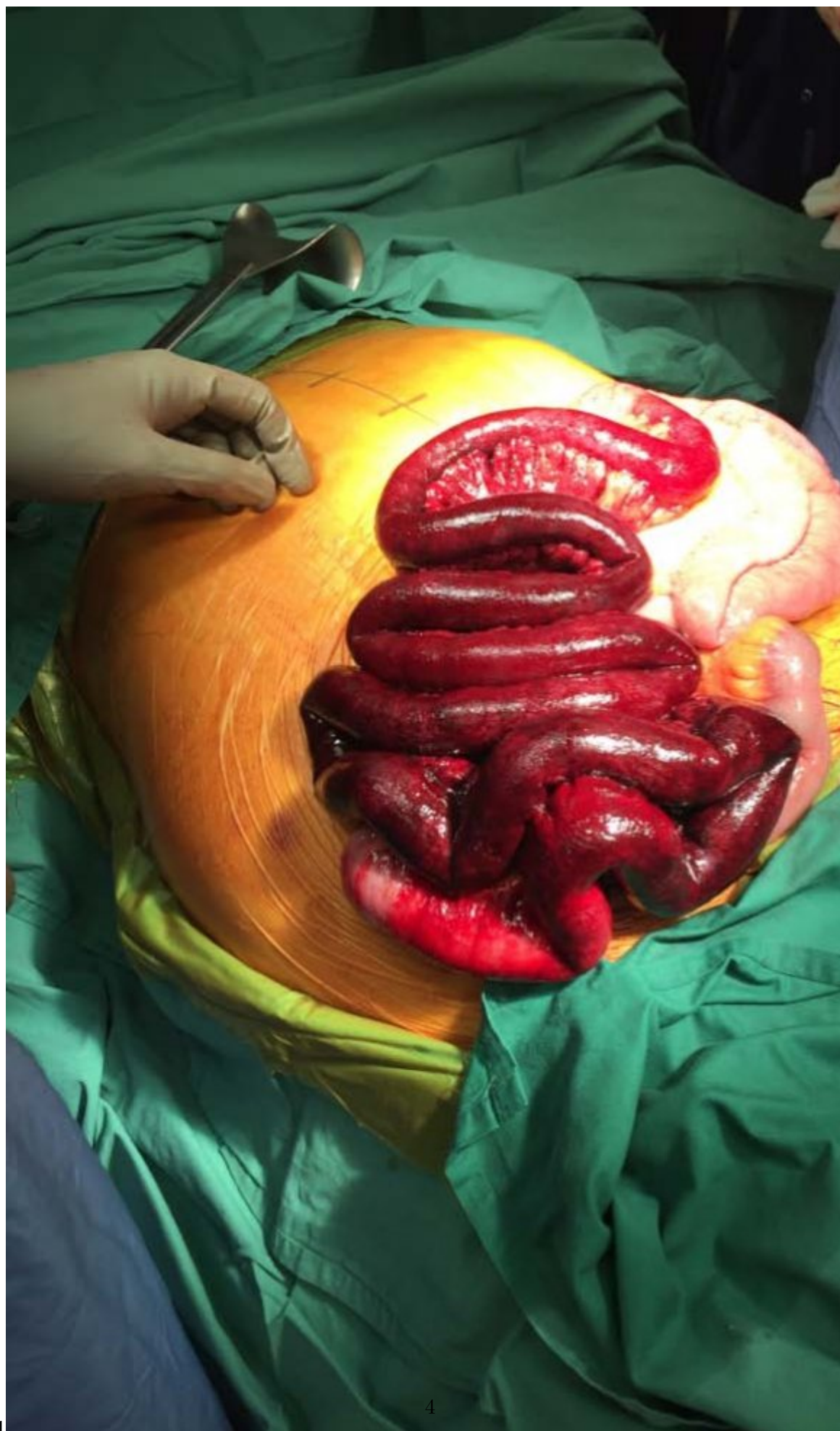

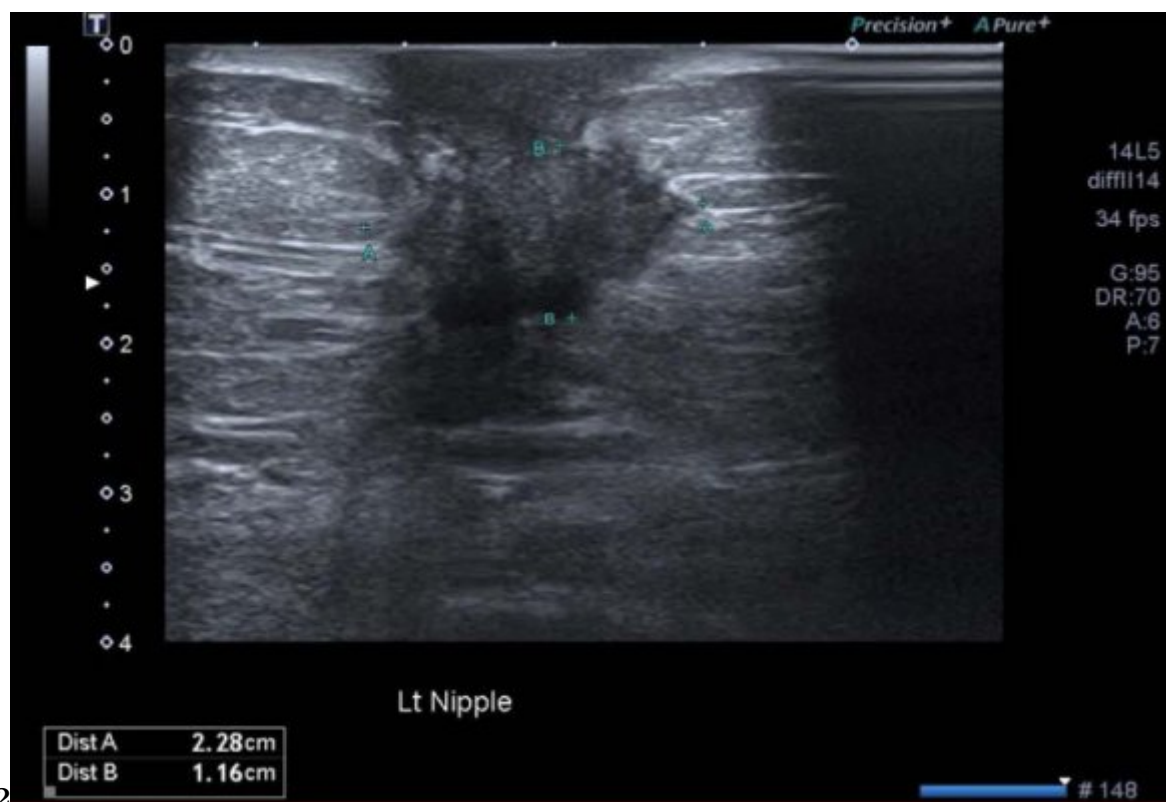Figure 1:



1

4

Figure 2: Figure 1 :



-
- 68 [Vokurka et al. ()] 'Acute mesenteric ischemia'. J Vokurka , J Olejnik , V Jedlicka . *Hepatogastroenterology* 2008.
69 55 (85) p. .
- 70 [Eltarawy et al. ()] 'Acute mesenteric ischemia: the importance of early surgical consultation'. I Eltarawy , Y
71 Etman , M Zenati . *Am Surg* 2009. 75 (3) p. .
- 72 [Kumar and Kamath ()] 'Acute superior mesenteric venous thrombosis: one disease or two?'. S Kumar , P S
73 Kamath . *Am J Gastroenterol* 2003. 98 p. 1299.
- 74 [Tilsed et al. ()] 'Guidelines: acute mesenteric ischaemia'. J Tilsed , A Casamassima , H Kurihara . *Eur J Trauma*
75 *Emerg Surg* 2016. 42 p. .
- 76 [Cangemi and Picco ()] 'Intestinal ischemia in the elderly'. J R Cangemi , M F Picco . *Gastroenterol Clin N Am*
77 2009. 38 p. .
- 78 [Kumar et al. ()] 'Mesenteric venous thrombosis'. S Kumar , M Sarr , P Kamath . *N Eng J Med* 2001. 345 p. .
- 79 [Tendler et al.] *Mesenteric venous thrombosis in adults*, D Tendler , T Lamont , P Grubel . UpToDate. (Internet)
- 80 [Aliosmanoglu et al. ()] 'Risk factors effecting mortality in acute mesenteric ischemia and mortality rates: a
81 single centre experience'. I Aliosmanoglu , M Gul , M Kapan . *Int Surg* 2013. 98 p. .
- 82 [Caine et al. ()] 'The hypercoagul able state of malignancy: pathogenesis and current debate'. G Caine , P
83 Stonelake , G Lip . *Neoplasia* 2001. (6) p. .
- 84 [Gradishar and Ruddy] *Up To Date [Internet]*. *Up To Date Inc*, W Gradishar , K Ruddy . p. 2019. (Breast
85 cancer in men. cited 6)
- 86 [UpToDate Inc (2019)] *UpToDate Inc*, 2019. 6 November 2019.