

# Coronary Artery Spasm-An Uncommon Condition after CABG

Cheung Hung-Leong

*Received: 15 December 2019 Accepted: 3 January 2020 Published: 15 January 2020*

## Abstract

Coronary artery bypass grafting (CABG) is one of the most common cardiac surgery done in Hong Kong for ischemic heart diseases. We report a case of a 55-year-old man who demonstrated native coronary artery spasm following on-pump CABG which was managed by intra-aortic balloon pump (IABP) insertion and vasodilators. Method: A 55-year-old man, ex-smoker, with history of PVD, presented with unstable angina. CABG was performed and the procedure was unremarkable. 2 hours after operation, patient developed sudden cardiac arrest. Bedside sternotomy was performed, findings was unremarkable. IABP was inserted and later further supported by VA ECMO. Coronary angiogram showed diffuse spasm all three native major coronary arteries, demonstrating competitive flow. All three native coronary arteries responded to Glyceryl trinitrate (GTN) infusion. Two bypass graft (LSV and LIMA) was patent. The coronary artery spasm improved with continuous GTN infusion.

**Index terms**— CABG, coronary artery spasm.

## 1 Coronary Artery Spasm-An Uncommon

Condition after CABG Lau Kwun-Wang Ambrose ? , Chengwai-Yeung Rechard ? , Chan Ho-Yan Howard ? & Cheung Hung-Leong ? Abstract-Aim: Coronary artery bypass grafting (CABG) is one of the most common cardiac surgery done in Hong Kong for ischemic heart diseases. We report a case of a 55-year-old man who demonstrated native coronary artery spasm following onpump CABG which was managed by intra-aortic balloon pump (IABP) insertion and vasodilators.

Method: A 55-year-old man, ex-smoker, with history of PVD, presented with unstable angina. CABG was performed and the procedure was unremarkable. 2 hours after operation, patient developed sudden cardiac arrest. Bedside sternotomy was performed, findings was unremarkable. IABP was inserted and later further supported by VA ECMO. Coronary angiogram showed diffuse spasm all three native major coronary arteries, demonstrating competitive flow. All three native coronary arteries responded to Glyceryl trinitrate (GTN) infusion. Two bypass graft (LSV and LIMA) was patent. The coronary artery spasm improved with continuous GTN infusion.

Results: This case illustrates coronary artery spasm, an uncommon post-CABG condition. It has an extremely high mortality and morbidity. It may occur anytime intra-operatively or immediate post-operative. It is still unclear on the actual etiology of coronary artery spasm after CABG. The standard for diagnosis is coronary angiogram, demonstrating diffuse coronary artery spasm responsive to intravenous injection of vasodilator agents. Management includes vasodilators, especially calcium channel blockers, supportive managemnt and Rho-inase inhibitor Conclusion: Our patient is fortunate to survive with minimal organ dysfunction and minimal functional impairment. We must be aware of this rare but extremely high mortality post CABG condition, and to act immediately.

## 2 Keywords: CABG, coronary artery spasm.

I.

## 3 Case Report

n ischemic heart diseases, first line treatment would be lifestyle modifications, followed by medical treatment (most commonly antiplatelets) and percutaneous coronary intervention (PCI). Coronary Artery Bypass Graft

(CABG) is mainly reserved for ischemic heart diseases refractory to optimal medical treatment, triple vessel diseases, left main diseases.

We report a case of 55-year-old man, exsmoker, presented with unstable angina. He was put on dual anti-platelet agents, but failed optimal medical therapy. He was also later found to be refractory to multiple PCI. He has also bilateral lower limb peripheral vascular diseases (PVD), with right common femoral artery and right superficial femoral artery stenosis with angioplasty done before.

As part of the work-up, coronary angiogram showed left main and triple vessel diseases. Preoperative echocardiography confirmed good left ventricle ejection fraction (60-65%). CABG procedure was performed with a long saphenous vein (LSV) to obtuse marginal (OM) branch and left internal mammary artery (LIMA) to left anterior descending (LAD) artery. Intra-operative transit-time flow measurement showed satisfactory flow to both LSV and LIMA grafts. Weaning from the cardiopulmonary bypass (CPB) was uneventful. The patient returned to cardiac care unit (CCU) in a stable condition with continuous low dose noradrenaline infusion. Patient was kept intubated in CCU. Patient's blood pressure was on high side and therefore systemic intravenous Glyceryl trinitrate (GTN) infusion was started at low dose.

2 hours after operation, patient developed sudden cardiac arrest with unmeasurable blood pressure. Cardiac monitoring showed ventricular fibrillation (VF). Shock was given and cardiopulmonary resuscitation (CPR) was initiated immediately. Bedside sternotomy was performed, and internal cardiac massage was carried out. There was no obvious bleeding or oozing from cardiac surface or suture lines. There was no sizeable pericardial effusion. Cardiac activity returned after 18 minutes of CPR. IABP was inserted via left femoral artery for hemodynamic support.

Patient was transferred to operating theatre for central VA ECMO (Veno-arterial Extracorporeal Membrane Oxygenation) as peripheral VA ECMO was contraindicated due to severe PVD. Intra-op TEE showed global hypokinesia especially at inferior and apex region. Transit-time flow measurement showed flow rate of 70mL/min for LIMA graft with a PI of 2.4, and flow rate of 86mL/min for LSV graft with a PI of 2.9.

Coronary angiogram after stabilization showed diffuse spasm all three native major coronary arteries (LAD, LCx, RCA), demonstrated competitive flow. All

## 4 Discussion

This case illustrates coronary artery spasm, an uncommon post-CABG condition. Literature reviewed was carried out for case reports post CABG coronary artery spasm. The incidence was reported to be between 0.8 % -1.3% among all CABG patients [1]. It has an extremely high mortality and morbidity. It may occur anytime intra-operatively or immediate postoperative. It may involve native coronary arteries or manipulated bypass grafts [2]. RCA is most commonly involved. It is still unclear on the actual etiology of coronary artery spasm after CABG, but literature review proposes several factors to be the culprit: oxidative stress, vascular damage, high levels of vasoconstrictors, electrolyte disturbances, hypothermia, hypocapnia, preoperative use of anti-hypertensives, and paradoxically high dose of nitroglycerine [3].

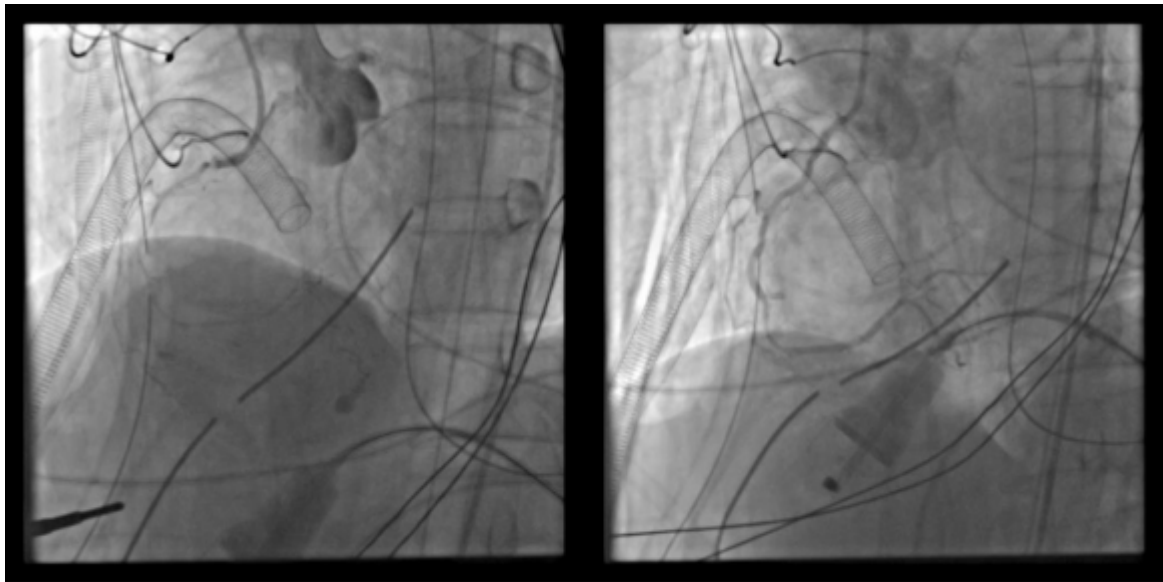
Coronary artery spasm is most commonly presented as ST segment elevation, hemodynamic instability and arrhythmias. Often the first sign of presentation is immediate cardiac arrest with VF [3]. The standard for diagnosis is coronary angiogram [4], demonstrating diffuse coronary artery spasm responsive to intravenous injection of vasodilator agents.

Several pre-operative measures were also proposed to avoid coronary artery spasm: avoid excessive manipulation of heart, avoid hypothermia, avoid excessive use of carbon dioxide in deair procedure (inducing vasoconstriction). Management options include conventional vasodilators, especially calcium channel blockers [3]. Some researchers also propose the usefulness of fasudil, a Rho-kinase inhibitor, in intractable severe coronary artery spasm after CABG resistant to conventional vasodilators [5].

Our patient is fortunate to survive with minimal organ dysfunction and minimal functional impairment. We must be aware of this rare but extremely high mortality post CABG condition, and to act immediately.

## 5 Conflict of interests:

The authors declare no conflict of interest. <sup>1</sup>



Left – coronary angiogram showing spasm of right coronary system  
Right – coronary angiogram showing relieve of spasm of right coronary system, responsive to GTN infusion

Figure 1:



- 
- 92 [Unai et al. ()] ‘Coronary artery spasm following off-pump coronary artery bypass surgery’. S Unai , H Hirose ,  
93 G Cook , Y Lee , S Miura , I Kigawa , S Fukuda , T Miyairi . *Int Heart J* 2014. 55 p. .
- 94 [Baek et al. ()] ‘Native coronary artery and grafted artery spasm just after coronary artery bypass grafting: a  
95 case report’. J H Baek , S S Han , D H Lee . *J Korean Med Sci* 2010. 25 p. .
- 96 [Lorusso et al. ()] ‘Refractory spasm of coronary arteries and grafted conduits after isolated coronary artery  
97 bypass surgery’. R Lorusso , E Crudeli , F Lucà , De Cicco , G Vizzardi , E , D ’aloia , A Gelsomino , S .  
98 *Ann ThoracSurg* 2012. 93 p. .
- 99 [Hosoba et al. ()] ‘Successful management of refractory lethal coronary spasm References Références Referencias  
100 after off-pump coronary bypass grafting’. S Hosoba , T Suzuki , N Takashima , T Kinoshita , S Kuryanagi ,  
101 H Nota , T Asai . *Ann Thorac Cardiovasc Surg* 2012. 18 p. .
- 102 [Inokuchi et al. ()] ‘Usefulness of Fasudil, a Rho-kinase Inhibitor, to Treat Intractable Severe Coronary Spasm  
103 after Coronary Artery Bypass Surgery’. K Inokuchi , A Ito , Y Fukumoto , T Matoba , A Shiose , T Nishida  
104 , . . Shimokawa , H . *Journal of Cardiovascular Pharmacology* 2004. 2020. 44 (3) p. .