

Prosthodontic Treatment Options in Implant Dentistry-A Review Article

Dr. Sheetal Parab

Received: 6 September 2021 Accepted: 4 October 2021 Published: 15 October 2021

Abstract

The rehabilitation of patients with dental implants can be a challenging and meticulous procedure. Due to the anatomic variations in different patients a standardized treatment approach cannot be followed. From the initial diagnosis itself the practitioner must plan the case bearing the eventual end in mind in order to provide the patient with a prosthesis that serves both purposes of functionality as well as esthetics. This article aims to highlight certain parameters such as available bone, bone densities, remaining ridge heights, tooth proportions, number of implants and the positions that the teeth would assume that would dictate the type of prosthetic options available to the patient. It would further aid the clinician to decide a stepwise treatment approach and in turn help in communication with the dental laboratory as well as the patient.

Index terms—

1 Introduction

The management of a patient with complete or partial edentulism can pose an arduous task to a clinician if a stepwise and organized treatment plan is not followed. Some of the important considerations and challenges include the anatomy of the maxilla and mandible, the pattern of bone resorption, quality of available bone for implants, development of pontic form, the role of the arches in speech, and perception of esthetics. Different clinical scenarios dictate different prosthetic options which can be broadly classified as fixed and removable options which will be described in this article.

2 II.

3 Prosthetic Options in Implant Dentistry

Implant dentistry is unique because additional foundation units may be created for a desired prosthodontic result. Thus, a range of treatment options is available to most partially and completely edentulous patients. In the past, greater emphasis has been placed on the bone available for implant insertion which determines the position and number of implants and consequently, final prosthesis design. 1 Classification of patients is needed not only for diagnostic purposes but also to facilitate treatment planning, patient education, and professional communication among different specialists. 2 Misch has classified the different types of implant prostheses available for patients while Simon and Raigrodski have specifically classified the types of residual ridge deficiencies and addressed the need for use of gingival prosthesis. 3 In 1989, Misch proposed five prosthetic options FP-1, FP-2, FP-3, RP-4 and RP-5 [Table ??].

4 Table 1: Mischs Classification of Implant Prosthesis

Author: e-mail: rahul13.shah@gmail.com

5 Available bone

The quality and quantity of the available bone have an important role to play in determining the number of implants that can be placed in a patient as well as the esthetic appeal that the prosthesis will eventually assume. To reap the maximum benefits of implant dentistry, it is important to treatment plan with the end in mind. A thorough patient history must be recorded and a treatment plan must be formulated with the help of diagnostic aids, such as models, wax-ups, and guides. Radiographs of the concerned areas must be taken to determine the implant positions and numbers. Misch and Judy (1985) gave a classification system for the available bone with treatment options for all categories. 4 FP-1 restorations: For ideal implant placement and natural esthetic appearance of final prosthesis require Division A bone FP-2 or FP-3 restorations: These prosthetic options may be considered depending on the amount of bone loss and lip positions for Division B and C bone. RP-4 or RP-5 restorations: These conditions may require osteoplasty considering interarch space to accommodate denture teeth for Division C bone.

IV.

6 Bone Density

Besides its external architecture, bone also has an internal architecture represented by its density. The strength of the bone supporting the endosteal implant is directly related to its density. The density of the bone must hence be accounted for as an important factor to be considered. The anterior mandible has greater bone density than the anterior maxilla. The posterior mandible has poorer bone density than the anterior mandible. The poorest bone density exists in the posterior maxilla and is associated with dramatic failure rates. 5 Fig. ??: Misch's Classification of Different Bone Densities

7 V. Number and Position of Implants

Depending on the diagnostic models, radiographic aids, and maxillomandibular relationship of the patient the ideal number of implants and the position that they would assume can be determined. The number of implants used to support a completely implant-supported restoration in the edentulous mandible usually ranges from 5 to 9 in the mandible, with at least four of these implants inserted between the mental foramina. A greater implant number in the completely edentulous maxilla is indicated to compensate for the less dense bone and more unfavorable biomechanics and ranges from 6 to 10. At least two or three of these implants should be placed in the pre-maxilla, depending on the arch shape and other force factors. 6 Other factors such as arch form, whether round, U, V, or tapered must be accounted for to achieve the best force distribution and have a good AP (anteroposterior spread) of the implants.

8 Abutment Position

An implant placed in an improper position can compromise the final results in terms of esthetics, biomechanics, and maintenance. The most compromising position for an implant is too facial because no prosthetic "trick" exists to mask it, resulting in compromised esthetics, phonetics, lip position, and function. The per mucosal position of the implant abutment is of particular importance for FP-1 prostheses. The ideal position is directly under the incisal edge position of the anterior natural tooth and under the central fossa of posterior natural teeth to be replaced. ?? VII.

9 Parafunctional Habits

Any aberrant habit that the patient has must be accounted for at the stage of the initial treatment planning process. Habits such as bruxism and clenching must be noted and corrective measures must be taken before the inception of any treatment. Antianxiolytic drugs, psychological counseling, and habitbreaking appliances can be provided to the patient. During the treatment planning of the final prosthesis, care must be taken to provide an implant-protected Occlusal scheme. This scheme aims to minimize force on the implants, distribute forces over a larger surface area, and protect the implants from aberrant forces caused by parafunctional habits. Certain measures such as maintaining light-centric contacts, having a mutually protected occlusal scheme must be noted.

10 VIII.

11 Esthetic Considerations

Depending on the available bone, maxillomandibular relationship the esthetic requirements of the patient can be fulfilled. Based on the resorption pattern of the patient an FP1, FP2, FP3, or else an RP4, RP5 prosthesis can be fabricated, where only the crown and where the gingival tissue is also replaced respectively. The esthetics can be further enhanced based on the material used.

Porcelain Fused To Metal-The main problem encountered with this restoration is related to the added bulk of metal used in the substructure to keep porcelain to its ideal 2 mm thickness.

Hybrid prosthesis-An alternative option in such situations is the hybrid prosthesis. Because acrylic acts as an intermediary between the porcelain teeth and metal substructure, the impact force during dynamic occlusal

94 loading also may be reduced. Hence, hybrid prostheses are indicated for implant restoration in large crown height
95 spaces as a general rule.

96 **12 Conclusion**

97 Implants have become the treatment of choice in many, if not most, situations when missing teeth require
98 replacement. In the current years, the field of implant dentistry has gained a large amount of popularity. With
99 proper evaluation, diagnosis, and treatment planning partial as well as complete edentulism can be well managed
using implant therapy and shows a lot of promise for the future.



Figure 1:

Type	Definition
FP-1	FP which replaces only the crown and appears like a natural tooth
FP-2	FP which replaces the crown and a portion of the root Crown contour appears normal in the occlusal half but is elongated or hypercontoured in the gingival half
FP-3	FP which replaces missing crowns and gingival color and portion of the edentulous site
RP-4	RP which is mainly an overdenture completely supported by implants
RP-5	RP which is an overdenture supported by both soft tissue and implant

FP=Fixed prosthesis, RP=Removable prosthesis

2

Figure 2: Fig. 2 :

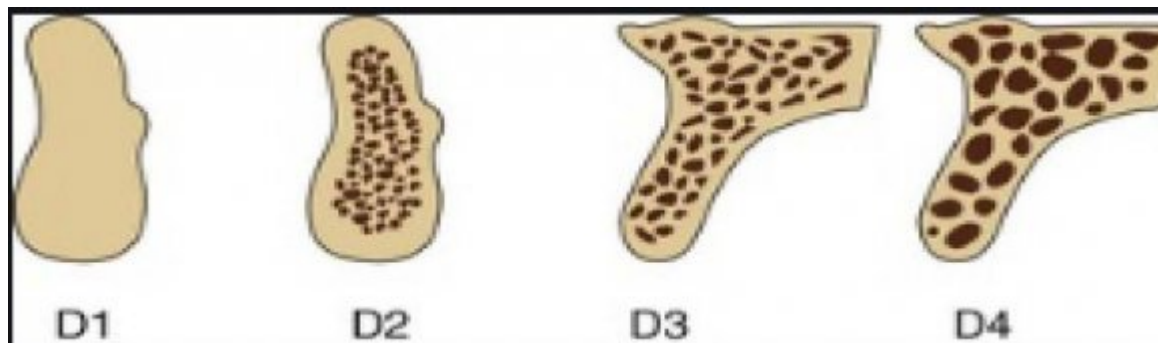
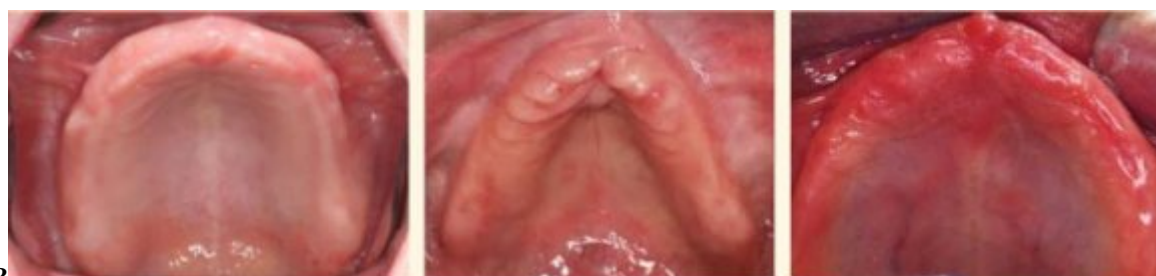

Figure 3:



3

Figure 4: Fig. 3 :

-
- 101 [Misch and Judy ()] 'Classification of partially edentulous arches for implant dentistry'. C E Misch , K W Judy
102 . *Int J Oral Implantol* 1987. 4 p. .
- 103 [Misch ()] *Contemporary Implant Dentistry*, C E Misch . 1999. St. Louis, MO: Mosby. p. . (2nd ed)
- 104 [Kim et al. ()] 'Cortical and cancellous bone thickness on the anterior region of alveolar bone in Korean: A study
105 of dentate human cadavers'. H J Kim , S K Yu , M H Lee , H J Lee , H J Kim , C H Chung . *J Adv Prosthodont*
106 2012. 4 p. .
- 107 [Dholam and Gurav ()] 'Dental implants in irradiated jaws: A literature review'. K P Dholam , S V Gurav . *J*
108 *Cancer Res Ther* 2012. 8 (1) p. . (Suppl)
- 109 [Simon and Raigrodski ()] 'Gingival-colored ceramics for enhanced esthetics'. H Simon , A J Raigrodski .
110 *Quintessence Dent Technol* 2002. 25 p. .
- 111 [Winter et al. ()] 'Micromotion of dental implants: Basic mechanical considerations'. W Winter , D Klein , M
112 Karl . *J Med Eng* 2013. 2013. p. 265412.