



GLOBAL JOURNAL OF MEDICAL RESEARCH: I
SURGERIES AND CARDIOVASCULAR SYSTEM
Volume 21 Issue 2 Version 1.0 Year 2021
Type: Double Blind Peer Reviewed International Research Journal
Publisher: Global Journals
Online ISSN: 2249-4618 & Print ISSN: 0975-5888

Papillary Muscle Hypertrophy as an Variant of HOCM- A Case Report

By Dr. Sunil Dighe, Dr. Kalyan Munde, Dr. Piyush Kalantri,
Dr. Zahidullah Khan & Dr. Mahesh Bodke

Grant medical College and Sir JJ Group of Hospital

Abstract- According to the 2011, ACCF/AHA guideline for the diagnosis and treatment of hypertrophic cardiomyopathy (HCM), the morphologic diagnosis of HCM is based on the presence of a hypertrophied as well as non-dilated left ventricle in the absence of another cardiac or systemic disease capable of producing the magnitude of that hypertrophy (usually ≥ 15 mm in adults or the equivalent relative to body surface area in children). Although the papillary muscles (PMs) are an anatomic part of the left ventricular (LV) chamber, the significance and diverse morphology of these structures in HCM has not been characterized in literature. Papillary muscle (PM) hypertrophy is a rare echocardiographic finding, with very few cases reported in the literature. Therefore, solitary PM hypertrophy can have clinically important for the screening of HCM as a newly identified subtype of or an early form of HCM. We are reporting the same case in which papillary muscle hypertrophy was a culprit for HOCM.

GJMR-I Classification: NLMC Code: WG 460



Strictly as per the compliance and regulations of:



© 2021. Dr. Sunil Dighe, Dr. Kalyan Munde, Dr. Piyush Kalantri, Dr. Zahidullah Khan & Dr. Mahesh Bodke. This is a research/review paper, distributed under the terms of the Creative Commons Attribution-Noncommercial 3.0 Unported License <http://creativecommons.org/licenses/by-nc/3.0/>), permitting all non-commercial use, distribution, and reproduction in any medium, provided the original work is properly cited.

Papillary Muscle Hypertrophy as an Variant of HOCM- A Case Report

Dr. Sunil Dighe ^α, Dr. Kalyan Munde ^σ, Dr. Piyush Kalantri ^ρ, Dr. Zahidullah Khan ^ω & Dr. Mahesh Bodke [¥]

Abstract- According to the 2011, ACCF/AHA guideline for the diagnosis and treatment of hypertrophic cardiomyopathy (HCM), the morphologic diagnosis of HCM is based on the presence of a hypertrophied as well as non-dilated left ventricle in the absence of another cardiac or systemic disease capable of producing the magnitude of that hypertrophy (usually ≥ 15 mm in adults or the equivalent relative to body surface area in children). Although the papillary muscles (PMs) are an anatomic part of the left ventricular (LV) chamber, the significance and diverse morphology of these structures in HCM has not been characterized in literature. Papillary muscle (PM) hypertrophy is a rare echocardiographic finding, with very few cases reported in the literature. Therefore, solitary PM hypertrophy can have clinically important for the screening of HCM as a newly identified subtype of or an early form of HCM. We are reporting the same case in which papillary muscle hypertrophy was a culprit for HOCM.

I. INTRODUCTION

Hypertrophic obstructive cardiomyopathy (HOCM) refers to those subjects with significant dynamic left ventricular outflow tract (LVOT) obstruction due to mechanical causes. Most of them presents with asymmetrical septal hypertrophy which result in Dynamic systolic anterior motion (SAM) of mitral leaflets¹. There are also few patients of HCM who are genotypically positive but phenotypically negative in HOCM. The cardiac phenotype of HCM shows great diversity in the degree and pattern of hypertrophy (asymmetric, concentric, or apical), age of onset, and clinical course. Solitary papillary muscle (PM) hypertrophy, a form of HCM manifested as predominant PM hypertrophy sparing the rest of other LV segments, has recently gained much attention to its mechanical cause for left ventricular outflow tract (LVOT) pressure gradient formation^{2,3}. The clinical diagnosis of hypertrophic cardiomyopathy (HCM) is conventionally made with cardiac imaging, at present, most frequently two-dimensional echocardiography. still, the use of cardiac magnetic resonance (CMR) imaging is increasing. Morphological papillary muscle anomalies without features of phenotypic LV hypertrophy which include isolated papillary muscle hypertrophy had gradually been recognized as variant in uncommon HCM^{4,6}. The clinical features of LV mid-cavity obstruction

caused by papillary muscle hypertrophy may vary from asymptomatic to dyspnea, angina, syncope, and even sudden cardiac death^{4,6}. Solitary papillary muscle hypertrophy as an uncommon variant form of HCM with coexisted additional, accessory papillary muscle may develop abnormally high resting LV mid-wall pressure gradient without SAM or significant regional LV wall hypertrophy. CMR provides complete tomographic imaging of the heart with high spatial resolution images and is an excellent imaging method to assess the PMs. It is also a important tool for further investigation and assessment of the different types of cardiomyopathies, since there are also some typical findings in this exam that may suggest a particular pathology or etiology.

II. CASE REPORT

A 33 yr old male presented to our hospital with chest discomfort-, Breathlessness at rest, palpitation, and syncope. The patient was known case Bicuspid Aortic Valve with Aortic Stenosis. He was a tobacco chewer and alcoholic addict. On admission, his heart rate was 60/min. BP 90/60 mm of hg. He has undergone Balloon Aortic Valvotomy 15 yrs back. Laboratory tests were performed, but the results were unremarkable which include complete blood count, liver and kidney function tests, serum levels of muscle and cardiac enzymes. A mid-systolic ejection murmur was heard along the left sternal border with chest X-ray showed no pulmonary congestion. ECG has LV strain Pattern. 2D Echo suggestive of severe Aortic Stenosis and Aortic Valve was showing Calcification within. We planned Coronary Angiography before sending a patient for Aortic Valve replacement.

Author ^α ^σ ^ρ ^ω [¥]: Department of Cardiology, Grant medical College and Sir JJ Group of Hospital, Byculla, Mumbai.
e-mail: sunil0732@gmail.com

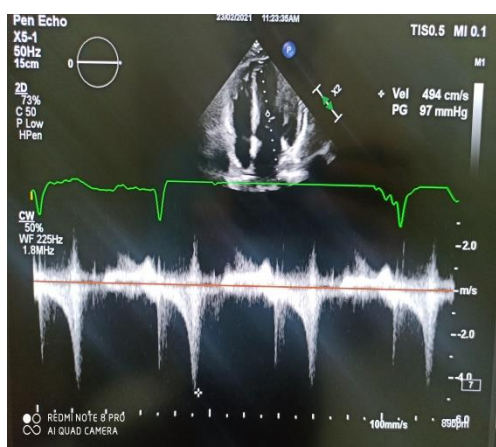


Figure 1

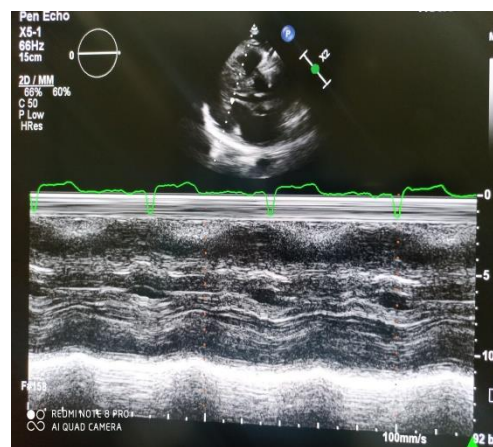


Figure 2

Figure 1: Mid Cavity Gradient in Apical 4 chamber View Figure 2: M mode of Parasternal long-axis view through Papillary muscle

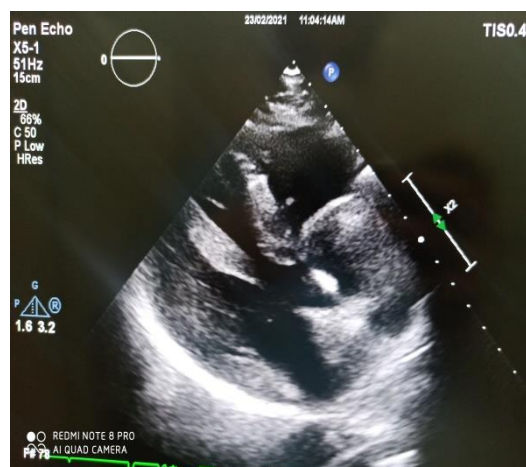


Figure 3

Figure 3: Parasternal Long Axis View showing Hypertrophy of Papillary Muscle

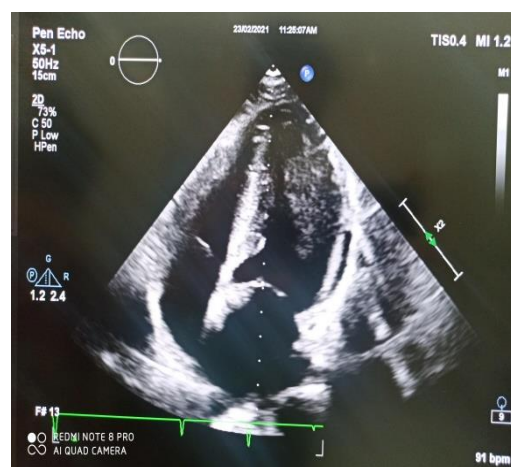


Figure 4

Figure 4: Apical 4 Chamber View showing hypertrophy of papillary muscle

2D Echo imaging of similar patient when focused on looking for aortic valve it was showing gradient at LVOT. Being no Much hypertrophy of the Interventricular septum and posterior wall, the gradient was further evaluated. it was found that Papillary muscle was thickened to a greater extent, which was creating a pressure gradient of 97 mm of hg, as shown in figure 1. Figure 2 also demonstrates the M mode showing compromised LV cavity at end Diastole. Similarly, in figure 1 we can see the calcified aortic Valve causing restriction of leaflet motion. patient was a known case of bicuspid aortic valve and i/v/o of severe nature (Peak/Mean Trans aortic gradient 89/45 mm of hg) of aortic stenosis. Gradients across mid cavity increased on doing Valsalva maneuver by the patient, which suggested a dynamic obstruction at mid cavity and the papillary muscle hypertrophy was the etiology for it. The thickness of the papillary muscle was 14 mm in our

patient, which was considered significant to cause an obstruction.

III. DISCUSSION

The clinical significance of abnormalities and hypertrophy of the PMs is a matter of debate. This morphological finding requires further investigation, as there are few articles published, and little information on this entity. The published literature Suggests that morphological abnormalities in PMs, such as anomalous insertion, are found in the context of LV wall hypertrophy and that they are not uncommon in HCM, especially in apical hypertrophy. But they have also been reported as the only morphological abnormality in a subgroup of patients with HCM. It has also been suggested that isolated PM hypertrophy is a possible variant of HCM. These changes may evolve, along with progressive hypertrophy over time.

The relevant abnormal findings in this patient are the hypertrophied PMs (with normal ventricular mass), hypertrophy has been associated, in some studies and case reports, with abnormal T-wave inversion and with a possible variant of HCM or an initial stage of this disease.

Clinically, HCM is usually recognized by maximum LV wall thickness ≥ 15 mm, with a thickness of 13–14 mm considered borderline, particularly in the presence of other compelling information (in presence of family history of HCM). Genetic testing for HCM is available as an important diagnostic tool. Still, it has limitations since about 50% of patients have an identifiable mutation in such patient, and a some proportion have variants in which the pathogenicity of the mutation is uncertain.

Despite this, the next step will be to perform a genetic test since this case may be an atypical presentation or initial stage of HCM. Stress echocardiography will also be important to determine the presence of ventricular gradients. As per the results of genetic tests and the patient's clinical course of disease, assessment and screening of patients first-degree relatives should be considered.

IV. CONCLUSION

Considering the available information on PM hypertrophy, the case presented may represent a gap in our knowledge of HCM. More investigation are needed in such situation, which may affect the definition of HCM and subsequently diagnosis, management and Prognosis of this HCM patients. With this case, particularly with its images, we states that HCM is a complicated disease that generally goes beyond the left ventricle walls. Such cases of HCM should not be missed, especially with availability of new imaging methods such as echocardiography and CMR. Papillary muscle hypertrophy defined as at least one of the two papillary muscles if is more than 1.1 cm in either vertical or horizontal diameter⁴⁻⁵. Echocardiography can be a useful tool for evaluating papillary muscle hypertrophy, which can cause significant gradient across LVOT. LVOT obstruction, in spite of less ventricular mass, papillary muscle hypertrophy should be considered a variant in the clinical setting.

REFERENCES RÉFÉRENCES REFERENCIAS

1. Williams LK, Frenneaux MP, Steeds RP. Echocardiography in hypertrophic cardiomyopathy diagnosis, prognosis, and role in management. *Eur J Echocardiogr.* 2009; 10:iii9–iii14.
2. Austin BA, Kwon DH, Smedira NG, Thamilarasan M, Lever HM, Desai MY. Abnormally thickened papillary muscle resulting in dynamic left ventricular outflow tract obstruction: an unusual presentation of hypertrophic cardiomyopathy. *J Am Soc Echocardiogr.* 2009; 22(105):105–106.
3. Pacileo M, Cirillo P, Prastaro M, Chiariello M. Latent left ventricular outflow tract obstruction induced by abnormal hypertrophic papillary muscle caused myocardial ischemia. *Int J Cardiol.* 2009; 132:270–272. doi: 10.1016/j.ijcard.2007.08.03
4. Kobashi A, Suwa M, Ito T, Otake Y, Hirota Y, Kawamura K. Solitary papillary muscle hypertrophy as a possible form of hypertrophic cardiomyopathy. *Jpn Circ J.* 1998; 62:811–816. doi: 10.1253/jcj.62.811.
5. Maron MS. Clinical utility of cardiovascular magnetic resonance in hypertrophic cardiomyopathy. *J Cardiovasc Magn Reson.* 2012; 14:13. doi: 10.1186/1532-429X-14-13
6. Correia AS, Pinho T, Madureira AJ, Araujo V, Maciel MJ. Isolated papillary muscle hypertrophy: a variant of hypertrophic cardiomyopathy? Do not miss a hypertrophic cardiomyopathy. *Eur Heart J Cardiovas Imaging.* 2013; 14: 296. doi: 10.1093/ehjci/jes195