

Pulmonary Vein Thrombosis Complicating Lung Cancer, Case Report and Literature Review

Zeine El Abasse¹, Sara Abouradi², Ejjebl Samia³, Salim Arous⁴, Mohamed El Ghali Benouna⁵ and Rachida Habbal⁶

¹ ibn rochd hospital center Casablanca Morocco

Received: 13 September 2021 Accepted: 2 October 2021 Published: 15 October 2021

Abstract

Background: Pulmonary vein thrombosis (PVT) is a rare clinical entity. The aetiologies are very diverse ranging from malignancy, to hyper-viscosity syndromes and other etiologies. the diagnosis is difficult because the patients may present with dyspnea, cough or hemoptysis which may be confused with an etiology of the pulmonary parenchyma. Case Report: We present a case of a 40-year-old man with a history of metastatic lung cancer diagnosed with PVT through CT scan showing the mass compressing along the right lower pulmonary vein. Transthoracic echocardiography revealed a left atrium compressed by a mediastinal tissue mass with acceleration of pulmonary venous flow on doppler, this patient was treated with low molecular weight heparin associated with palliative treatment of his cancer. Conclusions: Patients with PVT often may often have a nonspecific clinical presentation. Anticoagulation should be considered in patients with PVT given the life-threatening complications such as peripheral embolization.

Index terms—

1 Introduction

ulmonary vein thrombosis (PVT) is relatively rare and under diagnosed but fatal complication in clinical practice. Etiologies can be classified into surgical-related and non-surgical-related etiologies (1) Surgical PVT can occur as a complication following lung transplantation, lobectomy, and radiofrequency catheter ablation (1) Non-surgical etiologies can be due to cardiac causes such as atrial myxoma, pulmonary venous narrowing, atrial fibrillation, or non-cardiac related causes such as primary or secondary lung malignancies, polycythemia, and hemoglobinopathies such as sickle cell disease (1)(2)(3). Only few reports have been described this lethal complication after open lobectomy (4), lung transplantation or in association with metastatic carcinoma however some cases have been described as idiopathic. Pulmonary venous thrombosis may lead to systemic organ and peripheral artery infarction such as in the brain, kidneys, spleen, and

We report here a case of PVT in metastatic lung cancer and the objective of this work is to draw attention to this rare entity with its potentially fatal complications.

Author ? ? ? ? ¥ §: Department of cardiology, Hospital University Center Ibn Rochd, Casablanca, Morocco. e-mail: abassedr@gmail.com II.

2 Case Presentation

This is a 40-year-old man who presented for 1 months dry cough and large effort dyspnea He also reported weight loss of 7 kg in 10 months and hemoptysis complicated by a deterioration of the general condition. As antecedents, he smoked 1-2 packs/ day. On physical examination, the patient the patient was hemodynamically and respiratory stable with blood pressure (BP) =130/70 mmHg; heart rate (HR) =80 bpm; respiratory rate

(RR) =16 rpm, cardiac auscultation was normal. Pulmonary auscultation revealed crackling rales in the lower third of the right hemithorax. The laboratory analysis revealed anaemia with a haemoglobin level of 9.8 g/dL (normal: 11. 5-15), leukocytosis of $14.7 \times 10^3/\text{mm}^3$ (normal: $4. 0-10 \times 10^3$), an elevated C-reactive protein (CRP) level of 75 mg/dL (normal: 0-6)

The assessment of the extension of his tumor objectified bone and hepatic metastases, after a multidisciplinary consultation including cardiologist oncologist and pulmonologist, this patient was treated with low molecular weight heparin associated with palliative treatment of his cancer. During the next 90 days the clinical conditions worsening and the patients died 5 months after the Diagnosis. The PVT is a very rare condition, since the pulmonary circulation has an extensive network of collaterals for pulmonary venous drainage (2). The PVT usually presents in relation to a known antecedent that justifies the direct venous pulmonary lesion, reason why we consider crucial to rule out this entity in the patients with presentation symptoms and signs as hemoptysis, pulmonary infiltrate and/or thoracic pain after a potentially damaging procedure for the pulmonary veins such as venous anastomosis in lung transplant patients, lobectomies and lung carcinomas, among others (4).

Several causes of PVT have been identified, which include surgery involving veins such as lung transplantation or lobectomy; radiofrequency catheter ablation (RFCA) for atrial fibrillation(6); sclerosing mediastinitis; and certain primary or secondary tumors of the lung. Less common causes include: atrial myxoma; congenital pulmonary venous narrowing; and mitral stenosis with an obstructing left atrial clot (7) The case of this patient was discovered during a thoracoabdominal CT scan in the context of his metastatic lung cancer objectifying the PVT .

Any thoracic neoplasm can potentially extend to the pulmonary veins (8), Primary lungneoplasms can give rise to stenosis or invasion of the intrapericardial portion of the pulmonary veins and the left atrium(9)

Extension of a lung neoplasm to the left atrium through apulmonary vein can result in death caused by cardiac arrest or massive systemic tumor embolization of multiple organs (10) The most frequent malignant cause of PVT is a primary lung neoplasm (11,12). However, PVT can also occur following a metastatic cancer, such as metastatic sarcoma (11), liposarcoma (13), small cell lung cancer (14), and mantle cell lymphoma of the small intestine(2). Our patient was diagnosed with primary lung cancer Multiple factors probably contribute to thrombosis in pulmonary veins associated with malignancy. These include a hypercoagulable state and mechanical compression of the veins with resultant stasis and damage to the endothelium. (12)This case present a mediastinal mass that compress the pulmonary vein.

The Symptoms depend by the number and the severity of affected pulmonary veins, the collaterals and the rate of progression (15). The form of presentation varies widely and may include dyspnea, chest pain, cough or hemoptysis but these nonspecific symptoms are more frequently related to other diseases such as community-acquired pneumonia (CAP), pulmonary arterial infarction or vasculitis (6). Our patient presented with dyspnea complicated by hemoptysis Because of the PVT is a life-threatening entity and the variability in presenting symptoms, clinicians must have heightened sensitivity to the presence of the condition, although the diagnosis is now simpler given the increase in radiological explorations performed in our patients.

CXR finding could be nonspecific such as pulmonary and interstitial opacities and pleural effusion, so the final diagnosis is usually obtained with transesophageal echocardiogram, magnetic resonance imaging, which can distinguish between tumor and thrombus, or CT after injection of intravenous contrast in the late phase to reduce flow artifacts. (11).

Echocardiography may demonstrate the extension of the thrombus into the atrium; a transesophageal echocardiogram would be preferable over a transthoracic echocardiogram (16)Although not all thrombi can be directly visualized with twodimensional imaging, measurement of the blood flow velocities in the pulmonary veins can indirectly suggest this diagnosis (i.e. pulmonary vein blood flow acceleration indicates venous obstruction) (17) Pulmonary vein thrombosis can lead to gangrene of the lung and can require a repeat intervention, although development of collateral circulation through the intercostal veins may prevent this complication (18) In addition to pulmonary y infarction, PVT can often be complicated by pulmonary edema, and right ventricular failure (19) peripheral embolism can also occur and lead to limb ischemia, stroke and even a renal infarction. (20,21) Unfortunately, there are no specific guidelines for the treatment of PVT, but anticoagulation and antitumor therapy are used in non resectable tumors (2,7) Other forms of treatment include thrombectomy, which is considered if medical therapy fails and also has been tried successfully for PVT after lobectomy and lung transplant; however, limited data are available in malignancy-induced PVT (22) Lobectomy is considered when PVT is complicated with massive hemoptysis or pulmonary necrosis.

Anticoagulation therapy has been considered to effectively decrease the thrombus and prevent thrombosis formation. In previous reports, approximately 80% of patients with a thrombus in the PV stump preceived anticoagulation therapy which led to disappearance of the PV thrombus in most of them, without systemic embolization. (20,23) Therefore, anticoagulation therapy should be recommended in patients with a thrombus in the PV stump.

This patient was treated with low molecular weight heparin associated with palliative treatment of his cancer.

3 IV.

4 Conclusion

Pulmonary vein thrombosis presents in a nonspecific manner. The diagnosis is made with echocardiography. Establishing the diagnosis is crucial given the serious adverse outcomes, including peripheral embolization. The treatment remains challenging including anticoagulation in addition to treating the underlying condition ¹

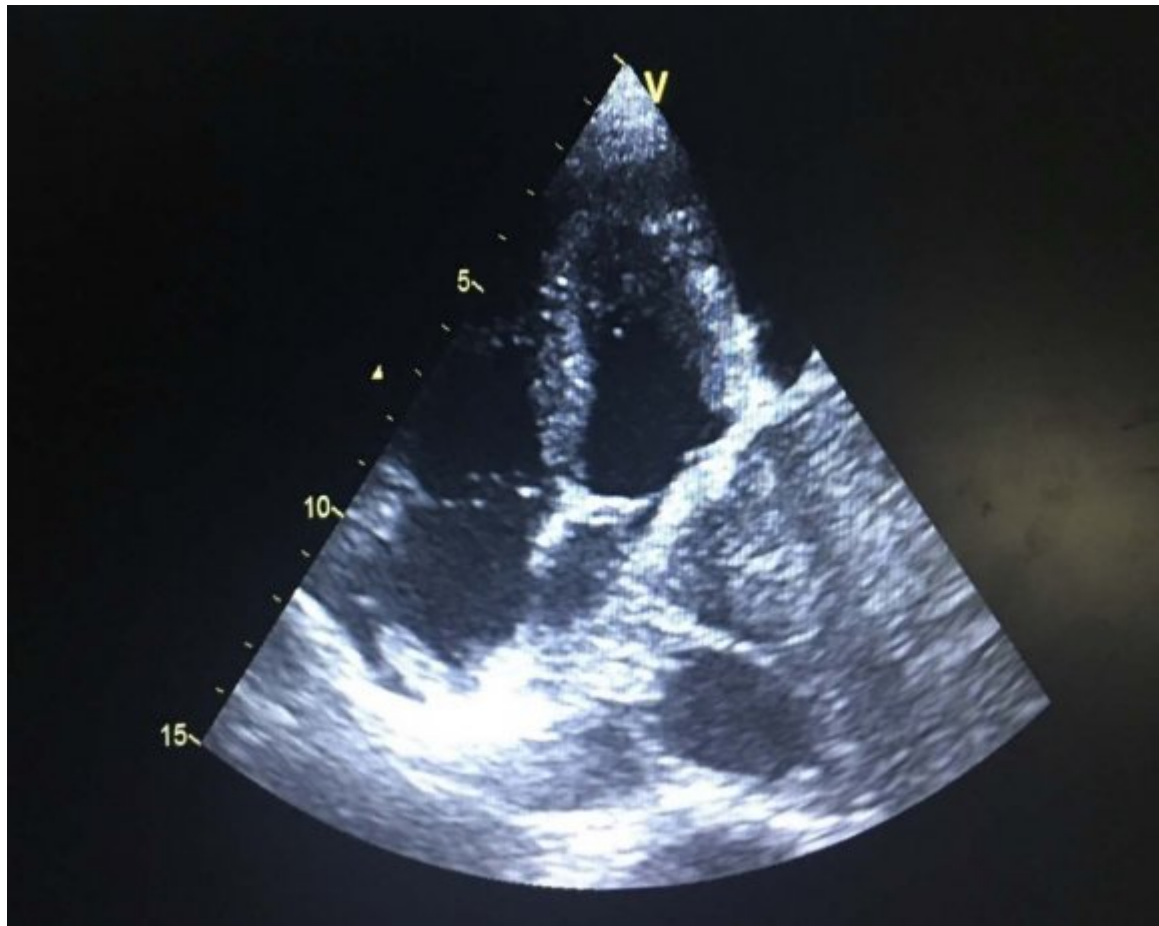


Figure 1:

¹© 2021 Global JournalsPulmonary Vein Thrombosis Complicating Lung Cancer, Report and Literature Review

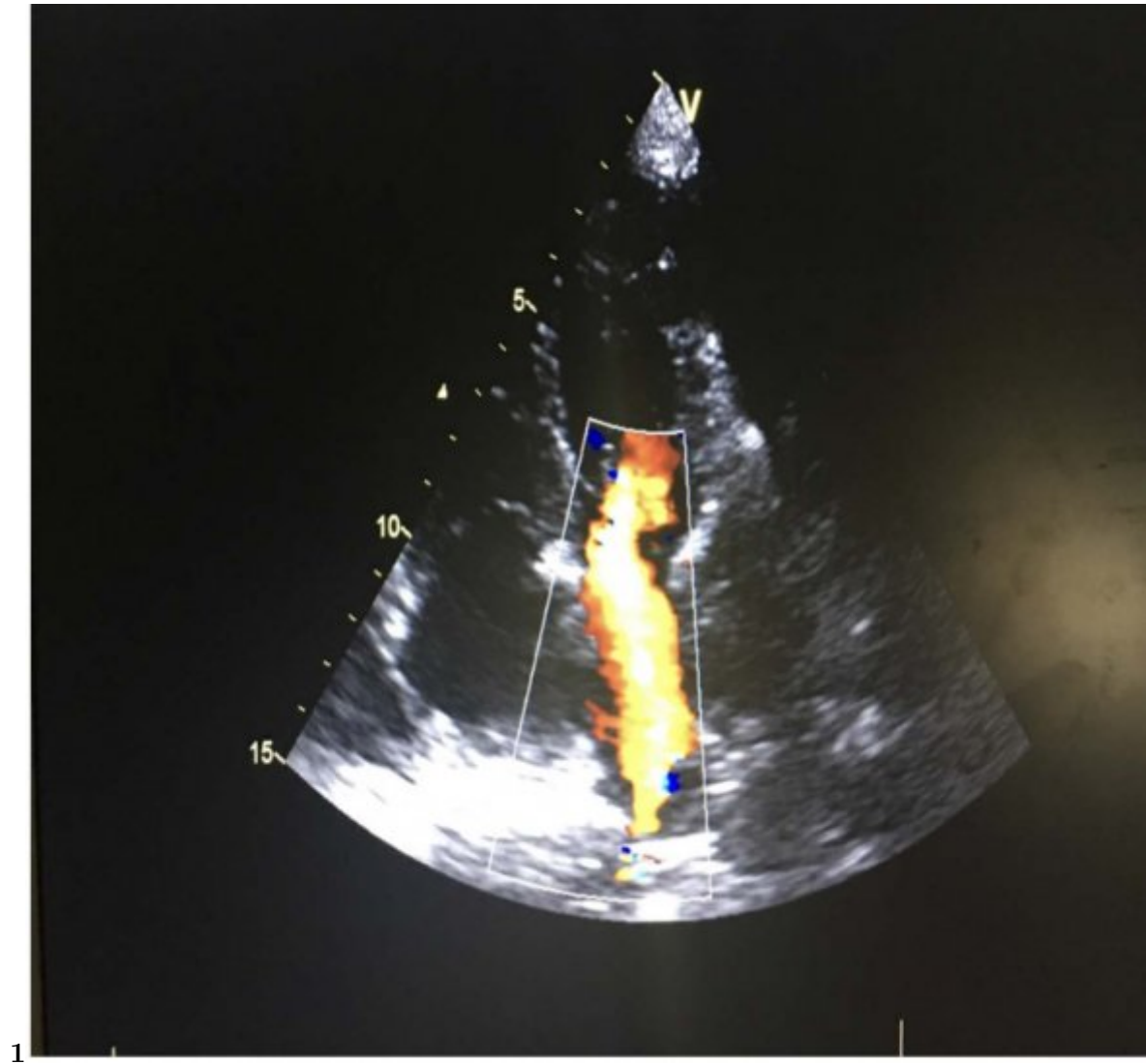


Figure 2: Figure 1 :

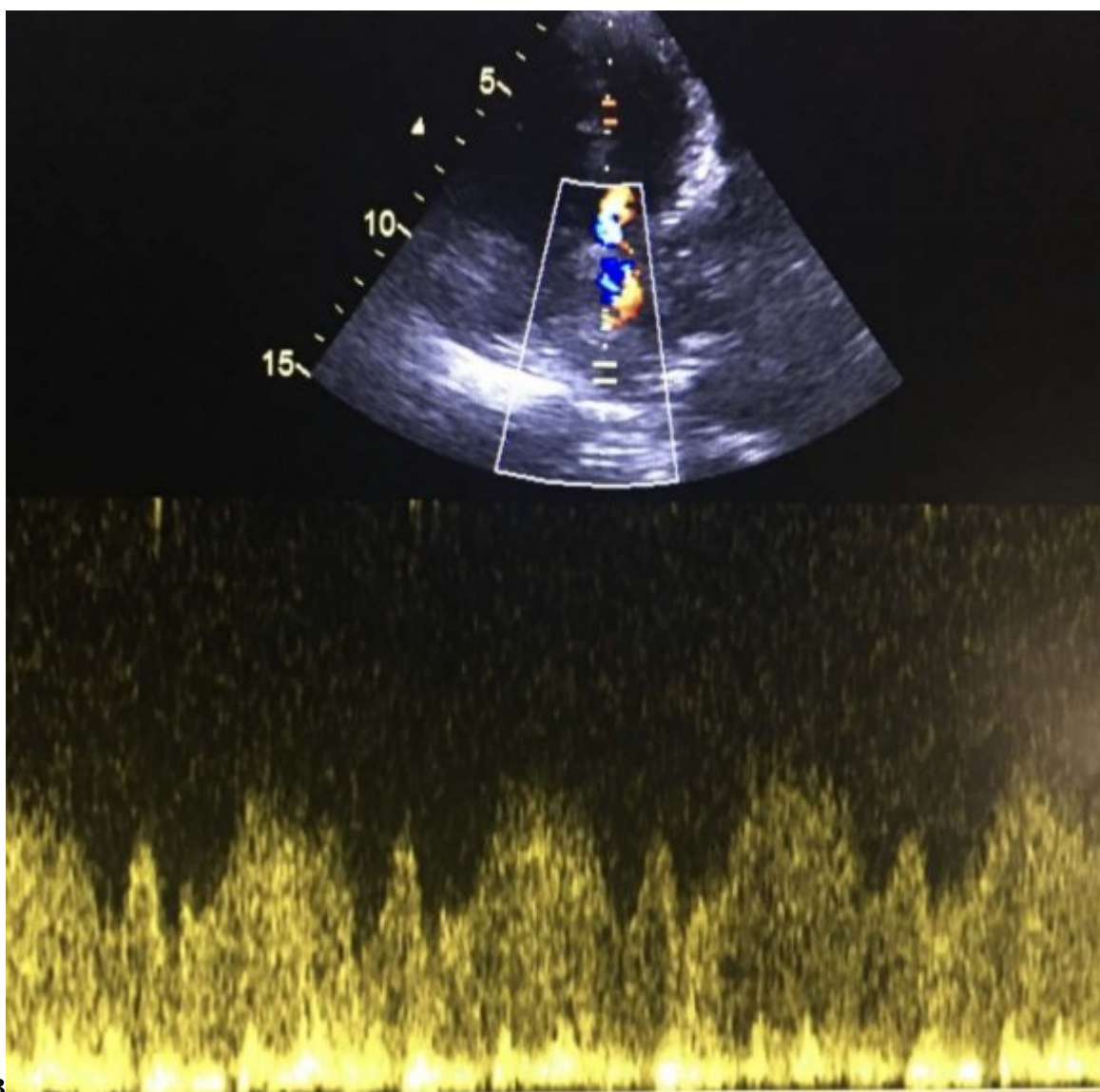


Figure 3: Figure 2 :Figure 3 :

[Sur] , Disponible Sur . <http://www.cureus.com/articles/5343-pulmonary-vein-thrombosis-a-recent-systema->

[Sur] , Disponible Sur . 10.1016/S0735-1097%2816%2931103-2. <https://www.jacc.org/doi/full/10.1016/S0735-1097%2816%2931103-2>

[Cancer: Significance in Assessing Local Extent with CT: Journal of Computer Assisted Tomography. juill ()]

, *Cancer: Significance in Assessing Local Extent with CT: Journal of Computer Assisted Tomography. juill*

1998. 22 (4) p. .

[Cavaco et al. ()] 'Idiopathic pulmonary fibrosis associated with pulmonary vein thrombosis: a case report'. R A

Cavaco , S Kaul , T Chapman , R Casaretti , B Philips , A Rhodes . *Cases Journal. déc* 2009. 2 (1) p. 9156.

[Lin et al. ()] 'Intracardiac extension of lung cancer via the pulmonary vein'. M-T Lin , S-C Ku , M-Z Wu , C-J

Yu . *Thorax* 2008. 20 (12) p. .

[Grau et al. ()] 'Lack of Evidence for Pulmonary Venous Thrombosis in Cryptogenic Stroke: A Magnetic

Resonance Angiography Study'. A J Grau , S O Schoenberg , C Lichy , F Buggle , M Bock , W Hacke

. *Stroke. mai* 2002. 33 (5) p. .

[Porres et al. ()] 'Learning from the Pulmonary Veins'. D V Porres , Á? P Morenza , E Pallisa , A Roque , J

Andreu , M Martínez . *RadioGraphics. juill* 2013. 33 (4) p. .

[Harada et al. ()] 'Left superior pulmonary venous thrombosis complicated with splenic infarction after video-

assisted thoracoscopic left upper lobectomy'. R Harada , K Yunoki , H Sugiyama , H Yamamoto , J Kondo ,

K Watanabe . *Journal of Cardiology Cases. juill* 2017. 16 (1) p. .

[Woodring et al. ()] 'Metastatic chondrosarcoma to the lung with extension into the left atrium via invasion of

the pulmonary veins'. J H Woodring , B Bognar , C S Van Wyk . *Clinical Imaging. sept* 2002. 26 (5) p. .

[Holmes et al. ()] 'Pulmonary Vein Stenosis Complicating Ablation for Atrial Fibrillation'. D R Holmes , K H

Monahan , D Packer . *JACC: Cardiovascular Interventions. avr* 2009. 2 (4) p. .

[Kim et al. ()] 'Pulmonary Vein Thrombosis'. N H Kim , C A Roldan , B K Shively . *Chest. août* 1993. 104 (2)

p. .

[Genta ()] 'Pulmonary vein thrombosis after bilobectomy and development of collateral circulation'. P R Genta

. *Thorax. 1 juin* 2003. 58 (6) p. .

[Burri et al. (2006)] 'Pulmonary vein thrombosis after lower lobectomy of the left lung'. E Burri , J Duwe , C

Kull , C Glaser , C A Maurer . *J Cardiovasc Surg oct* 2006. 47 (5) p. .

[Tamizifar et al. ()] 'Pulmonary Vein Thrombosis After Metastatic Liposarcoma'. B Tamizifar , M Zadeh , E

Foroghi . *Med Arh* 2012. 66 (1) p. 68.

[Cywinski et al. ()] 'Pulmonary vein thrombosis after sequential double-lung transplantation'. J B Cywinski , L

Wallace , B M Parker . *Journal of Cardiothoracic and Vascular Anesthesia. avr* 2005. 19 (2) p. .

[Saoraya and Inboriboon ()] 'Pulmonary Vein Thrombosis Associated with a Large Hiatal Hernia'. J Saoraya ,

P C Inboriboon . *The Journal of Emergency Medicine. mars* 2013. 44 (3) p. .

[Akiode and Prakash] *Pulmonary Vein Thrombosis Associated With Metastatic Carcinoma*, O Akiode , G

Prakash . p. 3.

[Chaaya and Vishnubhotla ()] *Pulmonary Vein Thrombosis: A Recent Systematic Review*, G Chaaya , P

Vishnubhotla . 2017. (cité 12 mars 2021)

[PULMONARY VEIN THROMBOSIS: IT'S NOT ALWAYS PULMONARY EMBOLISM | Journal of the American College of C

PULMONARY VEIN THROMBOSIS: IT'S NOT ALWAYS PULMONARY EMBOLISM | Journal of the

American College of Cardiology, (Internet. cité 12 mars 2021)

[López-Reyes et al. ()] 'Pulmonary venous thrombosis secondary to radiofrequency ablation of the pulmonary

veins'. R López-Reyes , A García-Ortega , A Torrents , L Fedec , P Calvillo , E A Libreros-Niño . *Respiratory*

Medicine Case Reports 2018. 23 p. .

[Nakano et al. ()] *Recurrent cerebral attack caused by thrombosis in the pulmonary vein stump in a patient with*

left upper lobectomy on anticoagulant therapy: case report and literature review. surg case rep, T Nakano , M

Inaba , H Kaneda . 2017. 3 p. 101.

[Manabe et al. ()] *Renal Infarction in a Patient with Pulmonary Vein Thrombosis after Left Upper Lobectomy.*

Case Rep Nephrol Urol, S Manabe , Y Oshima , M Nakano , T Fujii , T Maehara , K Nitta . 2014. 4 p. .

[Cipriano et al. ()] 'Report of a lung carcinoma extended to the left atrium through pulmonary vein'. F Cipriano

, L U Dessoti , A J Rodrigues , W V De Andrade Vicente , F Chahud , Prb Evora . *J Thorac Dis. janv* 2018.

10 (1) p. .

[Chan and Neumann ()] 'Small cell lung carcinoma invading the pulmonary vein and left atrium as imaged by

PET/CT'. V Chan , D Neumann . *Eur J Nucl Med Mol Imaging. déc* 2005. 32 (12) p. .

[Ichimura et al. ()] 'Thrombus Formation in the Pulmonary Vein Stump after Left Upper Lobectomy: A Report

of Four Cases'. H Ichimura , Y Ozawa , H Nishina , S Shiotani . *Ann Thorac Cardiovasc Surg* 2014. 20 p. .

(Supplement)