

1 A Study of Giant Ovarian Tumors Presenting with Higher  
2 Incidence of Torsion: A Journey of my Experience in Covid-19  
3 Pandemic at Tertiary Care Centre

4 Dr. Rajshree Dayanand Katke

5 Received: 10 June 2021 Accepted: 4 July 2021 Published: 15 July 2021

---

7 **Abstract**

8 The ovarian cases presenting to the gynecology are not new. However, during the COVID -19  
9 pandemic, a varied presentation was observed and hence demanded a study of such  
10 cases. Methodology: A cross-sectional observational case study of 20 gynecology cases with  
11 ovarian tumors operated during the COVID-19 pandemic from October 2020 to March 2021 at  
12 Grant Government Medical College; Mumbai. Results and Conclusion: The patients mainly  
13 presented with a chief complaint of abdominal distension; dyspepsia, and pain in the  
14 abdomen. Other presenting complaints included menstrual irregularities and menorrhagia,  
15 and difficulty in micturition. The age group studied comprised from 25 -65 years of age. The  
16 patients belonged to upper and upper-middle socioeconomic class and were mainly from the  
17 high -income group. The patients presented from both urban and rural residential areas.

---

19 **Index terms**— pandemic; torsion; COVID -19; huge ovarian tumor; gynecology; tumors.

20 A Study of Giant Ovarian Tumors Presenting with Higher Incidence of Torsion: A Journey of my Experience  
21 in Covid-19 Pandemic at Tertiary Care Centre

22 Dr. Rajshree Dayanand Katke

23 Abstract-Objective: The ovarian cases presenting to the gynecology are not new. However, during the COVID  
24 -19 pandemic, a varied presentation was observed and hence demanded a study of such cases.

25 Methodology: A cross-sectional observational case study of 20 gynecology cases with ovarian tumors operated  
26 during the COVID-19 pandemic from October 2020 to March 2021 at Grant Government Medical College;  
27 Mumbai.

28 **1 Results and Conclusion:**

29 The patients mainly presented with a chief complaint of abdominal distension; dyspepsia, and pain in the  
30 abdomen. Other presenting complaints included menstrual irregularities and menorrhagia, and difficulty in  
31 micturition. The age group studied comprised from 25 -65 years of age. The patients belonged to upper and  
32 upper-middle socioeconomic class and were mainly from the high income group. The patients presented from both  
33 urban and rural residential areas. The ovarian tumors were giant, with sizes ranging from 30 x 35 centimeters  
34 to 20 x 25 centimeters. The tumors underwent torsion for more than five turns in most of the cases with onset  
35 of the gangrenous ovary in some cases; these cases were managed with great surgical expertise and precision  
36 and timely intervention to minimize the intraoperative and post-operative complications; The histopathological  
37 report included epithelial tumors like serous and mucinous cystadenomas and non-epithelial tumors like granulosa  
38 cell tumors and fibrosarcoma.

39 The management of such cases was challenging because of the effects of the COVID-19 pandemic and the  
40 results of lockdown. In the period of lockdown, the emergency health services were available but still because of  
41 fear or some other reasons, the patients have not turned up to the specialist doctors in spite of they were having  
42 dull aching pain and enlarged tumor. When they came to us; they were already having the torsion of the huge  
43 tumor.

## 2 Criteria for Testing

i. A woman with respiratory illness with one of the following ii. History of travel to abroad in the last 14 days iii. Is a close contact of a laboratory proven positive patient iv. She is a health care worker herself v. Hospitalized with features of severe acute respiratory illness.

? In the reproductive period, non-inflammatory and inflammatory diseases of the lower genital tract, such as abnormal uterine bleeding and pelvic inflammatory disease, respectively, are common. Agynecologist's decision is fundamental in the definition of elective procedures that may be postponed depending on the general and clinical status of the patient and the availability of access to clinical treatment.

## 3 II.

## 4 Materials and Methods

A cross sectional observational case study of 20 gynaecological cases operated during the COVID-19 pandemic from a period of October 2020 to March 2021 at Grant Government Medical College, Mumbai.

## 5 III.

## 6 Results and Discussion

### 7 a) Distribution of cases as per age

The most common age group presentation being between 41-50 years of age group that is almost half of the study group followed by women in the age group of 31 -40 years and those in the age group of > 50 years.

### 8 b) Distribution of cases as per presenting symptoms

The most common complaint amongst the women who were symptomatic was b pain in abdomen in 30 % of the cases. Around 20 % of the cases were asymptomatic.

### 9 c) Distribution of cases as per Duration of presenting symptoms

Most of the cases had a history of onset of symptoms for more than 6 months, the cause of it can be attributed to the lockdown and the non availability of elective services.

? The patients mainly presented with a chief complaint of abdominal distension ,dyspepsia and pain in abdomen. Other presenting complaints included menstrual irregularities and menorrhagia and difficulty in micturition. The age group studied comprised from 25 -65 years of age.

The patients belonged to upper and upper middle socioeconomic class and the patients presented from both urban and rural residential areas.

The ovarian tumors were huge with size ranging from 30 x 35 centimeters to 20 x 25 centimeters.

The tumors underwent torsion for more than 5 turns In most of the cases with onset of gangrenous ovary in some cases, however were managed with great surgical expertise and precision and timely intervention so as to minimize the intra -operative and postoperative complications.

The histopathological report included epithelial tumors like serous and mucinous cystadenomas and non epithelialtumors like granulosa cell tumors and fibrothecoma were mainly from the high income group. The ovarian cases presenting to the gynecology is not new.

However during the COVID-19 pandemic a varied presentation was observed and hence demanded a study of such cases. Some of the selected cases are mentioned as follows-

## 10 CASE 1

A Case of 30 years old, married since 14 years Parity 3, Living 3, who presented with acute pain in abdomen. Her Ultrasound Abdomen + Pelvis was suggestive of heterogeneous to isoechoic solid lesion in left adnexa measuring 10.8 x 1.3 x 5.1 cm with ovarian vein engorgement & displacing the uterus inferiorly. cystic areas seen within suggestive of neoplastic lesion On Examination, her general condition was fair, vitals normal, no pallor/edema/icterus, cardiovascular/ respiratory system -within normal limits. On per abdomen examination, a 10x 8 cm hard, firm mass felt, irregular margins, lower border palpated, restricted mobility, generalised tenderness and guarding was present. On per speculum examination, white discharge was seen, uterus not felt separately from mass.

Tumor markers weresent: CA125 -7.25, CEA-2.38, rest tumor markers-WNL Contrast Enhanced Computed Tomography done on 11/2/2021 was suggestive of torsion of ovary along with part of fallopian tube.

On 13/2/2021, Patient was taken up for Emergency exploratory laparotomy done with ovarian mass excision. Frozen section was suggestive of germ cell tumor.

---

95 Histopathology was suggestive of mixed germ cell tumor (yolk sac tumor + dysgerminoma). Patient withstood  
96 the procedure well. Post operative monitoring done, followed by chemotherapy with Bleomycin + etoposide +  
97 Docetaxel.

## 98 11 CASE 2

99 A case of 37 years old, unmarried, nulligravida with right tubo-ovarian mass, with ventriculoperitoneal shunt,  
100 presented to outpatient department with pain abdomen, irregular menses.

101 On Examination, her general condition -fair, vitals normal, no pallor/edema/icterus, cardiovascular/ respira-  
102 tory system -within normal limits. On per abdomen examination, a mass of 30 weeks felt over abdomen, irregular  
103 margins present, firm to hard in consistency, immobile, local rise of temperature noted. A 60 yrsold, married  
104 since? years, parity 3, living 3, all normal deliveries, tubal ligation not done, post menopausal since 10-15 years,  
105 came with complaints of pain abdomen in right side.

106 On examination: general condition fair, vitally stable, no pallor/ edema/ icterus, cardiovascular/ respiratory  
107 system -within normal limits On Per abdomen -soft, minimal tenderness over right iliac fossa noted. On per  
108 speculum -cervix was pulled up, atrophied. Per vaginally a cystic mass felt in the right fornix, mobile, non  
109 tender,? uterus,? right adnexal mass, cervix pulled up, deviated to the left. Tumor markers-ca 125 -10.2 u / ml,  
110 LDH-325 U/L, CEA -1.9, beta hcg -5.4, AFP -13.

111 On 10/3/2021-Patient underwent exploratory laparotomy with total abdominal hysterectomy with bilateral  
112 salpingectomy with bilateral oophorectomy. Pt withstood the procedure well. post operatively patient was well.  
113 Histopathological report-sex cord stromal tumor, fibrothecoma.

## 114 12 CASE 4

115 A 42 years old Parity 3, Living 3 with a huge mass in abdomen and pain in abdomen on and off since 1 year.  
116 on per abdomen examination a cystic mass of 10 x 15 cm in hypogastric region extending from umbilicus to  
117 lower abdomen, regular margins, mobility+, non tender. On per speculum examination, cervix was taken up.  
118 On per vaginum examination, a 22 weeks mass felt, cystic in consistency with mass covering the right iliac fossa,  
119 extending upto umbilicus, right fornix obliterated.

120 On 1/2/2021-Ultrasound (A+P) suggestive of 17 x 21 22 cms complex solid cystic lesion with septations, likely  
121 arising from ovary, likely malignant etiology.

122 Tumor marker were sent, B hcg 0.1, CA19.9-2.6, CEA 1.1, AFP 1.37, CA 125-1

123 On 20/3/2021, exploratory laparotomy with retroperitoneal mass excision with Total Abdominal mass excision  
124 with B/L salpingo-oophorectomy. Histopathology report suggestive of Spindle cell tumor with differential  
125 diagnosis being-1. Low grade Fibromyxoid Sarcoma, 2. PEComa, 3. Lymphangioliomyomatosis

## 126 13 CASE 5

127 A 60 years. Parity 2, Living 2 came with complaint of pain in abdomen. On examination: general condition fair,  
128 vitally stable, no pallor/edema/icterus, cardiovascular/respiratory system -within normal limits On per abdomen  
129 examination a 24 weeks mass in hypogastrium, right iliac region, extending above umbilicus, regular margin, lower  
130 border felt, cystic in consistency, with restricted mobility felt. On per speculum examination, cervix pulled down  
131 and backwards. On per vaginum examination, uterus could not be felt separately. The unusual increased incidence  
132 of huge abdominal masses to our gynecological department raised a need to study the effects of lockdown. A  
133 similar effect of covid 19 pandemic leading to lockdown and inaccessibility of health facilities was studied that  
134 lead to a conclusion that although COVID-19 does not directly affect pregnancy outcomes, it has indirect adverse  
135 effects on maternal and child health. (2) ? These patients have had complaints like pain in abdomen for more  
136 than a year, however due to non availability of certain facilities like limitation of transport facility, cessation of  
137 elective surgical procedures, conversion of hospitals to COVID designated centres, led to a decreased accessibility  
138 of immediate medical help to these patients. ? As a result of which despite having symptoms they had a delay in  
139 the management of their cases. However administrative regulatory activities like lockdown were a need of hour  
140 in order to contain the rampant spread of the COVID -19 and reduce the morbidity and mortality associated  
141 with it. ? The epithelial and non epithelial tumors showed a greater incidence of torsion of adnexal mass with  
142 tumor thereby leading to gangrenous and necrotic changes and an acute abdomen.

143 In the modern era of medicine, such huge mucinous ovarian tumours have become rare in the current medical  
144 practice, as most of the cases are detected early during routine gynaecological examinations or on ultrasound.  
145 However this was not the case during lockdown. Conservative surgery as ovarian cystectomy and salpingo-  
146 oophorectomy is satisfactory for benign lesions.4 Frozen section is very significant to know the malignant variation  
147 of this tumour and that helps in the management of the patient. As in the huge tumours, the anatomical planes  
148 get distorted, so the surgical expertise is required to prevent the complications (3) Management of ovarian tumors  
149 depends on the patients age, the size of the cyst and its histopathological nature for large ovarian masses with a  
150 risk of malignancy and hence a staging laparotomy and intraoperative frozen section has their importance. (4)  
151 The ovarian tumors both benign as well as malignant can undergo torsion and have been reported in numerous  
152 studies. Patient can present with acute abdomen due to torsion. In a case presenting with acute abdomen with  
153 lump abdomen, ovarian mass with torsion should be considered as differential diagnosis. (5) The disruption of

## 14 CONCLUSION

154 services has resulted into health being affected in all ways including family planning services. It has been studied  
155 that there is a huge unmet need of contraception available. Hence a proper mitigation of family planning is of  
156 utmost demand, although restraining of COVID 19 pandemic is also important (6) IV.

### 157 14 Conclusion

158 Although the measures like lockdown have been imposed for the containment of the COVID 19 infection, the  
159 increased cases of torsion of adnexal masses was reported in my experience. With proper management protocols  
160 and with all universal safety precautions the cases were managed with a great surgical expertise. Non epithelial  
161 ovarian cancers mainly granulosa cell tumours have excellent prognosis. Sex cord stromal tumours with an  
162 indolent course have good short-term prognosis, but with a greater risk of relapse.

163 ? More and more studies are needed to be devised to study their clinical presentations, course, prognosis and  
164 role of different adjuvant therapies. Such studies are required at an international level for increasing the disease  
165 free survival rates, reducing relapse rates and to decrease the morbidity and mortality associated with such rare  
166 ovarian cancers. ? The management of such cases was challenging because the effects of COVID pandemic and  
167 effect of lockdown that restricted the availability and easy accessibility of health services thereby increasing the  
incidence of torsion of ovarian tumors. <sup>1</sup>

Age in years	No of cases	percentage
15- 20 years	1	5%
21-30 years	1	5%
31-40 years	4	20%
41-50 years	10	50%
> 50 years	4	20%

Figure 1:

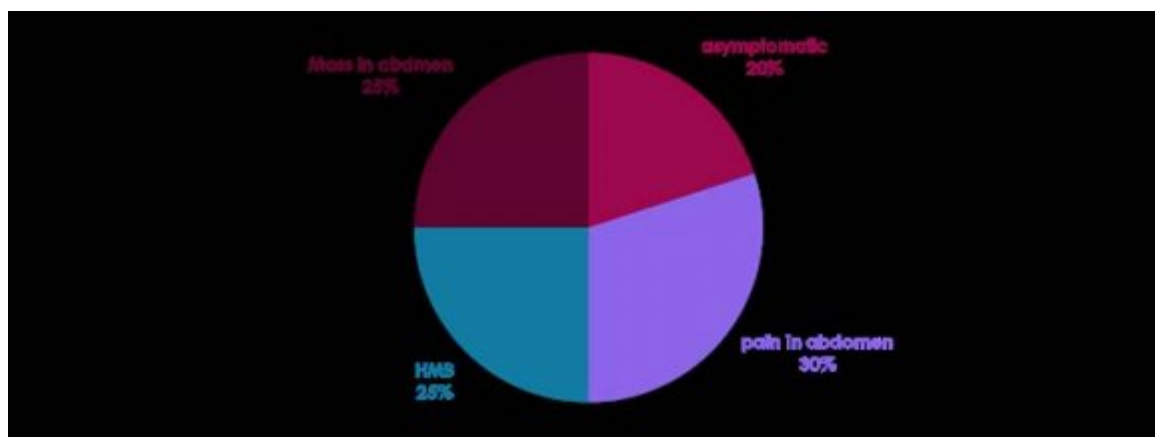


Figure 2:

168

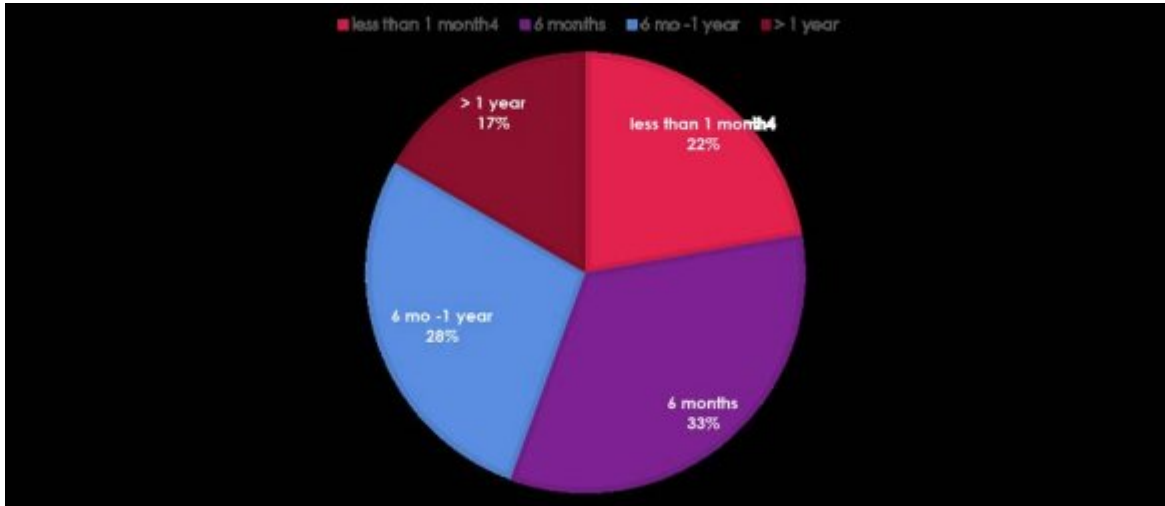


Figure 3:

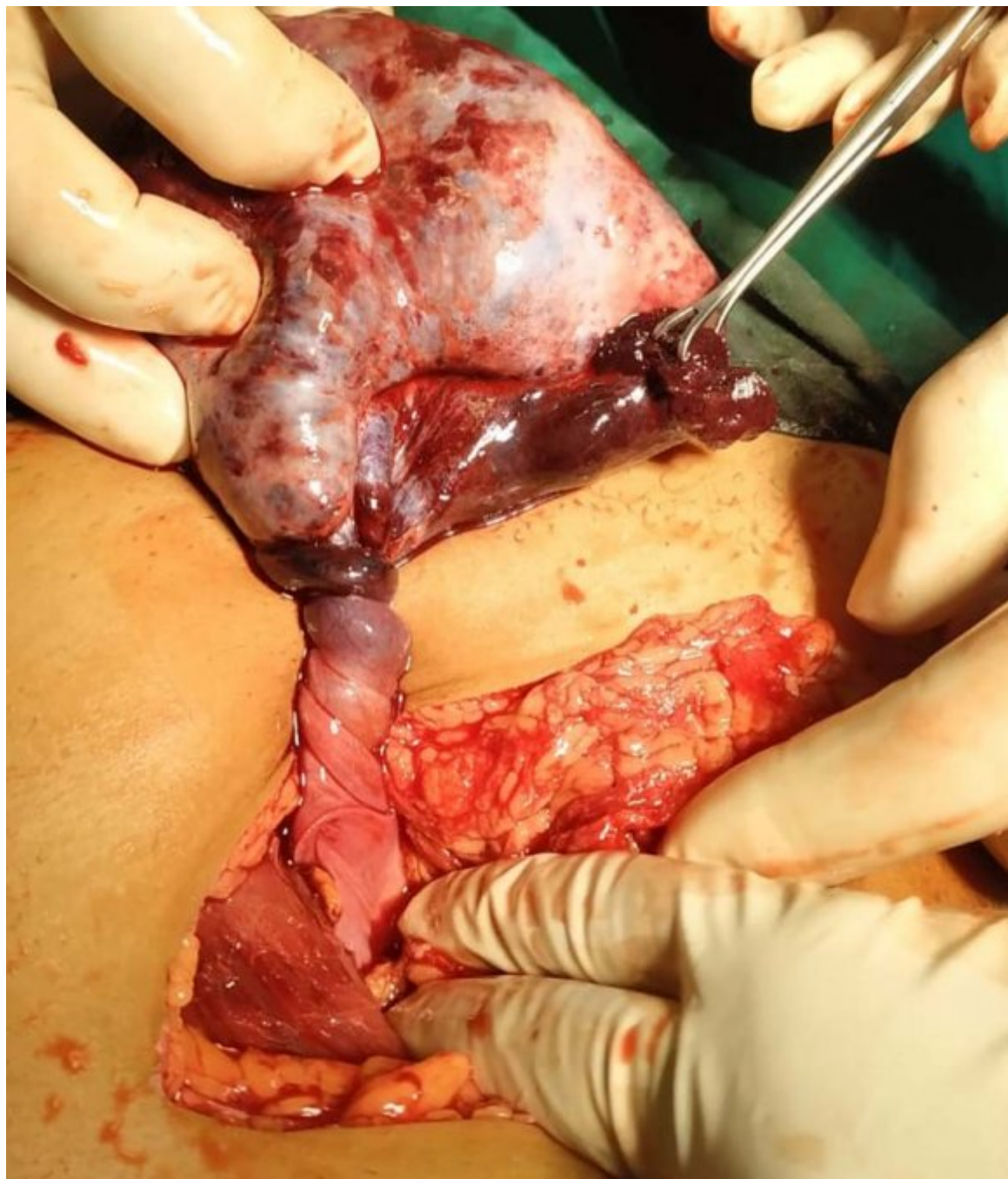


Figure 4:

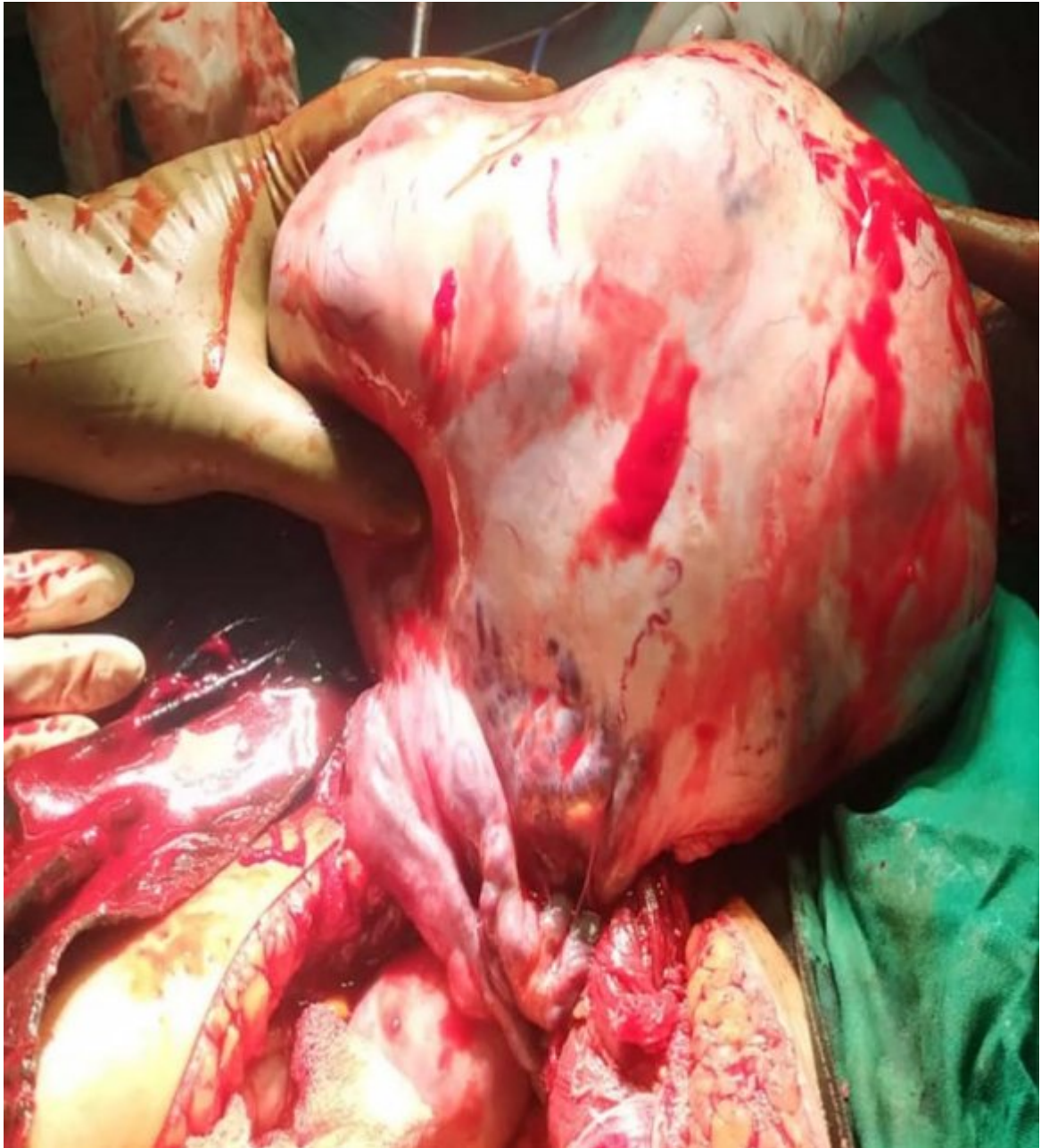

Figure 5:

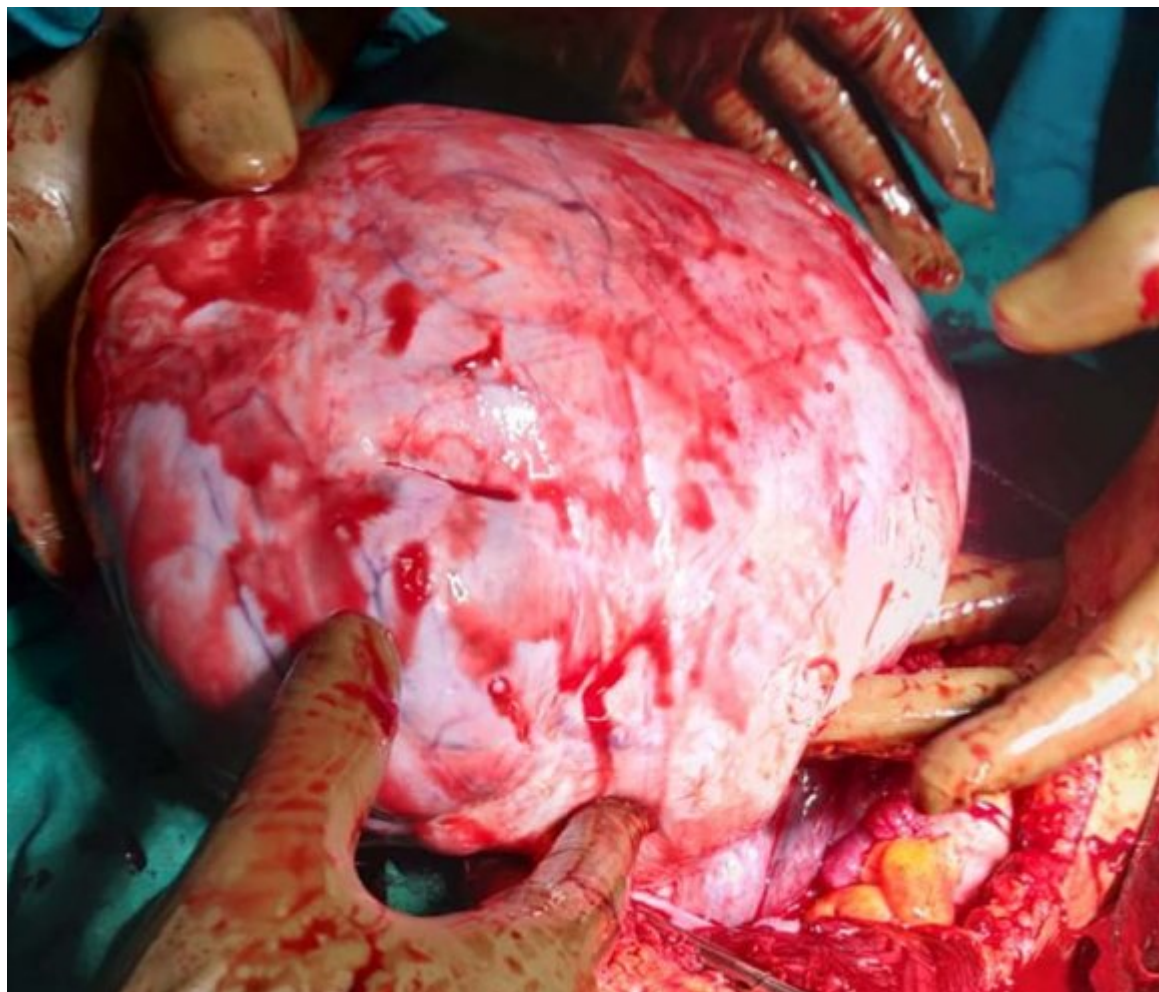

Figure 6:



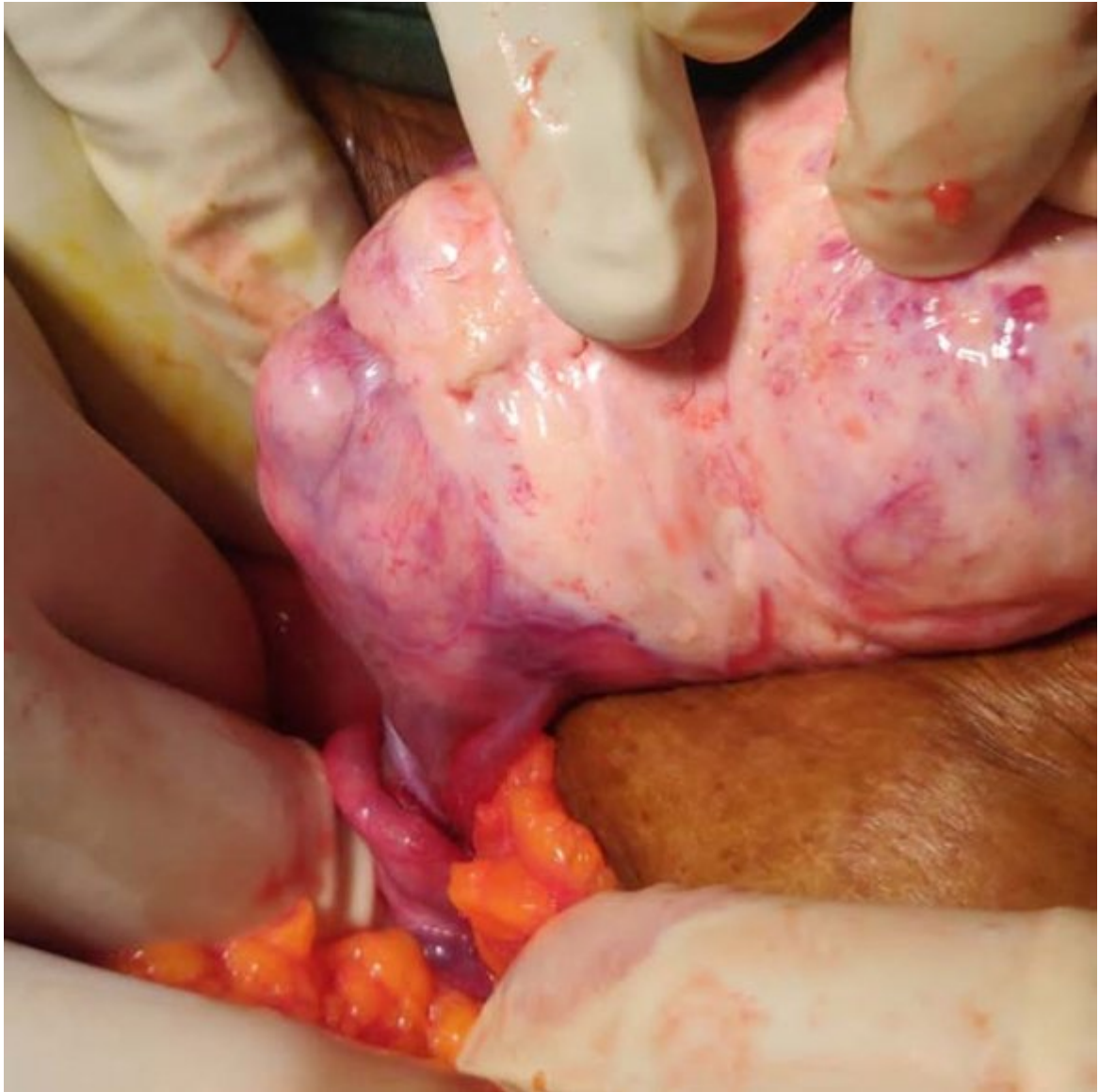

Figure 7:

Figure 8:

per protocol. If found suspect/symptomatic, should not be permitted to OT, and should be sent to designated swab collection facility.

8) All OT Personnel should follow COVID sanitisation protocols on entry to OT with repeated handwashing, social distancing and adequate protective gear.

9) Visiting relatives of the patients should also have COVID Negative swab report prior to entry to OT/wards.

? Re-evaluate admitted patients for signs and symptoms of COVID-19

? Encourage Physical Distancing (maintaining distance of 6 feet)

? There should not be any adjoining inhabited buildings within 20 meters

?

? Essential Elective (>2 to <3 months): Hysteroscopy for abnormal uterine bleeding (unknowledge causes, suspected malignancy, and menopausal transition), postmenopausal bleeding (suspected malignancy), cervical conization or looped electro excision procedure (to exclude neoplasm in the lower genital tract)

? Non-essential/elective surgery: Infertility procedures, family planning procedures (bilateral tubal ligation procedure).

The protocol followed at our tertiary care institute before operating the cases were as follow-

1) All elective patients should be admitted to Transit ward initially. Swabs should be sent for all patients from there.

2) After swab reports patients should be segregated into Covid/Non Covid Category.

3) Covid POSITIVE swab patients should be transferred to COVID facility/Centre (St. George's Hospital).

4) COVID NEGATIVE Swab patients should be transferred to respective unit wards.

5) Repeat swab should be sent for these patients from their respective wards 72 hrs. before proposed surgery.

6) All patients should have at least two consecutive negative swab reports, of which the latest swab should be within 72 hours of planned procedure.

7) All OT Healthcare workers, patients and visiting relatives should be screened before entering OT as

*[Note: ? Urgent (<24h): Postoperative infections, acute inflammatory abdomen (adnexal torsion, myoma torsion, ovarian cysts), hemorrhagic conditions (ovarian cysts); ? Elective urgent (<2 weeks): Surgeries for neoplasms of the lower genital tract and breast previously diagnosed by pathological examination;]*

169 .1 Acknowledgements: None

170 .2 Conflict of interest-NONE

171 [ World Health Organisation] , <https://www.who.int/> *World Health Organisation*

172 [Katke ()] ‘A huge benign mucinous cystadenoma of ovary: a case report and review of literature’. R D Katke .  
173 *Int J ReprodContraceptObstetGynecol*2014. 3 p. .

174 [Katke ()] ‘A huge ovarian mucinous cystadenoma (8.5kg) leading to bilateral hydronephrosis: a case report and  
175 review of literature’. R D Katke . *MOJ Clin Med Case Rep* 2017. 7 (1) p. .

176 [Katke] ‘Attitude and Practices of Family Planning in Antenatal Women in a Tertiary Care Hospital during  
177 COVID-19 Pandemic: Indian Perspective’. R D Katke . *J Gynecol* 2021 (1) p. 215.

178 [Goyal et al. (2020)] ‘The effect of the COVID-19 pandemic on maternal health due to delay in seeking health  
179 care: Experience from a tertiary center’. M Goyal , P Singh , K Singh , S Shekhar , N Agrawal , S Misra .  
180 *International Journal of Gynecology & Obstetrics* 2020 Jan 1.

181 [Katke (2015)] ‘Torsion of a Huge Ovarian Fibroma Presented as Acute Abdomen’. R D Katke . *Journal of Case  
182 Reports* 2015 May 11. 5 (1) p. .