



GLOBAL JOURNAL OF MEDICAL RESEARCH: F
DISEASES

Volume 21 Issue 5 Version 1.0 Year 2021

Type: Double Blind Peer Reviewed International Research Journal

Publisher: Global Journals

Online ISSN: 2249-4618 & Print ISSN: 0975-5888

A Novel Homozygous Mutation ABCA3gene: Presented as Sever Respiratory Distress Syndrome in a Term Neonate

By Dr. Samiya Al Hashmi, Dr. Jazel Manarang, Dr. Hussein Al Lawati
& Dr. Mujtaba. A. Al Ajmi

Abstract- Congenital surfactant deficiency is a rare condition diagnosed in newborns who present with respiratory distress at birth. We report a case of a term Omani neonate with fatal surfactant protein deficiency who was admitted to the Neonatal Intensive Care Unit (NICU) of the Royal Hospital with respiratory distress syndrome with persistent interstitial infiltrates on serial chest x-ray responsive to intermittent surfactant administration. He underwent a lung biopsy, and immunohistochemistry confirmed the diagnosis of congenital surfactant protein deficiency. However, despite aggressive treatment and supportive measures, his condition rapidly deteriorated, and he succumbed after two months of admission. This case report will highlight and review surfactant deficiency differential diagnoses, management, and complications.

Keywords: surfactant deficiency, term new-born, respiratory distress syndrome, Biopsy.

GJMR-F Classification: NLMC Code: WF 140



Strictly as per the compliance and regulations of:



A Novel Homozygous Mutation ABCA3 gene: Presented as Severe Respiratory Distress Syndrome in a Term Neonate

Dr. Samiya Al Hashmi ^α, Dr. Jazel Manarang ^σ, Dr. Hussein Al Lawati ^ρ & Dr. Mujtaba. A. Al Ajmi ^ω

Abstract- Congenital surfactant deficiency is a rare condition diagnosed in newborns who present with respiratory distress at birth. We report a case of a term Omani neonate with fatal surfactant protein deficiency who was admitted to the Neonatal Intensive Care Unit (NICU) of the Royal Hospital with respiratory distress syndrome with persistent interstitial infiltrates on serial chest x-ray responsive to intermittent surfactant administration. He underwent a lung biopsy, and immunohistochemistry confirmed the diagnosis of congenital surfactant protein deficiency. However, despite aggressive treatment and supportive measures, his condition rapidly deteriorated, and he succumbed after two months of admission. This case report will highlight and review surfactant deficiency differential diagnoses, management, and complications.

Keywords: surfactant deficiency, term new-born, respiratory distress syndrome, Biopsy.

I. INTRODUCTION

In preterm babies, respiratory distress is the most common manifestation of lung immaturity (less than 32 weeks of gestation), which due to deficient surfactant synthesis. Respiratory distress syndrome occurs less frequently to term infants, which may at times warrant further investigation, especially if with non-improvement to conventional treatment and causing significant morbidity and mortality [1,4]. Pulmonary surfactant is a complex mixture of phospholipids and protein which is produced, stored, and recycled by type II pneumocytes. It is found on the alveolar surface, and it functions to prevent alveolar collapse by lowering its surface tension aiding in normal respiration. Finding respiratory distress syndrome in a term neonate would raise a suspicion of an inherited deficiency in pulmonary surfactant [2,3]. Surfactant protein deficiencies are classified according to types; A3 (ABCA), B (SP-B), C (SFTPC), and SP-D. The most common type is Type A3, which was the first recognized inherited pulmonary surfactant disorder and had an autosomal recessive pattern. It is much more common to neonates and carries high mortality and morbidity rates [2,3,5]. Then it followed by

Corresponding Author ^ω: Senior consultant, Neonatology, Child Health Department, Royal Hospital, Muscat, Oman.
e-mail: dnmujtabaali70@gmail.com

Author ^α ^σ: Child Health Department, Royal Hospital, Muscat, Oman.

Author ^ρ: Consultant, Paediatric Pulmonology, Child Health Department, Royal Hospital, Muscat, Oman.

surfactant protein C (SFTPC) deficiency in with an autosomal dominant pattern of inheritance and is more associated with interstitial lung disease in older children and adults. Type A3 (ABCA) is similar to Type B (SP-B) in terms of severity. We report this rare case of congenital surfactant deficiency, the first documented case of Oman to the authors' knowledge. The subject, interestingly, had a familial history of the same presentation in a sibling that died within the first few weeks of life and was not thoroughly worked up. This report can assist the clinician regarding the approach to such cases and guide counselling the parents for possible future pregnancies.

II. CASE DESCRIPTION

A full-term (39 weeks) male infant weighing 3120 grams was born to a 31-year-old gravida four para three mother via spontaneous vaginal delivery. He was born vigorous with APGAR scores 8 and 9 at 1 and 5 minutes, respectively. Mother had gestational diabetes mellitus, diet-controlled with history of premature rupture of membrane two hours prior delivery without any other documented risk of sepsis. The parents are consanguineous (first cousins) and had a previous baby who as well presented with respiratory distress at birth, was admitted to the Neonatal intensive care unit, and died at two weeks of age.

On the second hour of life, the baby started to have respiratory distress, and physical examination revealed tachypnea with chest retractions and grunting. The infant transferred to the NICU for ventilator support, and complete septic workup including chest x-ray and blood gas were facilitated. The infant started on 25% inspired oxygen with flow 1.5L via nasal prongs on which capillary blood gas revealed respiratory acidosis (pH 7.27, PCO₂ 55.9, HCO₃ 21.8, and BE -0.9).

On admission, the chest radiograph revealed mildly hyperinflated lungs with perihilar interstitial markings (Figure 1). Succeeding chest x-ray on Day 2 showed worsening picture showing reduced lung volume and reticular infiltrations with positive air bronchogram, findings consistent with respiratory distress syndrome (RDS). He eventually required intubation for surfactant administration and was kept on ventilator assist-control mode. The baby's condition momentarily improved but

again had the worsening respiratory condition on the 3rd day of life requiring high-frequency oscillatory ventilation.

This clinical deterioration of cardio respiratory distress and temperature instability prompted repeat septic workup. Blood counts were normal, but C-reactive protein elevated. He initially treated with Cefotaxime and Vancomycin added after culture came positive for coagulase-negative staphylococcus. Repeat chest x-ray again revealed diffuse ground glass appearance for which another dose of surfactant given. Screening functional echocardiography also performed, which showed a small patent ductus arteriosus and a small fenestrated atrial septic defect secundum with mild pulmonary hypertension, which improved with sildenafil and prostaglandin nebulization.

The parents were counseled earlier on the possibility of the same condition as their previous baby and the need for subspecialty involvement. The pulmonology team was involved after the chest CT scan showed diffuse changes highly suggestive of interstitial lung disease (ILD), surfactant deficiency versus alveolar cause. Bronchoalveolar lavage also done to rule out infectious causes, but all turned out equivocal. To complete the workup, blood was sent for the whole-exome sequence together with a lung biopsy, which delayed due to the requirement of high ventilator parameters making him unsuitable for transfer to the operating theatre. In total, the baby received nine doses of surfactant, most of them offered immediate but temporary improvement in clinical status. A course of methylprednisolone and hydroxychloroquine (HCQ) tried but without any dramatic benefit.

The lung biopsy histology showed non-specific interstitial inflammation, which raised the suspicion of surfactant deficiency, and electron microscopy confirmed the diagnosis, revealing interstitial thickening with the proliferation of mesenchymal fibroblastic cells and chronic inflammatory infiltrated of lymphocytes, plasma cells, and scattered eosinophils. The parents received extensive counseling from the concerned subspecialties regarding the poor prognosis and outcome. During most of the patient's admission, the patient required high ventilatory parameters to maintain acceptable oxygen saturations. His condition was complicated with multiple bouts of clinical sepsis and bacteremia ventilated-associated pneumonia, particularly with endotracheal cultures growing *Acinetobacter baumannii* and *Klebsiella pneumoniae*. On day 58 of life, despite continuous supportive and humane care, the patient succumbed to respiratory failure.

III. DISCUSSION AND LITERATURE REVIEW

Congenital Pulmonary Surfactant Deficiency is a condition that requires a high index of suspicion. In this

report, we present a term neonate who developed severe respiratory distress within the first two hours from birth which was progressive until the third day of life. Intermittent surfactant administration offered immediate but temporary improvement of the condition; hence the possibility came into perspective. Respiratory distress syndrome (ARDS) is a common NICU diagnosis. It usually presents in preterm infants but can also occur in term babies, especially those born through a cesarean delivery or from diabetic mothers. The natural course of RDS has been well-studied which typically peaks within the first three days of life before the predictable clinical improvement. Its good response to surfactant therapy, especially those moderate to severe RDS, has also been well established. In this case, the baby presented with an RDS-like picture requiring ventilatory support in the first few days necessitating surfactant administration. However, its course was more progressive than usual, requiring high-frequency oscillatory ventilation and developing pulmonary hypertension. Serial chest radiographs, which initially showed reduced lung volume with air bronchograms, eventually revealed interstitial lung changes. With the history of a previous sibling with the same presentation who died at two weeks of life, a genetic cause suspected. Chest CT scan was requested by pulmonologist, which was suggestive of interstitial lung disease; hence multi-specialty consultation was done by neonatologist to pulmonology, genetic and surgical teams. Bronchoalveolar lavage was done to rule out infectious causes, but finally, lung biopsy confirmed the diagnosis.

Congenital surfactant deficiency is a rare genetic disorder that presents like respiratory distress syndrome but may have different clinical presentations depending on the type. Its incidence is unknown, but in the United States, it estimated at 1 in 1 million live births [1]. Several of causes can present with respiratory distress in newborns and should be excluded before arriving at the diagnosis [2,4,5]. Other differential diagnoses should be ruled out, include sepsis, wet lung, lung malformations as well as non-pulmonary causes of respiratory distress such as congenital heart diseases, among others. One subtype of surfactant protein deficiency is type B (SP-B) which is known to be a clinically progressive disease wherein most the cases lead to fatal hereditary neonatal lung disease. Alveolar capillary dysplasia is another differential diagnosis, a condition that happens due to misalignment of the pulmonary veins (ACD/MPV). It has a similar presentation to congenital surfactant deficiency, that is, occurring in term infants with respiratory distress soon after birth associated with cyanosis and severe pulmonary hypertension despite treatment [6,12]. Radiological appearance and lung biopsy help distinguish disorders of primary surfactant deficiency from other structural causes of lung disease.

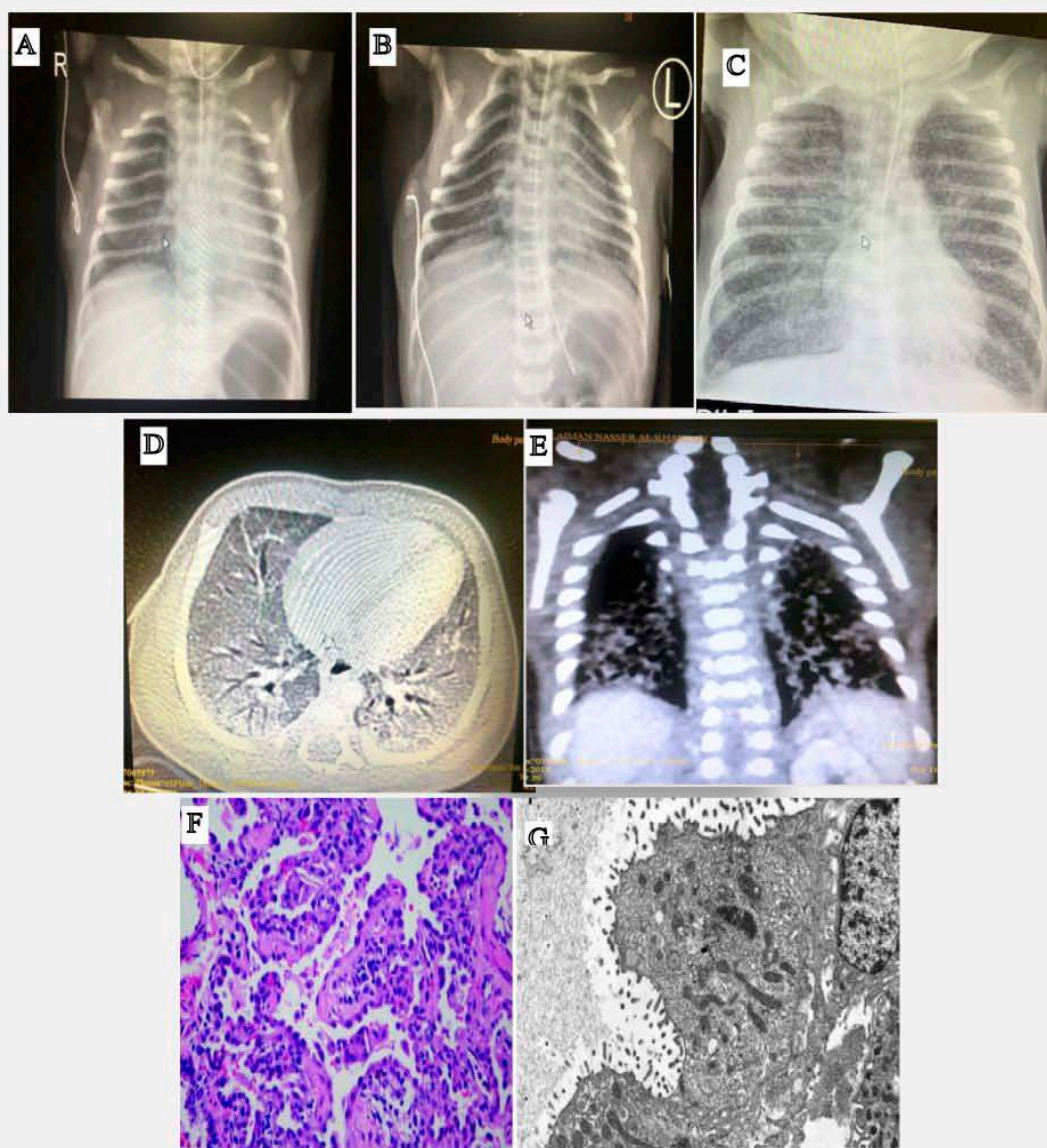


Fig. 1. Serial chest radiographs of neonate with ABCA3 deficiency. (A) At the time of admission 3hrs of age: mildly hyper-inflated lungs and mild perihilar interstitial markings. (B) Day 2 of life before receiving surfactant showed reduced lung volume and reticular infiltrations with positive air bronchogram (C). As is typical for the surfactant protein deficiencies, there is a hazy severe diffuse opacification. (D, E) Lung HRCT of the lungs showing patchy areas of ground-glass attenuation with thickening of interlobular septae. Histologic changes in the infant's lung in the surfactant dysfunction mutations ABCA3 -: early lobular remodeling and diffuse alveolar epithelial hyperplasia (F) Electron microscopic features of ABCA3 mutations (G): characteristic abnormal lamellar bodies with distinctive central and eccentric round dense bodies (F&G) picture, **Lee, Cleveland and Langston, 2011**)

Using electron microscopy with its ultrastructural feature provides an important point for diagnosis and helps direct further genetic study and evaluation. Histology, alveolar epithelial hyperplasia is a characteristic of surfactant deficiency in infants. Immunohistochemically, features of SP-B include unrecognizable lamellar bodies and an accumulation of abnormal appearing multivesicular bodies [1,3,6,7,]. In contrast, ABCA3 has tiny lamellar bodies with a prominent dense inclusion. The molecular gene study is providing the direction for genetic counseling among affected families to discuss the risks for future pregnancies. In families in which a mutation has been previously identified, it greatly aids in establishing even antenatal diagnosis. In this case, after confirmation of the diagnosis by lung biopsy and electron microscopy, the surfactant protein deficiency is most likely type B (SP-B), given its clinically progressive course. This definitive diagnosis was confirmed by a genetic study that was sent and reported with pathologic ABCA3 variant C.3253C>T p. (Gln1085) which is associated with autosomal recessive pulmonary surfactant metabolism dysfunction. It is also known as interstitial lung disease due to ABCA3 deficiency.

Among surfactant protein deficiencies, A3 (ABCA3) has been characterized by a variable clinical outcome ranging from fatal respiratory distress syndrome in the neonatal period to chronic interstitial lung disease developing in infancy or childhood. ABCA3 mutations are linked with a higher proportion of cases with significant positive family history the similar conditions [12,13]. Respiratory distress syndrome in term newborns can result from a deficiency in either SP-B or ABCA3 mutations with both genetic mutations having an autosomal recessive pattern of inheritance; whereas chronic ILD during infancy or early childhood can be the manifestation of either SP-C or ABCA3 mutations [11,12,13]. Despite all the supportive measures with ventilation, recurrent surfactant replacement therapy, hydroxychloroquine, and methylprednisolone, there was no improvement in the condition of the infant, and he died at the age of two months. Recurrent surfactant replacement therapy transiently improves the respiratory parameters in patients with surfactant deficiency but is not reported to be effective in the long term [6,7,8]. At present, the only curative option is lung transplantation. However, the procedure itself comes with high rates of complications, mostly with infection, thus the need for lifelong immunosuppressive drugs. [1,6,9]. Other supportive therapies available include sedation, inotropic support, high-dose glucocorticoids, and intravenous gamma globulin, which offer short-term improvement. Mechanical ventilation, HFOV, inhaled nitric oxide, and even extracorporeal membrane oxygenation may be necessary to aid oxygenation. Gene therapy is one area being looked into but yet to be established.

IV. CONCLUSION

In summary, a term baby presenting with respiratory distress syndrome picture should raise some suspicion of an underlying congenital surfactant deficiency, especially if it presents on a background of positive family history. Congenital surfactant protein ABCA3 deficiency is a fatal type of lung disease that requires intensive management, including ventilatory support, a trial of surfactant administration, and steroids due to its stormy clinical course. It warrants thorough evaluation with immunohistochemical and genetic studies confirming the underlying pathology. Timely establishment of the diagnosis is of utmost importance especially in educating couples on the condition's associated complications, treatment options and its guarded prognosis.

Abbreviations

NICU: Neonatal Intensive care unit; CQ: hydroxychloroquine; ILD: interstitial lung disease; SP-B: surfactant protein B; SFTPC: surfactant protein C gene, ATP-binding cassette transporter protein A3 (ABCA3) respiratory distress syndrome (RDS); HFOV high-frequency oscillatory ventilation.

Conflict of Interests

The authors declare no conflict of interest.

REFERENCES RÉFÉRENCES REFERENCIAS

1. Susan E. Wert, Jeffrey A. Whitsett, and Lawrence M. Nogee. Genetic Disorders of Surfactant Dysfunction. May 1, 2011; 12(4): <https://doi.org/10.2350/09-01-0586.1>
2. Somaschini, M., Nogee, L., Sassi, I., Danhaive, O., Presi, S., Boldrini, R., Montrasio, C., Ferrari, M., Wert, S. and Carrera, P. Unexplained Neonatal Respiratory Distress Due to Congenital Surfactant Deficiency. The Journal of Pediatrics, 01 Jun 2007, 150(6):649-53, 653.e1, DOI: 10.1016/j.jpeds.2007.03.008.
3. Christain.H, and Anand.M, Lancaster General Hospital, Lancaster, Pennsylvania. newborn respiratory distress. 2. *Am Fam Physician*. 2015 Dec 1; 92(11): 994-1002.
4. Gower WA, Wert SE, Nogee LM. Inherited surfactant disorders, *NeoReviews* October 2008, 9 (10) e458-e467; DOI: <https://doi.org/10.1542/neo.9-10-e458>.
5. Pickerd, N. and Kotecha, S., 2009. Pathophysiology of respiratory distress syndrome. *Paediatrics and Child Health*, 19(4), pp.153-157. doi: 10.1016/j.paed.2008.12.010.
6. Whitsett, J., Wert, S. and Weaver, T., 2015. Diseases of Pulmonary Surfactant Homeostasis. *Annual Review of Pathology: Mechanisms of Disease*, 10(1), pp.371-393doi: 10.1146/annurev-pathol-012513-104644.

7. Kurath-Koller, S., Resch, B., Kraschl, R., Windpassinger, C., Eber, E., 2015. Surfactant Protein B Deficiency Caused by Homozygous C248X Mutation—A Case Report and Review of the Literature. *American Journal of Perinatology Reports*, 05(01), pp.e053-e059. doi: 10.1055/s-0035-1545668.
8. Hamvas A. Inherited surfactant protein-B deficiency and surfactant protein-C associated disease: clinical features and evaluation. *Semin Perinatol*. 2006; 30(6): 316–326. doi: 10.1053/j.semperi.2005.11.002.
9. Eldridge, W., Zhang, Q., Faro, A., Sweet, S., Eghtesady, P., Hamvas, A., Cole, F. and Wambach, J., 2017. Outcomes of Lung Transplantation for Infants and Children with Genetic Disorders of Surfactant Metabolism. *The Journal of Pediatrics*, 184, pp.157-164.e2. doi: 10.1016/j.jpeds.2017.01.017.
10. Sleight E, Coombs R C, Gibson A T, Primhak R A. Neonatal respiratory distress in near-term infants—consider surfactant protein B deficiency. *Acta Paediatr*. 1997; 86(4):428–430, doi: 10.1111/j.1651-2227.1997.tb09037.x.
11. Shulenin S, Nogee LM, Annilo T, et al. ABCA3 gene mutations in newborns with fatal surfactant deficiency. *N Engl J Med* 2004; 350:1296–303. doi: 10.1056/NEJMoa032178.
12. Lee, E., Cleveland, R. and Langston, C., 2011. Interstitial Lung Disease in Infants and Children: New Classification System with Emphasis on Clinical, Imaging, and Pathological Correlation. 2011: 99–154. doi: 10.1007/978-1-4419-5872-3_8.
13. Doan, M., Guillerman, R., Dishop, M., Nogee, L., Langston, C., Mallory, G., Sockrider, M. and Fan, L., 2008. Clinical, radiological and pathological features of ABCA3 mutations in children. *Thorax* 2008; 63: 366–373. doi:10.1136/thx.2007.083766.

