



GLOBAL JOURNAL OF MEDICAL RESEARCH: F
DISEASES

Volume 22 Issue 1 Version 1.0 Year 2022

Type: Double Blind Peer Reviewed International Research Journal

Publisher: Global Journals

Online ISSN: 2249-4618 & Print ISSN: 0975-5888

Optimization of Treatment Methods for Purulent-Destructive Soft Tissue Diseases through the use of Laser Treatment Methods

By Teshaev Oktyabr Rukhullaevich, Muradov Alijon Salimovich
& Mavlyanov Olimboy Razzokovich

Abstract- Purpose: Optimization of methods for the treatment of purulent-destructive diseases through the complex application of photodynamic therapy (PDT) and CO₂ laser.

Materials and Methods: 360 patients with purulent-destructive soft tissue disease were examined and treated. Depending on the treatment carried out, the patients were conditionally divided into 3 groups: the 1st (control group) included 118 patients who underwent conventional traditional methods of treatment; in the 2nd group (main group I) there were 120 patients who, in combination with traditional methods of treatment, used PDT with a photosensitizer (PS) 0.05% methylene blue buffer solution (MB); and the 3rd group (main group II) included 122 patients where PDT was used in combination with traditional methods of treatment (0.05% methylene blue buffer solution was used as PS) and a CO₂ laser.

Keywords: photodynamic therapy, photosensitizer, methylene blue, CO₂ laser, laser surgery, microbe, planimetry.

GJMR-F Classification: NLMC Code: WO 511



Strictly as per the compliance and regulations of:



© 2022. Teshaev Oktyabr Rukhullaevich, Muradov Alijon Salimovich & Mavlyanov Olimboy Razzokovich. This research/review article is distributed under the terms of the Attribution-NonCommercial-NoDerivatives 4.0 International (CC BY-NC-ND 4.0). You must give appropriate credit to authors and reference this article if parts of the article are reproduced in any manner. Applicable licensing terms are at <https://creativecommons.org/licenses/by-nc-nd/4.0/>.

Optimization of Treatment Methods for Purulent-Destructive Soft Tissue Diseases through the use of Laser Treatment Methods

Teshaev Oktyabr Rukhullaevich ^α, Muradov Alijon Salimovich ^σ & Mavlyanov Olimboy Razzokovich ^ρ

Abstract- Purpose: Optimization of methods for the treatment of purulent-destructive diseases through the complex application of photodynamic therapy (PDT) and CO₂ laser.

Materials and Methods: 360 patients with purulent-destructive soft tissue disease were examined and treated. Depending on the treatment carried out, the patients were conditionally divided into 3 groups: the 1st (control group) included 118 patients who underwent conventional traditional methods of treatment; in the 2nd group (main group I) there were 120 patients who, in combination with traditional methods of treatment, used PDT with a photosensitizer (PS) 0.05% methylene blue buffer solution (MB); and the 3rd group (main group II) included 122 patients where PDT was used in combination with traditional methods of treatment (0.05% methylene blue buffer solution was used as PS) and a CO₂ laser. Clinical, microbiological, morphological and planimetric methods have been investigated to assess the effectiveness of the method.

Results: Photodynamic therapy with a light emitter ALT-Vostok-03 is a rather effective non-invasive and sparing method of treating purulent wounds and serves as a rationale for the application of the method of photodynamic therapy in clinical practice for the treatment of local acute purulent-inflammatory processes in combination with a CO₂ laser and traditional methods of treatment. In patients of the main group, the normalization of temperature and heart rate was observed at 3.0 ± 0.5 days, a decrease in LII indices to the normal level was observed at 7.0 ± 0.5 days after the treatment. Analysis of the dynamics of clinical manifestations showed that the treatment of purulent wounds using PDT with a photosensitizer of the blizzard blue leads to a rapid decrease in perifocal inflammatory manifestations. Hyperemia of the skin around purulent wounds and a decrease in perifocal inflammation persisted for 3.5 ± 0.5 days, a decrease in local edema was noted for 2.0 ± 0.5 days. The average length of hospital stays for patients in the main group averaged 5.0 ± 2.5 bed-days. After 3-5 sessions of PDT with a photosensitizer MS in the main group, the microbial contamination decreased to a critical level, and after 6-8 sessions, no microbial growth was observed.

Conclusion: The combined use of PDT and CO₂ laser is the most effective, in comparison with traditional methods of treatment, which leads to earlier cleansing from pus, active formation of granulation tissue and shortening the time of complete epithelialization of the wound surface.

Keywords: photodynamic therapy, photosensitizer, methylene blue, CO₂ laser, laser surgery, microbe, planimetry.

1. INTRODUCTION

Despite the achievements of recent years in the field of microbiology, immunology, intensive work on the development and implementation of new antibacterial drugs, improvement of surgical techniques, the problem of treating purulent-inflammatory diseases of soft tissues does not lose its relevance [4,8,32,36]. This problem is compounded by the growing number of pathogenic microorganisms resistant to both antibiotics and some antiseptics [25,31].

In the general structure of surgical diseases, surgical infection is observed in 35 - 45% of patients. At the same time, up to 70-80% of these patients are admitted to hospitals for urgent indications. In the structure of postoperative complications, surgical infection ranges from 32 to 75% [1, 2, 23, 13, 19, 9, 37, 34, 35, 43]. These impressive figures convincingly indicate the relevance and unsolved problem of purulent infection in surgery, which is a very serious medical, social and economic problem that remains relevant today [29].

Despite the availability of various methods of treatment used in purulent surgery, it does not reduce the number of patients with surgical infection, which contributed to the introduction of a wide range of physical and physicochemical methods of local treatment of purulent soft tissue diseases [1, 14, 20, 40].

One of the promising areas of modern medicine in solving this problem is the use of laser treatment methods. Photodynamic therapy (PDT) is a unique medical technology: highly effective, sparing, organ-preserving, providing good cosmetic and functional results [26]. PDT is a relatively new method of treatment based on the use of drugs - photosensitizers (substances that are sensitive to light) and laser radiation with a certain wavelength corresponding to the absorption peak of the photosensitizer [17,24].

Author α: Doctor of Medical Sciences, Professor, Head of the Department of Surgical Diseases of the Tashkent Medical Academy. e-mail: tma.tor@mail.ru

Author σ: Assistant of the Department of Surgical Diseases of the Tashkent Medical Academy. e-mail: dr.alimurod@mail.ru

Author ρ: Doctor of Medical Sciences, Professor of the Department of Surgical Diseases of the Tashkent Medical Academy. e-mail: olimboy.mavlyanov@tma.uz

II. RESEARCH PURPOSE

Improvement of the results of treatment of patients with purulent-destructive diseases of soft tissues with the help of local complex application of PDT and CO₂ laser.

III. MATERIALS AND METHODS

The study is based on the results of a comprehensive examination and treatment of 360 patients with purulent wounds of soft tissues who were treated in the department of purulent surgery of the 1-city clinical hospital on the basis of the Department of Surgical Diseases of the TMA from 2014 to 2019. Depending on the treatment carried out, the patients were conditionally divided into 3 groups: the 1st (control group) included 118 patients who underwent

conventional traditional methods of treatment; in the 2nd group (main group I) there were 120 patients who, in combination with traditional methods of treatment, used PDT with a photosensitizer (PS) 0.05% buffer solution of methylene blue (MS); and the 3rd group (main group II) included 122 patients where PDT was used in combination with traditional methods of treatment (0.05% methylene blue buffer solution was used as PS) and a CO₂ laser. According to our data, the distribution of patients by age and sex is presented in table 1. Among the examined patients, there were 189 (52.5%) women, 171 (47.5%) men, the age of the patients varied from 18 to 82 years. The main contingent of patients was of working age from 18 to 60 years - 277 patients (63%).

Table 1: Distribution of patients depending on age and gender

Age of the patients	Control group		Main group I		Main group II	
	Men	Women	Men	Women	Men	Women
From 18 to 44 years old	18	23	19	26	21	20
From 45 to 59 years old	15	17	16	18	19	15
From 60 to 74 years old	11	14	15	11	14	17
75 and elder	9	11	5	10	9	7
Total (%)	53(45%)	65(55%)	55(46%)	65(54%)	63(51,6%)	59(48,3)

According to clinical entities in patients, (13.4%), phlegmon in 43 patients (11.9%) and erysipelas prevailed in 63 patients (17.5%), carbuncle in postoperative suppuration of wounds of various 53 patients (14.8%), infected wounds in 48 patients localization in 34 patients (9.5%).

Table 2: Clinical entities of examined patients

No.	Nosology	Control group	Main group I	Main group II	Total
1.	Erysipelas	23	29	11	63(17,5%)
2.	Carbuncle	17	11	25	53(14,8%)
3.	Infected wound	19	22	7	48(13,4%)
4.	Phlegmon	12	13	18	43(11,9%)
5.	Postoperative wound suppuration	10	9	15	34(9,5%)
6.	Abscessed furuncle	7	8	13	28(7,8%)
7.	Soft tissue abscess	8	4	10	22(6,1%)
8.	Postinjective abscess	7	8	6	21(5,8%)
9.	Acute suppurative mastitis	5	6	9	20(5,5%)
10.	Suppurative hematoma	7	5	4	16(4,4%)
11.	Other nosology	3	5	4	12(3,3%)
Total		118	120	122	360(100%)

Analyzing table 3 on the location of a purulent wound, it can be noted that most often purulent wounds were localized in the body area 98 (27.3%) and lower limbs -73 (20.3%).

Table 3: Distribution of patients according to the location of the purulent wound

Nº	Body area	Control group	Main group I	Main group II	Total (abc and %)
1.	Body	34	28	36	98(27,3%)
2.	Lower limbs	21	33	19	73(20,3%)
3.	Neck	20	15	23	58(16,1%)
	Stomach	16	19	21	56(15,5%)
4.	Buttocks	14	15	16	45(12,5%)
5.	Upper limbs	13	10	7	30(8,3%)
	Total	118	120	122	360(100%)

The time from the onset of the disease to treatment and hospitalization in the hospital averaged 7.2 ± 3.5 days.

Table 4: Distribution of patients in the main and control groups depending on the nature of concomitant diseases

No.	Concomitant diseases	Control group (abc and %)	Main group I (abc and %)	Main group II (abc and %)	Total (abc and %)
1.	Hypertensive disease	26(22,0%)	29(24,1%)	22(18,0%)	77(21,4%)
2.	Coronary disease	18(15,2%)	14(11,7%)	19(15,5%)	51(14,2%)
3.	Diabetes mellitus	12(10,4%)	15(12,5%)	20(16,4%)	47(13,0%)
4.	Varicose of the lower extremities and CVI	13(11,0%)	19(16,0%)	11(9,0%)	43(12,0%)
5.	Respiratory diseases	11(9,3%)	7(5,8%)	8 (6,6%)	26(7,2%)
6.	Postinfarction cardiosclerosis	5(4,2%)	7(5,8%)	11 (9,0%)	23(6,4%)
7.	Diseases of the genitourinary system	5(4,2%)	7(5,8%)	9(7,4%)	21(5,8%)
8.	Arthropathy	9(7,6%)	7(5,8%)	5(4,1%)	21(5,8%)
9.	There was no concomitant pathology	19(16,1%)	15(12,5%)	17(14,0%)	51(14,2%)
		118	120	122	360(100%)

The analysis of concomitant diseases in the comparative groups shows that in the control group in 83.9%, in the main group I in 87.5%, and in the main group II in 86.0% of patients, one or more concomitant diseases were revealed. At the same time, arterial hypertension (21.4%), ischemic heart disease (14.2%), diabetes mellitus (13.0%) and varicose veins of the lower extremities with signs of varying severity of CVI (12.0%) prevailed.

Device characteristics

For photodynamic therapy, an ALT-Vostok model 03 light emitter was used, corresponding to the technical specifications TSh 64-15302652-002: 2010, Manufacturer LLC "NAF", Uzbekistan.

With the following main technical characteristics:

- 1) Radiation range 660-670nm with a power density of 200 mW / cm²;
- 2) Exit area of the emitting terminal 4 cm².

The distance from the end of the radiator to the wound surface was 2-5 cm in the absence of thermal discomfort in the patient. The total irradiation time depended on the area of the wound surface and ranged from 15 to 30 minutes.

For the session of the CO₂ laser, the apparatus "JZ-3A" was used. Laser wavelength: 10.6. Output Power: 1 ~ 15w. Exit mode: Focus, defocus.

In all studied groups, after the start of treatment, we studied general clinical parameters, morphology, microbiology and planimetry of purulent wounds in dynamics. After opening the abscess, all patients had bandaging on the next day after the operation, where the condition of the wound was assessed - resolution of hyperemia, swelling, pain and infiltration of the walls, the nature and amount of discharge from a purulent wound, the presence of non-viable, necrotic tissues and detritus was determined, as well as the timing of the appearance granulation and the beginning of epithelialization. The prints were taken from the walls of wounds for 3,7,10 days for cytological studies, as well as for dynamic control of changes in the microbial flora and its sensitivity to antibiotics.

After the surgical treatment of purulent foci, the dynamics of the course of the wound process in patients of the control and main groups were different, depending on the treatment.

In patients of the control group who received traditional treatment, temperature normalized on day 4.0 ± 0.5 , heart rate normalized on day 4.5 ± 0.5 , and a

decrease in leucocyte index of intoxication - on day 8.5 ± 0.5 after treatment. A decrease in perifocal edema in the area of purulent wounds was observed in patients for 4.5 ± 0.5 days. Hyperemia of the skin around the purulent wounds persisted for 5.0 ± 0.3 days, and infiltration of the edges and walls of the wounds - 8.5 ± 0.5 days. Table 7.

In the main group I, temperature normalized on the 3.0 ± 0.8 th days, the heart rate decreased to normal values by 3.5 ± 0.7 days, a decrease in leucocyte index of intoxication to the normal level was observed on the 8.0 ± 0.5 th days after carrying out medical measures. Analysis of the dynamics of clinical manifestations showed that the treatment of purulent wounds using photodynamic therapy with a photosensitizer blizzard blue leads to a rapid decrease in perifocal inflammatory manifestations. Hyperemia of the skin around purulent

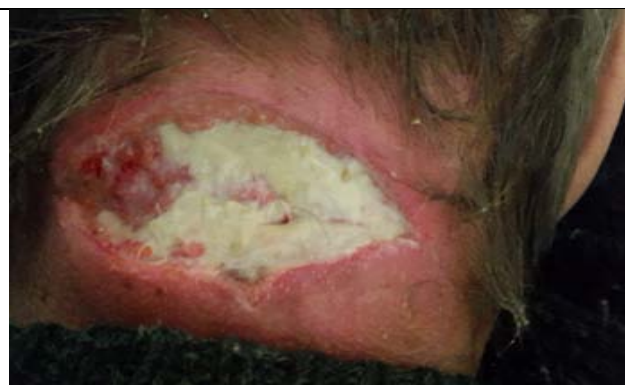wounds and a decrease in perifocal inflammation persisted for 4.0 ± 0.5 days, and infiltration of the edges and walls of wounds — 6.5 ± 0.5 days. Table 7.

In the main group II, temperature normalized on the 3.0 ± 0.5 th days, the heart rate decreased to normal values by 3.0 ± 0.5 days, and a decrease in leucocyte index of intoxication to the normal level was observed on days 7.0 ± 0.5 after therapeutic measures. Analysis of the dynamics of clinical manifestations showed that the treatment of purulent wounds using photodynamic therapy with a photosensitizer blizzard blue leads to a rapid decrease in perifocal inflammatory manifestations. Hyperemia of the skin around purulent wounds and a decrease in perifocal inflammation persisted for 3.5 ± 0.5 days, and infiltration of the edges and walls of wounds — 5.5 ± 0.5 days. Table 8.

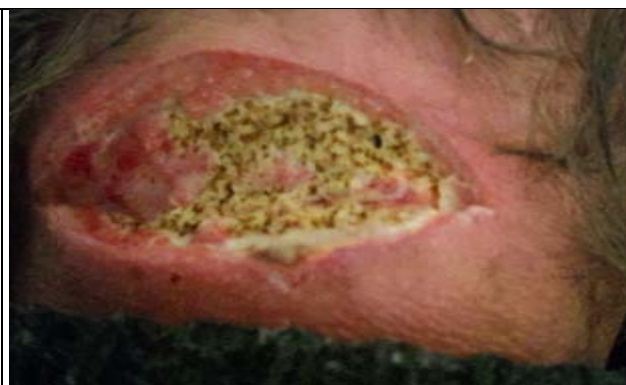Table 8: Comparative characteristics of the main clinical indicators of the studied groups in dynamics

Groups Indicators	Temperature normalization (days)	Heart rate normalization (days)	Normalization of leucocyte index of intoxication (days)	Decrease in perifocal inflammation (days)	Reduction of infiltration of the edges and walls of wounds (day)
Control group	4.0 ± 0.5	4.5 ± 0.5	8.5 ± 0.5	4.5 ± 0.5	8.5 ± 0.5
Main group I	3.0 ± 0.8	3.5 ± 0.7	8.0 ± 0.5	4.0 ± 0.5	6.5 ± 0.5
Main group II	3.0 ± 0.5	3.0 ± 0.5	7.0 ± 0.5	3.5 ± 0.5	5.5 ± 0.5

Пример: Больной С.С. 1954 г.р. ИБ №1650. Поступил с диагнозом: Карбункул шеи. Жалобы на боли, отечность, покраснение в области задней поверхности шеи, повышение температуры тела, а также слабость. Со слов болеет в течение 10 дней. Занимался самолечением-без эффекта. Анализах крови: Hb-132г/л, WBC-16х109/л, Ht-42,5%, СОЭ-10 мм/ч, АСТ – 0,38мкмоль, АЛТ – 0,29 мкмоль. Локальном осмотре по задней поверхности шеи имеется участок покраснение размером: 10,0х10,0 см при пальпации резко болезненно. 29.01.2016 г произведено операция “выскртые гнойника, некроэктомия”. После операции пациенту проведено 3 сеанса ФДТ (ФС 0,05% раствор метиленовый синий) с помощью фотодинамической устройства АЛТ Восток и СО₂-лазера (2 сеанса). Послеоперационный период прошел хорошо. Операционная рана очистилась от гнойного налета на 3 сутки лечение, появление грануляции через 4-5 дней и эпителизации через 5-6 дней по краям раны. Пациент выписан из стационара в удовлетворительном состоянии на 5-е сутки после операции.

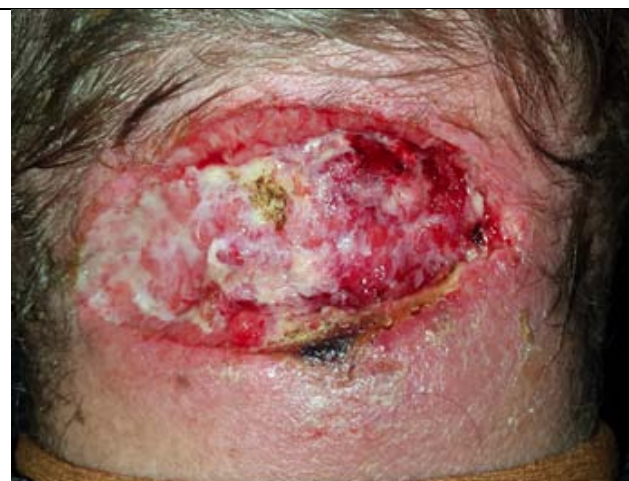

Pic 1: Carbuncle of the posterior surface of the neck after dissection. Fibrinous purulent exudate on the day of the wound.



Pic 2: The state of the wound after the 1st session of the CO₂ laser

Pic 3: The state of the wound after the 3rd session of the CO₂ laser (5th day, after the opened abscess). There is no Fibrinous purulent exudate, there are signs of granulation on the wound.



Observation of the course of purulent wounds in dynamics showed that the cleansing of wounds from purulent-necrotic masses during the traditional treatment occurred on the days 7.0 ± 0.5 (on the $4.5 \pm 0.5^{\text{th}}$ day in the main group I and 3.8 ± 0.5 in the main group II), the appearance of granulations was noted on $7.5 \pm 0.7^{\text{th}}$ days (on the $5.0 \pm 0.6^{\text{th}}$ day in the main group I and 4.0 ± 0.5 in the main group II), and marginal

epithelization was detected on $8.0 \pm 0.7^{\text{th}}$ days (on the $6, 5 \pm 0.5^{\text{th}}$ day in the main group I and 5.5 ± 0.5 in the main group II) after surgical treatment of a purulent focus - table 8. The average length of hospital stay for patients in the control group averaged 9.5 ± 3.5 bed-days (7.5 ± 3.0 in the main group I and 6.0 ± 2.5 in the main group II) - after a PDT session and a CO₂ laser, the terms decreased in the main group II.

Table 9: Comparative characteristics of the wound process depending on the treatment performed in dynamics

Groups	Medium terms (days)		
	Wound cleaning	Appearance of granulation	Onset of marginal epithelialization
Control group	7.0 ± 0.5	7.5 ± 0.6	8.0 ± 0.7
Main group I	4.5 ± 0.5	5.0 ± 0.6	6.5 ± 0.5
Main group II	3.8 ± 0.5	4.0 ± 0.6	5.5 ± 0.5

The staged planimetric studies carried out showed that in the main groups of patients, where PDT and CO₂ laser were used for treatment, the area of purulent wounds decreased faster than in the control group - Table 14. Thus, in patients of main group II, the area of purulent wounds decreased by 10th days by 72.7%, in patients in the main group this indicator is

69.5%, while with traditional treatment the area of purulent wounds decreased by 59.9% ($p < 0.05$).

Table 14: Comparative characteristics of planimetric indicators of purulent wounds in dynamics in the studied groups

Group of patients	Wound area (cm ² and %)			
	1 st day	3 rd day	7 th day	10 th day
Control group	147±6,0 cm ² (100%)	133±5,0 (90,4%)	75±3,0 (51%)	59±5,5 (40,1%)
Main group I	141±8,0 cm ² (100%)	119±5,0 (84,3%)	60±4,0 (42,5%)	43±2,5 (30,5%)
Main group II	143±5,0 cm ² (100%)	111±5,0 (77,6%)	48±4,0 (33,5%)	39±2,0 (27,3%)

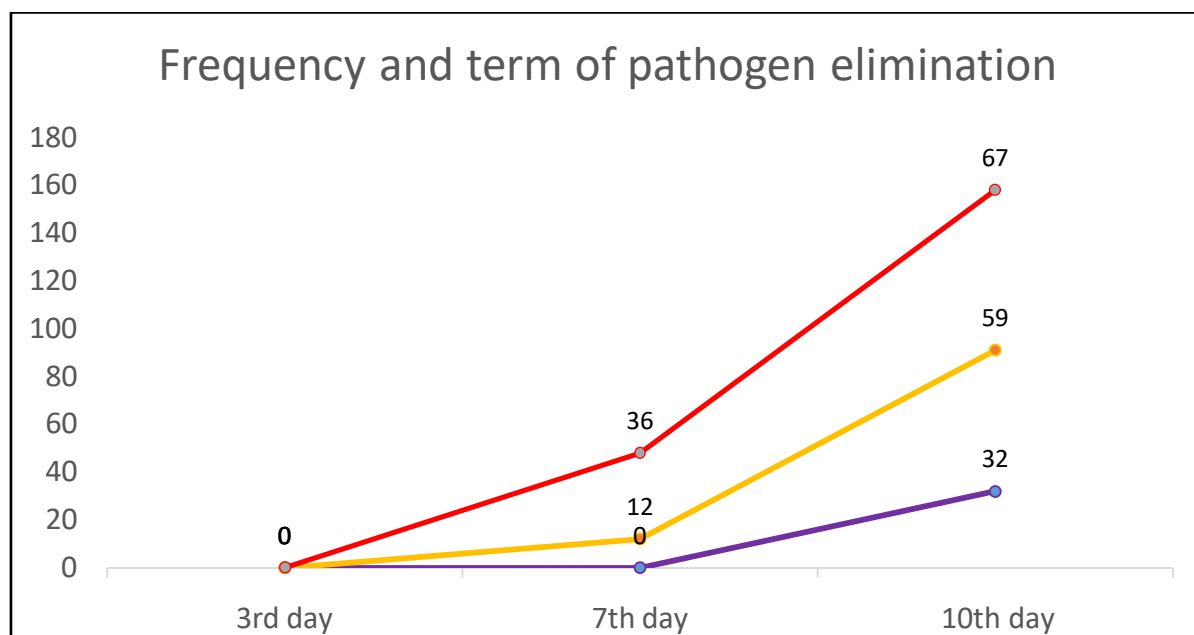
Studying the planimetric parameters obtained, we can conclude that the average daily rate of decrease in the area of purulent wounds in the control group was - 5.99% in 10 days, in the main group I, with the combined use of photodynamic therapy with photosensitizer methylene blue, the rate of shortening of the wound surface was -6.9 %, and in the main group II, with the combined use of photodynamic therapy and a CO₂ laser, the rate of shortening of the wound surface was higher and amounted to -7.2%.

In the course of monitoring the patients of the main group during the year, none of the patients showed the formation of keloid or gross hypertrophic scars. The scar tissue did not protrude above the skin level, was smooth, did not deform the skin and subcutaneous tissue, and was not adhered to the underlying tissues.

The study of the microbiology of purulent wounds shows that those obtained from patients of three groups were contaminated with microorganisms, i.e. growth was observed in all samples (100%). From 105 examined patients, 124 strains of microbes were

isolated, of which 86 (82%) were monocultures, 19 (18%) strains were found in an association of two types of microbes. In 9 (47.4%) cases, two types of staphylococci were sown; in 6 (31.5%) cultures hemolytic streptococci were associated with staphylococci and in 1 (5.3%) - E. coli. In one case, Candida fungi were excreted with E. coli, Proteus, and streptococci. The dominant pathogens of HVD were gram-positive microorganisms - 124/112 (91.4%), among which the leading position was occupied by staphylococci 83%, represented, in most of the crops, by St. aureus (92%). Representatives of the gram-negative flora were: Proteus spp. (3 / 2.5%), Ps. aeruginosae (7/6%), E. coli (2 / 1.5%).

A comparative analysis of the data obtained from the three examined groups of patients showed that all the methods of treatment used had an effect to one degree or another on the causative agent of the purulent-inflammatory process. The differences between these groups were manifested in the timing of the elimination of the pathogen (Figure 23).

**Fig. 23:** Frequency and term of pathogen elimination in comparative groups

As shown in the diagram, the change in the drillability of microbes from purulent foci occurs by the

seventh day. In 32% of patients in the control group who received traditional treatment, there was no growth of

the pathogen in the seeding on the 10th day of the study. In contrast, in group I of patients who received traditional treatment in combination with PDT, no growth of microbes was found. On the seventh day of examination in 12% of patients, and in the last study - in 59% of patients, which is 1.8 times more than in the control group. The best results were achieved in group II of the surveyed who received complex therapy - traditional treatment + PDT + CO₂ laser: elimination of the pathogen was observed on the seventh day in 36% of patients, which is 3 times higher than the indicators of group I patients. On the tenth day, the absence of growth was already in 67% of patients in this group, which is also higher than those of group I by 1.1 times, and in the control group of patients by 2 times. The data obtained allow us to conclude that the proposed method of treatment is highly effective.

Morphological studies have shown that, before surgical treatment, during histological studies, the walls and bottom of the wound are represented by destructive necrotic tissues, abundantly infiltrated by polymorphonuclear leukocytes, the tissues are edematous having venous and capillary plethora, stasis, perivascular diapedetic and focal hemorrhages.

The study of the dynamics of acute purulent-inflammatory diseases of soft tissues after traditional treatment showed that on the 3rd day, purulent-destructive and necrobiotic changes with infiltration of neutrophilic leukocytes prevailed in almost all types of purulent diseases. By the 7th day of traditional treatment, infiltration of neutrophilic leukocytes is more often observed, the number of abscesses and foci of necrosis increases, and the destruction of specific tissue structures is observed. By the 10th day of the examination, the processes of edema and destruction in the purulent-inflamed tissue calmed down somewhat, certain boundaries appeared in the areas of neutrophilic infiltration, proliferative inflammation developed around the foci of abscesses and necrobiosis, and connective tissue was formed.

IV. DISCUSSION

Thus, the presented data convincingly prove the high clinical efficacy of antibacterial therapy based on a CO₂ laser and photodynamic effects caused by the simultaneous action of a physical and chemical factor on the pathogenic microflora.

According to the literature data, the effectiveness of methylene blue as a photosensitizer in PDT has also been proven. Methylene blue has no dark toxicity to living cells. The photosensitizer and white light alone do not have photodynamic antimicrobial activity. Methylene blue had the maximum antibacterial activity at a concentration of 50 μM (0.05%). Considering the above positive qualities, methylene blue makes it

possible to widely recommend photodynamic therapy of purulent wounds in clinical medicine.

At the beginning of the twentieth century, the idea of a "magic bullet" was expressed by Paul Ehrlich, who suggested that incubation of bacteria with methylene blue dye should cause them to die when exposed to light. The effect of other photosensitizers was expressed to one degree or another, but the maximum effect with the minimum dose of laser radiation was achieved with the use of methylthioninium chloride (methylene blue) and zinc phthalocyanine [41].

The European Laser Association in 1997 published the work of S.E. Milson et al. [41,42], which reported that *H. pylori* after incubation with methylene blue, toluidine blue and hematoporphyrin derivatives was successfully inactivated at doses of 50 and 100 J / cm². The best photoinactivation effect was observed at a dose of 50 J / cm² with methylene blue. The work noted that the dose of 50 J / cm² is far beyond the damaging effect of laser radiation on the gastric mucosa [42].

The combined effect of PDT with methylene blue and a weak electric current (1 mA) on *E. coli* in vitro in order to enhance the effect of PDT increases the efficiency of PDT [34]. The effect of preliminary laser irradiation of bacteria before incubation with a photosensitizer is interesting. In cases where APDT was applied to highly resistant bacteria such as the microbacterium tuberculosis, preliminary laser irradiation disrupted the structure of the cell wall in vitro and made the bacterium more susceptible to APDT [7].

PDT with methylene blue and irradiation with broadband white light (400-700 nm) at a dose of 10 J / cm² inactivates Qb-bacteriophage RNA in vitro by linking it with plasma proteins [44].

The obtained clinical, histological, microbiological and immunological data indicate that photodynamic therapy with a laser and non-laser light source is a fairly effective non-invasive method for treating purulent wounds and serve as a rationale for the application of the method of photodynamic therapy in clinical practice for the treatment of local acute suppurative inflammation, in particular for the treatment of purulent proctological pathology [11].

The use of local photodynamic therapy in complex treatment with the use of laser radiation using the ALT "VOSTOK-03" apparatus and a photosensitizer of 0.05% methylene blue solution allows in a short time to achieve cleansing of wound surfaces from pathogenic microflora, to ensure the normalization of signs of intoxication in a shorter time compared to traditional treatment, to achieve a decrease in the number of progression of the pathological process on the foot from 31.5% to 6.7%, as well as a decrease in the number of deaths from 10.5% to 2.2% [29].

The optimal concentration of methylene blue in vitro, as well as the duration of laser radiation with a

wavelength of 630–670 nm for photodynamic effects on *Candida albicans*, have been determined. A study (on rabbits) of the possibility of using photodynamic therapy (PDT) in fungal keratitis was carried out. At the next stage, the PDT method was introduced into clinical practice for the treatment of patients with fungal keratitis. PDT with 0.1% methylene blue is an effective method of treating fungal (*C. albicans*) keratitis, which is confirmed by microbiological and clinical studies [16].

Observation of the results of treatment of patients with purulent-destructive diseases of soft tissues shows that the use of laser methods of CO₂ laser and subsequent PDT with the photosensitizer "Methylene blue" creates optimal conditions for cleansing the purulent focus from necrotic tissues and detritus, respectively, accelerating the reparative regenerative parameters. The method allows to achieve the fastest cleansing of the wound and reduce the duration of treatment in comparison with the control group of patients. The above results make it possible to evaluate the use of a CO₂ laser and PDT with a photosensitizer "Methylene blue" in the treatment of purulent-destructive diseases and to recommend it for use in surgical practice.

V. CONCLUSION

1. Selective use of a CO₂ laser allows for early and bloodless necrosectomy, improvement of wound repair, as well as reduction of its microbial contamination.
2. Photodynamic therapy, when used in patients with purulent-destructive diseases of soft tissues, allows at an earlier time to achieve cleansing of purulent wounds from pathogenic microbial flora, purulent exudate and accelerate its healing.
3. Photodynamic therapy is a fairly effective non-invasive and sparing method of treating purulent wounds and is a justified application of this method in clinical practice for the treatment of acute suppurative-inflammatory processes in combination with traditional methods.

REFERENCES RÉFÉRENCES REFERENCIAS

1. Абаев, Ю.К. Справочник хирурга. Раны и раневая инфекция / Ю.К. Абаев. - Ростов н/Д.: Феникс, 2006. - 427 с.
2. Азимшоев, А.М. Лазерная фотохимическая терапия гнойных ран с фотосенсибилизатором хлоринового ряда :автореф.дис. ... канд.мед.наук: 14.01.17 / Азимшоев А.М. – М., 2008.– 22 с.
3. Ахмедов, Б.А. Оптимизация методов лечения раненых с огнестрельными переломами костей конечностей: автореф. дис. ... д-ра мед. наук: 14.01.15, 14.01.17 / Ахмедов Багавдин Абдулгаджиевич. – СПб., 2010. – 48 с.

4. Баранов Е. В., Буравский А. В. и др. Антибактериальная фотодинамическая терапия в комплексном лечении пациентов с гнойно-септической патологией. «Лазерная и фотодинамическая терапия в медицине» Научно-практическая конференция . Гродно, ГрГМУ 2011. С 5-7.
5. Блатун Л. А. Местное медикаментозное лечение ран. Проблемы и новые возможности их решения / Л. А. Блатун // Consilium medicum. Хирургия. - 2007. - № 1. - С. 51-59.
6. Винник, Ю.С. Современные методы лечения гнойных ран / Ю.С. Винник, Н.М. Маркелова, В.С. Тюрюмин // Сибирское медицинское обозрение. – 2013. - № 1. – С. 18-24.
7. Волкова А., Лощенов В., Ершова Е. и др. Лазерные и информационные технологии в медицине XXI века// Материалы международной конференции. - СПб., 2001. - С. 414.
8. Галимзянов, Ф.В. Местное лечение и рациональная антибактериальная терапия инфицированных ран / Ф.В. Галимзянов // Международный журнал экспериментального образования. – 2014. - № 8, часть 2. – С. 111-112.
9. Гельфанд Б.Р. и др. Хирургические инфекции кожи и мягких тканей. Российские национальные рекомендации. Под ред. Б.Р. Гельфанда и др. М.: «Издательство МАИ», 2015, 109 с.
10. Гельфанд Б.Р. и др. Хирургические инфекции кожи и мягких тканей. Российские национальные рекомендации. Под ред. Б.Р. Гельфанда и др. М.: «Издательство МАИ», 2015, 109 с.
11. Гинюк В. А. Использование фототерапии для лечения гнойных ран и возможность ее применения у больных с острым парапроктитом / В. А. Гинюк // Военная медицина. - 2010. - №3.-С.79-83.
12. Дербенев В.А., Азимшоев А.М., Шарифов А.Д. Фотодитазин в комплексном лечении гнойных ран.// Рос. биотерапевт. Журн. 2007; 1:.
13. Дербенев, В.А. Крайне высокочастотная и лазерная терапия в лечении больных с гнойными ранами мягких тканей /В.А.Дербенев и соавт // Лазерная медицина. – 2010. – Т. 14. Выпуск 3. – С. 8 – 11.
14. Дуванский, В.А. Фотодинамическая терапия и воздушно-плазменные потоки в комплексном лечении больных с осложненными формами рожи / В.А. Дуванский, В.И. Елисеенко // Лазерная медицина. - 2004. - Т. 8, № 1-2. - С. 54-56.
15. Ерюхин И.А., Гельфанд Б.Р., Шляпников А.С. Хирургическая инфекция.// Питер. 2003, с. 106.
16. Зборовская А.В., Дорохова А.Э. Фотодинамическая терапия в лечении грибковых кератитов – от исследований «in vitro» к клинической практике. Точка зрения. Восток - Запад. 2016 № 2

17. Ищук А.В., Леонович С.И. Использование фотодинамической терапии лазерным аппаратом «Родник-1» с фотосенсибилизатором «Хлорофиллипт» в лечении гнойных ран и трофических язв нижних конечностей. 2008 -№1, том 16.
18. Корабоев У.М. Фотодинамическая терапия гнойных, длительно незаживающих ран и трофических язв (экспериментально-клиническое исследование)// Автореф. дис. д-ра мед. наук. М 2001.
19. Корейба К. А. Хирургические инфекционные поражения кожи и мягких тканей. Лечение длительно незаживающих ран: моногр. / К. А. Корейба, А. Р. Газиев. — Казань: Отечество, 2011. — 253 с.
20. Митиш, В.А. Гнойно-некротические поражения при нейроишемической форме синдрома диабетической стопы / В.А. Митиш, Ю.С. Пасхалова, И.А. Ерошкин, Г.Р. Галстян, Л.А. Блатун // Хирургия. – 2014. - № 1. – С. 48-53.
21. Рычагов П., В.М. Русинович, В.А. Гинюк . К обоснованию фотодинамической терапии при гнойной патологии .// Актуальные вопросы современной хирургии: материалы науч. конф., посвящ. 60-летию со дня рождения проф. Ю.С. Винника. Москва-Красноярск, 2008 г. С. 387–391.
22. Савельев В.С. и соав. Хирургические инфекции кожи и мягких тканей. Российские национальные рекомендации. Москва , 2009 г. Монография.
23. Савельева В.С., Кириенко А.И. Клиническая хирургия: национальное руководство: в 3 т. Под ред. Савельева В.С., Кириенко А.И.. Т. 1. М.: ГЭОТАРМедиа, 2008, 864 с.
24. Садыков Р.А., Касымова К.Р., Садыков Р.Р. Технические и научные аспекты фотодинамической терапии.- Ташкент, 2012.
25. Сидоренко, С.В. Микробиологические аспекты хирургических инфекций / С.В. Сидоренко // Инфекции в хирургии. - 2003- Т. 1, № 1.- С. 22-27.
26. Странадко Е.Ф. Конференции по лазерной медицине как летопись двадцати лет развития фотодинамической терапии в России и Украине. ФОТОБИОЛОГИЯ ТА ФОТОМЕДИЦИНА, 1, 2 '2013
27. Толстых П.И., Петрин С.А., Дербенев В.А., Азимшоев А.М. При-менение фотодинамической терапии в комплексном лечении трофических язв венозной этиологии.// «Высокие хирургические, лазерные и информационные технологии в медицине». Сб. науч. тр. Ст-Петербург 2003; 17—19.
28. Толстых П.И., Странадко Е.Ф., Корабоев У.М и др. Фотодинамическое воздействие на бактериальную микрофлору ран в эксперименте.// Журн. микробиологии, эпидемиологии и иммунобиологии. 2001. № 2. С. 85–87.
29. Хамдамов Б.З., Сайфиддинов С.И. Оптимизация методов местного лечения гнойно-некротических поражений стопы при сахарном диабете // Международный журнал прикладных и фундаментальных исследований. – 2015. – № 3-1. – С. 22-24;
30. Шандуренко И.Н. Биологически активные гелеобразующие перевязочные средства в комплексном лечении гнойных и огнестрельных ран. // Автореф. дисс. на соискание уч. степени док. мед. наук-М. 2006- С.30.
31. Шляпников, С.А. Использование макролидов при хирургических инфекциях кожи и мягких тканей / С.А. Шляпников, В.В. Федорова // Русский медицинский журнал. - 2004. - Т. 12, № 4. – С. 204-207.
32. Шляпников, С.А. Хирургические инфекции мягких тканей. Подходы к диагностике и принципы терапии / С.А. Шляпников, Н.Р. Насер // Русский медицинский журнал. - 2006. - Т. 14, № 28. – С. 2009-2013.
33. Яковлев С. В. Госпитальные инфекции, вызванные грамотрицательными микроорганизмами: клиническое значение и современные возможности терапии / С. В. Яковлев // Инфекции и антимикроб. терапия. - 2007. - № 6. - С. 133-36.
34. Capella M. , Menezec S.// Int . J. Radiat. Biol. - 1992. - Vol. 62 (3). - P. 321- 326.
35. Chebotar I.V., Mayanskiy A.N., Konchakova E.D., Lazareva A.V., Chistyakova V.P. Antibiotic resistance biofilm bacteria. Klinicheskaya mikrobiologiya i antimikrobnaya khimioterapiya. 2012; 14 (1): 51–8.
36. Danilevicius, M. MRSA decontamination using octenidine-based products / M. Danilevicius, A. Juzeniene, I. Juzenaite-Karneckiene, A. Versinina // Br. J. Nurs. – 2015. – Vol. 24, Sup. 15. – P. S36-S40.
37. Falanga V. Wound Bed Preparation in Practice //EWMA JOURNAL. – 2004. - V. 4, N. 2. – P. 2-5.
38. Kozlov R.S., Krechikova O.I., Ivanchik N.V. et al. Etiology of Nosocomial Bacterial Infections in Russia. Rosnet Study Group. Proceedings of the 48th Interscience Conference on Antimicrobial Agents and Chemotherapy; 2008 Oct 25-28; Washington, DC, USA; p. 572, abst. K-4108.
39. Kratz G., Back M., Arnander C. et al. Immobilised beparin accelerates the healing of human wounds in vivo // Scand.J. Plast. Reconstr. Surg. Hand. Surg. - 1998. -Vol. 32, № 4. - P. 3B1-3B5.
40. Li, T. Effect of negative pressure on growth, secretion and biofilm formation of Staphylococcus aureus / T. Li, G. Wang, P. Yin, Z. Li, L. Zhang, J. Liu, M. Li, L. Zhang, 178 L. Han, P. Tang // Antonie Van Leeuwenhoek. – 2015. – Vol. 108, Is. 4. – P. 907-917.

41. Milson C. // Lasers in Medical Science. - 1997. - Vol. 12, № 2. - P. 134- 135.
42. Milson C. et al// Ann. Univ. College. - London: Medical School, 1998. - On-Line.
43. Pulgar S., Mehra M., Quintana A. et al. The epidemiology of hospitalised cases of skin and soft tissue infection in Europe. 18th European Congress of Clinical Microbiology and Infectious Diseases. 2008, Barcelona, Spain, Abstr. P821.
44. Schneider J., Quentin P., Floyd R. // Photochem. Photobiol. -1999. - Vol. 70 (6). - P. 902- 909.

