



GLOBAL JOURNAL OF MEDICAL RESEARCH: F
DISEASES
Volume 22 Issue 1 Version 1.0 Year 2022
Type: Double Blind Peer Reviewed International Research Journal
Publisher: Global Journals
Online ISSN: 2249-4618 & Print ISSN: 0975-5888

Problems of Early Diagnosis of the Abdominal Cavity with Concomitant Abdominal Trauma in Children

By Khadjibaev A.M., Juraev J.A., Pulat K. Sultanov
& Makhmudjon M. Pulatov

Abstract- In the structure of child mortality, trauma comes first among the causes of death in children over one year of age. Mortality in children with multiple and concomitant trauma remains high - from 7.1 to 22%.

The aim of the work is to improve the results of diagnostics and surgical treatment of post-traumatic stress disorder with closed abdominal trauma using medical tactics in dependence on the severity of trauma and the degree of damage to the organs and the use of modern methods of surgery.

Materials and methods: Over the past 10 years (2010-2019), 118 patients aged 1 to 18 years with associated injuries were hospitalized in the Republican Scientific Center for Emergency Medical Aid (RSCEMA) in the department of emergency surgery. All patients underwent a comprehensive examination, which included X-ray studies, CT, endovisual and endosurgical interventions.

Keywords: *polytrauma, concomitant trauma, catatrauma, complex diagnostics, abdominal trauma.*

GJMR-F Classification: NLMC Code: WI 900



Strictly as per the compliance and regulations of:



Problems of Early Diagnosis of the Abdominal Cavity with Concomitant Abdominal Trauma in Children

Khadjibaev A.M.^α, Juraev J.A.^σ, Pulat K. Sultanov^ρ & Makhmudjon M. Pulatov^ω

Abstract- In the structure of child mortality, trauma comes first among the causes of death in children over one year of age. Mortality in children with multiple and concomitant trauma remains high - from 7.1 to 22%.

The aim of the work is to improve the results of diagnostics and surgical treatment of post-traumatic stress disorder with closed abdominal trauma using medical tactics in dependence on the severity of trauma and the degree of damage to the organs and the use of modern methods of surgery.

Materials and methods: Over the past 10 years (2010-2019), 118 patients aged 1 to 18 years with associated injuries were hospitalized in the Republican Scientific Center for Emergency Medical Aid (RSCEMA) in the department of emergency surgery. All patients underwent a comprehensive examination, which included X-ray studies, CT, endovisual and endosurgical interventions.

Results: The most frequent combinations of abdominal injuries were observed in patients with head trauma – 104 (88%) cases, chest – 31 (29.8%), limbs – 16 (13.6%), spine – 2 (1.7%) and pelvis – 1 (0.84%). Injuries were received by victims of road accidents – 78 (66.4%) cases, falls from a height – 39 (33.0%) and domestic injuries – 1 (0.84%).

Among the patients, a combination of 6 anatomical areas was identified in 6 (5%) cases; 5 regions – 8 (6.8%); 4 regions – 18 (15.2%); 3 regions – 46 (39%) and 2 regions – 40 (33.9%)

Conclusions: Improvement of minimally invasive methods for diagnosing abdominal injuries by expanding the therapeutic capabilities of video laparoscopy improves the results of surgical treatment for concomitant abdominal trauma.

Keywords: polytrauma, concomitant trauma, catatrauma, complex diagnostics, abdominal trauma.

I. INTRODUCTION

A feature of modern childhood traumatism is an increase in the number of many types of injuries – combined and multiple trauma, leading to an increase in mortality and disability [1]. In peacetime, concomitant injury most often occurs because of road accidents and falls from a height [7].

According to the many authors, the mortality rate in childhood with associated injuries ranges from 7.1% to 22% [2,3]. High mortality is associated with late diagnosis of internal bleeding, as well as the emergence of several foci of nociceptive pathological impulses, which, with a sufficiently long and intense exposure, leads to disintegration and disruption of urgent compensatory mechanisms, therefore, to an increase in the severity and resistance of traumatic shock. [3.4]

The combination of trauma to the abdominal organs with damage to other anatomical areas of the body aggravates the condition of the victim, significantly complicates the diagnosis and worsens the prognosis [6]. In a timely manner undetected abdominal injuries lead to an error in the choice of surgical tactics. Despite the improvement of laboratory instrumental and minimally invasive diagnostic methods, in the surgery of abdominal injuries, the errors of diagnosis and, accordingly, the surgical treatment tactics are 20-38%. [3.4]

The aim of the study is to develop a therapeutic and diagnostic algorithm for surgical treatment for concomitant abdominal trauma in children.

II. MATERIALS AND METHODS

Over the past 10 years (2010-2019), 118 patients aged 1 to 18 years with combined injuries were hospitalized in the Republican Scientific Center for Emergency Medical Aid (RSCEMA) in the department of emergency surgery. Of these, 61 (33.9%) patients applied through the emergency room, 51 (43.2%) – by gravity without a referral, and 6 (5%) – by gravity in a referral from other institutions. 83 (70.3%) were boys and 36 (29.6%) were girls.

Taking into account the periodization of childhood adopted in pediatrics, the material is divided into three age groups: younger, from 0 to 3 years – 17 (14.4%) children, average age 1.8 ± 1.1 years; average,

Author α: Doctor of Medical Sciences, Professor, Minister of Health of the Republic of Uzbekistan.

Author σ: Doctoral student, Resident Doctor, Republican Scientific Center of Emergency Medical Care, Tashkent, Uzbekistan.

Author ρ: Doctor of Medical Sciences, Doctor of Emergency Surgery at the RSCEMA, Tashkent, Uzbekistan. e-mail: sultanovpk@bk.ru

Author ω: Ph.D., Resident of the Department of Emergency Surgery No. 1 of the Republican Scientific Center for Emergency Medical Aid of the Republic of Uzbekistan.

4-11 years old – 69 (58.5%) patients, average age 8.4 ± 2.1 years; the oldest, 12-18 years old – 32 (27.1%) children, the average age is 15 ± 1.5 years [5]. Injuries were received by victims of road accidents – 78 (66.4%) cases, falls from a height – 39 (33.0%) and domestic injuries – 1 (0.84%).

Among the patients, a combination of 6 anatomical areas was identified in 6 (5%) cases; 5 regions – 8 (6.8%); 4 regions – 18 (15.2%); 3 regions – 46 (39%) and 2 regions – 40 (33.9%) (Diagram. 1).

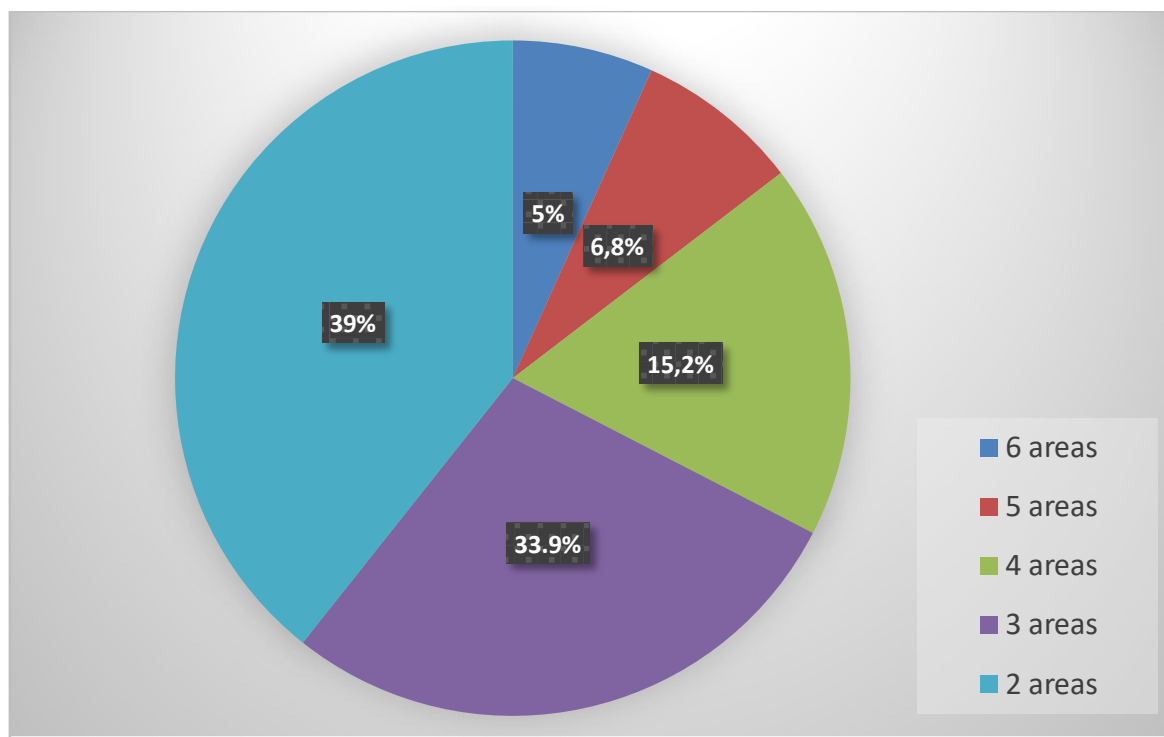


Diagram 1: Abdominal trauma in combination with other areas of the body.

The most frequent combinations of abdominal injuries were observed in victims with head grass – 104 (88%) cases, chest – 31 (29.8%), limbs – 16 (13.6%), spine – 2 (1.7%) and pelvis – 1 (0.84%) (Fig. 2)

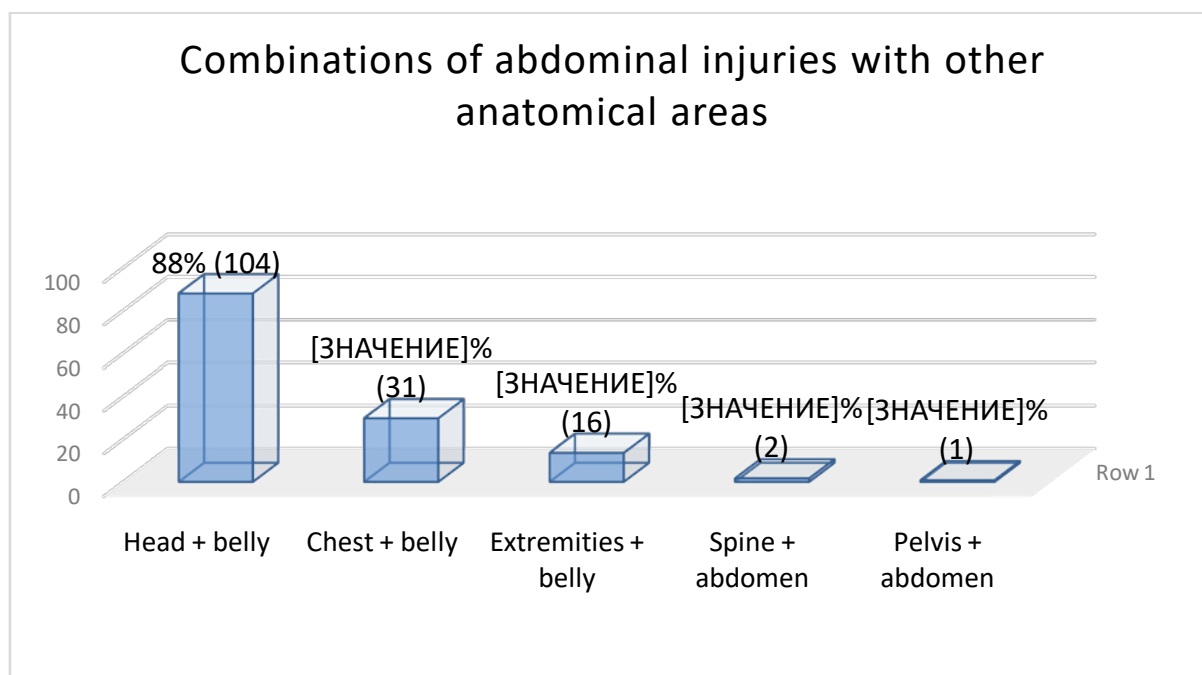


Diagram 2: Combinations of abdominal injuries with other anatomical areas.

The logistic factor, which determines the duration of treatment and the timeliness of diagnostic and therapeutic procedures, depending on the severity of the injuries, plays the most essential role in the therapeutic efficacy in concomitant trauma [9]. The key to success at the stages of diagnosis and determination of treatment tactics is the first "golden" hour of hospitalization, during which it provides an opportunity for the survival of victims with associated trauma. Of the 118 hospitalized patients with associated injuries, 73 (62%) patients came to the RSCEMA within 1 hour from the moment of injury, 18 (10%) - 2 hours, 9 (5%) - 5 hours, 18 (10%) - more than 5 hours.

The severity of the injury was assessed using the ISS scale [8]. Assessment of the severity of the injury showed that among them, injuries of a critical degree prevailed - 31 (26.3%) patients, 63 severe (53.4%) and 24 moderate (20.3%).

Among children with concomitant trauma, 64 (54.2%) were admitted in consciousness, 14 (11.9%) - in a state of stunning, 7 (5.9%) - in a soporous state, 33 (28%) - in various degrees of coma.

Determination of the dominant trauma is one of the most difficult sections in the treatment of victims with concomitant trauma. In the analyzes carried out by our center with combined trauma, in 85 (72%) cases, abdominal injuries were the dominant trauma, which posed the greatest threat to the victim's life. In most cases, with combined abdominal trauma, liver damage was noted in 40 (33.9%) cases, spleen - 39 (33%), kidney - 6 (5.08%), small intestine - 6 (5.08%), large intestine - 2 (1.7%) and gallbladder - 2 (1.7%). (Diagram 3).

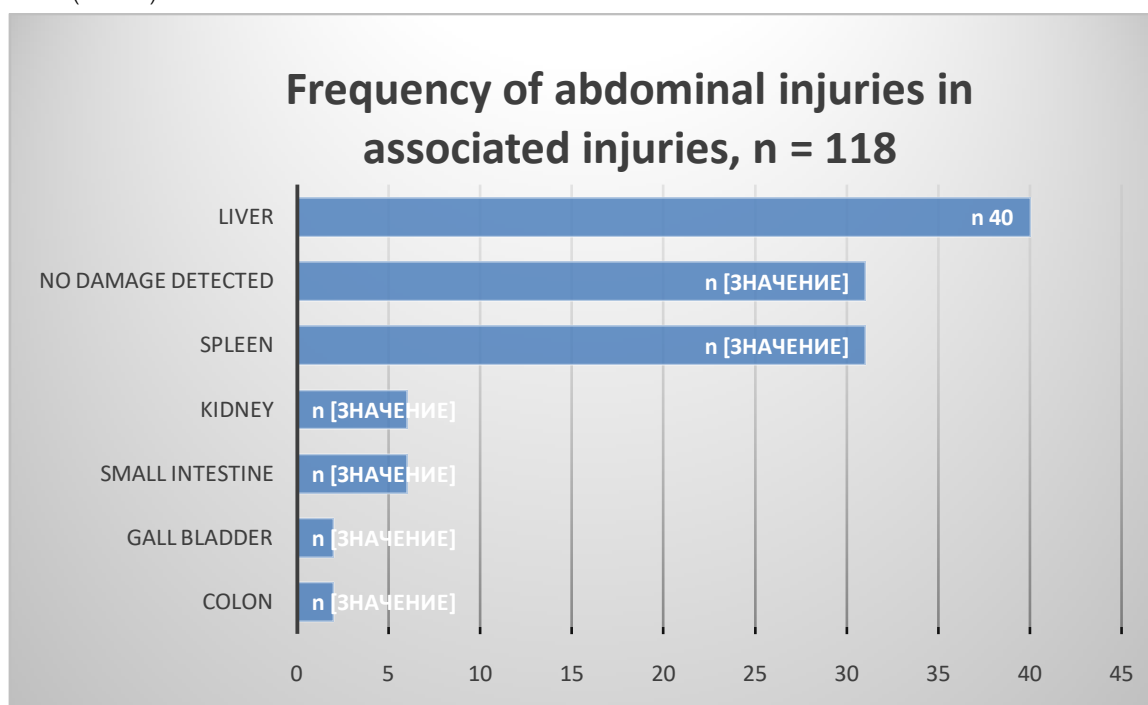
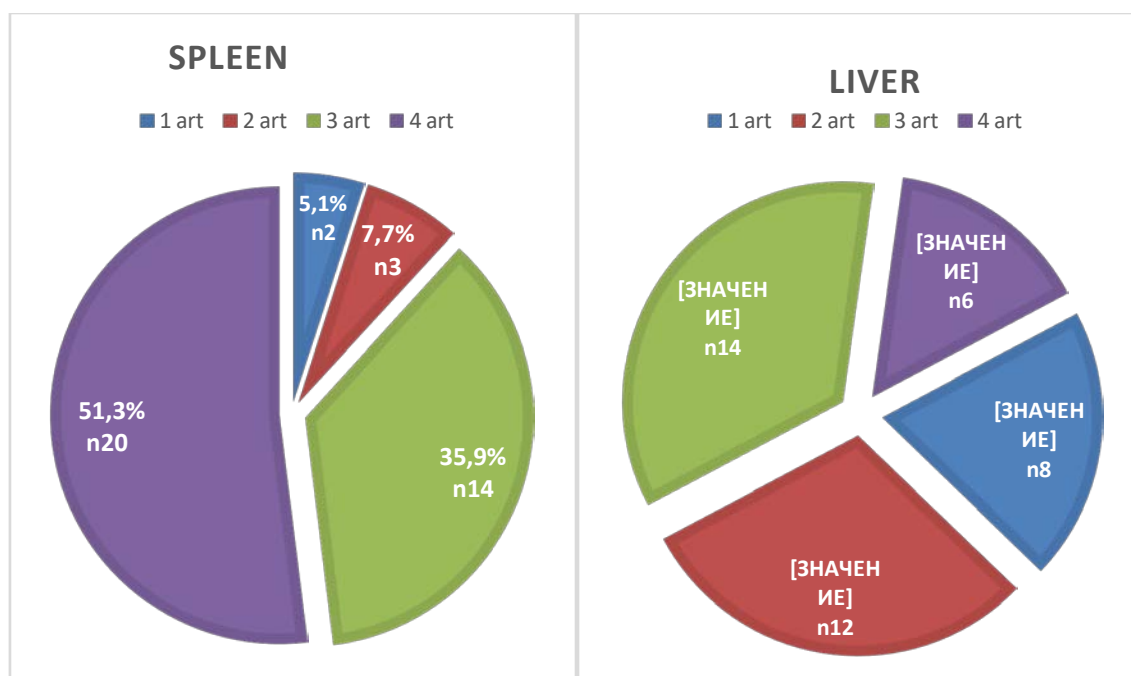


Figure 3: Frequency of injuries to the abdominal organs in concomitant injuries in children.

In our observations, the source of hemoperitoneum was mainly damage to the liver and spleen. According to the classification of injuries of parenchymal organs AATS (American Association of Trauma Surgery, 1994) - the American Association of Injury Surgery, a shortened scale of injuries, where 5 degrees of severity are distinguished [8,10], damage to the spleen I degree was noted in two cases (5.1%); grade II spleen injury was observed in 3 (7.7%) patients; III degree - in 14 (35.9%) patients; IV degree - in 20 (51.3%) victims, respectively. Grade V damage to the spleen was not observed. First-degree liver damage was detected in 8 (20%) patients; second degree - in 12 (30%); the third - in 14 (35%); the fourth - in 6 (15%). the

fifth degree of degree of damage was not revealed in our patients.

The degree of damage to the parenchymal organs of the abdomen according to AIS



III. RESULTS AND DISCUSSION

In the diagnosis of combined abdominal injuries, ultrasound played an important role. Instrumental studies were started with ultrasound, with further re-examination 1 hour after admission and every 3 hours during the day. Among 118 children with concomitant injuries, in 90 (76.3%) cases, an ultrasound examination of the abdominal organs was performed, in 5 (4.2%) cases an emergency operation was performed without preliminary ultrasound examination, 23 (19.5%) died during shock measures upon admission before the ultrasound. At the same time, the sensitivity of ultrasound in determining hemoperitoneum in patients with abdominal trauma was 95.6%, and the diagnostic efficiency was 97.9%.

Polypositional radiography was performed according to standard techniques, while in 99 (83.9%) cases a simultaneous plain radiography of the skull, spine, chest and abdomen (including laterography), pelvis and extremities (according to indications) was performed. Of the total number of studies, 54 (53.5%) patients showed various bone-traumatic injuries of the limb on X-ray examination, 6 (5.94%) patients showed rib fractures and 39 (39.4%) children showed no pathology on X-ray. revealed. The sensitivity of X-ray examination in the diagnosis of injuries to the abdominal organs was low and amounted to 41.2 to 66.4%.

Multispiral computed tomography (MSCT) is a non-invasive method that provides valuable additional information about the extent, number and extent of damage in associated injuries. MSCT was performed in 46 (39%) patients. At the same time, MSCT of the head and neck was performed in 11 (24%), chest - 4 (8.7%),

abdomen - 12 (26%), pelvis - 2 (4.3%). In 3 (6.5%) cases, a total MSCT examination was performed from the head to the lower extremities, which made it possible to simultaneously reveal the presence of damage to all anatomical regions in a few minutes. MSCT had a sensitivity of 97% -98%, a specificity and accuracy of 98%.

The final method in diagnosing abdominal injuries was laparoscopy, which made it possible to avoid unnecessary laparotomies. Diagnostic laparoscopy was performed in 45 (38.1%) cases of patients with ultrasound examination of the presence of free fluid in the abdominal cavity. Of these, 6 (5.1%) cases of abdominal injuries were not detected, in 4 (3.4%) patients, the operation was completed laparoscopically by coagulation of small ruptures of parenchymal organs and sanitation of the abdominal cavity: in 1 (0.8%) case performed laparoscopic suturing of the rupture of the liver, in 3 (2.5%) - diathermocoagulation of ruptures of the spleen. Diagnostic laparoscopy in 35 (29.7%) children revealed the presence of a large amount of blood due to deep damage to the liver and spleen with active bleeding, in connection with which they underwent a conversion to laparotomy. In 30 (25.4%) cases, laparotomy was immediately performed due to a large amount of free fluid on ultrasound and unstable hemodynamic parameters, among which in 23 (19.5%) cases the operation ended with coagulation and suturing of liver damage, in 32 (27, 1%) - splenectomy.

Diagnostic laparoscopy makes it possible to determine the amount and nature of fluid in the abdominal cavity and, based on this, the volume of the operation is planned: to complete the operation

laparoscopically or switch to laparotomy. In 73.3% of cases of associated injuries, diagnostic and therapeutic laparoscopy made it possible to complete the operation laparoscopically without unnecessary laparotomy, however, due to the diagnosis of extensive damage to the abdominal organs with active bleeding and the presence of a large amount of free blood in the abdominal cavity, in 26.0% of cases, conversion to laparotomy was performed. The sensitivity of diagnostic laparoscopy for blunt abdominal trauma was 100%, specificity - 91% and accuracy - 96%. It were not observed complications after diagnostic manipulations. The mortality rate of children with concomitant abdominal trauma was 21 (23%) children. The total number of bed-days was 9.3 ± 0.8 .

In case of combined injury, together with the operation of the abdominal cavity, operations were performed simultaneously:

- 15 operations on the head. Craniotomy with removal of subdural hematoma - 3, intracerebral hematoma-2, Imposition of dilated cranial holes with removal of intracerebral hematoma and drainage -1, Imposition of dilated cranial openings with removal of subdural hematoma-2, Open osteosynthesis-2 with pin osteosynthesis -2, Closed osteosynthesis by

pinning-2, Closed osteosynthesis with an external fixation device-1.

- 11 operations on the chest. Thoracotomy Suturing of a lung injury-1, Thoracoscopic hemostasis in case of injury of intercostal arteries-1, Thoracoscopic coagulation of a lung injury-4, Thoracoscopic suturing of a lung injury-2, Removal of coagulated hemothorax-3.
- 66 surgical interventions for injuries of the musculoskeletal system. Most of all were hip injuries - 28 operations, lower leg bones - 32 and pelvic bones - 6.

It was created a tactic based on the Ultrasound Score - USS scale (Fig. 2) to improve the diagnosis of injuries to the abdominal organs. An ultrasound scan in dynamics is conducted with a zero USS score, i.e. in the absence of free fluid in the abdominal cavity, and an operation of the dominant injury is performed in the presence of a dominating damage to another anatomical location. Diagnostic laparoscopy or laparotomy are performed when USS is equal to 1 or 2 or more. The operation of other anatomical locations is performed after intra-abdominal bleeding has been stopped and the integrity of the internal organs of the abdominal cavity has been eliminated.

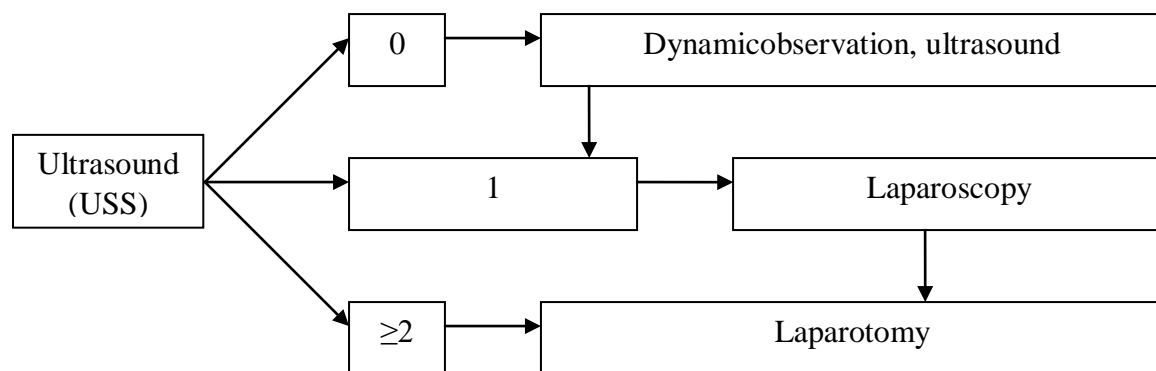


Figure 2: Algorithm for the treatment of patients with closed abdominal trauma

According to the recommended algorithm, the first stage is to restore the functions of vital organs with the elimination of damage to the anatomical regions, where there is a dominant, life-threatening nature of damage. The restoration of the anatomical and functional integrity of other anatomical areas, where the nature of the damage is not dominant, is carried out in the second stage.

IV. CONCLUSIONS

1. Ultrasound gradation of the volume of free fluid in the abdominal cavity USS (Ultrasound Score) makes it possible to determine the surgical tactics for concomitant abdominal trauma.

2. In cases of severe trauma with unstable hemodynamics, a total MSCT examination from the head to the lower extremities is justified for the timely detection of the dominant injury and other injuries.
3. Improvement of minimally invasive methods for diagnosing abdominal injuries by expanding the therapeutic capabilities of video laparoscopy improves the results of surgical treatment for concomitant abdominal trauma.
4. The proposed algorithm allows, first of all, to restore the dominant and life-threatening damage to the anatomical areas, from which, along with anti-shock measures, it is necessary to begin the surgical treatment tactics.

REFERENCES RÉFÉRENCES REFERENCIAS

1. Shapkina A.N. "Closed trauma of living animals in children". Tutorial. Vladivostok Medicine DV 2017. Art 4-5. [Shapkina A.N Zakritaya travma jivoat u detey. Uchebnoe posobie. Vladivostok Meditsina DV 2017. St 4-5.]
2. Abakumov M.M., Lebedev N.V., Malyarchuk V.I. "Injury to the abdomen with concomitant injury". M Medicine 2005; 178 [Abakumov M.M., Lebedev N.V., Malyarchuk V.I. Povrej-deniya jivota pri sochetannoy travme. M Meditsina 2005; 178]
3. AkilovKh.A., PrimovF.Sh. "Bulletin of Emergency Medicine", 2014, No. 3 Improving the diagnosis and surgical treatment of closed abdominal injuries in children. Pp. 96-100 [Akilov X.A., Primov F.Sh. Vestnik ekstrennoy meditsiny, 2014, № 3 Sovershenstvovanie diagnostiki i xirurgicheskogo lecheniya zakritix travm jivota u detey. 96-100 st]
4. F. CHIKAEV, R. A. Ibragimov, and Yu. V. Bondarev Kazan State Medical University City Emergency Hospital No. 1, Kazan [CHIKAEV V.F., IBRAGIMOV R.A., BONDAREV Yu.V. Kazanskiy gosudarstvenniy meditsinskiy universitet Gorodskaya bolnitsa skoroy meditsinskoy pomoshi № 1, g. Kazan]
5. Vorontsov I.M., Mazurin A.V. Propedeutics of childhood diseases. SPb: Folio 2009. [Vorontsov I.M., Mazurin A.V. Propedevtika detskix bolezney. SPb: Foliant 2009.]
6. Abakumov M.M., Galankina I.E., Vilk A.P. Possibilities of conservative treatment of spleen injuries with closed abdominal trauma. Magazine them. N.V. Sklifosovsky "Emergency medical care." 2013; (4): 30-34.
7. Spiridonova EA, Rumyantsev SA, Sharshov FG et al. "Improving the provision of emergency medical care to children with severe trauma". Intensive care bulletin. 2012.-1.-P.74-80. [Spiridonova Ye A, Rumyantsev S.A, Sharshov F.G idr. Sovershenstvovanie okazanie ekstrennoy meditsinskoy pomoshi detyam s tyajyoloy travmoy. Vestnik intensivnoy terapii. 2012.-1.-S.74-80.]
8. Khadjibaev A.M., Sultanov P.K., Kim Hoon. Features of Patients Associated with Falls from Heights Admitted to Republican Research Center of Emergency Medicine. Journal of Trauma and Injury (Seoul, South Korea). 2015 No. 28 (4). P.223-294. DOI: 10.20408 / jti.2015.28.4.248
9. Milyukov AYU. Tactical features consistent with differentiated medical care to victims with injuries of the pelvis in the prehospital and transportation. GeniusofOrthopedics. 2012; 4: 24-28.
10. Baker, S. P., O'Neill, B., Haddon, W., Jr., & Long, W. B. The injury severity score: A method for describing

patients with multiple injuries and evaluating emergency care // Journal of Trauma. - 1974.- N14. - P187-196.