

CrossRef DOI of original article:

# Treatment and Evolution of Appendicular Mucoceles in Six Cases

Received: 1 January 1970 Accepted: 1 January 1970 Published: 1 January 1970

## Abstract

*Index terms—*

## 1 Introduction

appendiceal mucocele (AM) or mucosecretory tumor of the appendix is a pathological entity referring to cystic dilatation of the appendiceal lumen, secondary to intraluminal accumulation of mucinous, gelatinous, or translucent secretions, which may involve the entire organ or a segment of it, most often distal [1].

This condition is rare. It is observed in 0.15 to 0.6% of appendectomies and represents 7% to 8% of appendicular tumors [2]. Its treatment ranges from simple appendectomy in benign forms to right hemicolectomy for cancer in malignant mucoceles [3].

The most serious complications are the risk of malignancy and peritoneal pseudomyxoma (PMP) in case of perforation [4,5]. The objective of this work was to report our experience in the management of appendiceal mucoceles.

## 2 II.

## 3 Our Observations

Over an 11-year period from 2010 to 2020 we performed 2024 appendectomies. An anatomopathological examination of the surgical specimen was performed in 876 cases. This examination showed an appendicular mucocele in 6 cases (0.68%). We report below the observations of these 6 patients.

## 4 Observation 1

A 44-year-old patient with no prior history of any kind visited the surgical emergency room with right iliac fossa pain that had been evolving for three days. The patient had nausea but no transit disorders. On clinical examination, the temperature was 38.5°C, the general condition was preserved and there was pain and tenderness in the right iliac fossa. Clinically the diagnosis of appendicular syndrome was retained. The sedimentation rate was accelerated with figures of 50 at the first hour and 75 at the second hour. On the blood count, the white blood cell count was 10500/mm<sup>3</sup>. Abdominal ultrasound revealed pain in the right iliac fossa when the probe was passed, and a thick-walled non-compressible appendix. The diagnosis of appendicitis was made and the patient was operated on using the McBurney approach. Intraoperatively, an appendix measuring 8.5 cm x 5 cm with a point of increased volume was discovered. Appendectomy was performed. The postoperative course was simple and the patient was discharged at D3 postoperatively after resumption of transit and oral feeding.

Anatomopathological examination of the appendicular specimen (figure 1) showed a simple appendicular mucocele without any degenerative focus (figure 2, 3). The colonoscopy performed at 3 months was normal. The patient was lost to follow-up after 12 months.

A Observation 2 A 63-year-old patient with no previous history consulted for a painful but non febrile mass in the right iliac fossa that had appeared three months earlier. The mass had progressively increased in size until it reached the present dimensions. There was no transit disorder (diarrhea, constipation) and no rectal bleeding. The physical examination revealed a painful right iliac fossa with a regular surface, poorly limited, fixed to the deep and superficial plane. On rectal examination, the lower pole of the mass could not be felt. Clinically, the diagnosis of colonic tumor was evoked. Colonoscopy could not be performed and tumor markers (CEA, CA 19-9) were not detected. The sedimentation rate was accelerated with figures of 45 at the first hour and 85 at the

second hour. The white blood cell count was 13500/mm<sup>3</sup>. The C-reactive protein was increased to 200 mg/l. Abdominal ultrasound revealed a heterogeneous mass in the right iliac fossa, suggesting an abscess. The patient was operated by median laparotomy. When the abdomen was opened, there was no abscess in the right iliac fossa, but a large appendix measuring 15 cm x 7 cm, with a pedicle base on the cecum. On palpation of the colonic frame there was no tumor, there was no adenopathy in the abdomen, no ascites or mucus. The diagnosis of appendicular mucocele was evoked. An appendectomy with resection of the base of the cecum was performed. The postoperative course was simple and the patient was discharged at 5 days postoperatively after resumption of transit and oral feeding.

The anatomical-pathological examination showed a simple appendicular mucocele without any degenerative focus. Colonoscopy performed at 3 months postoperatively was normal. The patient was lost to follow-up after 6 months.

## 5 Observation 3

A 38-year-old G3P3 patient with no particular medical or surgical history consulted the surgical emergency room for right iliac fossa pain evolving for three days. The date of the last ones was known by the patient, there was no menstrual cycle disorder. The patient also complained of nausea and vomiting. The physical examination revealed pain and tenderness in the right iliac fossa, the temperature was 38.9°C. The rectal examination revealed pain at the top and right fingertips. The vaginal touch was normal. The sedimentation rate was 45 at the first hour and 70 at the second hour. The white blood cell count was 14500/mm<sup>3</sup>. The C-reactive protein was increased to 78mg/l. Abdominopelvic ultrasound showed a hypoechoic structure with a thickened wall suggesting a periappendicular abscess. The right uterine adnexa and uterus were normal. The patient was operated by laparotomy (Mc Burney). During the operation, an appendix measuring 8 cm long was discovered, enlarged in its proximal part and indurated in its median part. The right uterine appendages were unremarkable. An appendectomy was performed (Figure 4). The postoperative course was simple and the patient was discharged at 2 days postoperatively.

Anatomopathological examination of the appendectomy specimen showed a mucinous cystadenocarcinoma without invasion of the appendicular base. There was no metastatic embolism in the vessels and no perineural envelopment. Pelvic ultrasound performed at three months post-op showed normal right and left uterine appendages. The colonoscopy performed at the same date was normal. The patient refused the proposed reintervention to perform a hemicolectomy. Tumor markers (CEA, CA 19-9 ca 125) were normal at 12 and 24 months. The last pelvic ultrasound done after 36 months was normal. She was subsequently lost to follow-up.

## 6 Observation 4

A 54-year-old patient was admitted to the emergency room with sudden onset right iliac fossa pain that had been evolving for 4 days with nausea but no transit disorders. On clinical examination, the temperature was 38.5°C, there was pain and tenderness in the right iliac fossa. Abdominal ultrasound was not performed. The sedimentation rate was accelerated with figures of 30 at the first hour and 50 at the second hour. The white blood cell count was 10300/mm<sup>3</sup>. The C-reactive protein was increased to 21mg/l. The diagnosis of acute appendicitis was evoked and the patient was operated. At laparotomy through McBurney's approach, an appendix measuring 9 cm x 5 cm was discovered. The appendectomy was performed (figure 5). When the appendix was cut, mucus was seen to be flowing. This fact necessitated the resection of the appendicular stump taking away the base of the appendix on the cecum. The postoperative course was simple and the patient was discharged on day 3.

The anatomical-pathological examination of the appendicular specimen showed a simple appendicular mucocele without any degenerative focus. Colonoscopy was not performed. The patient was lost to follow-up after the first postoperative consultation at one month postoperatively.

## 7 22

## 8 Observation 5

A 68-year-old patient with known hypertension and G6P6 menopausal disease consulted for right iliac fossa pain that had been present for 3 months. The pain was dull without radiations, there was no weight loss. Clinical examination revealed a firm right iliac fossa mass adherent to the deep plane. Pelvic touch was normal. Ultrasound examination showed a hypoechoic mass of digestive appearance, heterogeneous, independent of the right psoas muscle and the bladder, measuring 169 mm long and 80 mm in diameter, pushing the right adnexa posteriorly. There was no adenopathy and no ascites. Colonoscopy showed a decrease of the colonic lumen, the poor colonic preparation did not allow to affirm the presence of an intra luminal lesion (tumor). Tumor markers were normal. The rest of the biological work-up was also normal (blood glucose, blood count, prothrombin rate). An indication for laparotomy was given for a tumor of the cecum. During the operation, there was no colonic tumor and a large appendicular tumor was discovered. The mass was oblong, elongated and well limited, 17.5 cm in length and 7 cm in diameter, with a healthy base, but with an epiploic call and small intestines. There was no adenopathy, ascites or mucoid effusion in the abdominal cavity. The uterus and adnexa were normal.

An appendectomy was performed. The postoperative course was simple and the patient was discharged at 8 days postoperatively. Anatomopathological analysis of the surgical specimen confirmed the diagnosis of appendicular mucocele without malignant cells, of mucinous cystadenoma type. Ultrasound of the abdomen done at 6 months was normal as was colonoscopy done at 12 months. Tumor markers could not be performed. The patient was lost to follow-up after 27 months.

## 9 Observation 6

A 55-year-old chronically constipated patient was accompanied by his parents in January 2019 for late postprandial vomiting associated with altered general condition evolving around 05 months. He had no abdominal pain, cessation of matter and gas, hematemesis, melena, and rectorrhagia. The patient had anorexia, reported asthenia and weight loss with an estimated weight loss of 2% of the body weight (Formal weight: 87 kg Current weight 83kg). The conjunctiva were slightly colored, the blood pressure was 130/90 mmHg, the pulse was 80 beats/min and the respiratory rate was 20cycles/min. There was an abdominal tumefaction from the right para-umbilical region to the right flank. The mass was round, painless, firm, mobile and dull on percussion. On digital rectal examination the prostate appeared to be enlarged, and the fingernail brought back soft stools. The diagnosis of cystic tumor of the mesentery was evoked. Due to post prandial vomiting, an oesogastroduodenal fibroscopy was performed and revealed an erythematous fundic gastropathy. Abdominopelvic CT scan showed a homogeneous liquid mass in favor of a mesenteric cyst corresponding to a giant cystic lymphangioma (Figures 6 and 7). Biologically, the hemoglobin level was 8.7 g/dL, the white blood cell count was 4600 and the platelets were 189000. Blood glucose was normal, as well as creatinine and prothrombin level (92%). Regarding tumor markers, CEA was 8ng/ and CA19-9 was 53 IU/ml. The patient was transfused and then operated on. Intraoperatively it was a large, firm, pearly white mass measuring 14 cm x 7 cm, located at the ileocaecal junction at the junction of the three caecal bands (Figure 8). The appendix was not seen. There was no adenopathy, no ascites. Palpation of the colonic frame did not reveal any tumor. We performed the removal of the mass (figure 9). The postoperative course was simple and the patient was discharged at D7 postoperatively. On anatomopathological examination it was an appendicular mucocele.

At 6 months post-op, the patient underwent a colonoscopy which was normal as were the tumor marker assays (CEA was 4.5ng/ml and CA19-9 was 17 IU/ml). Contacted by telephone in July 2021, the patient was doing well, and claimed to have regained his appetite and weight. III.

## 10 Discussion

Appendicular mucocele is a rare condition, observed in 0.2% to 0.7% of appendectomy specimens according to the literature [6][7][8]. The first Ivorian case seems to have been reported by Kouadio L et al in 2003 [9].

The treatment of appendiceal mucocele is surgical, balancing appendectomy in healthy tissue and right hemicolectomy. The surgical procedure can be conducted by laparotomy or laparoscopic surgery [10][11][12]. To prevent any risk of rupture of the appendicular mass, some authors perform the appendicular resection with automatic suture forceps [12][13][14]. Appendectomy is sufficient for a simple appendicular mucocele or a mucinous cystadenoma. When in doubt intraoperatively, some authors excise the caecal insertion of the appendicular base [12,15], others perform a resection of the cecum, and still others perform a right hemicolectomy [16,17].

In the present study, simple appendectomy was performed in five patients and excision of the caecal insertion of the appendicular base in one patient (observation 2). Intraoperatively, exploration of the colonic framework is important if the operation is performed by a large laparotomy or by laparoscopic surgery, otherwise a colonoscopy should be performed in the follow-up of the patient to look for a synchronous or metachronous colonic tumor [6,15]. In women it is essential to explore the adnexa [7,18].

It is important to avoid intraoperative rupture and to look for this rupture on anatomopathological examination of the specimen. This rupture has a poor prognosis because it exposes the risk of peritoneal pseudomyxoma [15,19]. This was not found in our observations.

Anatomopathological examination is essential in the subsequent management, especially if a simple appendectomy has been performed. If there is no invasion of the appendicular base, no metastatic embolism in the vessels and no perineural envelopment, a simple appendectomy can be performed, otherwise a right hemicolectomy with lymph node curage should be performed [1,15,20].

Long-term postoperative follow-up is crucial because cancers have been discovered after a followup of 12 to 33 months and a peritoneal pseudomyxoma occurred after a follow-up of more than 60 months [7,15]. In our study, no tumor recurrence or metastasis was observed after one year of follow-up. Only one patient is currently followed up, the others have been lost to follow-up.

## 11 IV.

## 12 Conclusion

Appendicular mucocele is a rare condition. The treatment of appendicular mucocele is surgical for two reasons; its potential malignancy on the one hand and on the other hand the risk of a peritoneal pseudomyxone or gelatinous

## 12 CONCLUSION

---

159 disease of the peritoneum in case of perforation. The evolution and prognosis are conditioned by the histological  
160 type, the surgical procedure and the peritoneal. Long-term follow-up after surgery is important because of the  
risk of possible recurrence.

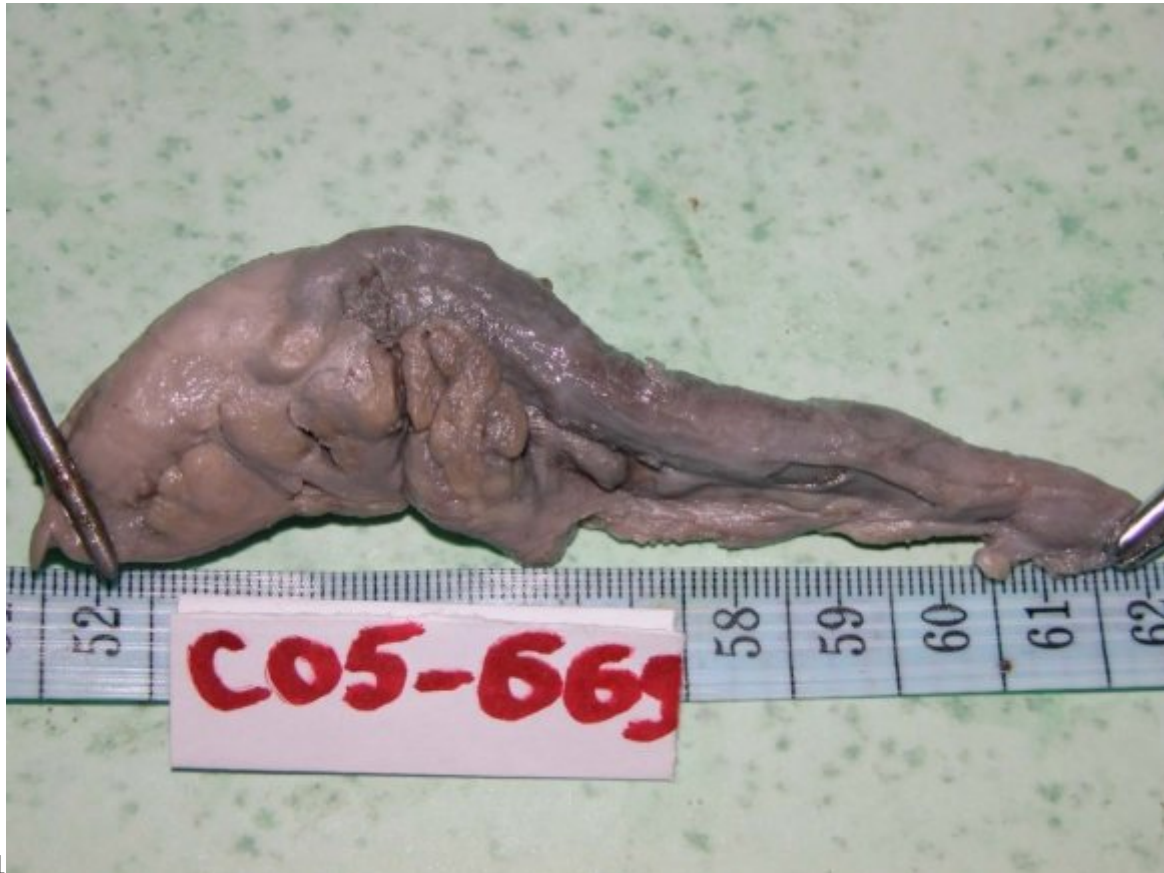

Figure 1: Figure 1 :

161



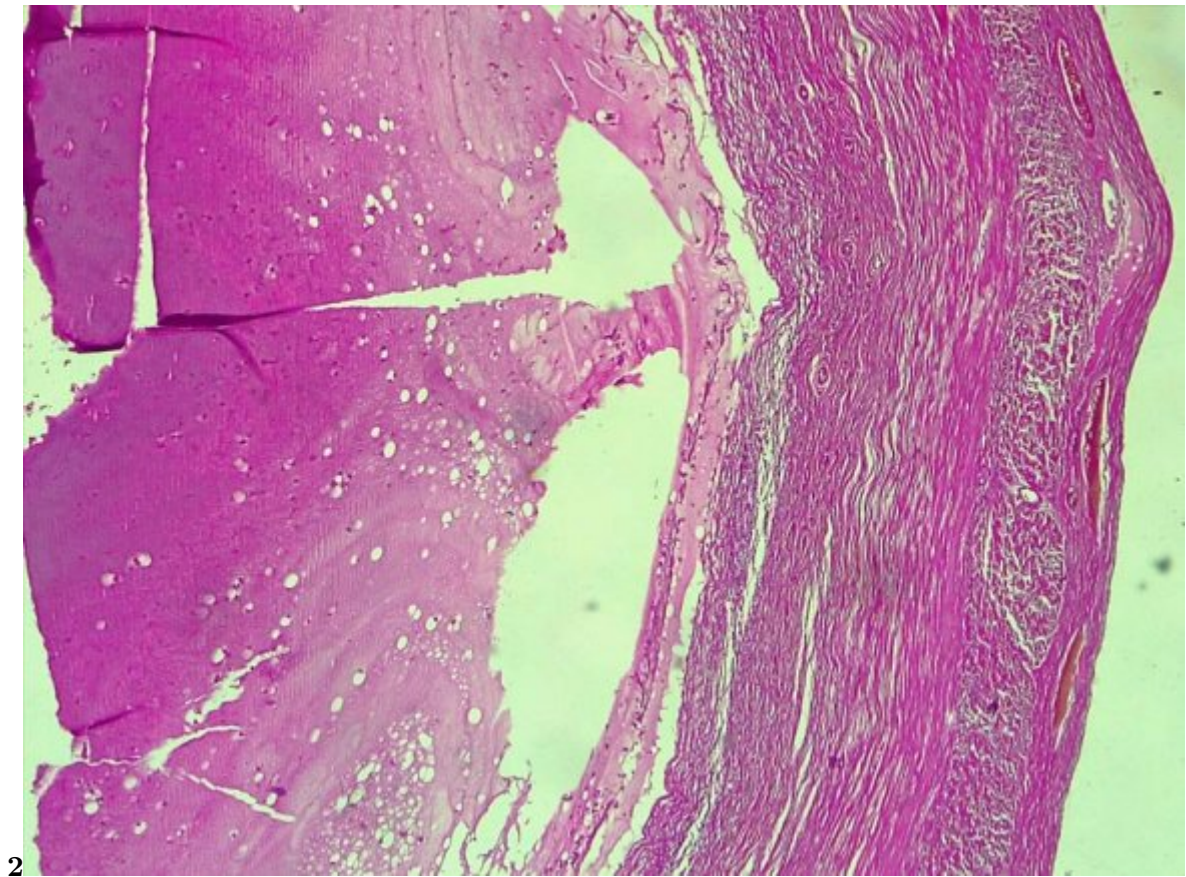


Figure 2: Figure 2 :

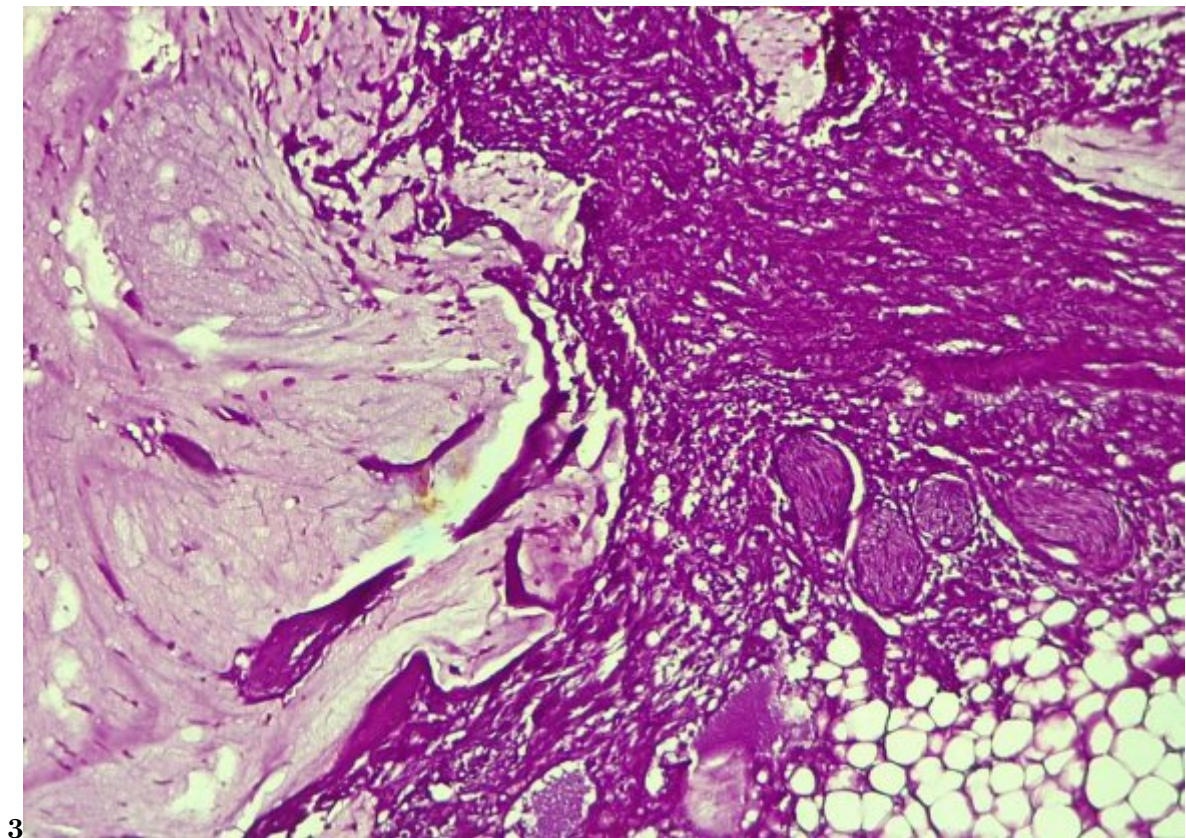


Figure 3: Figure 3 :

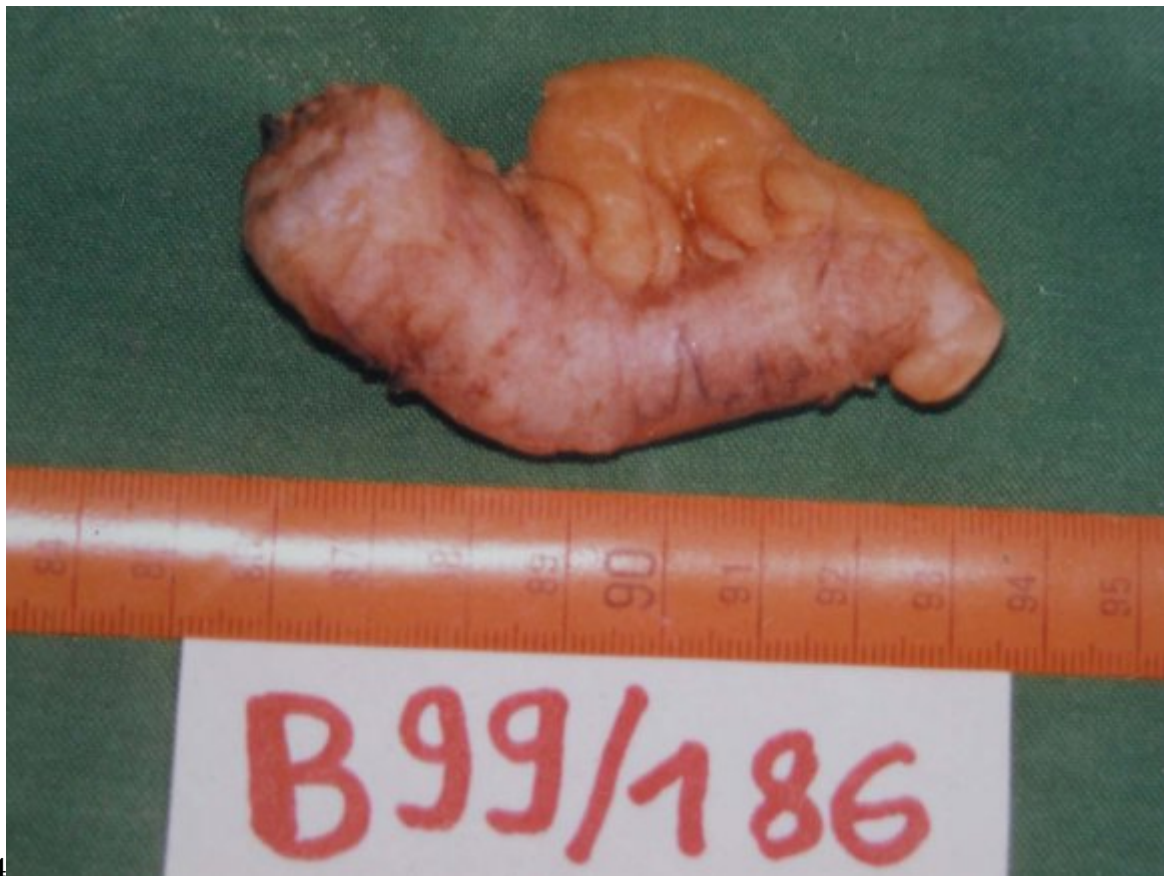
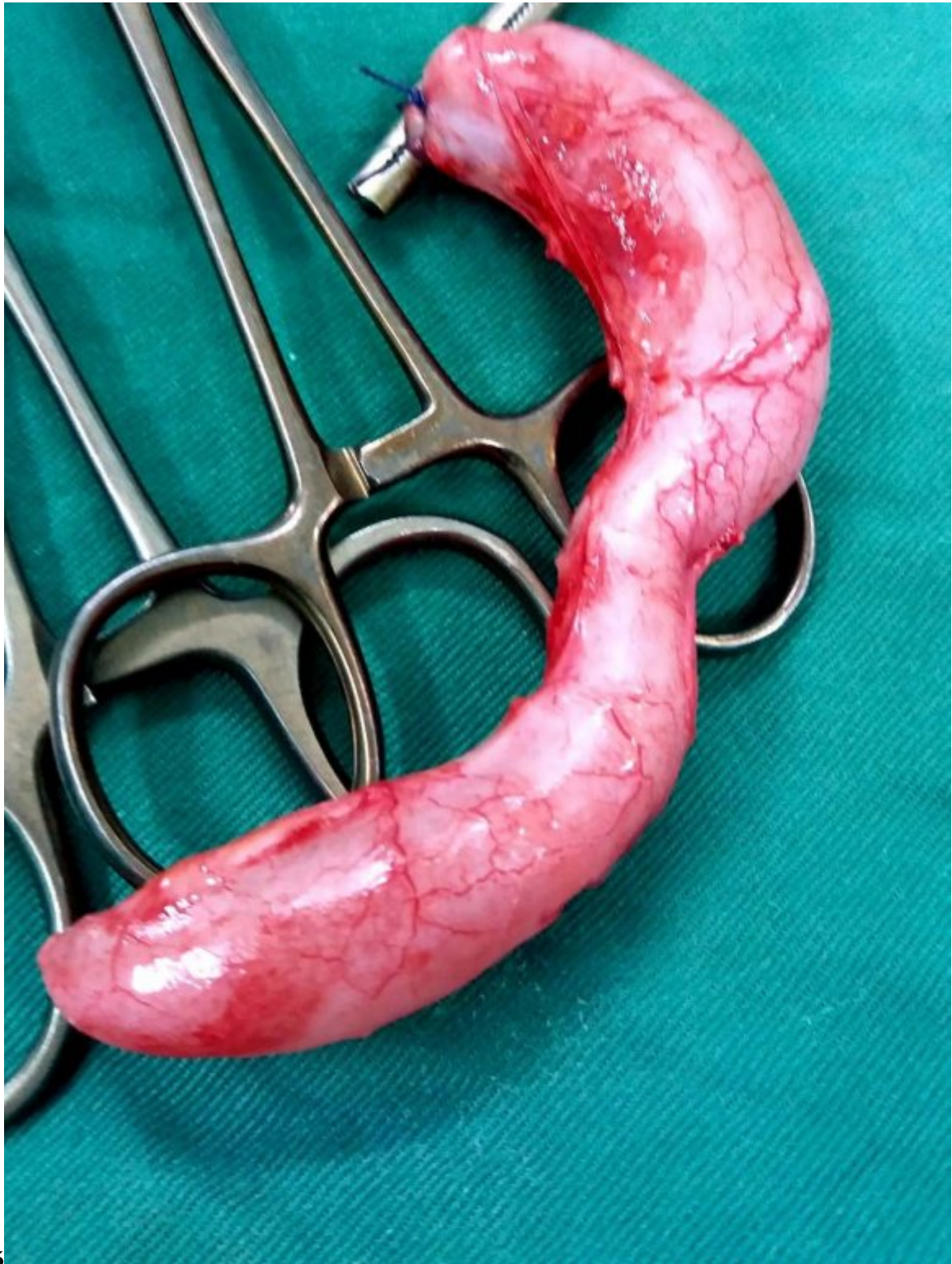
Figure 4: Figure 4 :





5

Figure 5: Figure 5 :

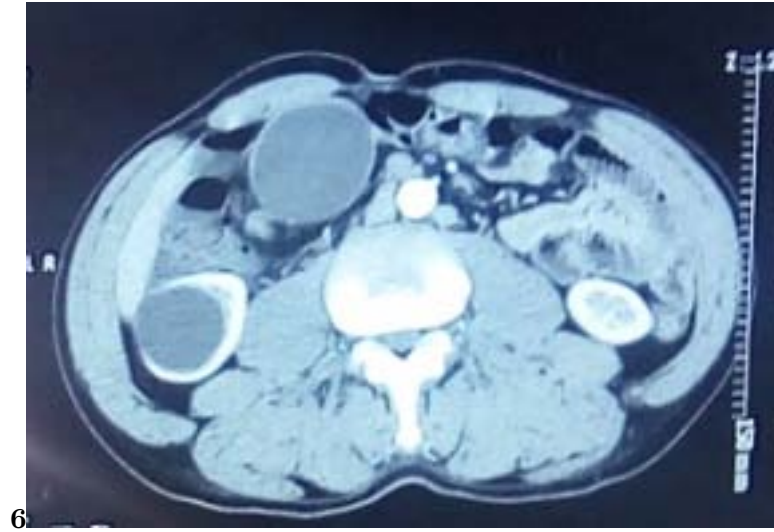


Figure 6: Figure 6 :

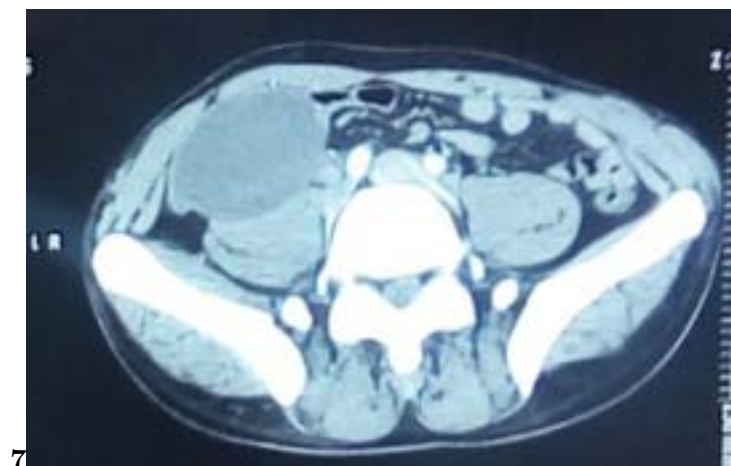
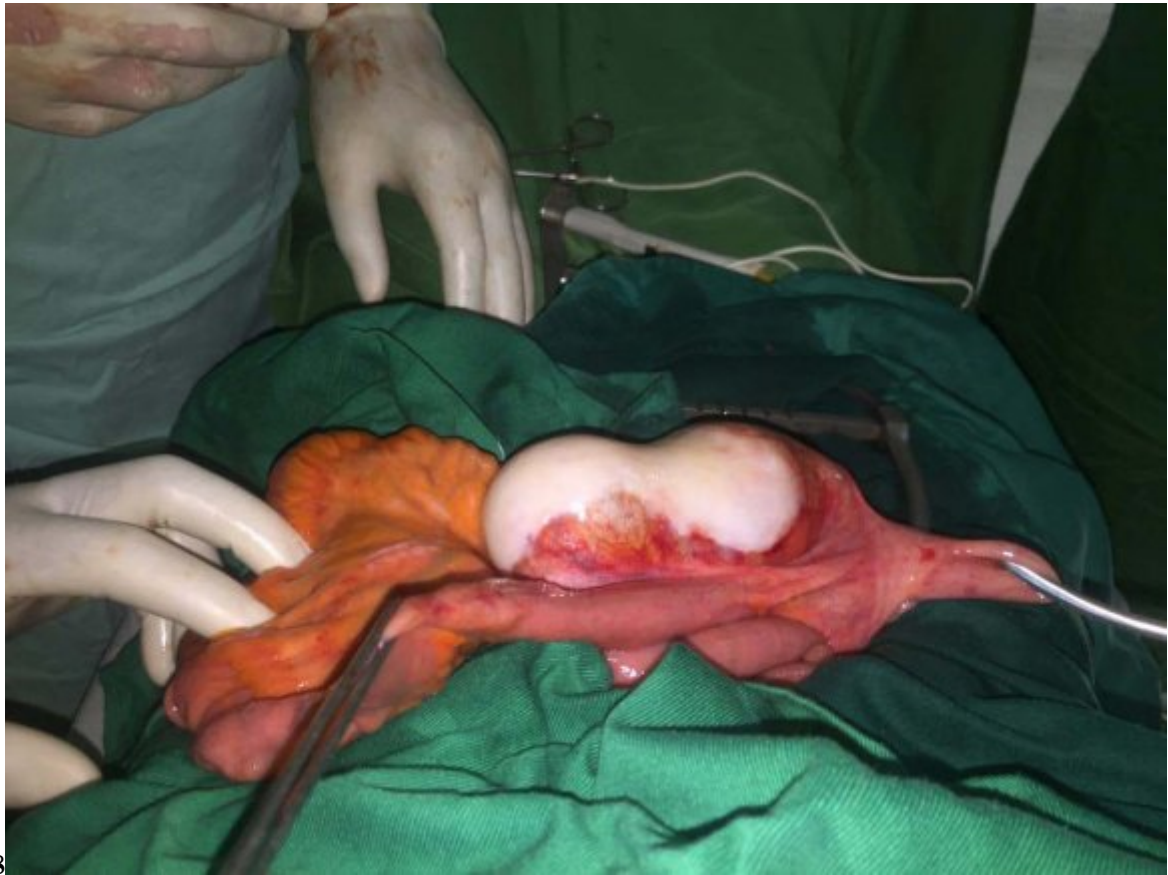

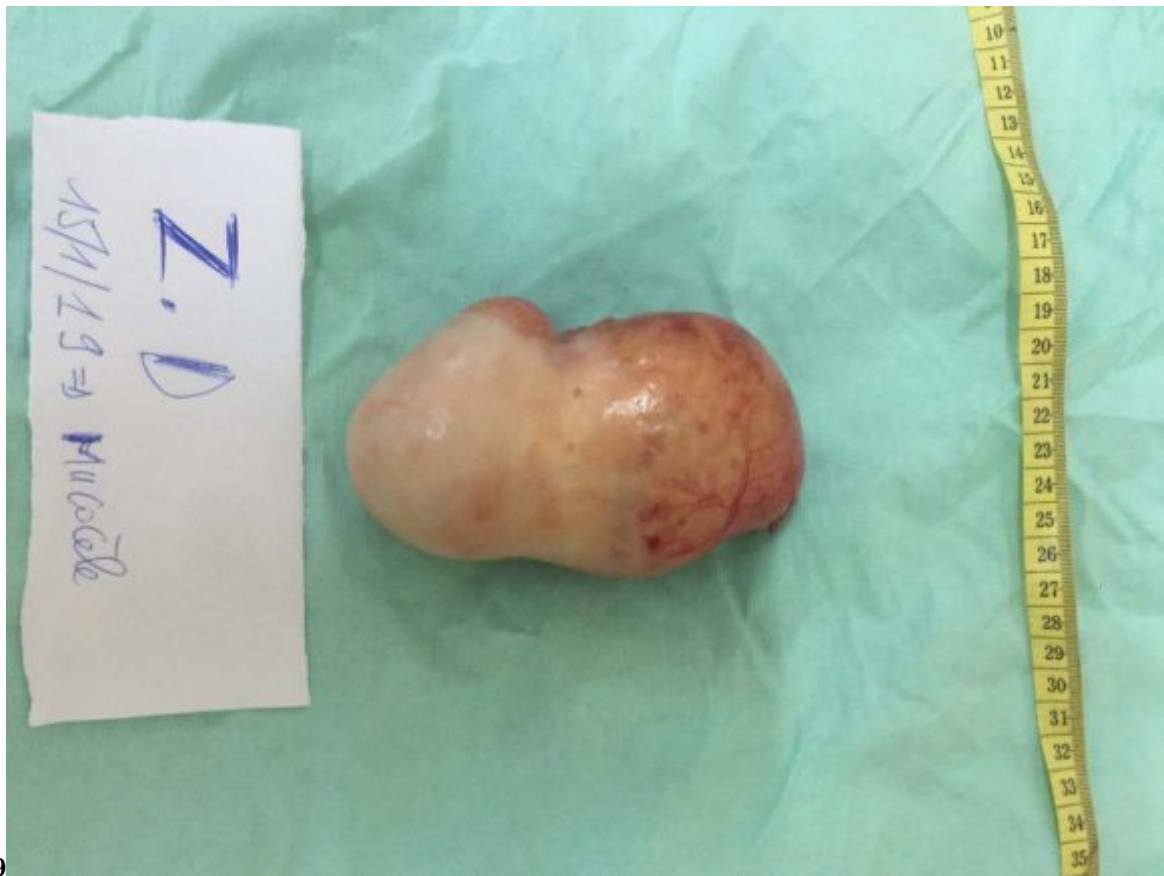Figure 7: Figure 7 :





8

Figure 8: Figure 8 :



9

Figure 9: Figure 9 :

---

Conflict of Interest: All the authors do not have any possible conflicts of interest.

[Euroasian Journal of Hepato-Gastroenterology] , *Euroasian Journal of Hepato-Gastroenterology* 6 (2) p. .

[Fairi et al. ( )] , A Fairi , R Detchev , J C Patel , Mucocèle Appendiculaire . *J Chir* 1995. 132 (10) p. . (intérêt de l'exérèse par coelioscopie)

[Weber et al. ( )] , G Weber , C Teriitehau , Y Goudard , De Saint-Blancard , P Minvielle , F Chavillot , C . *Mucocèle appendiculaire. Feuilles. de Radiologie* 2009. 49 (1) p. .

[Motsumi et al. ( )] 'A case report of a giant appendiceal mucocoele and literature review Pan'. M J Motsumi , P Motlaleselo , G Ayane , S O Sesay , J R Valdes . 10.11604/pamj.2017.28.106.13832. *African Medical Journal* 2017. 28 p. 106.

[Ejtehadi et al. ( )] *Acute Torsion of Appendicular Mucocoele*, F Ejtehad , J Brooks , Hassan Ali , H Vijay , V . 10.1155/2017/9409281. ID 9409281. <https://doi.org/10.1155/2017/9409281> 2017.

[Consulté le 12 juillet 2021] <https://studylibfr.com/doc/5529414/MA> Consulté le 12 juillet 2021,

[Peghini et al. ( )] 'Gelatinous disease of the peritoneum of appendiceal origin. A propos of 2 Senegalese cases'. M Peghini , P Barabe , J M Veillard , L Diagne , M D Sarr , P S Mbaye . *Dakar Med* 1989. 34 (1-4) p. .

[Sertkaya et al.] *Giant Appendicular Mucocoele Due to Mucinous Cystadenoma*, M Sertkaya , A Emre , E M Pircanoglu , O Peker , E Cengiz , M Karaagaç .

[Aletera and Ansari ( )] 'Incidental appendiceal mucinous neoplasm mimicking a left adnexal mass: A case report'. A Aletera , El Ansari , W . *International Journal of Surgery Case Reports* 2020. 74 p. .

[Foulaa et al. ( )] 'Laparoscopic management of appendicular mucinous cystadenoma, case report'. M S Foulaa , A M Alardhib , S A Othmanb , Mirza Garia , MK . *International Journal of Surgery Case Reports* 2019. 54 p. .

[Miraliakbari and Chapman ( )] 'Laparoscopic treatment of an appendiceal mucocoele'. R Miraliakbari , W H Chapman . *J Laparoendosc Adv Surg Tech Ann* 1999. 9 (2) p. .

[Ruiz-Tovar et al. ( )] 'Mucocoele of the appendix'. J Ruiz-Tovar , D G Teruel , M Gastineires , A S Dehesa , P L Quindos , E M Molina . *World J Surg* 2007. 31 (3) p. .

[Ghaddou et al. ( )] *Mucocèle Appendiculaire: diagnostic, traitement, pronostic (à propos de 30 cas) Service des urgences chirurgicales viscérales*, Y Ghaddou , M Bouali , K Elhattabi , F Z Bensardi , R Lefriyekh , A Fadil . 2014. 35. CHU Ibn Rochd Casablanca Maroc

[Kouadio et al. ( )] 'Mucocèle appendiculaire: un diagnostic différentiel auquel il faut penser'. L N Kouadio , K Kouadio , T H Turquin . *Med Afr N* 2000. 47 (3) p. .

[Wakunga et al. ( )] 'Mucocèle appendiculaire: à propos d'un cas observé à Lubumbashi'. E Wakunga , O Mukuku , Bugemem , M Tshiband , A Kipili , P Mobambo . *Pan African Med J* 2014. 18 p. 36.

[Moujahid et al. ( )] 'Mucocèle appendiculaire: à propos de dix cas'. M Moujahid , A Ali , A Achour , M I Janati . *Journal africain du cancer* 2010. 2 (2) p. . (Google Scholar)

[Armstrong et al. ( )] 'Mucocèle appendiculaire»: intérêt d'une coelio conversion de prudence et d'un suivi'. O Armstrong , J Lepourry , E Frampas , CassagnauE . *Gastroentérologie Clin Biol* 2010. 34 (6-7) p. .

[Pitiakoudis et al. ( )] 'Mucocèle of the appendix a report of five cases'. M Pitiakoudis , A K Tsaroucha , K Mimidis , A Polychronidis , G Minopoulos , C Simopoulos . *Tech Cooproctol* 2004. 2 p. .

[Société Savante des maladies et cancers de l'appareil digestif: tumeurs appendiculaires (hors TNE) / SNFGE. org-Société savante des maladies et cancers de l'appareil digestif: tumeurs appendiculaires (hors TNE) / SNFGE. org-Société savante médicale française d'hépatogastroentérologie et oncologie,

[Zissin et al. ( )] 'Synchronous mucinous tumors of the ovary and the appendix associated with pseudomyxoma peritonei: CT findings'. R Zissin , G Gayer , A Fishman , E Edelstein , M Shapiro-Feinberg . *Abdom Imaging* 2000. 25 p. .

[Beyrouiti et al. ( )] « La maladie gélatineuse du péritoine ». *Presse Médicale*, M I Beyrouiti , R Beyrouiti , F Frikha , B A Mohamed , A Mohamed , B A Hazem . 2007. 36 p. .

[Loungrath et al. ( )] '« Pseudomyxome péritonéal ou maladie gélatineuse du péritoine»: nouveaux concepts et nouvelle prise en charge thérapeutique'. R Loungrath , S Causeret , C Brigand , F N Gilly , O Glehen . *Ann. Chir* 2005. 130 (2) p. .