



GLOBAL JOURNAL OF MEDICAL RESEARCH
SURGERIES AND CARDIOVASCULAR SYSTEM
Volume 13 Issue 2 Version 1.0 Year 2013
Type: Double Blind Peer Reviewed International Research Journal
Publisher: Global Journals Inc. (USA)
Online ISSN: 2249-4618 & Print ISSN : 0975-5888

Atypical Atrioventricular Nodal Reentry Tachycardia with Eccentric Retrograde Left-Sided Activation of Coronary Sinus

By Trajkov I., Kovacevik D. & Gjorgov N.

Clinical Hospital Acibadem-Sistina, Macedonia

Abstract - Background: Recent anatomical and electro-physiological studies demonstrated, that in the human atrioventricular node there are two main extension, rightward and leftward posterior nodal extension (LPNE). The occurrence of eccentric retrograde atrial activation has been demonstrated to be from 6 to 8% in patients with AVNRT by several previous reports.

Objectives: The study was performed to confirm that standard right atrium ablation is effective and successful for atrioventricular node reentry tachycardia (AVNRT) with eccentric retrograde left-sided activation, masquerading a tachycardia which look like as a tachycardia using left accessory pathway.

Methods and Results: During a 7 years period (from 2002 to 2008), 865 consecutive patients underwent electrophysiological study. In the group with atrioventricular node reentry tachycardia (AVNRT) there were 178 patients. In the group with typical fast-slow AVNRT (162 pts) there was concentric retrograde activation of the both atrium.

Keywords : *atypical AVNRT, eccentric retrograde activation, catheter ablation.*

GJMR-I Classification : *NLMC Code: WX 218*



ATYPICAL ATRIOVENTRICULAR NODAL REENTRY TACHYCARDIA WITH ECCENTRIC RETROGRADE LEFT-SIDED ACTIVATION OF CORONARY SINUS

Strictly as per the compliance and regulations of:



Atypical Atrioventricular Nodal Reentry Tachycardia with Eccentric Retrograde Left-Sided Activation of Coronary Sinus

Trajkov I. ^α, Kovacevik D. ^σ & Gjorgov N. ^ρ

Abstract - Background: Recent anatomical and electrophysiological studies demonstrated, that in the human atrioventricular node there are two main extension, rightward and leftward posterior nodal extension (LPNE). The occurrence of eccentric retrograde atrial activation has been demonstrated to be from 6 to 8% in patients with AVNRT by several previous reports.

Objectives: The study was performed to confirm that standard right atrium ablation is effective and successful for atrioventricular node reentry tachycardia (AVNRT) with eccentric retrograde left-sided activation, masquerading a tachycardia which look like as a tachycardia using left accessory pathway.

Methods and Results: During a 7 years period (from 2002 to 2008), 865 consecutive patients underwent electrophysiological study. In the group with atrioventricular node reentry tachycardia (AVNRT) there were 178 patients. In the group with typical fast-slow AVNRT (162 pts) there was concentric retrograde activation of the both atrium. The 16 patients were with atypical AVNRT (10 pts with slow-slow AVNRT and 6 pts with LPNE). The ablation was performed, in all patients in the triangle of Koch on the slow pathway of atrioventricular node. The successful rate of ablation was 99.4 % (177/178 pts). The incidence of AVNRT with eccentric retrograde activation was 3.4%. In the follow up period (16 ± 12 months), there is no recurrence of AVNRT in the group with LPNE.

Conclusions: This study demonstrated the different electrophysiologic characteristics between the AVNRT patients with eccentric and concentric retrograde atrial activation. Standard ablation, but a little bit higher in the triangle of Koch, closer to the fast pathway, in the right atrium is effective and successful for AVNRT with retrograde left eccentric conduction in the coronary sinus.

Keywords : atypical AVNRT, eccentric retrograde activation, catheter ablation.

I. INTRODUCTION

A V nodal reentrant tachycardia (AVNRT), the most common form of paroxysmal supraventricular tachycardia, is characterized by nearly simultaneous activation of the atria and ventricles. The human compact AV node is small, just 3-5 mm, has a very long rightward posterior extension that travels down to the area between the tricuspid annulus and down to the floor the CS ostium.

Authors ^{α σ ρ} : Clinical Hospital Acibadem-Sistina, Department of cardiology, Skopje, Macedonia. E-mails : drivantrajkov@yahoo.com, drtrajkov@acibademsistina.com.mk

In the typical slow/fast AVNRT the rightward inferior extension of the AV node is using for antegrade slow pathway conduction and the fibers crossing the tendon of Todaro for retrograde fast pathway conduction.

The classical electrophysiological definition of the dual nodal pathway represents an abrupt increase of nodal A-V conduction of at least 50 ms between the Atrial and His (AH) potential intervals, with an anterograde block in the fast pathway conduction and selective conduction over the slow pathway. This phenomenon is known as a AH jump.

a) Ventricular - Atrial (VA) conduction time

A typical AVNRT is considered when the VA interval is measured either from the onset of ventricular activation (on surface ECG to the earliest deflection of the atrial activation in the His bundle electrogram or high right atrium) is < 60 ms, or < 95 ms respectively. Retrograde AV junctional pathways have been characterized as fast (HA interval < 100 ms), intermediate (100–200 ms), or slow (> 200 ms).

b) Retrograde atrial activation sequence during AVNRT

AVNRT has been traditionally classified as slow-fast or typical AVNRT, and fast-slow or atypical AVNRT, according to the conventional description of dual AV junctional pathways. The fast pathway of the re-entry circuit runs superiorly and anteriorly in the triangle of Koch, whereas the slow pathway runs inferiorly and posteriorly close to the coronary sinus ostium. Indeed, in the majority of slow-fast cases of AVNRT, the site of the earliest atrial activation is close to the apex of Koch's triangle, near the AV node-His bundle junction. In the fast-slow form, the site of the earliest atrial activation is usually recorded posterior to the AV node near the orifice of the coronary sinus.

c) "Left-Variant" of atypical AVNRT

During reentry tachycardia, a small numbers of patients with AVNRT, have eccentric coronary sinus (CS) activation. The earliest retrograde activation site is on the left-sided from the coronary sinus, masquerading as tachycardia using a left accessory pathway. According the recent electrophysiological studies, from the Atrio-Ventricular (AV) node there are two extensions, infero-

posterior and a leftward posterior nodal extension (LPNE), which take a part in the left variant of atypical AVNRT.

The purpose of this study is to assess the incidence of atypical AVNRT with eccentric CS activation, and to determinate the efficacy of the slow pathway ablation in patients with AVNRT with left side extension.

II. METHODS

The study was conducted from April 2002 to October 2008 at the Clinic for Cardiology, in Skopje, Republic of Macedonia. During a 7 year period 178 consecutive patients underwent electrophysiological study for management of Atrioventricular Nodal reentry tachycardia. The indication for electrophysiology study (EPS) in these patents was symptomatic tachycardia, previous recorded tachycardia with surface electrocardiogram,

a) Electrophysiology testing and ablation protocol

Informed written consent was obtained in all patients before the procedure. Antiarrhythmic agents were discontinued for at least 4 half-lives. Three 6F quadripolar electrode catheters were introduced into the right femoral vein and positioned in the high right atrium (HRA), His bundle (HB) region, and in the right ventricular (RV) apex. One 6F decapolar electrode catheter was introduced in the left cubital or left subclavian vein for mapping of the coronary sinus (CS). The diagnostic catheters were used for either recording of local electrogram or pacing. For radiofrequency ablation, a quadripolar electrode catheter with a 4 mm distal electrode and a deflectable tip was used. Radiofrequency (RF) current was generated from ATAKR II (Medtronic). The catheter position was anatomically monitored with fluoroscopy. Surface ECG lead I, II, and V1, and intracardiac electrograms from various sites were simultaneously displayed and recorded on Pruka 4000. (GE Medical) The pacing stimuli were delivered through a programmable stimulator (Bloom Electrophysiology). Complete anterograde and retrograde electrophysiological studies for atrioventricular node (AVN) were conducted in each patient using incremental

and extrastimulus testing techniques. Conduction intervals and refractory periods of AVN were measured and defined. After that was performed programmed electrical stimulation was applied in order to induce the clinical tachycardia. Baseline electrophysiological evaluation and tachycardia induction were performed during incremental pacing and extra stimulation (basic cycle length: 400 - 600 msec) from the right atrium and right ventricle.

Retrograde atrial activation sequence during atypical left variant AVNRT was determined by the intracardiac electrograms recorded from the high RA (HRA), His-bundle (HB) region and the Coronary Sinus (CS). The earliest retrograde atrial activation site was confirmed by mapping the right side of the interatrial septum and the CS. The absence of accessory pathway was confirmed by basic electrophysiological procedures.

Induced AVNRT's were classified into slow-slow, fast-slow, and slow-fast forms according to the previously described criteria

b) Slow pathway (SP) ablation

The SP ablation was performed in all patients at the conventional region at the right inferoseptal area between the tricuspid annulus and the CS ostium during sinus rhythm targeting the SP potential.

Inducibility of AVNRT was assessed after each ablation. Successful ablation was defined as elimination of the retrograde SP conduction for at least 30 minutes after the last energy application.

c) Statistical Analysis

Data was analyzed using commercially available statistical program. Continuous variables were reported as mean \pm SD. Categorical variables were reported as percentages.

III. RESULTS

a) Patient Characteristics

In the group with atypical AVNRT (16 pts), ten patients were with classified as slow/slow AVNRT, and 6 were classified with retrograde left eccentric conduction. (table1). In all patients there was no identifiable underlying heart disease.

Result of electrophysiological studies	Patients	% of 178
AVNRT slow/fast	159	89.3%
AVNRT slow/slow	10	5.6%
AVNRT with retrograde left eccentric conduction	6	3.4%
AVNRT with bystander AVRT	2	1.1 %
AVNRT with AV node diseased	1	0.26%
Total ablated patients	173	97.1%
<i>Without ablation</i>	5	2.9 %

AVNRT - atrioventricular nodal reentrant tachycardia,
AVRT - atrioventricular reentry tachycardia

Table 1 : Patients with AVNRT

b) Basic electrophysiological characteristic

The basic electrophysiological characteristics are summarized in table 2. All patients showed dual AV node pathways, defined as a AH jump (prolongation of AH interval of more than 50 msec) between two consecutive programmed decremental stimulation cycles with either single or double extrastimuli from right atrium. Retrograde dual AV nodal pathway physiology

was also demonstrated by a sudden jump-up in H-A (VA) interval and a simultaneous shift of the earliest retrograde atrial activation site from the superoseptal to the inferoseptal area during ventricular extra stimulation. In the group of AVNRT with LPNE (6 pts), the earliest retrograde atrial activation was recorded at the proximal coronary sinus (C1.2) (fig.1.2).

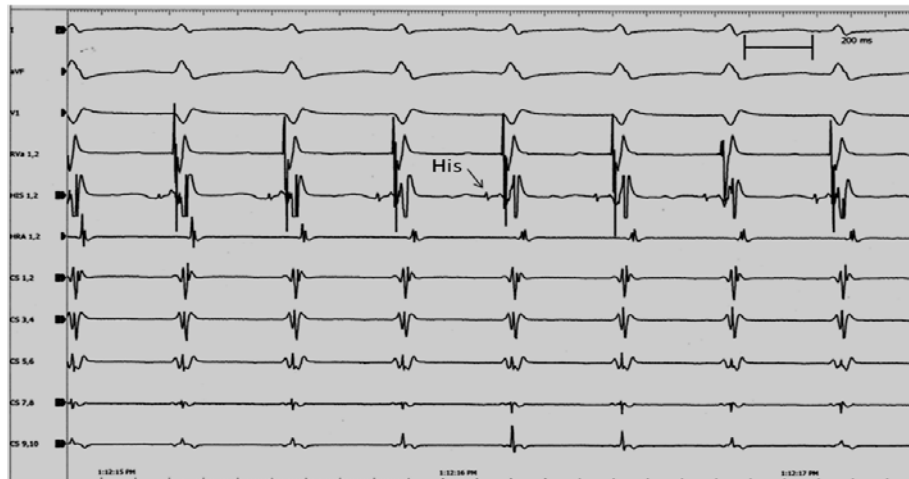


Figure 1 : Intracardiac electrocardiogram of the AVNRT (slow/fast)

Слика 1. Внатрешен срцев електрокардиограм на АВНРТ (спора/брза)

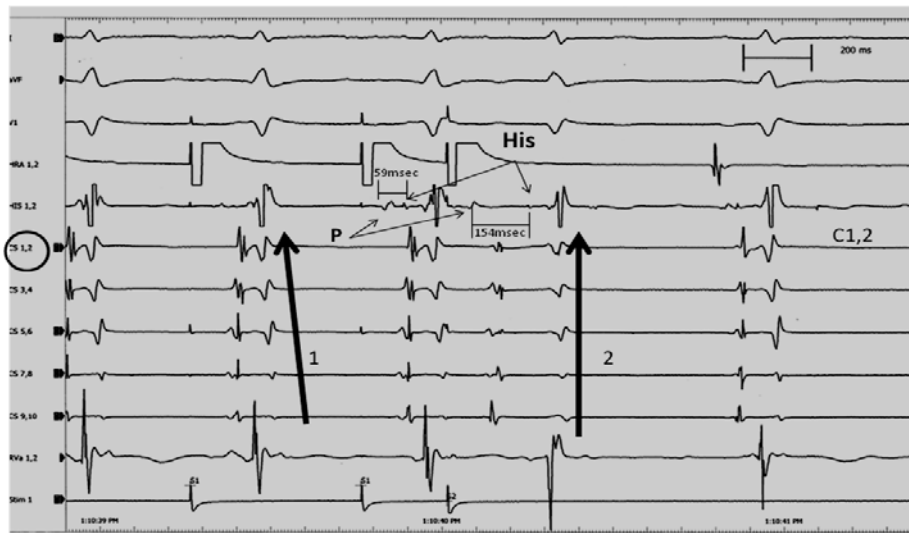


Figure 2 : Intracardiac electrocardiogram in patient with AVNRT with retrograde left eccentric conduction. Earliest retrograde atrial activation is from distal coronary sinus electrodes (C1, 2), with eccentric impulse propagation (arrow 1). During the program pacing stimulation from high right atrium, there was a Atrium-His jump (AHJ) from 59 to 154 msec, with concentric retrograde atrial activation (arrow 2).

There was no difference in electrophysiological characteristics in each subform of AVNRT. There were significantly more another atrial arrhythmia (atrial flutter/fibrillation-figure 3) in the group of atypical AVNRT, especially in the subform of LPNE (table 2).

	AVNRT slow/fast (163pts)	AVNRT slow/slow (10pts)	AVNRT LPNE (6 pts)	p
AH (msec)	75 ± 25msec	86 ± 38msec	80 ± 21msec	n.s.
HV (msec)	35 ± 10 msec	32 ± 11msec	39 ± 9 msec	n.s.
AH jump	163 (100%)	10 (100%)	6 (100%)	
VA – retrograde jump	45pts(28%)	1 (10%)	0(0%)	0.01
VA Wenckebach point	410 ± 34 msec	401±55msec	422±19 msec	n.s.
junctional rhythm during ablation	155pts (95%)	8pts (80%)	5pts (83%)	n.s
Atrial flater/fibrillation during EPS	15pts (9.2%)	6pts (60%)	5pts(83%)	.001
RF energy number application	3 (1-6)	5(2-10)	4.6 (1-9)	n.s.

LPNE - leftward posterior nodal extension

EPS – electrophysiological study

Table 2: Intracardiac characteristic of the patients during electrophysiological studies

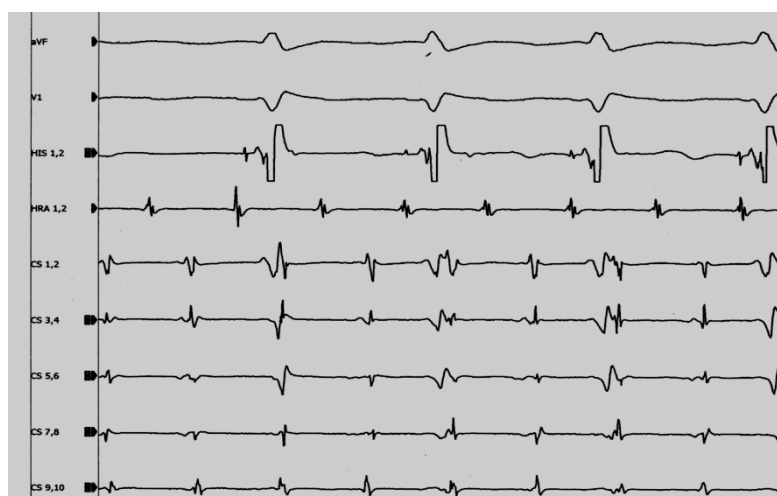


Figure 3: Atrial flutter during electrophysiological study

Слика 3. Предкоморен флатер за време на електрофизиолошка студија

IV. PATIENTS WITH ECCENTRIC CS ACTIVATION

Typical ablation sites between the tricuspid annulus and the anterior edge of the CS ostium produces accelerated junctional rhythm (rightward inferior extension injury) but fails to eliminate AVNRT. Because of that, delivering of the radiofrequent (RF) energy was in the higher parts in the triangle of Koch. We prefer to reach the target of the leftward inferior extension along the roof of the proximal CS. We avoid positioning the catheter straight upward to the roof or in lumen of CS during ablation because in that position is very easy to injured the fast pathway or ostium of CS. (figure 4). Among six patients with the eccentric CS activation, the SP ablation was performed at the right inferoseptal region during sinus rhythm. In all six patients, accelerated junctional rhythm was induced during energy applications. After the mean of 4,6 (from 1 to 9 times of the energy application) at the right inferoseptum and midseptum, atypical AVNRT was non inducible. Four of the patients (4/6) atypical AV there

was nodal echo beats (one or two). The mean Wenckebach CL of the retrograde SP significantly prolonged after the right inferoseptal ablation. (Before vs. after ablation: 405 ± 63 msec vs 466 ± 37 msec; $P = 0.012$). There was no complication related to the SP ablation.

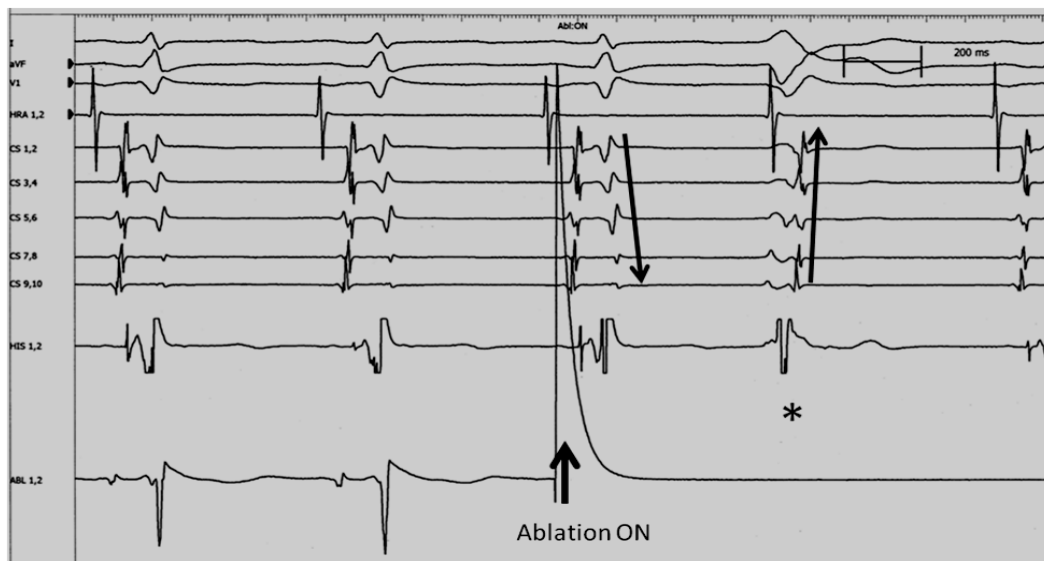


Figure 4 : Intracardiac electrocardiogram of the ablation in the higher parts in the triangle of Koch with shifting of the earliest retrograde atrial activation site from the superoseptal to the inferoseptal area (*nodal extra beat) without accelerated junctional rhythm.

Post ablation follow up

No recurrence of AVNRT was observed during a mean ambulatory follow-up period of 16 ± 12 months in all 6 patients.

V. DISCUSSION

a) Major Findings

In our study, atypical AVNRT was observed in 9% of patients (16/178). The eccentric CS activation pattern was found in (6/16 pts). It's 37.5% of the patients with atypical AVNRT. But only 3.4 % in hole group of AVNRT (6/178 pts) were with left variant. The conventional right inferoseptal SP ablation did not abolish eccentric retrograde conduction from CS, but the clinical tachycardia was not inducible in any of the 6 patients with left variant of AVNRT. Standard right atrium ablation is effective and successful for AVNRT with retrograde left eccentric conduction in the coronary sinus.

b) Incidence of eccentric coronary sinus activation pattern in AVNRT

Hwang et al.^[3] reported that the earliest retrograde atrial activation was recorded within the CS in 0% (0/310 patients) among typical form and in 43% (20/46 patients) among atypical form, while Nam et al.^[1] reported its incidence of 6% (3/52 patients) among typical form and 80% (8/10 patients) among atypical form. Chen et al.^[5] reported its incidence of 8% (16/211 patients) among typical form and 14% (2/14 patients) among atypical form.

c) Slow pathway ablation for atypical AVNRT with eccentric coronary sinus activation

Whether the retrograde left-sided atrionodal connection constitutes the critical component of the

reentrant circuit or only an innocent bystander in atypical AVNRT with the eccentric CS activation pattern is controversial.^[1-3] Furthermore, whether the eccentric CS activation pattern during atypical AVNRT is the hallmark of AVNRTs that require left-sided ablation remains to be elucidated. Jackman et al.^[4] reported that the leftward PNE constituted the retrograde limb of the reentrant circuit and the SP ablation at the earliest retrograde activation site within the proximal CS was, therefore, required to eliminate atypical AVNRT with the eccentric CS activation pattern. Conversely, others postulated that the retrograde left-sided atrionodal connection was an innocent bystander; therefore, conventional right-sided SP ablation was sufficient to eliminate inducibility of atypical AVNRTs with the eccentric CS activation pattern.^[3,5] Otomo^[6], among eight patients with the eccentric CS activation, the standard right-sided ablation lengthened the VA Wenckebach CL and rendered atypical AVNRT nonsustained in seven of eight patients (88%), possibly suggesting partial injury to the retrograde eccentric SP induced by the right-sided ablation. The retrograde eccentric SP conduction was eliminated only after the SP ablation at the earliest atrial activation site within the CS.

VI. CONCLUSION

Atrioventricular node reentry tachycardia can be associated with eccentric retrograde left-sided activation, masquerading as tachycardia using a left accessory pathway. In our study, incidence of atypical left variant of AVNRT was 3.4%. We performed standard RF ablation, but a little bit higher in the triangle of Koch, closer to the fast pathway. In that position, ablation in the right atrium is effective and successful for AVNRT

with retrograde left eccentric conduction in the coronary sinus.

REFERENCES RÉFÉRENCES REFERENCIAS

- Nam GB, Rhee K-S, Kim J, Choi KJ, Kim YH. Left atrionodal connections in typical and atypical atrioventricular nodal re-entrant tachycardias: activation sequence in the coronary sinus and results of radiofrequency catheter ablation. *J Cardiovasc Electrophysiol* 2006;17:1–7.
- Vijayaraman P, Kok LC, Rhee B, Ellenbogen KA. Unusual variant of atrioventricular nodal re-entrant tachycardia. *Heart Rhythm* 2004;2:100–102.
- Hwang C, Martin DJ, Goodman JS, Gang ES, Mandel WJ, Swerdlow CD, Peter CT, Chen PS. Atypical atrioventricular node reciprocating tachycardia masquerading as tachycardia using a left-sided accessory pathway. *J Am Coll Cardiol* 1997;30:218–225.
- Lockwood D, Otomo K, Wang Z, Forresti S, Nakagawa H, Beckman K, Scherlag BJ, Patterson E, Lazzara R, Jackman WM: Electrophysiologic characteristics of atrioventricular nodal reentrant tachycardia: Implications for the reentrant circuits In: Zipes DP, Jalife J, eds. *Cardiac Electrophysiology. From Cell to Bedside. Fourth Edition*. Philadelphia, PA: W.B. Saunders, 2004, pp. 537-557.
- Chen J, Anselme F, Smith TW, Zimetbaum P, Epstein LM, Papageorgiou P, Josephson ME: Standard right atrial ablation is effective for atrioventricular nodal reentry with earliest activation in the coronary sinus. *J Cardiovasc Electrophysiol* 2004; 15:2-7.
- Otomo K., Okamura H., Noda T., Satomi K., Shimizu W., Suyama K., Kurita T., Aihara N., Kamakura S., "Left-Variant" Atypical Atrioventricular Nodal Reentrant Tachycardia: Electrophysiological Characteristics and Effect of Slow Pathway Ablation within Coronary Sinus. *J Cardiovasc Electrophysiol*. 2006; 17(11):1177-1183.
- Nawata H, Yamamoto N, Hirao K, Miyasaka N, Kawara T, Hiejima K, Harada T, Suzuki F. Heterogeneity of anterograde fast-pathway and retrograde slowpathway conduction patterns in patients with the fast-slow form of atrioventricular nodal reentrant tachycardia: electrophysiologic and electrocardiographic considerations. *J Am Coll Cardiol* 1998;32:1731–1740.
- Goldberger J, Brooks R, Kadish A. Physiology of "atypical" atrioventricular junctional reentrant tachycardia occurring following radiofrequency catheter modification of the atrioventricular node. *Pacing Clin Electrophysiol* 1992;15:2270–2282.
- Owada S, Iwasa A, Sasaki S, Higuma T, Kimura M, Kobayashi T, Ashikaga K, Okumura K. "V-H-A pattern" as a criterion for the differential diagnosis of atypical AV nodal reentrant tachycardia from AV reciprocating tachycardia. *Pacing Clin Electrophysiol* 2005;28:667–674.
- McGuire MA, Yip AS, Lau KC, Lo CW, Richards DA, Uther JB, Ross DL. Posterior ("atypical") atrioventricular junctional reentrant tachycardia. *Am J Cardiol* 1994;73:469–477.
- Sakabe K, Wakatsuki T, Fujinaga H, Oishi Y, Ikata J, Toyoshima T, Hiura N, Nishikado A, Oki T, Ito S. Patient with atrioventricular node reentrant tachycardia with eccentric retrograde left-sided activation: treatment with radiofrequency catheter ablation. *Jpn Heart J* 2000;41:227–234.

GLOBAL JOURNALS INC. (US) GUIDELINES HANDBOOK 2013

WWW.GLOBALJOURNALS.ORG