

# Neurogenic Bladder Revealing a Pernicious Anemia: One Case Report and Literature Review

Omar Riyach<sup>1</sup>

<sup>1</sup> Department of urology, University Hospital Center Hassan II-FES, MOROCCO.

*Received: 10 December 2013 Accepted: 31 December 2013 Published: 15 January 2014*

---

## Abstract

Background: Neurogenic or neuropathic bladder is defined as any defective functioning of the bladder caused by impaired innervations. Pernicious anemia is a rare cause of neurogenic bladder and it is often accompanied by other neurological manifestations. The standard treatment is based on parenteral vitamin administration. We report a unique case of pernicious anemia revealed by a neurogenic bladder successfully managed by vitamin B12 administration. Case presentation: A 45-year-old man presented with lower urinary tract symptoms (LUTS) with urine retentions. The patient was an important postvoid residual volume. The uroflowmetry result of the patient was low. Cystoscopy reveals a normal urethra, prostatic fossa, and bladder. Urodynamic testing demonstrated a failure voiding bladder. The diagnostic of pernicious anemia was suspected in laboratory exams which have showed megaloblastic anemia and Serum antibodies to gastric parietal cells, the diagnostic was confirmed by gastric biopsy.

---

*Index terms—*

## 1 Introduction

urogenic lower urinary tract dysfunction or neurogenic bladder (NGB) dysfunction may be caused by various diseases and events affecting the nervous system controlling the lower urinary tract [1]. It occurs equally in men and women [2]. Pernicious anemia is a rare cause of myelopathy linked to a deficiency of vitamin B12. The urinary disturbances are part of the neurological signs. But it has never seen that a neurogenic bladder was the first and the only neurological sign of this pathology. We report one case of pernicious anemia revealed by neurogenic bladder with complete urinary function recovery after treatment with vitamin B 12, and we analyzed the clinical data and reviewed the relevant literature published.

## 2 II.

## 3 Case Presentation

A 45-year-old man presented with mild to moderate lower urinary tract symptoms (LUTS) of one year duration with frequent history of catheterizations for urine retentions. He has no past history of infection, urethral stricture disease, or benign prostatic hypertrophy. The patient was comfortable and had no sensation of needing to void. The physical examination reveals no sensitive or motor deficits. A catheter was placed but the patient was unable to void after the catheter was removed. A postvoid residual volume obtained by noninvasive bladder ultrasonography reveals 1000 mL (figure 1). Retrograde and voiding urethro-cystography was normal (figure 2). The uroflowmetry result of the patient was Qmax: 6, 3 mL/sec. Cystoscopy reveals no obstructive lesions and a normal-appearing urethra, prostatic fossa, and bladder. Urodynamic testing demonstrated a normal capacity, compliant bladder The patient was unable to sense filling at any volume and is also unable to generate any voiding contraction (figure 3). Examination of the peripheral blood showed the red blood cell count to be 2,

42 2 million, WBC 2800, hemoglobin 7.9 Gm. per 300 cc., hematocrit 28 per cent, and average cell volume 12.7  
43 Cu. microns. In the stained blood films the erythrocytes varied greatly in size and in shape, reticulocytes were  
44 slightly less than a per cent, and the percentage of neutrophils was reduced with many of them having multilobed  
45 nuclei. Laboratory exams showed also revealed Serum antibodies to gastric parietal cells in the peripheral blood  
46 examination, the diagnosis of pernicious anemia was selected by highlighting a chronic gastritis fundic atrophy  
47 and intrinsic factor antibodies. The patient was treated by vitamin B12 orally at 500 mg / day and received a  
48 folic acid. The evolution was marked by a disappearance under treatment of urinary disturbances, macrocytosis  
49 correction and normalization of vitamin B12. At 6 months follow-up, clinical symptoms had improved, and  
50 postvoid residual (PVR) was 75 mL.

## 51 4 Discussion

52 Pernicious anemia (PA) (also known as Biermer's disease [3] and Addisonian anemia [4]) is a macrocytic anemia  
53 due to vitamin B12 (cobalamin) deficiency, which, in turn, is the result of deficiency of intrinsic factor [5]. The  
54 deficiency of intrinsic factor is a consequence of the presence of atrophic body gastritis (ABG), which results in the  
55 destruction of the oxyntic mucosa, and thus, the loss of parietal cells, which normally produce chlorhydric acid as  
56 well as intrinsic factor [6]. The term PA is sometimes used as synonym for cobalamin deficiency or for macrocytic  
57 anemia, but to avoid ambiguity, PA should be reserved for conditions that result from impaired secretion of  
58 intrinsic factor and atrophy of oxyntic mucosa [7]. PA is considered an autoimmune disorder due to the frequent  
59 presence of gastric autoantibodies directed against intrinsic factor, as well as against parietal cells. PA is often  
60 considered a synonym of autoimmune gastritis, because PA is thought to be the end stage of an autoimmune  
61 process that results in severe damage of the oxyntic gastric mucosa [8]. Recent experimental and clinical data  
62 strongly suggest an involvement of long-standing *Helicobacter pylori* (*H pylori*) infection in the pathogenesis of  
63 ABG and PA, but it is still under debate whether PA may be included among the long-term consequences of *H*  
64 *pylori* gastritis [9]. Disturbed genitourinary function is a well known late result of neurologic disease in patients  
65 with pernicious anemia but the details of the functional deficit as related to the general neurologic condition as  
66 well as the eventual prognosis have received very little study. The earliest symptom to appear in male patients  
67 is usually impotence. Hesitancy, weakness of the urinary stream, and finally urinary retention, dribbling, or  
68 overflow incontinence develop later. Exceptionally our patient presented a neurogenic bladder as the first and the  
69 only symptom of pernicious anemia. Neurologic examination in these patients invariably shows cutaneous sensory  
70 impairment in the lower legs and diminished or absent vibratory sense to the level of the iliac crests. Evidence of  
71 lateral column disease may or may not be present. Cystometric examination usually discloses the presence of an  
72 atonic bladder paralysis with impaired sense of bladder filling, very low intravesical pressure, increased bladder  
73 capacity and variable amounts of residual urine. Most observers agree that bladder neck and sphincter symptoms  
74 may disappear with treatment of the pernicious anemia [10,11,12]. As we have shown in our case the patient  
75 regained normal bladder function as regards both symptoms and cystometric findings after a few of liver therapy  
76 by vitamin B12. The prognosis when the paralysis is of longer duration is undoubtedly less favorable. Urologic  
77 measures designed to avoid mechanical damage to the detrusor muscle, urinary tract infection, and bladder neck  
78 obstructions are of prime importance during the period of recovery. The clinical management of patients with PA  
79 is based on the treatment of cobalamin deficiency which is able to correct the anemia, whereas the neurological  
80 complications may be corrected only if the replacement treatment is given soon after their onset. The therapeutic  
81 recommendations for PA with regard to dosage and administration of vitamin B12 substitution treatment are  
82 divergent [13]. According to our protocol, a higher dosage of cobalamin is used orally at 500 mg / day in addition  
83 of folic acid. PA is an often silent and underdiagnosed autoimmune disease, because its onset and progression  
84 are very slow, According to the literature the urinary disorders occur at an advanced stage of the disease and  
85 respond to treatment with vitamin B 12. For the first time in the English literature, a case of pernicious anemia  
86 diagnosed by neurogenic bladder as the only manifestation of this pathology is presented. Our findings indicate  
87 that treatment of urinary retention associated with pernicious anemia is managed by intermittent catheterization  
88 with oral vitamin B12 administration, with complete urinary function recovery.

89 IV.

## 90 5 Conclusion

91 Neurogenic bladder is one of disturbed neurologic function that occurs in pernicious anemia, but it has never been  
92 reported that this symptom is the only manifestation of this disease. Our case is the first of its kind to expose  
93 this clinic particularity, and still the best example for a reversible neurogenic bladder with complete recovery of  
94 urinary function after medical treatment.

## 95 6 a) Consent

96 Written informed consent was obtained from the patient for publication of this manuscript and accompanying  
97 images. A copy of the written consent is available for review by the Editor-in-Chief of this journal. <sup>1</sup>

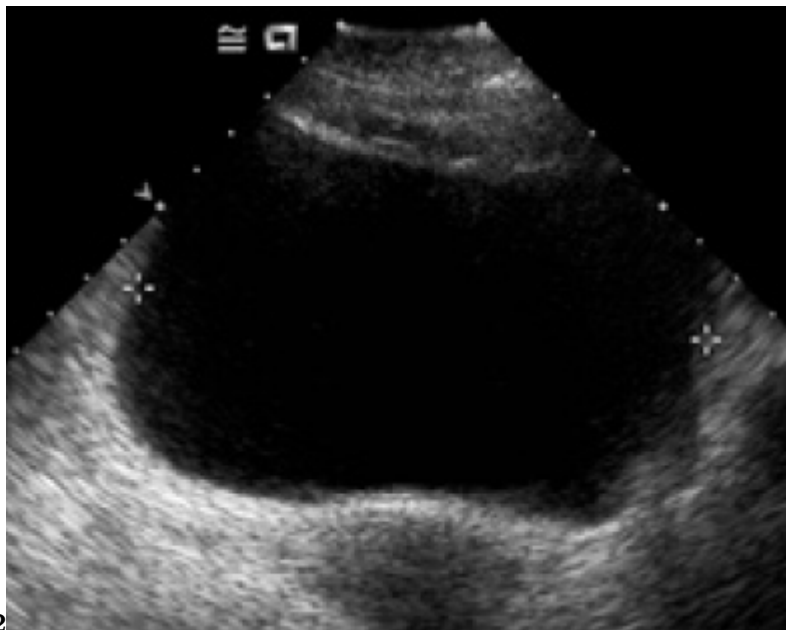
---

<sup>1</sup>© 2014 Global Journals Inc. (US)



1

Figure 1: Figure 1 :



2

Figure 2: Figure 2 :

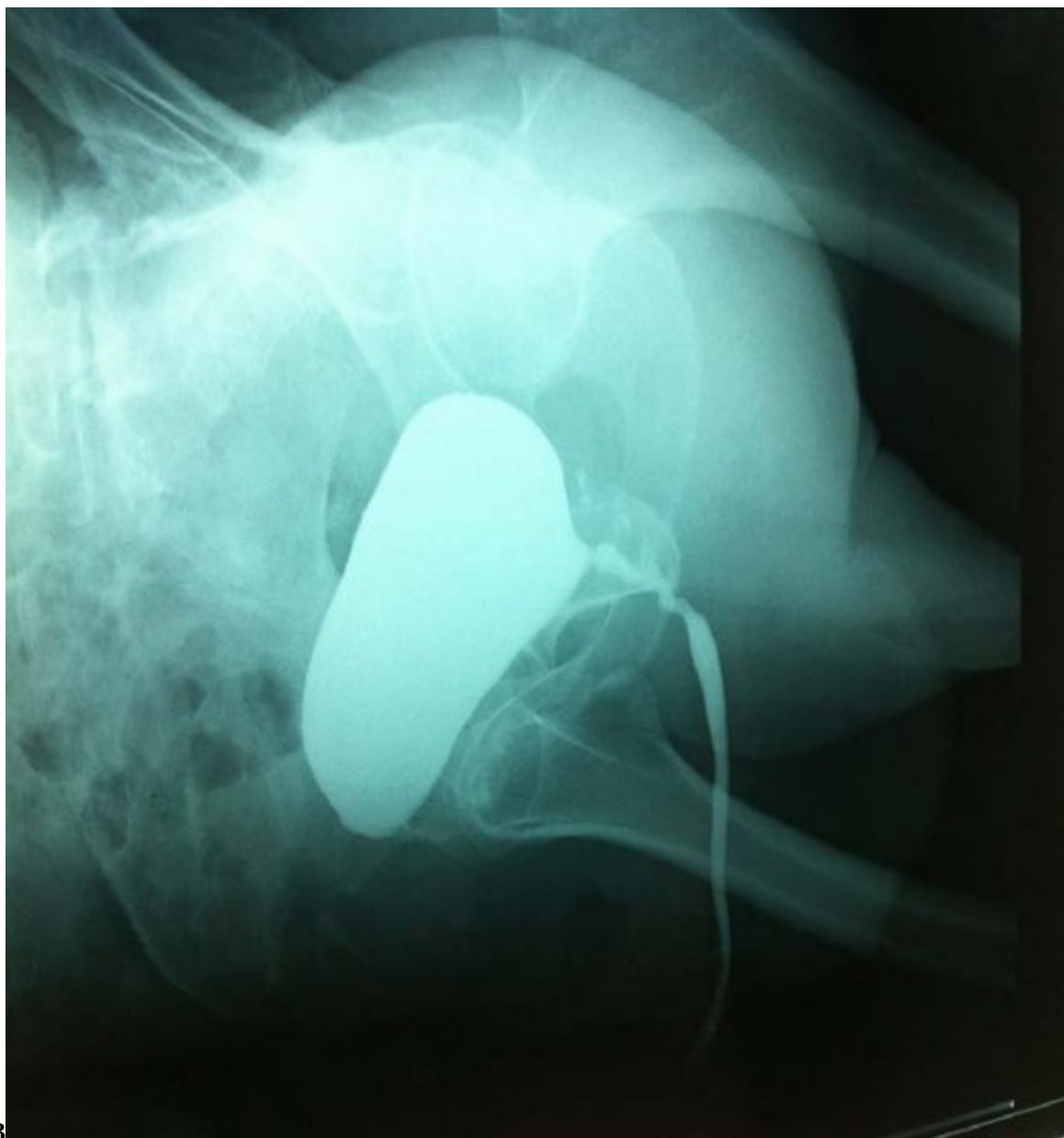


Figure 3: Figure 3 :

- 
- 98 [Curtis et al. ()] ‘Acute urinary retention and urinary incontinence’. L A Curtis , T S Dolan , R D Cespedes .  
99 *Emerg Med Clin North Am* 2001. 19 (3) p. .
- 100 [Meecham and Jones ()] ‘Addison’s disease and Addisonian anaemia’. J Meecham , E W Jones . *Lancet* 1967. 1  
101 p. .
- 102 [Toh et al. ()] ‘Autoimmune gastritis and pernicious anemia’. B H Toh , P A Gleeson , S Whittingham , I R Van  
103 Driel . *The autoimmune diseases*, N R Rose, I R Mackay (ed.) (St. Louis, MO) 1998. Academic Press. p. .  
104 (3rd ed)
- 105 [Zittoun ()] ‘Biermer’s disease’. J Zittoun . *Rev Prat* 2001. 51 p. .
- 106 [Hvas and Nexø ()] ‘Diagnosis and treatment of vitamin B12 deficiency—an update’. A M Hvas , E Nexø .  
107 *Haematologica* 2006. 91 p. .
- 108 [Babior (ed.) ()] *Erythrocyte disorders: Anemias related to disturbance of DNA synthesis (megaloblastic anemias)*,  
109 B M Babior . Williams JW, Beutler E, Erslev AJ, Lichtman MA (ed.) 1998. New York: McGraw-Hill. p. .  
110 (4th ed)
- 111 [D’elios et al. ()] ‘Gastric autoimmunity: the role of Helicobacter pylori and molecular mimicry’. M M D’elios ,  
112 B J Appelmelk , A Amedei , M P Bergman , Del Prete , G . *Trends Mol Med* 2004. 10 p. .
- 113 [Farquharson and Graham ()] ‘Liver therapy in the treatment of subacute combined degeneration of the cord’.  
114 R F Farquharson , D Graham . *Canadian M. A. J* 1930. 23 p. 137.
- 115 [Wintrobe et al. ()] ‘Megaloblastic and nonmegaloblastic macrocytic anemias’. M M Wintrobe , G R Lee , D R  
116 Boggs , T C Bithell , J Foerster , J W Athens , J N Lukens , M M Wintrobe , G R Lee , D R Boggs , T C  
117 Bithell , J Foerster , J W Athens , J N Lukens . *Clinical hematology*, 1981. p. . (8th ed)
- 118 [Lee et al. ()] ‘Sleisenger & Fordtran’s gastrointestinal and liver disease: pathophysiology, diagnosis, manage-  
119 ment’. E L Lee , M ; Feldman , M Feldman , L S Friedman , M H Sleisenger . *Philadelphia: Saunders* 2002.  
120 p. . (Gastritis and other gastropathies. 7th ed)
- 121 [Stedman’s online medical dictionary Lippincottt Willi-ams Wilkins (2007)] ‘Stedman’s online medical dictio-  
122 nary’. <http://www.stedmans.com>. Accessed *Lippincottt Willi-ams & Wilkins*, July 23, 2007.
- 123 [Ungley and Suzman] ‘Subacute combined degeneration of the cord: symptomatology and effects of liver therapy’.  
124 C C Ungley , M M Suzman . *Brain* 52. (2.71, 192.9)
- 125 [Hyland and Farquharson ()] ‘Subacute combined degeneration of the spinal cord in pernicious anemia’. H H  
126 Hyland , R F Farquharson . *Arch. Neurol. & Psychiat* 1936. 36 p. 66.